

# Use of medical sodium hyaluronate gel in surgical removal of a glass intraocular foreign body

Journal of International Medical Research

48(9) 1–5

© The Author(s) 2020

Article reuse guidelines:

[sagepub.com/journals-permissions](https://sagepub.com/journals-permissions)

DOI: 10.1177/0300060520956856

[journals.sagepub.com/home/imr](https://journals.sagepub.com/home/imr)

Jun Zhang , Hanyan Mao, Xi Zou and Guohua Deng 

## Abstract

A 38-year-old healthy man presented to our department of ophthalmology after sustaining an ocular injury in a glass explosion more than 10 days prior. A glass intraocular foreign body (IOFB) was found in the left eye. During surgical removal of the IOFB, medical sodium hyaluronate gel was used to detach the IOFB from the retina; this avoided damage to the retina and made it easier for the surgeons to grasp the glass fragment. Multiple surgical instruments have been developed to help remove IOFBs; however, many optic hospitals have limited surgical instruments, thus increasing the difficulty of the operation. The application of sodium hyaluronate gel, a widely used agent, may be a new technique in IOFB surgery.

## Keywords

Intraocular foreign body, glass, hyaluronate gel, surgery, ocular trauma, case report

Date received: 29 March 2020; accepted: 14 August 2020

## Introduction

Ocular trauma accounts for 7.00% to 9.22% of all bodily injuries.<sup>1</sup> Traumatic eye injuries involving intraocular foreign bodies (IOFBs) may result in severe visual loss. After identifying the size and location using computed tomography and B-scan ultrasonography, a diamond-coated IOFB forceps should be used to remove 1- to 3-mm glass shards, whereas >3-mm glass fragments require a diamond-coated forceps.<sup>2</sup> However, glass

fragments are difficult to grasp because of their smooth surface. In the present case, we used medical sodium hyaluronate gel, a

---

Department of Ophthalmology, The Third People's Hospital of Changzhou, Changzhou, Jiangsu, China

### Corresponding author:

Guohua Deng, Department of Ophthalmology, The Third People's Hospital of Changzhou, 300 Lanlin North Road, Changzhou, Jiangsu 213000, China.

Email: [czydgh@163.com](mailto:czydgh@163.com)



Creative Commons Non Commercial CC BY-NC: This article is distributed under the terms of the Creative

Commons Attribution-NonCommercial 4.0 License (<https://creativecommons.org/licenses/by-nc/4.0/>) which permits non-commercial use, reproduction and distribution of the work without further permission provided the original work is attributed as specified on the SAGE and Open Access pages (<https://us.sagepub.com/en-us/nam/open-access-at-sage>).

widely used agent in ophthalmic surgery, for easy removal of an IOFB.

## Case report

A 38-year-old healthy man presented to the Department of Ophthalmology of The Third People's Hospital of Changzhou in July 2019 after having sustained an eye injury in a glass explosion more than 10 days previously. After administration of emergency treatment at a local hospital, most of the glass fragments were removed; however, the patient complained of visual loss and photophobia. Upon examination, his visual acuity was 0.3 in the right eye and counting fingers in the left eye. Several small pieces of glass remained in the cornea, and the nasal side of the cornea was thinner than the lateral side, which may have been due to entrance of the IOFB (Figure 1). The chamber was stable without cells or flare. The pupil was round, measured 3 mm in diameter, and was sensitive to light, and the lens appeared transparent but was not very clear. Computed tomography (Figure 2) and ultrasonography (Figure 3) were performed to identify the size and position of the IOFB.

To avoid secondary retinal damage, we surgically removed the IOFB. Intraoperatively, we found that the glass fragment was too large, smooth, and tightly attached to the retina to be grasped with a claw forceps (Figure 4). Therefore, we injected medical sodium hyaluronate gel for intraocular use (Healon; Johnson & Johnson Vision, Jacksonville, FL, USA) into the posterior

segment to protect the retina and slow the decline of the glass. After picking up one side of the glass using a retinal brush, the Healon flowed under the glass, and the glass stayed upright because of the viscosity of the Healon. The glass was finally grasped with the claw forceps (Figures 5 and 6).

Postoperatively, the patient recovered well. One week after the surgery, optical coherence tomography of the site of IOFB removal showed no abnormality of the

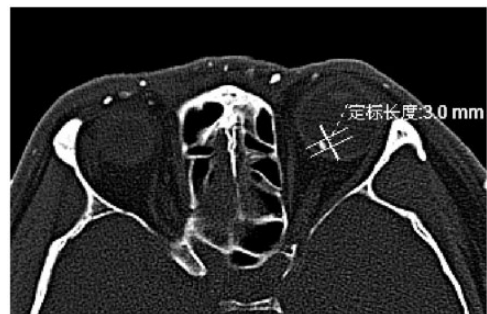


Figure 2. Computed tomography findings.




Figure 3. Ophthalmic ultrasound findings.



Figure 1. Anterior segment optical coherence tomography of the cornea.

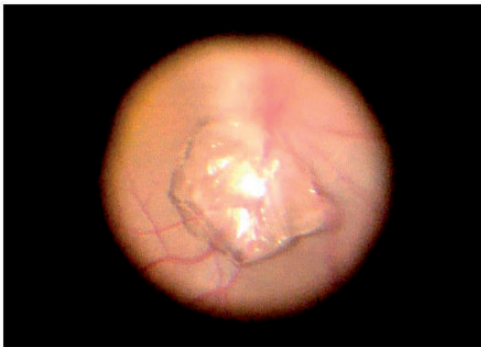retina, and the visual acuity of the left eye was 0.3 (Figure 7).

## Discussion

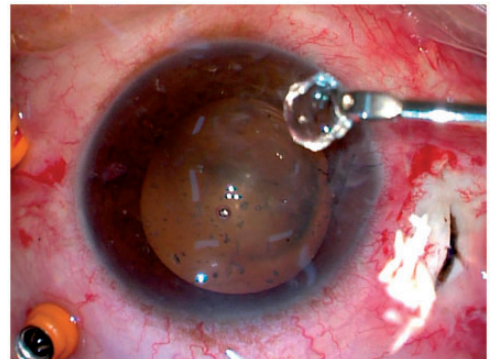
Because of inadequate occupational health and safety training, the incidence of IOFBs is high in China and results in vision loss in many patients.<sup>3</sup> Unlike metallic and vegetative IOFBs, glass pieces have stable chemical properties and cannot be extracted in some cases. One review revealed no complications when glass IOFBs were left intact, while 13 of 43 eyes that underwent surgical removal sustained iatrogenic retinal damage.<sup>4</sup>

However, mechanical complications such as macular injury and retinal laceration may arise from the retained glass.<sup>5</sup> In the present case, the piece of glass was >3 mm in diameter, and we decided to surgically remove the IOFB to avoid secondary retinal damage.

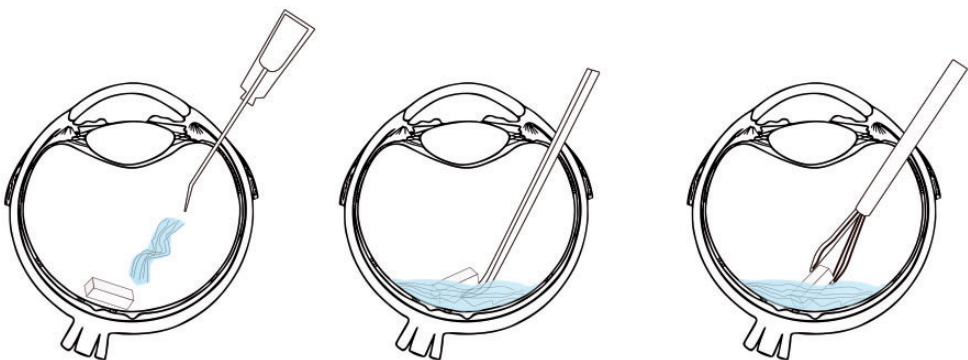
Previous reports have indicated that metallic IOFBs of >3 mm and nonmetallic IOFBs require specialized IOFB grasping forceps for removal.<sup>6</sup> However, many hospitals have limited surgical instruments, and removal of IOFBs with normal grasping forceps may be challenging. Application of sodium hyaluronate gel, a widely used



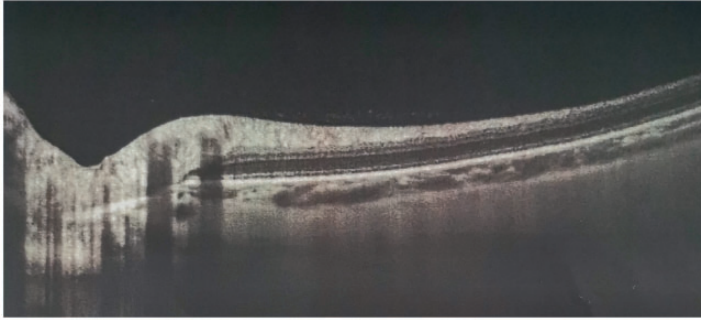
**Figure 4.** Large glass piece tightly attached to the retina.



**Figure 6.** Removal of the piece of glass with a claw forceps.



**Figure 5.** Foreign body removal. From left to right: hyaluronate gel was injected onto the retina, the piece of glass was pried up with the retina brush and remained upright, and the glass was removed with a claw forceps.



**Figure 7.** Postoperative optical coherence tomography image of the site of foreign body removal.

agent, may be a new and useful technique in IOFB surgery.

Because a piece of glass is flat, it is difficult to grasp its wide edge when it is attached to the retina. However, its narrow edge may be easier to grasp when in the upright position. The density of glass is approximately  $2.5\text{ g/cm}^3$ , and that of heavy water is  $1.77\text{ g/cm}^3$ ; this indicates that a glass IOFB may not float upward even after injecting heavy water. Sodium hyaluronate (density of approximately  $1.1\text{ g/cm}^3$ ) has high viscosity and flows slowly when applied with external force. In this case, after we had picked up one side of the glass using a retinal brush, Healon flowed under the glass. Because of its high viscosity, the Healon flowed slowly and held the glass upright for a few seconds, making it easier to grasp.

Sodium hyaluronate is used as a viscoelastic gel to facilitate healing and regeneration of surgical wounds. It prevents damage to the endothelial layer of the cornea, functions as a lubricant, eliminates physical damage to other tissues, and maintains an adequate operative space and depth of the anterior chamber. It is particularly important in glaucoma surgery, anterior segment surgery, and corneal transplantation.<sup>7</sup> In addition, sodium hyaluronate reduces the intraocular pressure in implant surgery. Furthermore, it can be used to treat dry

eye, to reposition and unroll the retina following detachment, and to treat anterior synechiae lysis, tissue separation, and mechanical adhesions.<sup>8,9</sup>

In the present case, sodium hyaluronate gel was used as a viscoelastic agent to keep the glass fragment upright for a few seconds, facilitating easier grasping of the IOFB.

## Conclusion

Sodium hyaluronate is used worldwide. If appropriate forceps for IOFB surgery are not available or the IOFB position needs adjusted and held, sodium hyaluronate gel may be effectively used because of its high viscoelasticity.

## Authors' contributions

Jun Zhang: Data and image curation, Hanyan Mao and Xi Zou: Writing – original draft preparation, Guohua Deng: Writing – reviewing and editing.

## Declaration of conflicting interest

The authors declare that there is no conflict of interest.

## Ethical approval


The privacy rights of human subjects was observed, and informed consent was obtained from the patient for performance of the described procedures and the publication of

this case report. Ethics committee approval was not obtained because the intraocular use of hyaluronate gel is approved by the National Medical Products Administration of China and is widely used in ocular surgeries in China; additionally, the removal of intraocular foreign bodies is a common surgery in our hospital.

### Funding

This study was supported by the Science and Technology Support Program of Changzhou (CE20175039), Science and Technology Support Program of Changzhou (CJ 20190062), Science and Technology Project for Talents of Health and Family Planning Commission (QN201941), and Funding from Young Talent Development Plan of Changzhou Health Commission (CZQM2020091).

### ORCID iDs

Jun Zhang  <https://orcid.org/0000-0002-2497-6839>

Guohua Deng  <https://orcid.org/0000-0003-0804-1117>

### References

1. Adzic-Zececic A, Files-Bradaric E and Petrovic M. Overlooked retained intraocular foreign body. *Vojnosanit Pregl* 2015; 72: 463–465.
2. Yeh S, Colyer MH and Weichel ED. Current trends in the management of intraocular foreign bodies. *Curr Opin Ophthalmol* 2008; 19: 225–233.
3. Zhang Y, Zhang MN, Jiang CH, et al. Intraocular foreign bodies in China: clinical characteristics, prognostic factors, and visual outcomes in 1421 eyes. *Am J Ophthalmol* 2011; 152: 66–73.e1.
4. Gopal L, Banker AS, Deb N, et al. Management of glass intraocular foreign bodies. *Retina* 1998; 18: 213–220.
5. Ray S, Friberg TA, Beatty RR, et al. Late posterior migration of glass intraocular foreign bodies. *Arch Ophthalmol* 2004; 122: 923–926.
6. Loporchio D, Mukkamala L, Gorukanti K, et al. Intraocular foreign bodies: a review. *Surv Ophthalmol* 2016; 61: 582–596.
7. Volpi N, Schiller J, Stern R, et al. Role, metabolism, chemical modifications and applications of hyaluronan. *Curr Med Chem* 2009; 16: 1718–1745.
8. Schiller J, Volpi N, Hrabárová E, et al. *Hyaluronic acid: a natural biopolymer*. Hoboken: John Wiley & Sons, Inc., 2011, pp. 3–34.
9. Valachová K, Volpi N, Stern R, et al. Hyaluronan in medical practice. *Curr Med Chem* 2016; 23: 3607–3617.