

All-Soft-Tissue Medial Patellofemoral Complex Reconstruction for Revisions and Skeletally Immature Knees



Miho J. Tanaka, M.D., Ph.D.

Abstract: The medial patellofemoral complex provides the primary static restraint to lateral patellar translation and is composed of the medial patellofemoral ligament and medial quadriceps tendon femoral ligament. Multiple techniques including medial patellofemoral ligament and/or medial quadriceps tendon femoral ligament reconstruction have demonstrated good results; however, modification of the femoral fixation technique is required for skeletally immature patients or revision cases in which anatomic bony fixation on the femur is not possible. This technique describes an all-soft-tissue procedure for single-bundle medial patellofemoral complex reconstruction in which the graft is fixed on the adductor tendon while using the medial collateral ligament as a distalizing pulley, for anatomic and isometric recreation of the native ligament.

The medial patellofemoral complex (MPFC) provides the primary restraint to lateral patellar translation and is composed of the medial patellofemoral ligament and medial quadriceps tendon femoral ligament fibers.¹⁻⁴ The midpoint of this complex anteriorly has been shown to be at the junction of the medial border of the quadriceps tendon and patella, which can serve as an anatomic landmark for graft fixation.⁴

For femoral fixation, anatomic reconstruction has been shown to be critical to recreate the function of the MPFC, and numerous techniques to identify proper femoral tunnel positioning have been described. However, in revision cases or in skeletally immature knees, bone tunnel or anchor placement at the anatomic location on the medial femur may not be feasible. In these cases, several soft-tissue fixation options have been described. The adductor tendon can be used as a graft for reconstruction, or with a free graft attached to this

structure.^{5,6} However, this fixation is more proximal than the anatomic footprint and can cause tightening with knee flexion.⁷ The medial collateral ligament (MCL) pulley technique also has been described; however, the MCL is more anterior to the native footprint, and anteriorization of the femoral fixation point has been shown to lead to abnormal length changes with tightening in extension⁸ (Fig 1).

The current technique describes an all-soft-tissue MPFC reconstruction technique that allows for anatomic reconstruction and isometric function of the graft, without placing bone tunnels or implants in the medial femur. This technique can be useful for skeletally immature knees or revision cases in which anatomic bony fixation cannot be achieved.

Surgical Technique

Preoperative Preparation

This procedure is performed with the patient in the supine position. A semitendinosus allograft 6 mm in diameter is used. Arthroscopy is performed before the procedure in order to address chondral defects and concurrent pathology as needed.

Quadriceps Tendon Fixation

A 1-inch longitudinal incision is made centered over the anterior midpoint of the MPFC, which is identified at the junction of the medial border of the quadriceps tendon and the superomedial border of the patella.⁴ The superomedial corner of the patella is exposed,

From the Department of Orthopaedic Surgery, Massachusetts General Hospital, Harvard Medical School, Boston, Massachusetts, U.S.A.

Received April 23, 2024; accepted May 20, 2024.

Address correspondence to Miho J. Tanaka, M.D., Ph.D., Department of Orthopaedic Surgery, Massachusetts General Hospital, Harvard Medical School, 175 Cambridge St., Suite 400, Boston, MA 02114, U.S.A. E-mail: mtanaka5@mgh.harvard.edu

© 2024 THE AUTHORS. Published by Elsevier Inc. on behalf of the Arthroscopy Association of North America. This is an open access article under the CC BY-NC-ND license (<http://creativecommons.org/licenses/by-nc-nd/4.0/>).

2212-6287/24665

<https://doi.org/10.1016/j.eats.2024.103125>

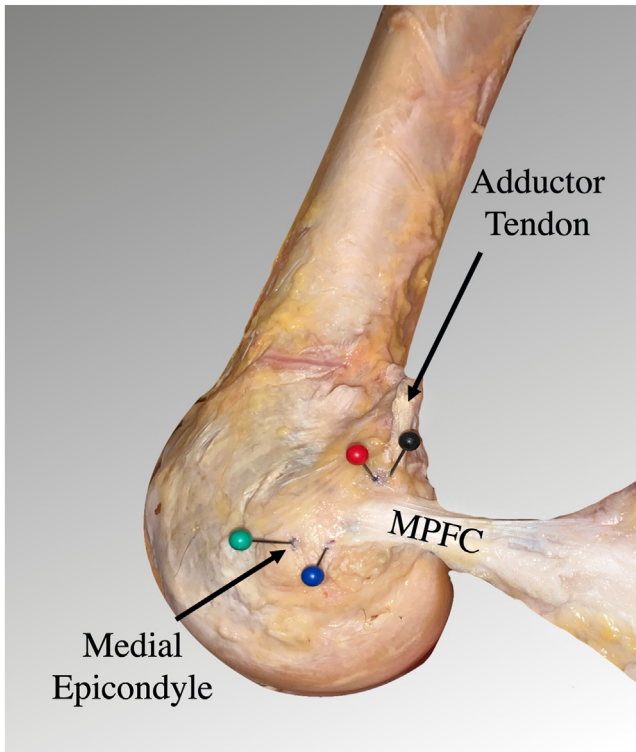


Fig 1. Medial view of a right knee dissection demonstrates the MPFC footprint attaching distal to the adductor tendon insertion and posterior to the medial epicondyle. (MPFC, medial patellofemoral complex.)

and a 1-cm longitudinal incision is placed through layers 1 and 2, with care taken to keep layer 3 intact. The distal quadriceps tendon is exposed, and a 1-cm incision is made in a partial-thickness fashion at the junction between the medial and central thirds of the distal quadriceps tendon attachment.

A right-angled clamp is passed from the incision on the distal quadriceps, exiting through the incision at the superomedial corner of the patella. The graft is retrieved with the clamp and pulled through the quadriceps tendon (Fig 2A). The graft is then folded over on itself (Fig 2B) and secured using a looped suture used to place locking sutures from medial to lateral over the overlapped graft, ending at the superomedial corner of the patella (Fig 2C). One limb of the suture is then passed through the periosteum at the superomedial corner of the patella from an anterior to posterior fashion using a free needle. The suture limbs are tied to each other to secure the graft to the patellar periosteum. The incision in the distal quadriceps tendon is closed to prevent propagation proximally using an interrupted nonabsorbable suture (Fig 3 A and B).

Femoral Fixation

On the medial femur, a 1-inch incision is made on the anterior margin of the adductor tubercle. The adductor

tendon is identified just posterior to the posteromedial aspect of the distal femoral shaft and exposed (Fig 4). Using a right-angled clamp, a passing suture is placed around the adductor tendon for later passage of the graft, ensuring that this suture is as distal as possible near the adductor tubercle.

The MCL fibers are then identified using palpation during valgus stress on the knee, distal to the medial epicondyle. The posterior fibers of the superficial MCL are exposed and elevated to create a tunnel under the MCL fibers (Fig 5). A curved clamp is passed under the MCL to exit through the anterior incision previously made through layers 1 and 2 at the MPFC midpoint (Fig 6A), and the free end of the graft is retrieved and passed between layers 2 and 3 to exist posterior to the MCL (Fig 6B).

Once retrieved posterior to the MCL, using the passing suture previously placed around the adductor tendon, the free end of the graft is then shuttled to loop around the adductor tendon (Fig 7A). The knee is brought to 60° of knee flexion, and slack is removed from the graft. The free graft end is sutured to the remainder of the graft to loop around the adductor tendon, and preliminary fixation is attained using the interrupted nonabsorbable suture (Fig 7B). Graft function is assessed to confirm 2 quadrants of lateral translation in extension, less than half quadrant around 30°, and demonstrating slackening in flexion. Once confirmed, the remainder of the sutures are placed in an interrupted fashion, to secure fixation of the graft too itself, creating a loop around the adductor tendon (Fig 8).

Discussion

Several alternatives to bony fixation on the medial femur for medial patellofemoral ligament or medial quadriceps tendon femoral ligament reconstruction have been described. Fixation using a loop around the adductor tendon, or alternatively using part of the adductor tendon as a graft, has been described by several authors.^{5,6} However, Black et al.⁷ demonstrated unfavorable length changes with these techniques, consistent with the fact that fixation on the adductor tubercle is more proximal than the anatomic location of the femoral attachment of the MPFC.

Fixation of the graft using an MCL sling also has been described, in which the graft is looped around the MCL and fixed anteriorly on the patella.^{9,10} Although the MCL technique can ensure that the graft is adequately distalized, biomechanical studies have demonstrated that anteriorization of the tunnel can lead to abnormal length changes, with increased tightening of the graft in extension when compared with the anatomic MPFC footprint.⁸

The use of anchors in skeletally immature knees requires careful use of fluoroscopy to avoid the risk of

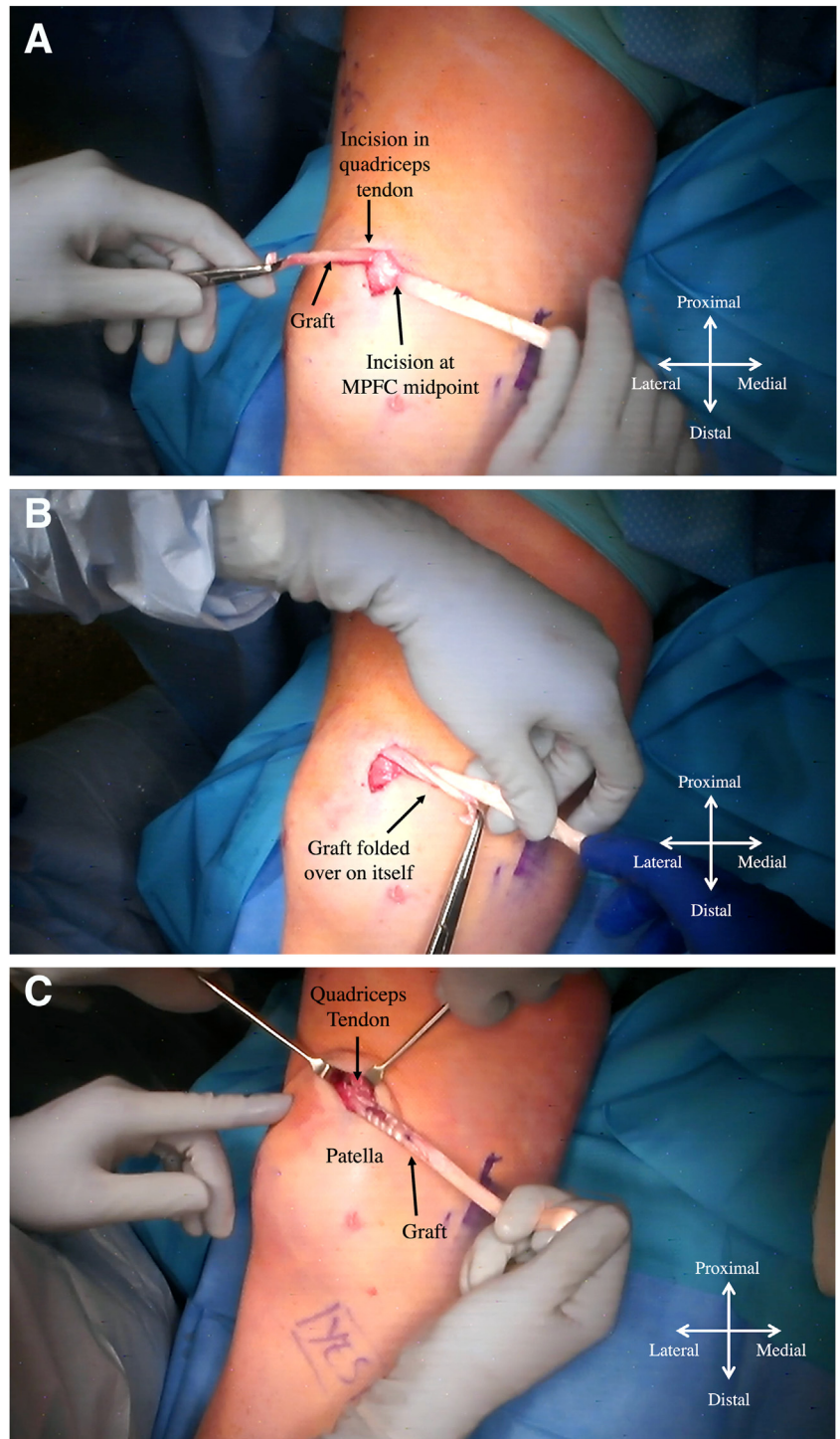


Fig 2. Intraoperative view of a right knee demonstrates an MPFC graft that has been passed from the incision at the MPFC midpoint, exiting through an incision in the quadriceps tendon (A) and is folded over onto itself (B). (C) The graft is secured to itself with locking sutures. (MPFC, medial patellofemoral complex.)

injuring the physis. Complications of inappropriate anchor placement have demonstrated proximal migration of the anchor during growth, leading to subsequent failure, emphasizing the need for appropriate anchor placement.¹¹ However, considerable variability has been demonstrated in the location of the MPFC footprint in relation to the distal femoral physis,¹² and

therefore the optimal location for anchor placement has not been identified.

The current technique provides an anatomic, implant-less option for MPFC reconstruction using soft-tissue fixation on both the extensor mechanism and the medial femur. In comparison with previously described soft-tissue fixation techniques on the femur, the

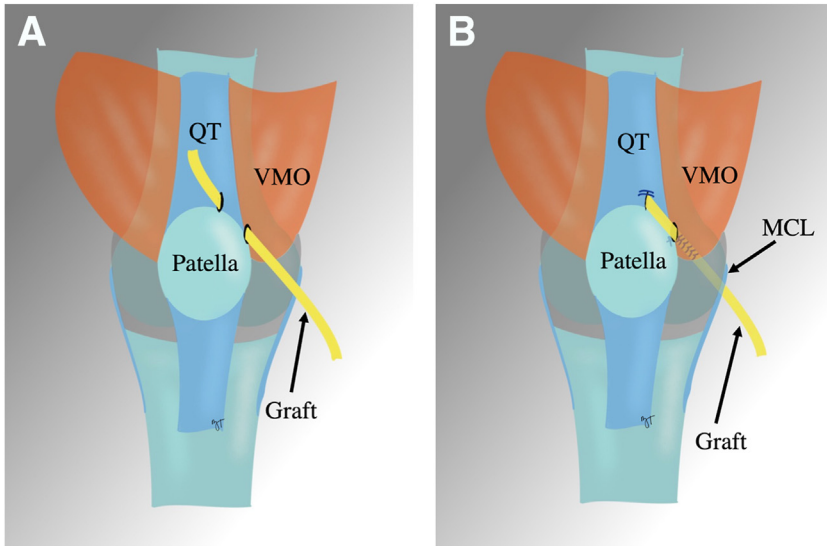


Fig 3. Schematic drawing of a right knee. (A) The graft is passed from the incision at the MPFC midpoint through an incision in the quadriceps tendon. (B) the graft is sutured to itself, secured to the superomedial patella, and passed deep to the VMO, existing posterior to the MCL fibers. (MCL, medial collateral ligament; MPFC, medial patellofemoral complex; QT, quadriceps tendon; VMO, vastus medialis oblique.)

Fig 4. Intraoperative view of a right knee demonstrates exposure of the adductor tendon.

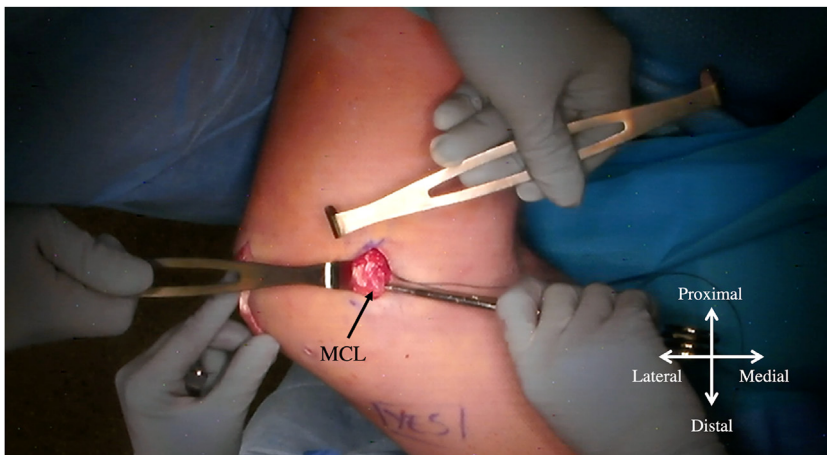
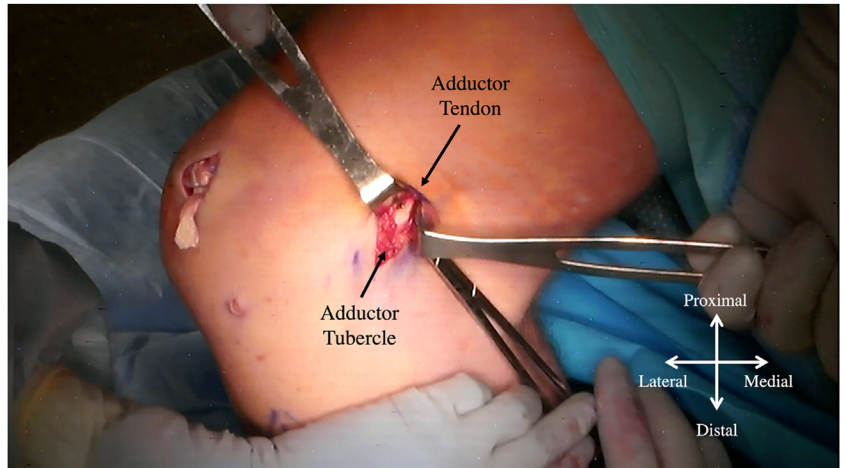


Fig 5. Intraoperative view of a right knee demonstrates exposure of the posterior fibers of the MCL. (MCL, medial collateral ligament.)

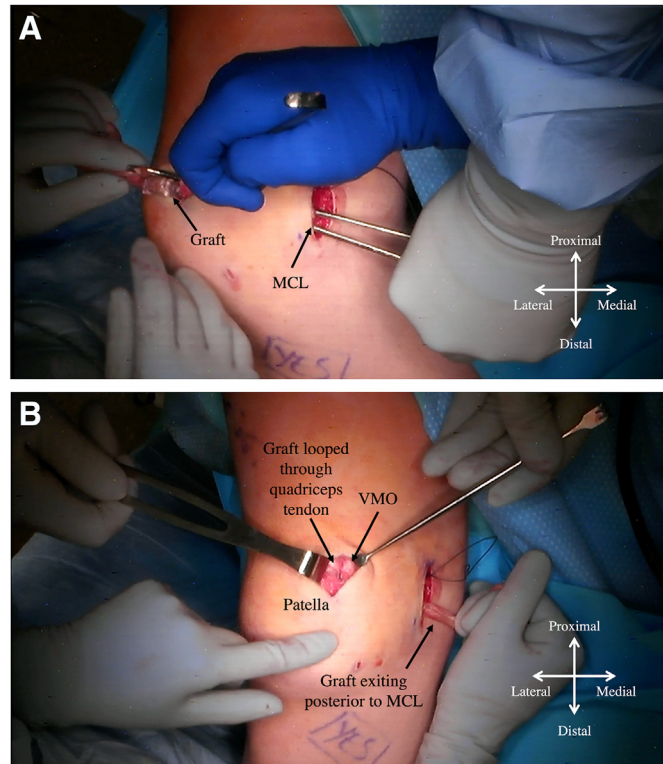


Fig 6. Intraoperative view of a right knee. The graft is passed between layer 2 and layer 3 of the medial knee (A) and retrieved posterior to the MCL (B). (MCL, medial collateral ligament; VMO, vastus medialis oblique.)

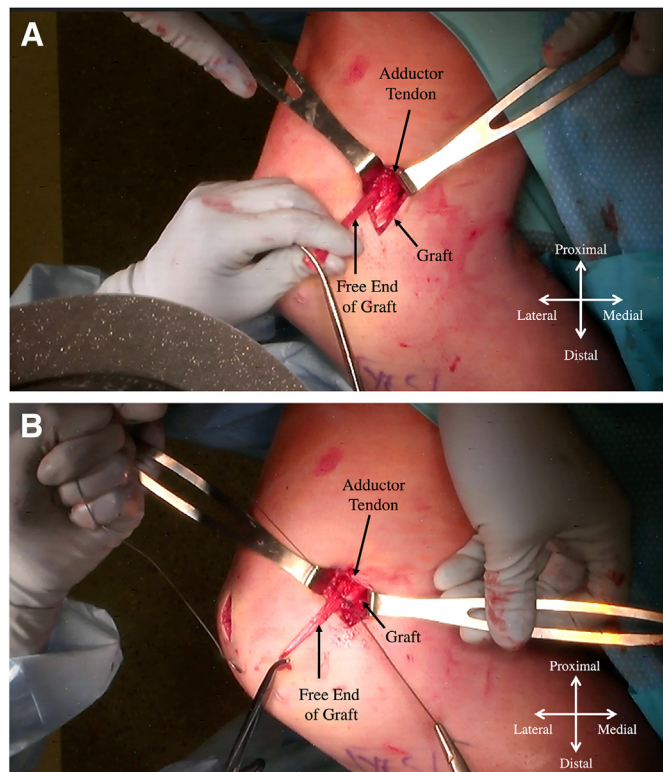


Fig 7. Intraoperative view of a right knee. The graft end is looped around the adductor tendon (A) and sutured to itself (B).

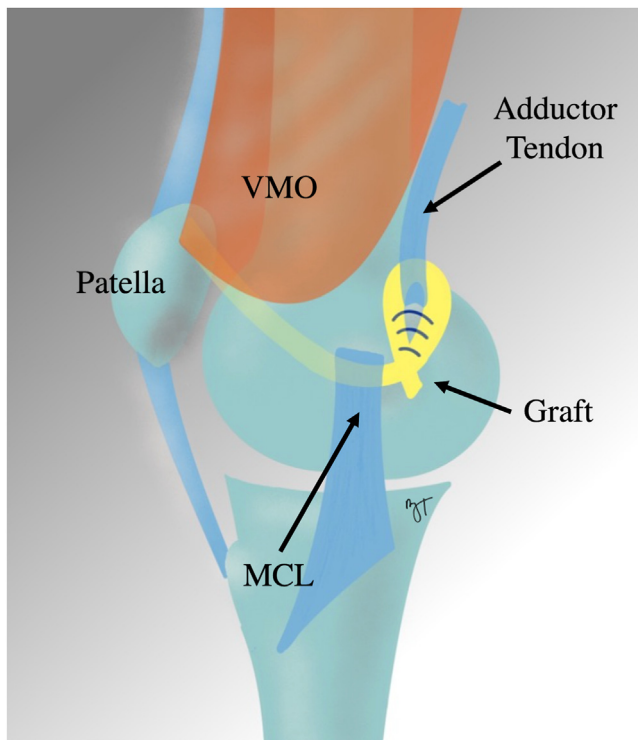


Fig 8. Schematic drawing of a right knee demonstrates the MPFC graft passed deep to the VMO, exiting posterior to the MCL, and looped around the adductor tendon. (MCL, medial collateral ligament; MPFC, medial patellofemoral complex; VMO, vastus medialis oblique.)

current technique provides anatomic function with minimal length changes throughout knee range of motion due to the posteriorizing fixation on the adductor tubercle while using the MCL as a distalizing pulley. The advantage of this soft-tissue technique is

Table 1. Pearls and Pitfalls

Pitfalls	Pearls
Improperly placed incisions can make it difficult to access or visualize the anatomic fixation sites.	The MCL fibers can be identified by palpating the fibers while placing valgus stress on the knee.
The graft should be passed between layers 2 and 3 and not subcutaneously or into the joint.	Arthroscopic visualization after graft passage can confirm that the graft has not been passed intra-articularly.
An appropriate soft-tissue bridge on the distal quadriceps tendon should be maintained for adequate graft fixation.	Preliminary suture fixation can be used to confirm appropriate graft length before final fixation.
Overtightening of the graft can lead to medial instability or increased patellofemoral contact pressures.	The length of the graft can be set with the knee at 60° flexion to ensure that the patella is adequately centered within the trochlear groove.

MCL, medial collateral ligament.

Table 2. Advantages and Disadvantages

Advantages	Disadvantages
All-soft-tissue fixation requires no implants.	Looping the graft through both the extensor mechanism and for femoral fixation may require longer graft lengths than in other techniques.
Low cost because of the lack of implants needed.	Placement of a defect in the quadriceps tendon may limit future quadriceps tendon procedures (e.g., ACL graft).
No risk of patella fracture.	The looped graft may feel more prominent on the femur than with the use of bone tunnels.
Excellent option for revision MPFL cases in which adequate bone stock on the medial femur is not available.	This technique may not be useful in cases of severe medial knee (i.e., MCL injury).
Excellent option for skeletally immature knees without abnormal graft function or risk of violating the physis.	
No radiographic confirmation of femoral fixation required.	

ACL, anterior cruciate ligament; MCL, medial collateral ligament; MPFL, medial patellofemoral ligament.

that it allows for appropriate recreation of graft function without the need for anchors or bone tunnels on the femur, which can be useful in the setting of skeletally immature patients or in revision cases in which an additional bone tunnel on the medial femur in the anatomic location may not be feasible (Table 1). In addition, the entirely soft-tissue fixation minimizes the need for, and costs related to, implants. Disadvantages of this technique may include limitations in subsequent procedures that may require an intact quadriceps tendon or adductor tendon (Table 2).

This technique describes an implant-less, all-soft-tissue MPFC reconstruction that includes anatomic soft-tissue fixation on the medial femur. In addition to the previously described soft-tissue fixation method on the extensor mechanism, this technique additionally incorporates all-soft-tissue fixation on the medial femur that is more anatomic than previously described techniques.

Disclosures

The author (M.T.) declares the following financial interests/personal relationships which may be considered as potential competing interests: consulting or advisory for Johnson & Johnson; board membership, American Orthopaedic Society for Sports Medicine, AO Foundation, and *Arthroscopy*; funding grants from Voice in Sport, AANA, and Fujifilm Corporation; and consulting or advisory for Verywell Health.

References

1. Fulkerson JP, Edgar C. Medial quadriceps tendon-femoral ligament: Surgical anatomy and reconstruction technique to prevent patella instability. *Arthrosc Tech* 2013;2:e125-e128.
2. Joseph SM, Fulkerson JP. Medial quadriceps tendon femoral ligament reconstruction technique and surgical anatomy. *Arthrosc Tech* 2019;8:e57-e64.
3. Tanaka MJ. Variability in the patellar attachment of the medial patellofemoral ligament. *Arthroscopy* 2016;32:1667-1670.
4. Tanaka MJ, Voss A, Fulkerson JP. The anatomic midpoint of the attachment of the medial patellofemoral complex. *J Bone Joint Surg Am* 2016;98:1199-1205.
5. Alm L, Krause M, Mull C, Frosch KH, Akoto R. Modified adductor sling technique: A surgical therapy for patellar instability in skeletally immature patients. *Knee* 2017;24:1282-1288.
6. Sillanpää PJ, Mäenpää HM, Mattila VM, Visuri T, Pihlajamäki H. A mini-invasive adductor magnus tendon transfer technique for medial patellofemoral ligament reconstruction: A technical note. *Knee Surg Sports Traumatol Arthrosc* 2009;17:508-512.
7. Black SR, Meyers KN, Nguyen JT, et al. Comparison of ligament isometry and patellofemoral contact pressures for medial patellofemoral ligament reconstruction techniques in skeletally immature patients. *Am J Sports Med* 2020;48:3557-3565.
8. Smirk C, Morris H. The anatomy and reconstruction of the medial patellofemoral ligament. *Knee* 2003;10:221-227.
9. Chotel F, Bérard J, Raux S. Patellar instability in children and adolescents. *Orthop Traumatol Surg Res* 2014;100(1 suppl):S125-S137.
10. Kumahashi N, Kuwata S, Tadenuma T, Kadowaki M, Uchio Y. A "sandwich" method of reconstruction of the medial patellofemoral ligament using a titanium interference screw for patellar instability in skeletally immature patients. *Arch Orthop Trauma Surg* 2012;132:1077-1083.
11. Kupczik F, Gunia Schiavon ME, Sbrissia B, de Almeida Vieira L, de Moura Bonilha T. Anchor proximal migration in the medial patellofemoral ligament reconstruction in skeletally immature patients. *Rev Bras Ortop* 2013;48:465-468.
12. Jabbouri SS, McLaughlin W, Joo P, Cooperman D, Fulkerson JP, Frumberg DB. Localization of the adductor tubercle in the skeletally immature: A computed tomography study with patellofemoral surgical implications. *Am J Sports Med* 2023;51:1792-1798.