

Research article

Enzyme replacement reverses abnormal cerebrovascular responses in Fabry disease

David F Moore¹, Gheona Altarescu¹, Peter Herscovitch² and Raphael Schiffmann^{*1}

Address: ¹Developmental and Metabolic Branch, National Institute of Neurological Disorders and Stroke, National Institutes of Health, Bethesda, MD 20892, USA and ²PET Department, National Institutes of Health, Bethesda, MD 20892, USA

E-mail: David F Moore - moored@ninds.nih.gov; Gheona Altarescu - Altaresg@ninds.nih.gov; Peter Herscovitch - PHerscovitch@cc.nih.gov; Raphael Schiffmann* - rs4e@nih.gov

*Corresponding author

Published: 18 June 2002

Received: 22 March 2002

BMC Neurology 2002, 2:4

Accepted: 18 June 2002

This article is available from: <http://www.biomedcentral.com/1471-2377/2/4>

© 2002 Moore et al; licensee BioMed Central Ltd. Verbatim copying and redistribution of this article are permitted in any medium for any purpose, provided this notice is preserved along with the article's original URL.

Abstract

Background: Fabry disease is a lysosomal X-linked enzyme deficiency of α -galactosidase A associated with an increased mortality and morbidity due to renal failure, cardiac disease and early onset stroke.

Methods: We examined the functional blood flow response of the brain after visual stimulation (reversing checkerboard pattern), and cerebral vasoreactivity following acetazolamide (15 mg/kg) with [¹⁵O]H₂O and positron emission tomography (PET) in Fabry disease. Twenty-six hemizygous patients (age range 19–47 years) were enrolled in a randomized double-blind placebo-controlled 6-month trial of enzyme replacement therapy administered by intravenous infusion every two weeks. Regional cerebral blood flow (rCBF) was measured with PET at the beginning and end of the trial.

Results: Fabry patients had a significantly greater increase in rCBF following visual stimulation and acetazolamide challenge compared to controls. Visual reactivity was normal. The time for recovery of the cerebral vasculature following acetazolamide was prolonged in Fabry patients compared to controls. The abnormal rCBF response induced by visual stimulation and acetazolamide decreased significantly following enzyme replacement therapy, as did the prolonged recovery of the cerebral vasculature.

Conclusions: Enzyme replacement therapy reverses the exaggerated cerebrovascular response in Fabry disease.

Background

Fabry disease is an X-linked disorder resulting in reduced activity of the lysosomal enzyme α -galactosidase A [1,2]. This results in the systemic accumulation of D-galatosyl conjugates, particularly globotriosylceramide (Gb3) [3,4]. Although the disorder is heterogeneous, patients suffer renal, cardiovascular and cerebrovascular complications [4]. Enzyme replacement therapy has recently shown to have an effect on resting cerebral blood flow abnormalities and on other organ systems functions [5,6]. In the cer-

ebrovascular system there is an increased incidence of stroke together with vessel ectasia [7]. This may be related to the progressive accumulation of storage material in the cerebral vessel or possibly, may be due to an abnormality of vessel function [8,9]. The cerebrovascular complications are distributed predominantly in the posterior circulation with a progressive increase over time in the posterior distribution of small vessel disease as found on T₂-weighted images or fluid attenuated inversion recovery (FLAIR) MR [7,10,11]. It likely that such high signal le-

sions on MR images represent ischemic small vessel disease, however, there are no neuropathological-radiological correlative studies confirming this assumption. Since ischemic brain lesions are irreversible, and accumulate over years, demonstrating a reduction in incidence is likely to require prolonged therapy in a relatively large cohort of patients following this disease endpoint. Previously, in Fabry disease, we have reported resting cerebral hyper-perfusion in a predominantly vertebro-basilar distribution together with abnormalities of vascular nitrotyrosine staining. This was reversed by enzyme replacement therapy [5,10]. The current study examines the cerebrovascular system in Fabry disease in response to functional and pharmacological activation.

We hypothesized that the cerebral vasculopathy of Fabry disease is associated with abnormal cerebrovascular responses, and furthermore, that these would normalize with repeated intra-vascular infusion of α -galactosidase A [5,6]. We compared the functional cerebrovascular responses in Fabry disease to those in age and sex matched controls using both visual stimulation and acetazolamide challenge by [^{15}O]H $_2$ O and positron emission tomography (PET) to measure rCBF. The patients were then re-examined following a 6-month double-blind placebo-controlled trial of enzyme replacement therapy (ERT). Functional activation by visual stimulation was chosen to examine the vertebro-basilar diathesis of Fabry disease. Acetazolamide, on the other hand, was hypothesized to identify areas of decreased cerebral perfusion following maximal cerebral vasodilation in Fabry disease compared to controls. Such an abnormality, if present, might then be used to assess the therapeutic efficacy of enzyme replacement therapy.

We define our usage of the term cerebral *vasomotor reserve* as ($\Delta\text{CBF}_{\text{res}}$) the CBF response at 20 or 30 minutes post-acetazolamide challenge minus the resting CBF for each subject. We define cerebral *vascular reactivity* as the functional CBF response to a stimulus minus the resting CBF ($\Delta\text{CBF}_{\text{react}}$) while the maximal response to acetazolamide challenge provides an index of the cerebrovascular capacity. The CBF response curve to acetazolamide can be considered like a high pass filter with an onset time constant to a steady state τ_1 and an offset time constant of τ_2 . Alteration and prolongation of τ_2 will correspond to *prolonged cerebral vascular response time*. An important concept of a high pass filter is that the system response is dependent on both the resistive (R) and capacitive (C) elements. Hence, the steady state value as well as time constants τ_1 and τ_2 depend on both the R and C components. Therefore the value of $\Delta\text{CBF}_{\text{res}}$ also depends on the RC component of the cerebral vascular system so that if there is an increased R component then $\Delta\text{CBF}_{\text{res}}$ will be reduced, a situation seen in cerebral vaso-occlusive disease. If on the

other hand the RC components are approximately equal in the comparison groups, similar steady state values of CBF and $\Delta\text{CBF}_{\text{res}}$ values will be seen. The magnitude of the steady state response by itself gives an index of the cerebrovascular capacitive component (C).

Patients and Methods

Patients

The methodology for this work has been described in detail [5]. Twenty-six male hemizygote patients with Fabry disease (age range 19–48, mean age 33.7 ± 8.1 years) and 10 control subjects (age range 21–48 years, mean age 33.4 ± 9.7 years) were enrolled in the study. The Institutional Review Board of the National Institute of Neurological Disorders and Stroke and the NIH Radiation Safety Committee approved the study and all patients and healthy volunteers gave their written and informed consent. All patients recruited to this study had neuropathic pain (main inclusion criterion) no focal or global neurological deficits and normal clotting function. Radiological evidence consistent with small vessel disease was noted primarily on the FLAIR MRI as hyper-intense signal areas in 10 patients. Four patients had one lesion on FLAIR imaging, three patients had 3 lesions and three patients had > 3 lesions. There was no significant progression of the lesion burden over the 6-month trial period. No significant radiological abnormality was found on magnetic resonance angiography in the Fabry patients with no report of dolichoectasia. One patient, randomized to the placebo study arm, withdrew from the study for personal reasons and three further patients (1 from the ERT group and 2 from the placebo group) declined the follow-up acetazolamide challenge arm of the study at completion of the trial. A further patient had suffered a lacunar infarct ten years prior to commencement of the present study. The double-blind placebo-controlled randomized trial of ERT consisted of intravenous infusions of α galactosidase A (*Replagal*[™]) every two weeks (Transkaryotic Therapies, Inc., Cambridge, MA) with fourteen patients receiving ERT and twelve placebo for six months.

PET Procedure

PET was performed with a Scanditronix PC2048-15B tomograph (transverse resolution of ~ 6.5 mm). A radial arterial line was placed in all participants for measurement of the [^{15}O]H $_2$ O input function and arterial blood gases. Subjects were aligned in the scanner with slices parallel to the orbital-meatal line with at least one slice obtained within the posterior fossa. The head was restrained with a thermoplastic facemask. Transmission scans were obtained with a rotating $^{68}\text{Ge}/^{68}\text{Ga}$ pin source, and were used to correct emission scans for attenuation.

Emission scans (four minutes duration) were obtained after intravenous injection of 35 mCi of [^{15}O]H $_2$ O and were

begun automatically following arrival of radioactivity in the brain. Each study commenced with a sham scan in order to acclimatize the subject to scanning procedure which was followed by two resting cerebral blood flow scans during which the subject maintained eye closure. Two scans during visual stimulation were also performed 10 minutes apart. During visual activation the subjects were asked to focus on a black and white pattern reversal screen. The reversal frequency was 8 Hz. This stimulus frequency is known to induce the maximal change in the striate cortex blood flow [12]. The visual stimulus was commenced ~15 seconds before radioactivity reached the head. Following the visual activation scans, intravenous acetazolamide was injected at a dose of 15 mg/kg body weight and two further scans were obtained 20 and 30 minutes later.

Data Analysis

The time shift between arterial blood and brain data was determined by aligning the scanner count rate data (sampled at ~1 Hz) to the blood data with the slice count data fitted to a one-tissue compartment two-parameter model. The CBF images were constructed from a pixel-by-pixel least square fit for blood flow and partition coefficient [13,14]. The MRI T1 template was downloaded from the Montreal Neurological Institute [<http://www.bic.mni.mcgill.ca/>] [15]. This served as a template for spatially registering the PET data. Prior to spatial registration the MRI template and PET rCBF images were resampled to 256×256×90, 0.9375 mm isotropic voxels. Pixel-by-pixel averaging of the replicated visual activation PET scans was performed. Spatial registration of the PET images and T1 MRI template was performed using SPM99 [<http://www.fil.ion.ucl.ac.uk/spm/spm99.html>] [16].

The analysis is divided into a comparison of the baseline Fabry group with the control group and the comparison of the ERT group with the placebo group. A straight comparison was made between the control group and the baseline (time zero) Fabry group visual and acetazolamide co-registered PET data using SPM99 allowing appropriate multiple comparisons analyses. In order to isolate a potential treatment effect following ERT, a mixed statistical model was used. This analysis of variance model divides the total variance into fixed and random effects with the treatment effect attributable to the fixed effect. A two-step approach was adopted. The first allowing isolation of the fixed effect by forming subtraction images for each patient by subtracting the pre-trial response from the post-trial response forming a contrast image. The second consisted of direct comparison of the ERT and non-ERT subgroups contrast images. In this way, the attributable treatment effects were compared for the analysis of the visual activation and acetazolamide responses on a patient-by-patient basis. This gave for each patient a difference image repre-

senting an independent estimate of each subject's response to visual activation and acetazolamide after ERT or placebo. Statistical parametric maps (SPM_t) were then calculated on the spatially registered PET images by obtaining a set-level statistic of $p < 0.05$ after setting the voxel threshold at $p < 0.05$ or less and the cluster extent at 1024 or greater. The cluster extent threshold represents ~1.0 cm³ of brain tissue. The set-level statistic represents the statistical significance of the compared data volumes. All the p-values given in the 'Results' section are the set-level statistic.

In order to characterize the visual activation response further, a specific region of interest (ROI) was used that included Brodmann areas 17, 18 and 19 as determined from the Talairach-Tournoux electronic brain atlas [17]. The visual ROI was derived from T1 MRI template which was then used to mask the SPM registered CBF images prior to calculation of the visual CBF responses. The mean visual cortex CBF and global CBF values were calculated on a pixel-by-pixel basis after setting a CBF threshold value of 10.0 ml/min/100 g of tissue below which the pixels were excluded from calculation. This CBF level represents the lower limit of CNS tissue viability. The ROI consisted of both gray and white matter areas associated with the visual cortex and association areas.

Results

No statistical significant difference was found at baseline between control subjects and patients for age, arterial blood gas parameters (P_aO₂, P_aCO₂, pH) and the visual angle subtended by the visual activation screen. This was also true comparing the ERT and placebo groups at baseline and after the six-month enzyme replacement therapy trial. The global CBF post acetazolamide challenge and mean visual ROI cerebral blood flow results are summarized in Table 1 and 2.

Visual Activation Studies (Table 1)

Mean absolute CBF in the visual cortex was significantly greater in Fabry patients during visual stimulation compared to the control group ($p = 0.002$). The visual CBF reactivity ($\Delta\text{CBF}_{\text{react}}$) following visual stimulation was calculated in each subject by subtracting the visual cortex resting cerebral blood flow from the mean visual activation CBF. No significant difference was found in the visual area $\Delta\text{CBF}_{\text{react}}$ between patients and controls. After enzyme replacement therapy there was no significant change in the mean absolute CBF response to visual stimulation over the visual area ($p = 0.184$), or in $\Delta\text{CBF}_{\text{react}}$ compared to placebo ($p = 0.629$).

Acetazolamide Challenge Studies – global CBF (Table 2)

Resting and post-acetazolamide global CBF values were not significantly different between the control group and

Table 1: Summary of mean visual area CBF and reactivity in Fabry disease compared to controls together with the mean visual area resting and post stimulation CBF changes in the ERT Fabry and placebo groups following the double-blind, placebo-controlled randomized trial. All values are means \pm standard deviation.

Cerebral Blood Flow [ml/min/100 g tissue]	Fabry Patients n = 26	Control Subjects n = 10	P value
Rest	25.7 \pm 3.8	22.8 \pm 2.9	0.019
Visual Activation	29.43 \pm 3.44	25.78 \pm 2.45	0.002
Change with visual activation	3.74 \pm 2.91	3.0 \pm 2.88	0.498
Cerebral Blood Flow change Post ERT or Placebo	Enzyme Replacement Group n = 14	Placebo Group n = 11	P value
Change in resting rCBF	-2.3 \pm 3.7	1.1 \pm 4.2	0.050
Change in rCBF during visual activation	-1.75 \pm 2.6	0.61 \pm 5.08	0.184
Mean Visual Area Reactivity	0.51 \pm 3.41	-0.47 \pm 5.84	0.629

Table 2: Summary of global resting and post-acetazolamide CBF in Fabry disease compared to controls together with the mean resting and post-acetazolamide global CBF changes in the ERT Fabry and placebo groups following the double-blind, placebo-controlled randomized trial. All values are means \pm standard deviation.

Global Cerebral Blood Flow [ml/min/100 g tissue]	Fabry Patients	Control Subjects	P value
Rest	42.0 \pm 4.9, n = 26	39.2 \pm 4.8, n = 10	0.136
Post-acetazolamide 20 minute time point	57.5 \pm 8.9, n = 26	57.9 \pm 7.9, n = 9	0.969
Post-acetazolamide 30 minute time point	56.9 \pm 7.9, n = 26	54.2 \pm 8.6, n = 10	0.406
Cerebral Blood Flow change Post-ERT or Placebo	Enzyme Replacement Group	Placebo Group	P value
Resting Cerebral Blood Flow	-3.5 \pm 4.6, n = 14	1.3 \pm 5.1, n = 11	0.026
Post-acetazolamide 20 minute time point	-3.9 \pm 7.9, n = 13	0.5 \pm 10.8, n = 9	0.314
Post-acetazolamide 30 minutes time point	-7.0 \pm 5.5, n = 13	1.1 \pm 9.2, n = 9	0.036

the untreated patient group for either the twenty-minute or thirty-minute time point. Following the enzyme replacement trial, no significant change in the global CBF was found at the 20-minutes post-acetazolamide time point in the ERT group compared to the placebo group, however, the resting global CBF in the ERT group was significantly decreased ($p = 0.026$). A significant reduction ($p = 0.036$) in the global CBF was found 30-minutes post-acetazolamide in the ERT group compared to the placebo group. No difference in the global vasomotor reserve was found between Fabry patients and controls before or following ERT.

Regional SPM Analysis of Visual Activation and Acetazolamide Challenge Studies

There was a significantly increased blood flow in the Fabry patients during visual stimulation compared to controls (Figure 1, $p < 0.001$). The increased rCBF was found predominantly in the posterior circulation area and visual cortex but some voxels increases in rCBF were found in the anterior circulation. No rCBF voxels were found to be significantly greater in the control group compared to the

Fabry group (data not shown). Restriction of the rCBF analysis to Talairach-defined visual cortex ROI showed no significant difference in visual reactivity ($\Delta\text{CBF}_{\text{react}}$) between the patient and control groups.

Following acetazolamide at the 20-minute time point, the rCBF in the control group was significantly elevated in a more central and anterior distribution ($p = 0.041$), while the distribution of the higher rCBF voxels in the Fabry group was more posterior (data not shown, $p = 0.002$). At the 30-minute time point the significantly elevated rCBF in the control group had disappeared while the significantly elevated rCBF in the Fabry group persisted (Figure 2, $p = 0.003$) indicating a prolonged cerebral vascular response time. No difference in regional $\Delta\text{CBF}_{\text{res}}$ between the Fabry and control groups was found indicating normal regional cerebral vascular reserve in Fabry disease.

ERT resulted in a significantly lower absolute rCBF during visual stimulation in the treatment group compared to the placebo (Figure 3, $p < 0.001$) while no significantly decreased areas of rCBF were found in the placebo group. A

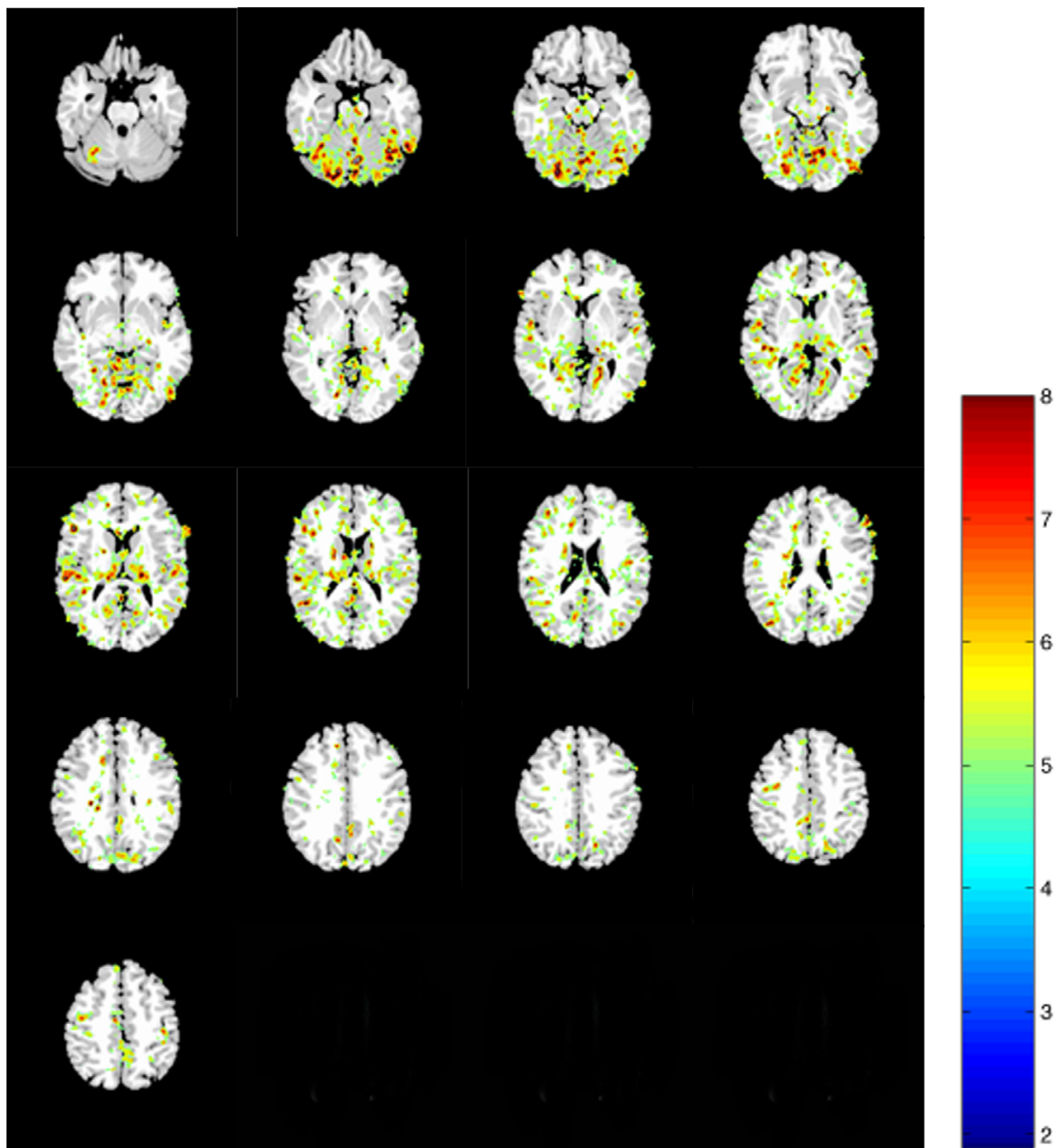


Figure 1
rCBF SPM{t} map of significantly increased blood flow in the Fabry group (n = 26) compared to the control group (n = 10) during visual stimulation. No significant rCBF elevation was found in the control group compared to Fabry patients at the same set-level of inference (results not shown).

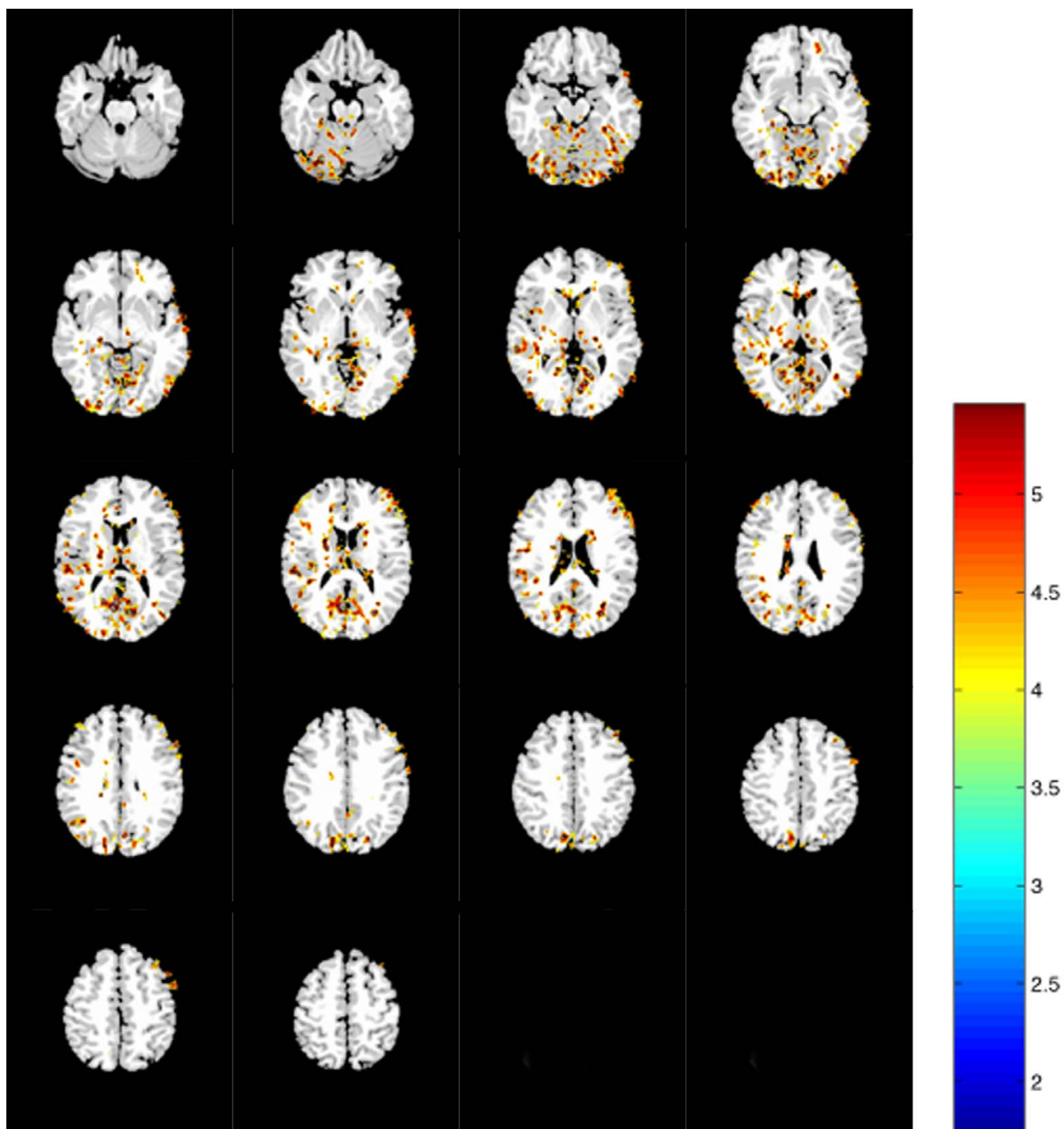


Figure 2
 Acetazolamide challenge rCBF SPM{t} map of significantly increased blood flow in the Fabry group (n = 26) compared to normal controls (n = 10). The rCBF at thirty minutes post-infusion of acetazolamide was significantly greater in Fabry patients in many brain regions, with a posterior predominance. No significant rCBF elevation at the same set-level of inference was found in the control group compared to Fabry patients (results not shown).

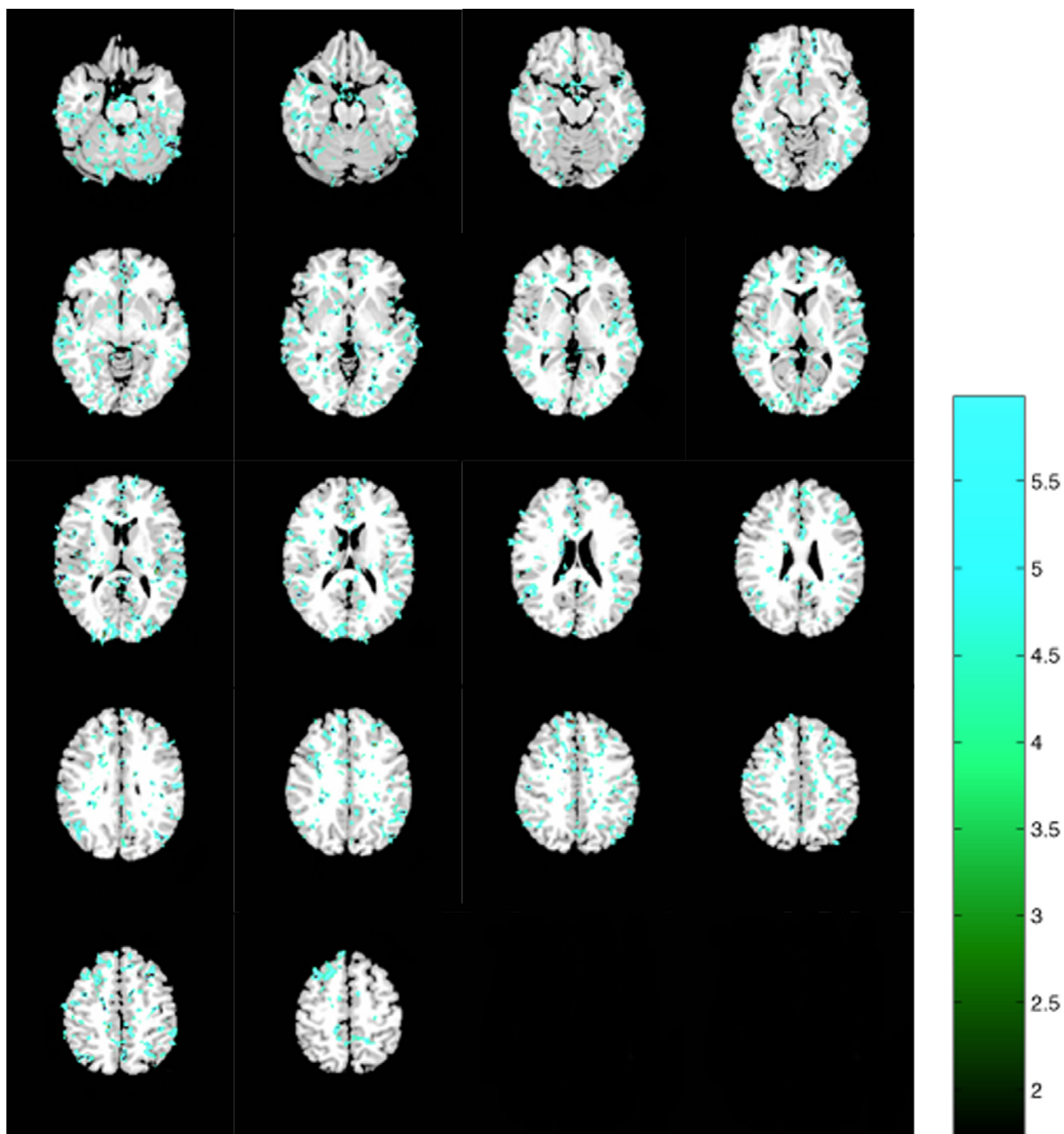


Figure 3
SPM{t} map of significantly lower rCBF in the ERT treatment group (n = 14) during visual stimulation compared to the placebo group (n = 11) in many regions throughout the brain.

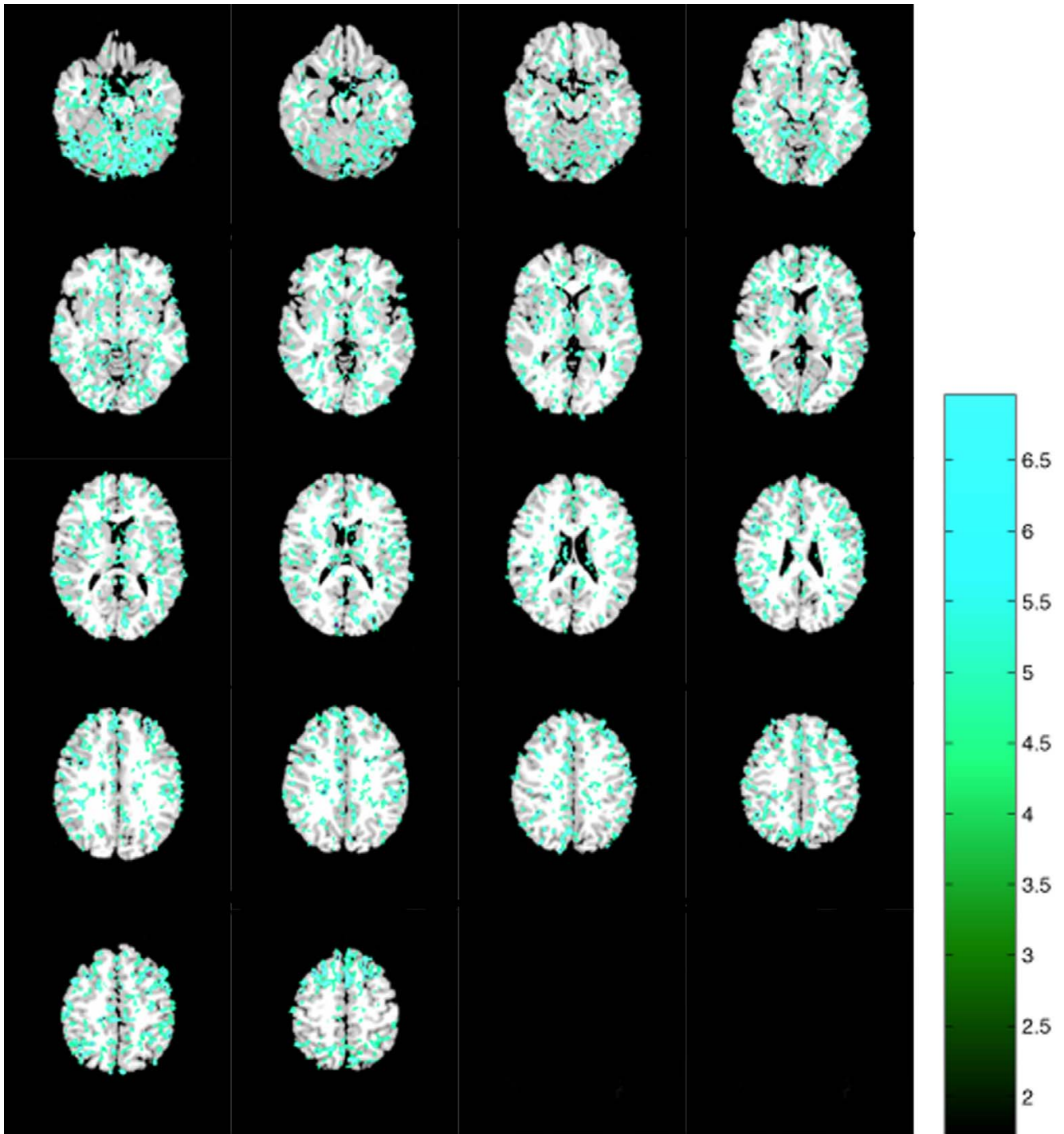


Figure 4
SPM{t} map of significantly lower rCBF 30-minute following acetazolamide challenge in the ERT group (n = 13) compared to the placebo group (n = 9).

reduction in rCBF was also found when the analysis was restricted to the visual cortex ($p < 0.001$) with no areas of significantly decreased rCBF in the placebo group. ERT led to decreased rCBF after acetazolamide infusion at both time points (time = 20 minutes, $p < 0.001$, time = 30 minutes, $p = 0.004$, Figure 4). No significant decrease in rCBF was found at a comparable cluster extent and voxel threshold in the placebo group.

Discussion

Our data indicate the presence of an abnormal functional response to visual stimulation both in global and regional CBF analysis in Fabry disease. This however was not due to an alteration in vascular reactivity. Previously, we demonstrated that the resting rCBF in Fabry disease is elevated compared to controls particularly in the posterior circulation [5]. In view of the normal visual area reactivity in Fabry disease, these findings indicate that the Fabry group response to visual activation is largely explained by the elevated resting rCBF. However, the more generalized cerebrovascular response noted in both the carotid and vertebro-basilar circulation suggests stimulus spread in Fabry disease, possibly due to a decreased response threshold in non-visual cortex vasculature. Following ERT, this resting rCBF abnormality was reversed [5].

The cerebral visual stimulation paradigm used in the current study is known to induce maximal cerebral blood flow [12] and is therefore a useful stimulus for the study of neuro-vascular coupling. Visual stimulation was chosen in particular because of the known predilection of the cerebrovascular abnormalities in Fabry disease for the posterior circulation [7,10]. The lack of an increase or decrease in visual rCBF reactivity in Fabry disease suggests normal neuro-vascular coupling mechanism [18,19].

Acetazolamide-induced maximal cerebral vasodilatory response is often used to assess cerebrovascular reserve [20]. The greatest difference between our patients and controls occurred at the 30-minute time point rather than at the 20-minute time point of the acetazolamide challenge. This finding is consistent with a prolongation of the cerebral vascular response time in the Fabry disease. ERT significantly decreased the prolonged cerebral vascular response time. The vasodilator effect of acetazolamide on the cerebral vasculature has been characterized by both PET and transcranial Doppler (TCD) studies [21,22]. At a dose of 15 mg/kg the effect of acetazolamide is thought to be supramaximal with maximal cerebral vasodilation induced within about 20 minutes. By TCD a maximal dose-response was found to occur with an acetazolamide infusion of between 15 and 18 mg/kg with maximal vasoreactivity occurring between 10 and 30 minutes post acetazolamide [21]. Using $[^{15}\text{O}]\text{H}_2\text{O}$ and PET, a further study of rCBF following 1 g of acetazolamide demonstrat-

ed the peak response to occur at 10 minutes while the plateau phase occurred during the twenty to thirty minute time period post acetazolamide [22]. The measurements in the current study obtained at twenty and thirty minutes post acetazolamide injection therefore, probably corresponds to the plateau phase of reported acetazolamide responses.

The CBF response to supra-maximal acetazolamide challenge consists of a phase of increasing CBF followed by a plateau phase with a terminal recovery phase. This can be considered in terms of cerebrovascular resistance and capacity, analogous to a high pass filter where high frequency components of the system response are removed. The importance of this analogy is that the plateau response is dependent on both the system's resistive and capacitive components. In the present study it was seen that the vasomotor reserve in Fabry disease was within normal limits despite the elevated resting rCBF. The cerebrovascular capacity in Fabry disease was also within normal limits, suggesting absence of clinically significant vaso-occlusive disease in the cohort of Fabry patients examined. This finding is supported by the absence of abnormalities on magnetic resonance angiography in the same group. Reduced $\Delta\text{CBF}_{\text{res}}$ would be expected when the resistive component is increased reducing the amplitude of the acetazolamide induced plateau response.

The hyperemic cerebrovascular response to hypercapnia or acetazolamide is not inhibited by nitric oxide synthase inhibitors such as N^{G} -monomethyl-L-arginine (L-NMMA) suggesting that NO does not mediate vasoreactivity [23,24]. The mechanism of acetazolamide vasodilation, beyond smooth muscle intracellular and extracellular acidosis due carbonic anhydrase inhibition, is unclear. Abnormalities of the peripheral vasculature responses to acetylcholine have been previously described in Fabry disease together with nitric oxide pathway dysregulation [5,9] suggesting participation of non-NO regulation of vascular tone. A similar vascular hyper-responsiveness has been noted in caveolin-1 knock-out mice [25,26] raising the possibility that the accumulation of Gb_3 results in over-activity of uncoupled endothelial nitric oxide synthase within endothelial cell caveolae generating superoxide and other reactive oxygen species [27]. The latter may have a vasodilatory effect [28]. Predominance of vascular abnormalities in the vertebro-basilar system in Fabry disease suggests fundamental biologic differences between the anterior and the posterior circulation. Such difference might, for example, result from the neural crest origin of pericytes and vascular smooth muscle in the anterior circulation as opposed to paraxial mesoderm in the vertebro-basilar or posterior circulation [29].

Conclusion

The current study indicates that ERT normalized acetazolamide-induced prolonged cerebral vascular response time in Fabry disease. This finding suggests that the underlying abnormality is present at the luminal side of the blood-brain barrier (BBB) complex and is due to an abnormality of the cerebral vessels since it is unlikely that α -galactosidase A crosses the BBB to any appreciable extent. Further, the treatment effect appeared to be uniform across all cerebral vascular distributions.

Competing interests

None declared

Authors' contributions

DFM carried out and coordinated the PET studies, performed the data and statistical analysis and drafted the manuscript. GA contributed to carrying out the PET studies and drafting of the manuscript. PH participated in the design of the study and drafting the manuscript. RS conceived of the study and participated in its design and coordination together with drafting the manuscript.

Acknowledgements

The National Institute of Neurological Disorders and Stroke intra-mural program funded this study.

References

- Brady R, Gal AE, Bradley RM, Martensson E, Warshaw AL, Laster L: **Enzymatic defect in Fabry disease: ceramide trihexosidase deficiency.** *N Engl J Med* 1967, **276**:1163-1167
- Kint J: **Alpha-galactosidase deficiency.** *Science* 1970, **167**:1268
- Kanda A, Nakao S, Tsuyama S, Murata F, Kanzaki T: **Fabry disease: ultrastructural lectin histochemical analyses of lysosomal deposits.** *Virchows Arch* 2000, **436**:36-42
- Desnick R, Ioannou YA, Eng CM: **α -Galactosidase A Deficiency: Fabry Disease.** *Valle. (Edited by: R Charles, Scriver, Arthur L, Beaudet William, S Sly David) New York, McGraw-Hill* 2001, 3733-3774
- Moore DF, Scott LJC, Gladwin MT, Altarescu G, Kaneski C, Suzuki K, Pease-Fye M, Ferri R, Brady RO, Herscovitch P, Schiffmann R: **Regional Cerebral Hyper-Perfusion and Nitric Oxide Pathway Dysregulation in Fabry Disease: Reversal by Enzyme Replacement Therapy.** *Circulation* 2001, **104**:1506-1512
- Schiffmann R, Kopp J, Austin H, Sabnis S, Moore DF, Weibel T, Balow J, Brady RO: **A randomized double-blind, placebo-controlled trial of enzyme replacement therapy in Fabry disease.** *JAMA* 2001, **285**:2743-2749
- Mitsias P, Levine SR: **Cerebrovascular complications of Fabry's disease.** *Ann Neurol* 1996, **40**:8-17
- Evans O, Parker CC, Haas RH, Naidu S, Moser H, Bock HGO: **"Inborn errors of metabolism of the nervous system. Chapter 68, Neurology in Clinical Practice."** *Butterworth-Heinemann, Woburn, MA, ed. Third Edition,* 2000
- Altarescu G, Moore DF, Pursley R, Campia U, Goldstein S, Bryant M, Panza JA, Schiffmann R: **Enhanced endothelium-dependent vasodilation in Fabry disease.** *Stroke* 2001, **32**:1559-1562
- Moore DF, Herscovitch P, Schiffmann R: **Selective arterial distribution of cerebral hyper-perfusion in Fabry disease.** *J Neuroimaging* 2001, **11**:303-307
- Crutchfield K, Patronas NJ, Dambrosia JM, Frei KP, Banerjee TK, Barton NW, Schiffmann R: **Quantitative analysis of cerebral vasculopathy in patients with Fabry disease.** *Neurology* 1998, **50**:1746-1749
- Fox P, Raichle ME: **Stimulus rate determines regional brain blood flow in the striate cortex.** *Ann Neurol* 1985, **17**:303-305
- Herscovitch P, Markham J, Raichle ME: **Brain blood flow measured with intravenous O-15 water. Theory and error analysis.** *J Nucl Med* 1983, **24**:782-789
- Koeppel R, Holden JE, Polcyn RE, Nickles RJ, Hutchins GD, Weese JL: **Performance comparison of parameter estimation techniques for the quantitation of local cerebral blood flow by dynamic positron computed tomography.** *J Cereb Blood Flow Metab* 1985, **5**:214-223
- Collins D, Zijdenbos AP, Kollokian JG, Kabani NJ, Holmes CJ, Evans AC: **Design and construction of a realistic digital brain phantom.** *IEEE Transactions on Medical Imaging* 1998, **17**:463-469
- Friston K, Ashburner J, Frith CD, Poline JB, Heather JD, Frackowiak RSJ: **Spatial registration and normalization of images.** *Human Brain Mapping* 1995, **2**:165-189
- Nowinski W, Bryan RN, Raghavan R: **The Electronic Clinical Brain Atlas.** *New York, Thieme.* 1999
- Faraci F, Heistad DD: **Regulation of the Cerebral Circulation: Role of Endothelium and Potassium Channels.** *Physiological Reviews* 1998, **78**:53-97
- Szabo C: **Physiological and pathophysiological roles of nitric oxide in the central nervous system.** *Brain Research Bulletin* 1996, **41**:131-141
- Inao S, Tadokoro M, Nishino M, Mizutani N, Terada K, Bundo M, Kuchiwaki H, Yoshida J: **Neural Activation of the Brain with Hemodynamic Insufficiency.** *J Cereb Blood Flow Metab* 1998, **18**:960-967
- Dahl A, Russell D, Rootwell K, Nyber-Hansen R, Kerty E: **Cerebral vasoreactivity assessed with transcranial Doppler and regional cerebral blood flow measurements. Dose, serum concentration, and time course of the response to acetazolamide.** *Stroke* 1995, **26**:2302-2306
- Hayashida K, Tanaka Y, Hirose Y, Kume N, Iwama T, Miyake Y, Ishida Y, Matsuura H, Miyake Y, Nishimura T: **Vasoreactive effect of acetazolamide as a function of time with sequential PET ^{15}O -water measurements.** *Nuclear Medicine Communications* 1996, **17**:1047-1051
- Kiss B, Dallinger S, Findl O, Rainer G, Eichler HG, Schmetterer L: **Acetazolamide-induced cerebral and ocular vasodilation in humans is independent of nitric oxide.** *Am. J. Physiol* 1999, **276**:R1661-R1667
- White R, Deane C, Vallance P, Markus HS: **Nitric Oxide Synthase Inhibition in Humans Reduces Cerebral Blood Flow but Not the Hyperemic Response to Hypercapnia.** *Stroke* 1998, **29**:467-472
- Razani B, Engelman JA, Wang XB, Schubert W, Zhang XL, Marks CB, Macaluso F, Russell RG, Li M, Pestell RG, Di Vizio D, Hou H, Kneitz B, Lagaud G, Christ GJ, Edelmann W, Lisanti MP: **Caveolin-1 null mice are viable but show evidence of hyperproliferative and vascular abnormalities.** *Journal of Biological Chemistry* 2001, **276**:38121-38138
- Razani B, Lisanti MP: **Caveolin-deficient mice: insights into caveolar function and human disease.** *Journal of Clinical Investigation* 2001, **108**:1553-1561
- Cai H, Harrison DG: **Endothelial dysfunction in cardiovascular diseases: the role of oxidant stress.** *Circ Res* 2000, **87**:840-844
- Wei E, Christman CW, Kontos HA, Povlishock JT: **Effects of oxygen radicals on cerebral arterioles.** *Am J Physiol* 1985, **248**:H157-H162
- Etchevers H, Vincent C, Le Dourarin NM, Couly GF: **The cephalic neural crest provides pericytes and smooth muscle cells to all blood vessels of the face and forebrain.** *Development* 2001, **128**:1059-1068

Pre-publication history

The pre-publication history for this paper can be accessed here:

<http://www.biomedcentral.com/1471-2377/2/4/prepub>