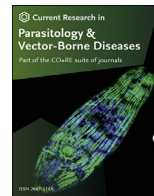


Contents lists available at [ScienceDirect](https://www.sciencedirect.com)

Current Research in Parasitology & Vector-Borne Diseases

journal homepage: www.editorialmanager.com/crpvbd/default.aspx

Neospora caninum and *Toxoplasma gondii* as causes of reproductive losses in commercial sheep flocks from Argentina



Paola Della Rosa^a, María A. Fiorentino^b, Eleonora L. Morrell^b, María V. Scioli^b,
Fernando A. Paolicchi^b, Dadín P. Moore^{b,c}, Germán J. Cantón^b, Yanina P. Hecker^{b,c,*}

^a National Institute of Agricultural Technology (INTA), W3470, Mercedes, Argentina

^b National Institute of Agricultural Technology (INTA), 7620, Balcarce, Argentina

^c Institute of Innovation for Agricultural Production and Sustainable Development (IPADS Balcarce), INTA-CONICET, Balcarce, 7620, Argentina

ARTICLE INFO

Keywords:

Neospora caninum
Toxoplasma gondii
Abortion
Perinatal death
Sheep

ABSTRACT

The aim of this study is to provide preliminary data about the occurrence of *Neospora caninum*- and *Toxoplasma gondii*-related abortions and perinatal deaths in sheep from Argentina. Thirty ovine aborted foetuses and 33 perinatal deaths were submitted to the Veterinary Diagnostic Service at INTA EEA Balcarce (Argentina) during 2017–2019. A complete necropsy was performed on all specimens submitted, and foetal and placental tissues were examined. Foetal cavity fluids were collected for assessment of antibodies to *N. caninum* and *T. gondii* by indirect fluorescent antibody technique (IFAT). Placental and foetal tissue samples were collected for DNA extraction and histopathological analysis. The differential diagnosis with other causes of abortion was carried out. Of the sampled specimens, 20.63% (13/63) displayed evidence for *N. caninum* infection by IFAT and PCR, and in 61.5% (8/13) of the positive specimens the parasite was confirmed as the cause of abortion/perinatal death based on the presence of compatible histological lesions and/or positive immunohistochemistry test, positive PCR and/or positive IFAT, and no other infectious agents diagnosed. In contrast, *T. gondii* infection was confirmed in 9.52% (6/63) of the analysed specimens, but only in 2 lambs *T. gondii* was determined as the death cause. *Neospora caninum* and *T. gondii* co-infections were confirmed in 4 analysed specimens (2 aborted foetuses and 2 perinatal deaths). These results demonstrated that *N. caninum* is efficiently transmitted and a frequent cause of ovine reproductive failure in the commercial analysed flocks compared with *T. gondii*. Despite *T. gondii* congenital infection was detected in some specimens (6/63), it was confirmed as the cause of death in only two of them. Thus, and considering the limited availability of confirmed samples, we could not determine whether toxoplasmosis is a major problem in Argentinian sheep flocks or not. More studies on a greater number of specimens from different ovine production systems under different management conditions are necessary to assess the real impact of neosporosis and toxoplasmosis in Argentina.

1. Introduction

Neospora caninum is an apicomplexan protozoan parasite recognized as a major cause of abortion and severe economic losses to the cattle industry worldwide (Reichel et al., 2013). Cattle can be infected horizontally by the ingestion of *N. caninum* oocysts shed in the faeces of the definitive hosts (canids), or vertically from the mother to the foetus during gestation (Lindsay & Dubey, 2020). In addition, transplacental transmission can occur following recrudescence of a persistent infection during pregnancy (endogenous transplacental transmission), or after a new infection by ingestion of oocysts (exogenous transplacental

transmission) (Trees & Williams, 2005). Although neosporosis has been shown as a major cause of abortion in cattle, *N. caninum* has also been detected in many animal species, including sheep (Lindsay & Dubey, 2020). *Neospora caninum* can be congenitally transmitted in naturally infected sheep and can cause abortion and perinatal mortality (González-Warleta et al., 2018). Several reports have suggested the role of naturally acquired *N. caninum* infections in sheep, and its involvement in poor reproductive performance and abortions in flocks from different countries, i.e. Argentina (Hecker et al., 2019), Brazil (Moraes et al., 2011; Filho et al., 2017; Pereira et al., 2021), Iran (Asadpour et al., 2013), Iraq (Al-Shaeli et al., 2020), Italy (Gazzonis et al., 2019), New Zealand (West

* Corresponding author. National Institute of Agricultural Technology (INTA), 7620, Balcarce, Argentina.

E-mail address: hecker.yanina@inta.gob.ar (Y.P. Hecker).

<https://doi.org/10.1016/j.crpvbd.2021.100057>

Received 24 August 2021; Received in revised form 12 October 2021; Accepted 27 October 2021

2667-114X/© 2021 The Authors. Published by Elsevier B.V. This is an open access article under the CC BY-NC-ND license (<http://creativecommons.org/licenses/by-nc-nd/4.0/>).

et al., 2006; Howe et al., 2012), Spain (Moreno et al., 2012; González-Warleta et al., 2014, 2018), Tunisia (Amdouni et al., 2018), and UK (Bartley et al., 2019). However, the role of *N. caninum* as a significant pathogen and abortifacient in flocks is yet under discussion. On the other hand, *T. gondii* has been reported as one of the most common abortive agents in sheep worldwide (Lindsay & Dubey, 2020). *Toxoplasma gondii* and *N. caninum* are closely related cyst-forming apicomplexan parasites with similar clinicopathological manifestations in sheep that can be differentiated both through immunohistochemical analysis and by detecting parasite DNA (Moreno et al., 2012). For this reason, it has been suggested that *N. caninum* may have been misidentified as *T. gondii* in previous studies (Moreno et al., 2012; González-Warleta et al., 2014, 2018).

The productivity of small ruminant flocks depends on their reproductive efficiency. In Argentina, ovine abortion is a major cause of economic losses (unpublished data of the Veterinary Diagnostic Service at INTA Balcarce, Argentina). Nevertheless, the research about abortion aetiology is still scarce (Paolicchi et al., 2013; Fiorentino et al., 2017; Gual et al., 2018; Hecker et al., 2019). Ovine neosporosis has been recently reported in Argentina. Initially, serological surveys demonstrated that *N. caninum* seroprevalences were 3% and 1.54% in dairy and meat sheep, respectively, indicating that *N. caninum* may not be an important pathogen affecting reproduction in Argentinian flocks (Hecker et al., 2013, 2018). Later, Hecker et al. (2019) reported the first case of ovine abortion caused by *N. caninum*. In addition, although anti-*T. gondii* antibodies have been investigated in Argentina (Hecker et al., 2013, 2018), clinical disease is also scarcely reported (Gual et al., 2018). In order to further evaluate the importance of protozoan parasites as causal agents of reproductive losses in sheep from Argentina, the aim of this study is to provide data about the occurrence *N. caninum* and *T. gondii* in cases of ovine abortion and perinatal death.

2. Materials and methods

2.1. Necropsy and sampling of aborted fetuses and perinatal deaths

A total of 30 aborted fetuses and 33 perinatal deaths from different sheep flocks were submitted to the Veterinary Diagnostic Service at INTA EEA Balcarce (Argentina) during 2017–2019. A complete necropsy was performed on all specimens. Foetal and placental tissues were examined by standard gross pathology procedures (Campero et al., 2003). Foetal cavity fluids were collected and stored at -20°C until assessment for the presence of antibodies against *N. caninum* and *T. gondii* by indirect fluorescent antibody technique (IFAT). Placental and foetal tissue samples (central nervous system, heart, lungs, liver, tongue, forelimb and hindlimb muscles) were collected for DNA extraction and histopathological analysis according to Hecker et al. (2019).

2.2. Serology

All foetal fluid samples were evaluated for anti-*N. caninum* and anti-*T. gondii* specific IgG by IFAT using a cut-off titre of 1:10 and the pertinent positive and negative controls as described earlier (Hecker et al., 2019).

2.3. DNA extraction and PCR

DNA was extracted using a commercially available kit according to the manufacturer's recommendations (High Pure PCR Template Preparation Kit, Roche, Mannheim, Germany). DNA concentration was measured using an Epoch micro-volume spectrophotometer system (Epoch, Biotek® Instruments, Inc., Vermont, USA). The concentration of DNA for all samples was adjusted with PCR-grade water to 50–100 ng/ μl .

For detection of *N. caninum* DNA, an adapted single-tube nested-PCR on the internal transcribed spacer 1 (ITS1) region was carried out using the external primers TgNN1 and TgNN2 (0.01 μM) and the internal primers NP1 and NP2 (0.2 μM) (Regidor-Cerrillo et al., 2014). In

addition, a PCR assay on the B1 gene was used to detect *T. gondii* DNA using the primers Tox5 and Tox8 (0.5 μM) as previously described by Moré et al. (2010). For both PCRs, the amplifications were performed in a reaction mixture of 24 μl consisting of 10 mM Tris-HCl, 2 mM MgCl_2 , 200 μM of each dNTP, and 1 unit of Taq Polymerase (Taq Pegasus, PB-L, Argentina). DNA of *N. caninum* (Nc1 strain) and *T. gondii* (RH strain) were used as positive controls. The DNA tachyzoite extraction (from each parasite) was made using the High Pure PCR Template Preparation Kit, (Roche) following the manufacturer's recommendations to extract DNA from blood cells. The secondary amplification products were visualized in a 1.8% agarose gel electrophoresis using SYBR Safe DNA gel stain (Invitrogen, Carlsbad, CA, USA) under UV light.

2.4. Procedures for differential diagnosis

Samples of lungs and abomasal content were cultured to determine the presence of aerobic, CO_2 -dependent and microaerophilic bacteria (*Brucella* spp., *Campylobacter* spp., *Salmonella* spp., *Listeria* spp.) (Fiorentino et al., 2017). In addition, a direct fluorescent antibody test was performed on foetal kidney imprints and smears of abomasal content for identification of *Leptospira* spp. and *Campylobacter* spp. (Campero et al., 2003) and a PCR assay on the *omp1* gene was used to detect *Chlamydia* spp. in placental and foetal tissue samples (Sachse, 2004). Finally, for viral isolation, spleen homogenates were inoculated onto Madin-Derby bovine kidney (MDBK) cell cultures as described Odeón et al. (2003) and were tested for border disease virus (BDV) by an indirect fluorescent antibody procedure with a polyclonal antibody (VMRD, Pullman, TN, USA).

2.5. Histopathological and immunohistochemical analysis

Five μm -thick sections of each foetal tissue were cut, mounted on glass microscope slides, and stained with haematoxylin and eosin (H&E). Histopathological lesions found in analysed tissues were classified according to their severity and the number of inflammatory lesions. Lesions were classified as mild when they were limited to focal lymphohistiocytic inflammatory infiltrates. Multifocal non-suppurative inflammatory lesions were classified as moderate. Lesions were classified as severe when necrotizing areas were observed with the presence of non-suppurative inflammation, in some cases, with the presence protozoan cysts and/or mineralization. Tissues that had protozoan-compatible lesions were selected and analysed by immunohistochemistry (IHC) test using polyclonal antibodies against *N. caninum* (kindly provided by Dr M. Anderson, UC Davis, USA) and *T. gondii* (kindly provided by Dr M.C. Venturini, UNLP, Argentina) and Dako EnVision kit (Carpinteria, CA, USA), employed according to the manufacturer's instructions.

2.6. Established criteria for etiological diagnosis

A diagnosis of congenital infection with *N. caninum* or *T. gondii* was made when PCR and/or IFAT results were positive. Furthermore, these parasites were confirmed as the cause of abortion or perinatal death according to the following criteria: (i) presence of compatible histopathological lesions and/or positive IHC test; (ii) positive PCR and/or positive IFAT; and (iii) no other infectious agents diagnosed. When the cause of death could not be narrowed down to either *Neospora* or *Toxoplasma* because the IHC test was negative for both pathogens, death was deemed to be caused by "protozoan parasites". Finally, a diagnosis was considered indeterminate when no causative agent could be detected by any of the laboratory tests.

3. Results

3.1. Diagnosis of the analysed specimens

A total of 30 aborted fetuses and 33 perinatal death cases were received from 9 to 8 flocks, respectively. Information about the number

of analysed specimens according to production system and its location is included in Table 1. The submitted aborted foetuses had a gestation age of 2–5 months; gestation age of 80% of them was between 110 and 150 days. In 18 out of the 30 aborted foetuses, the cause of foetal death was determined (60%) (Table 2). In 14 foetuses, the abortion was caused by an infectious agent, of which 8 were caused by protozoan infection (57.14%). On the other hand, in 25 out of the 33 perinatal death cases a diagnosis was achieved (75.75%) (Table 2). Of these, 14 lamb deaths were caused by infectious agents, of which protozoans were involved in 5 cases (35.71%).

3.1.1. *Neospora caninum*

Congenital infection with *N. caninum* (PCR and/or presence of antibodies) was confirmed in 9 out of 30 (30%) aborted analysed foetuses (Table 3). However, *N. caninum* was confirmed as the cause of abortion (based on the presence of compatible histopathological lesions and/or positive IHC test, positive PCR and/or positive IFAT, and no other infectious agent diagnosed) only in 7 foetuses (23.33%). In one of the aborted foetuses (#18N203), co-infection with *N. caninum* + *T. gondii* was detected (positive PCR for both pathogens); nevertheless, although the lesions were compatible with protozoan parasites, the etiological diagnosis could not be confirmed because the IHC test was negative for both pathogens. In another foetus (#18N204) a co-infection was detected but the final diagnosis was associated with *Leptospira* spp. since it resulted positive by IFAT (data not shown) and the lesions observed were compatible with lesions caused by this spirochete.

Congenital infection with *N. caninum* was confirmed in 4 out of 33 (12.12%) perinatal death cases. Nevertheless, only in a single specimen (3.03%) the infection with *N. caninum* was considered as the cause of perinatal death (based on the presence of compatible histopathological lesions, positive PCR and/or positive IFAT, and no other infectious agent diagnosed) (Table 3). In another perinatal death case (#19N120), co-infection with *N. caninum* + *T. gondii* was detected by PCR with lesions compatible with protozoan parasites, but the IHC test was negative for both pathogens; thus the final diagnosis could not be confirmed. In addition, in 2 death cases of lambs infected with *N. caninum* (#18N132 and #18B87) lesions compatible with foetal stress were detected, i.e. lesions associated with foetal hypoxia and presence of meconium in

Table 1

Number of analyzed specimens according to the production system and its location

Death cause	Production system (N)	Location (n)
Abortion	Meat flocks (N = 8)	Buenos Aires (n = 19)
		Corrientes (n = 5)
		Santa Fe (n = 1)
Perinatal death	Dairy flocks (N = 1)	Entre Ríos (n = 1)
	Meat flocks (N = 7)	Buenos Aires (n = 4)
		Buenos Aires (n = 24)
		Corrientes (n = 8)
Dairy flocks (N = 1)	Buenos Aires (n = 1)	

Abbreviations: N, number of flocks; n, number of specimens.

Table 2

Diagnoses of the analyzed specimens

Agent diagnosed	Cause of abortion	Cause of perinatal death	Total specimens
<i>Neospora caninum</i>	7	1	8
<i>Toxoplasma gondii</i>	0	2	2
Protozoan parasites ^a	1	2	3
Other infectious causes (bacteria, viruses, fungi)	6	9	15
Non-infectious causes	4	11	15
Indeterminate diagnosis	12	8	20
Total specimens	30	33	63

^a Mixed infection with *N. caninum* and *T. gondii*.

bronchi or pulmonary alveoli; thus in these cases we assumed that foetal stress was the cause of death because the lesions were not compatible lesions with protozoan parasites.

Histopathological findings in all aborted foetuses and dead lambs where the infection with *N. caninum* was considered the cause of the reproductive loss, varied in their severity from mild to moderate but no differential severity lesions were found between aborted foetuses and perinatal death cases. Lesions varied from non-suppurative inflammatory infiltrates, areas of necrosis and/or parasite cysts in younger foetuses to lesions limited to a mild non-suppurative inflammatory infiltrate in the full-term aborted foetuses or perinatal death cases. Some specimens were mummified, their tissues being severely autolyzed. When placenta was available, the most common lesion was a diffuse lymphohistiocytic placentitis with vasculitis, and multifocal necrosis. In the central nervous system, moderate to severe multifocal non-suppurative necrotizing myelomeningoencephalitis was commonly detected. In one aborted foetus, this lesion was severe and associated with the presence of *N. caninum* cysts (#19N56). In the heart, the most frequent lesion was a moderate diffuse lymphohistiocytic endocarditis with extensive myocarditis and pericarditis (Fig. 1A). Finally, non-suppurative multifocal glossitis and non-suppurative hepatitis (Fig. 1B) and pneumonia were commonly observed. *N. caninum* cysts and/or unencysted zoites were detected in IHC analysis of the brain (#19N56) (Fig. 1C) and tongue (#17N156).

3.1.2. *Toxoplasma gondii*

Congenital infection with *T. gondii* was confirmed based on PCR and/or presence of antibodies in 2 out of the 30 (6.66%) aborted foetuses, but this parasite could not be confirmed in any of these specimens as the cause of death since no compatible lesions and/or positive IHC test were detected. Co-infections with *N. caninum* alone (#18N203) and *Leptospira* spp. and *N. caninum* (#18N204) were detected in two aborted foetuses. Again, in both foetuses the abortion could not be associated directly with *T. gondii* (Table 3).

Among perinatal death cases, congenital infection with *T. gondii* was confirmed in 4 out of 33 lambs (12.12%), but only in 2 of them (6.06%) the infection was determined as the cause of death (based on the presence of compatible histopathological lesions, positive PCR and/or positive IFAT, and no other infectious agent diagnosed) (Table 3). Two death lambs were co-infected with *T. gondii* + *N. caninum* (#18N132 and #19N120), although the diagnosis could not be associated with *T. gondii* as indicated above (Section 3.1.1). In addition, in one perinatal death case, there were severe histological lesions compatible with protozoan infection (#19N117), but the IHC test was negative and unfortunately, there were no tissues and serum samples available for molecular and serological studies, respectively; therefore the diagnosis could not be confirmed.

In the two specimens in which the death was caused by *T. gondii* (#19N115 and #19N116) the histological lesions ranged from moderate to severe with non-suppurative multifocal necrotizing meningoencephalitis (Fig. 1D), non-suppurative multifocal necrotizing myocarditis, non-suppurative interstitial pneumonia, multifocal non-suppurative glossitis and multifocal non-suppurative myositis. Immunohistochemistry for *T. gondii* was negative in all tissues with compatible lesions and no serological evidence for this parasite was detected in foetal fluids.

4. Discussion

In the present study, aborted foetuses and perinatal death cases were analysed and the importance of *N. caninum* and *T. gondii* as causes of reproductive losses in sheep production systems in Argentina was assessed. To the best of our knowledge, this is the first study carried out on a significant number of aborted sheep foetuses and perinatal deaths in Argentina and even in South America, using serology, molecular and histopathological techniques. Previous serological studies in Argentina have hypothesized that *N. caninum* would not be an important pathogen

Table 3Diagnosis of *Neospora caninum* and *Toxoplasma gondii* by histopathology, serology (IFAT), PCR and immunohistochemistry (IHC) in the studied specimens

ID	Moment of fetal death	Histopathological lesions compatible with protozoan parasites	<i>Neospora caninum</i>			<i>Toxoplasma gondii</i>			Congenital infection	Etiological diagnosis
			IFAT	PCR	IHC	IFAT	PCR	IHC		
17N156	112 dg	+	+	+	+	-	-	-	<i>N. caninum</i>	<i>N. caninum</i>
18N197	80 dg	+	-	+	-	-	-	-	<i>N. caninum</i>	<i>N. caninum</i>
18N198	80 dg	+	+	+	-	-	-	-	<i>N. caninum</i>	<i>N. caninum</i>
18N199	Full term	+	-	+	-	-	-	-	<i>N. caninum</i>	<i>N. caninum</i>
18N201	Full term	+	+	+	-	-	-	-	<i>N. caninum</i>	<i>N. caninum</i>
18N203	Full term	+	-	+	-	-	+	-	<i>N. caninum</i> + <i>T. gondii</i>	<i>N. caninum</i> or <i>T. gondii</i> ?
18N204	Full term	-	+	-	-	-	+	-	<i>N. caninum</i> + <i>T. gondii</i>	<i>Leptospira</i> spp.
19N56	130 dg	+	+	+	+	-	-	-	<i>N. caninum</i>	<i>N. caninum</i>
19N119	Full term	+	+	+	-	-	-	-	<i>N. caninum</i>	<i>N. caninum</i>
18N132	Perinatal death	-	+	+	-	-	+	-	<i>N. caninum</i> + <i>T. gondii</i>	Fetal stress
18B78	Perinatal death	+	-	+	-	-	-	-	<i>N. caninum</i>	<i>N. caninum</i>
18B87	Perinatal death	+	na	+	-	na	-	-	<i>N. caninum</i>	Fetal stress
19N115	Perinatal death	+	-	-	-	+	+	-	<i>T. gondii</i>	<i>T. gondii</i>
19N116	Perinatal death	+	na	-	-	na	+	-	<i>T. gondii</i>	<i>T. gondii</i>
19N117	Perinatal death	+	na	na	-	na	na	-	<i>N. caninum</i> or <i>T. gondii</i> ?	<i>N. caninum</i> or <i>T. gondii</i> ?
19N120	Perinatal death	+	+	+	-	-	+	-	<i>N. caninum</i> + <i>T. gondii</i>	<i>N. caninum</i> or <i>T. gondii</i> ?

Abbreviations: dg, days of gestation; na, not available.

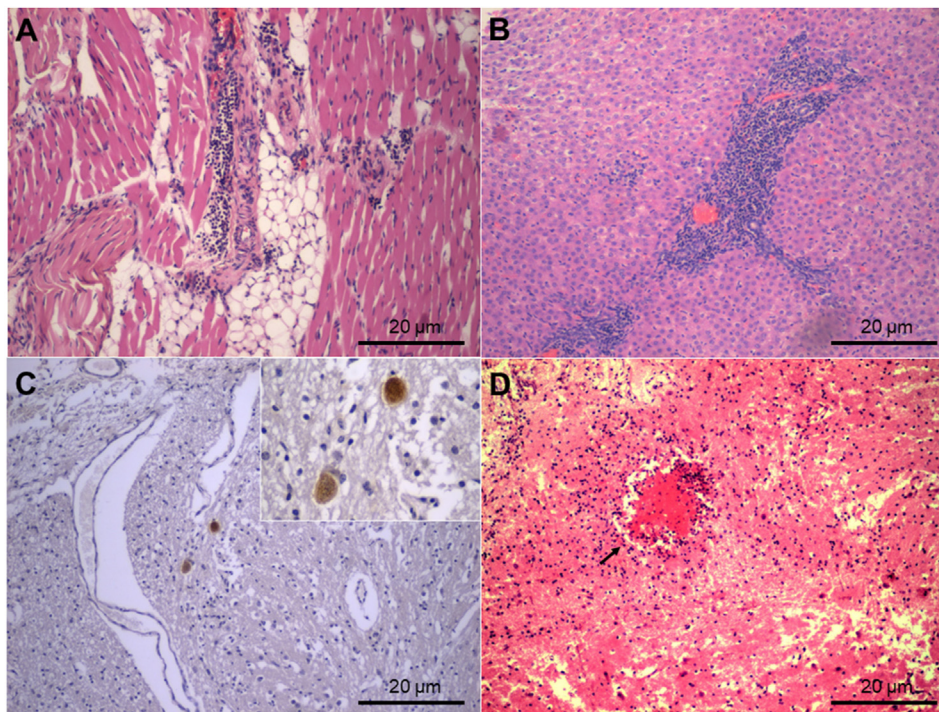


Fig. 1. Pathological findings in the analysed specimens with neosporosis and toxoplasmosis. **A** Severe non-suppurative myocarditis in a full-term foetus infected with *N. caninum* (H&E, 100 \times). **B** Severe non-suppurative periportal hepatitis in a 1-day-old lamb infected with *N. caninum* (H&E, 100 \times). **C** Protozoan cysts of *N. caninum* immunolabeled in cerebral cortex (IHC, 100 \times). **D** Severe non-suppurative focal necrotizing encephalitis in a 1-day-old lamb infected with *T. gondii* (black arrows) (H&E, 100 \times).

of the reproductive tract in the Argentinian flocks (Hecker et al., 2013, 2018). However, a low number of flocks were sampled in these studies, and the results may have underestimated the real impact of ovine neosporosis. In the present study, although the number of flocks under study was limited, the fact that they come from four Argentinian provinces in which the dairy and meat ovine production is important (https://www.magyp.gov.ar/sitio/areas/d_ovinos/), gives relevance to the preliminary results obtained. The present study allowed us to determine the frequency of congenital infections by PCR and/or IFAT, and the involvement of the protozoan pathogens *N. caninum* and *T. gondii* as causes of abortion or perinatal death based on the presence of compatible histopathological lesions and/or positive IHC test.

The results of the present study showed that *N. caninum* is frequently vertically transmitted in Argentinian sheep flocks (20.63% of the 63 specimens) in agreement with previous results reported in other countries (Hughes et al., 2005; Buxton et al., 2007; Howe et al., 2012; Moreno

et al., 2012; Razmi & Naseri, 2017). Considering that *N. caninum* is one of the most important causes of bovine abortion in Argentinian production systems, an epidemiological relationship may be involved. Further, the use of farm working dogs is frequent in both systems (bovine and ovine) and this practice may influence our findings. Although the main transmission way of *N. caninum* has traditionally been considered to be vertical, a previous study in Argentina indicated that in some farms with specific husbandry conditions, the horizontal transmission may play a key role (Moré et al., 2009). Therefore, further studies analysing more specimens from more flocks are necessary to expand our knowledge of the epidemiology of ovine neosporosis in Argentina.

Neospora caninum was confirmed as the cause of death in 8 (7 abortions and 1 perinatal death) out of 13 specimens with *N. caninum* congenital infection. In these 8 specimens, no evidence of other pathogen infection was detected (including *T. gondii*). Although IHC test was performed in these foetuses to differentiate from *T. gondii*, positive

immunostaining for *N. caninum* was detected only in two aborted foetuses, possibly due to the mild to moderate lesions found in these specimens and the low sensitivity of this technique as previously reported (Van Maanen et al., 2004). However, the detection of *N. caninum* DNA by PCR (and the absence of *T. gondii* DNA), the presence of antibodies detected by IFAT and the compatible histological lesions were sufficient to confirm *N. caninum* as the cause of these reproductive losses.

In the present study, most of the aborted foetuses referred for diagnosis had a gestational age of 75 days or more. Therefore, in the absence of early abortion specimens to analyse, this study could not determine the term in which *N. caninum*-related abortions were more prevalent. Experimental infections with *N. caninum* in sheep have shown that *N. caninum* can cause foetal death at any time of gestation (Weston et al., 2009; Arranz-Solís et al., 2015) although under field conditions sheep abortions of less than 75 days of gestation are difficult to find and recover for further analysis. Howe et al. (2012) suggested that naturally infected sheep are exposed to lower infectious doses and at variable times during pregnancy compared with animals under experimental conditions. Thus, a variety of pregnancy outcomes could be expected in any given flock experiencing abortions due to *N. caninum* infection. However, if we consider that this species is very efficiently vertically transmitted in flocks and that the moment of parasite reactivation occurs during mid-gestation, due to the natural immunosuppression that occurs in the dam, it could be hypothesized that most of the abortions occur from this moment on, as it has been previously reported in cattle (Benavides et al., 2014).

In this study, the presence of parasite cysts in the central nervous system was detected by IHC test in one aborted foetus at 130 days of gestation (#19N56) infected with *N. caninum*. This finding was previously described by González-Warleta et al. (2018) but in stillbirth with milder lesions and an immunologically controlled infection, allowing the parasite to reach a quiescent stage. However, in the present study, the histopathological lesions found in this aborted foetus were severe, indicating the absence of foetal immunocompetence and an uncontrolled infection that finally caused its foetal death. In addition, many of the foetuses in which *N. caninum* was diagnosed showed moderate or mild lesions, according to the gestation progress. Previous studies have reported that the severity and distribution of lesions in the central nervous system, heart and lungs may be affected by gestational age (Weston et al., 2009; Benavides et al., 2014). Considering the PCR results for *N. caninum* in the present study indicating congenital infection, it is likely that the parasite reactivation occurs after the middle of the gestation period, as previously reported (Jolley et al., 1999; González-Warleta et al., 2014, 2018). Therefore, the foetuses were already immunocompetent, so the foetal lesions were less severe, although the foetal or perinatal deaths were caused. Other authors reported that the effects of neosporosis could be more damaging in sheep than in cattle, even though the transplacental passage of the parasite occurs when the foetal lambs have already developed immunocompetency (Arranz-Solís et al., 2015; González-Warleta et al., 2018). However, in the present study *N. caninum* was only the cause of a single perinatal death (#18B78), and the histopathological lesions found in this specimen were mild and no parasite cysts were detected.

As shown in Table 3, congenital coinfections were detected by IFAT and PCR in two aborted foetuses and in two perinatal deaths. In two of these specimens (#18N203 and #19N120), histopathological lesions were compatible with protozoan parasites, but the death cause could not be confirmed because the IHC test was negative in both specimens. Gondim et al. (2017) reviewed the serological cross-reactivity among *T. gondii*, *Hammondia* spp., *N. caninum* spp., *Sarcocystis* spp. and *Besnoitia besnoiti* in cattle, reporting serological cross-reactivity between *T. gondii* and *N. caninum*. However, in the coinfecting specimens studied here, antibodies were only detected against *N. caninum* and not against *T. gondii*, possibly due the presence of persistently infected but clinically unaffected dams that reactivated their *N. caninum* infection during gestation producing the endogenous transplacental transmission of the

parasite (González-Warleta et al., 2018). In addition, the lack of antibodies against *T. gondii* in the analysed specimens may indicate an acute infection or the existence of an immune response in the dams that prevented the parasite reactivation during gestation and, thus, the endogenous transplacental transmission (Benavides et al., 2017). Likewise, the PCR results allowed confirming a co-infection with both parasites. It has been shown by others that a flock with reproductive problems exhibited simultaneously both *N. caninum* and *T. gondii* infections (Hässig et al., 2003). Therefore, we cannot rule out that the simultaneous infection with both pathogens has caused death in both specimens. However, the aetiology of reproductive failure is multifactorial and therefore the possible contribution of other factors (physical, chemical and biological) cannot be completely ruled out.

Toxoplasma gondii is one of the most important pathogens of the reproductive tract in small ruminants, leading to important losses in the sheep industry worldwide due to abortions after primo-infection of pregnant sheep (Dubey, 2009). The presence of *T. gondii*-seropositive sheep was previously reported in Argentina (Hecker et al., 2013, 2018) and a case of spontaneous abortion due to *T. gondii* infection has been reported in a flock in Buenos Aires Province (Gual et al., 2018). In the present study, endogenous transplacental transmission of *T. gondii* was scarcely detected (9.52%) coinciding with the findings of other authors from other countries suggesting that this transmission route may not be important for this pathogen (Buxton et al., 2007; Dubey, 2009; Innes et al., 2009) compared with the frequently detected endogenous transplacental transmission of *N. caninum* in cattle (Trees & Williams, 2005; Lindsay & Dubey, 2020) and sheep (Jolley et al., 1999; González-Warleta et al., 2018). Additionally, *T. gondii* could only be confirmed as the cause of two perinatal deaths but not in aborted foetuses, being less frequent than previously reported in the literature (Hughes et al., 2005; Dubey, 2009; Moraes et al., 2011; Moreno et al., 2012; Sah et al., 2019).

The histopathological findings in the *T. gondii*-infected perinatal death cases (#19N115, #19N116) were more severe compared with lesions found in perinatal death cases caused by *N. caninum* infection. Similar findings have been described in naïve dams infected for the first time providing evidence that maternal and foetal immune systems are unable to control *T. gondii* infection (Benavides et al., 2017). Therefore, an out-of-control parasite infection that invades the placenta and the developing foetus causes its death. Unfortunately, because *T. gondii* could not be diagnosed as death cause in any foetus, a comparative analysis with *N. caninum*, considering lesion severity and abortion timing for aborted foetuses could not be made. A recent study of Nayeri et al. (2021) reported the global prevalence of *T. gondii* infection in the aborted foetuses. This study provided evidence that the overall prevalence rates of *T. gondii* infection detected by molecular methods or serological tests in aborted foetuses and stillbirths were 42% and 16%, respectively, over a total of 4383 studied specimens. The findings of this global meta-analysis show the importance of *T. gondii* as a cause of reproductive losses worldwide. Considering the limited availability of analysed samples in the present study, we could neither confirm nor rule out that toxoplasmosis is a major problem in Argentinian sheep flocks.

5. Conclusions

The results of the present study showed that *N. caninum* is vertically transmitted and was frequently associated as a cause of reproductive losses in sheep from the analysed Argentinian flocks. Considering that *N. caninum* is one of the most important causes of bovine abortion in Argentina, an epidemiological study about ovine neosporosis evaluating other husbandry conditions should be performed. The findings demonstrate that neosporosis should be included as a frequent cause of ovine abortion in Argentina. Despite *T. gondii* congenital infection was detected in some specimens (6/63), it was confirmed as the cause of death in only two of them. Thus, and considering the limited availability of confirmed samples, we could not determine whether toxoplasmosis is a major problem in Argentinian sheep flocks or not. More studies on a greater

number of specimens from different ovine production systems under different management conditions are necessary to assess the real impact of neosporosis and toxoplasmosis in Argentina.

Funding

This study was funded by research grants from the Agencia Nacional de Promoción Científica y Tecnológica (FONCyT: PICT 2016-0195), INTA (PE 115055 and 2019-PE-E1-1002-001), Argentina, and from Red CYTED113RT0469 (PROTOZOOVAC).

Ethical approval

Animal procedures were performed according to standard protocols and guidelines from the Animal Ethics Committee (CICUA#008/2015) at INTA, Argentina.

CRediT author statement

Conceived and designed the experiments: YPH, MAF, GJC. Performed the experiments: PDR, YPH, MAF, GJC, ELM, MVS. Analysed the data: YPH, PDR. Contributed reagents/materials/analysis tools: YPH, MAF, PDR, GJC, ELM, DPM, FP. Wrote and commented on the manuscript: PDR, YPH, GJC, MAF, DPM, FP, ELM. All authors read and approved the final manuscript.

Declaration of competing interests

The authors declare that they have no known competing financial interests or personal relationships that could have appeared to influence the work reported in this paper.

Acknowledgments

We gratefully acknowledge the technicians and colleagues from the Animal Health Group at INTA Balcarce.

References

- Al-Shaeli, S.J.J., Ethaeb, A.M., Gharban, H.A.J., 2020. Molecular and histopathological identification of ovine neosporosis (*Neospora caninum*) in aborted ewes in Iraq. *Vet. World* 13, 597–603. <https://doi.org/10.14202/vetworld.2020.597-603>.
- Amdouni, Y., Rjeibi, M.R., Awadi, S., Rezik, M., Gharbi, M., 2018. First detection and molecular identification of *Neospora caninum* from naturally infected cattle and sheep in North Africa. *Transbound. Emerg. Dis.* 65, 976–982. <https://doi.org/10.1111/tbed.12828>.
- Arranz-Solis, D., Benavides, J., Regidor-Cerrillo, J., Fuertes, M., Ferre, I., Ferreras, M.C., et al., 2015. Influence of the gestational stage on the clinical course, lesional development and parasite distribution in experimental ovine neosporosis. *Vet. Res.* 46, 19. <https://doi.org/10.1186/s13567-014-0139-y>.
- Asadpour, R., Jafari-Joozani, R., Salehi, N., 2013. Detection of *Neospora caninum* in ovine abortion in Iran. *J. Parasit. Dis.* 37, 105–109. <https://doi.org/10.1007/s12639-012-0141-0>.
- Bartley, P.M., Guido, S., Mason, C., Stevenson, H., Chianini, F., Carty, H., et al., 2019. Detection of *Neospora caninum* DNA in cases of bovine and ovine abortion in the South-West of Scotland. *Parasitology* 146, 979–982. <https://doi.org/10.1017/S0031182019000301>.
- Benavides, J., Collantes-Fernández, E., Ferre, I., Pérez, V., Campero, C., Mota, R., et al., 2014. Experimental ruminant models for bovine neosporosis: What is known and what is needed. *Parasitology* 141, 1471–1488. <https://doi.org/10.1017/S0031182014000638>.
- Benavides, J., Fernández, M., Castaño, P., Ferreras, M.C., Ortega-Mora, L., Pérez, V., 2017. Ovine toxoplasmosis: A new look at its pathogenesis. *J. Comp. Pathol.* 157, 34–38. <https://doi.org/10.1016/j.jcpa.2017.04.003>.
- Buxton, D., Maley, S.W., Wright, S.E., Rodger, S., Bartley, P., Innes, E.A., 2007. *Toxoplasma gondii* and ovine toxoplasmosis: New aspects of an old story. *Vet. Parasitol.* 149, 25–28. <https://doi.org/10.1016/j.vetpar.2007.07.003>.
- Campero, C.M., Moore, D.P., Odeón, A.C., Cipolla, A.L., Odriozola, E., 2003. Aetiology of bovine abortion in Argentina. *Vet. Res. Commun.* 27, 359–369. <https://doi.org/10.1023/a:1024754003432>.
- Dubey, J.P., 2009. Toxoplasmosis in sheep - the last 20 years. *Vet. Parasitol.* 163, 1–14. <https://doi.org/10.1016/j.vetpar.2009.02.026>.

- Filho, P.C.G.A., Oliveira, J.M.B., Andrade, M.R., Silva, J.G., Kim, P.C.P., Almeida, J.C., et al., 2017. Incidence and vertical transmission rate of *Neospora caninum* in sheep. *Comp. Immunol. Microbiol. Infect. Dis.* 52, 19–22. <https://doi.org/10.1016/j.cimid.2017.05.006>.
- Fiorentino, M.A., Stazonati, M., Hecker, Y., Morsella, C., Cantón, G., Romero Harry, H., et al., 2017. *Campylobacter fetus* subsp. *fetus* ovine abortion outbreak in Argentina. *Redvet* 18, 1–11. <https://www.redalyc.org/pdf/636/63653574024.pdf>.
- Gazzonis, A., Villa, L., Manfredi, M.T., Zanzani, S., 2019. Spatial analysis of infections by *Toxoplasma gondii* and *Neospora caninum* (Protozoa: Apicomplexa) in small ruminants in northern Italy. *Animals (Basel)* 9, 916. <https://doi.org/10.3390/ani9110916>.
- Gondim, L.F.P., Mineo, J.R., Schares, G., 2017. Importance of serological cross-reactivity among *Toxoplasma gondii*, *Hammondia* spp., *Neospora* spp., *Sarcocystis* spp. and *Besnoitia besnoiti*. *Parasitology* 144, 851–868. <https://doi.org/10.1017/S0031182017000063>.
- González-Warleta, M., Castro-Hermida, J.A., Calvo, C., Pérez, V., Gutiérrez-Expósito, D., Regidor-Cerrillo, J., et al., 2018. Endogenous transplacental transmission of *Neospora caninum* during successive pregnancies across three generations of naturally infected sheep. *Vet. Res.* 49, 106. <https://doi.org/10.1186/s13567-018-0601-3>.
- González-Warleta, M., Castro-Hermida, J.A., Regidor-Cerrillo, J., Benavides, J., Álvarez-García, G., Fuertes, M., et al., 2014. *Neospora caninum* infection as a cause of reproductive failure in a sheep flock. *Vet. Res.* 45, 88. <https://doi.org/10.1186/s13567-014-0088-5>.
- Gual, I., Giannitti, F., Hecker, Y.P., Shivers, J., Entrocassi, A.C., Morrell, E.L., et al., 2018. First case report of *Toxoplasma gondii*-induced abortions and stillbirths in sheep in Argentina. *Vet. Parasitol. Reg. Stud. Reports* 12, 39–42. <https://doi.org/10.1016/j.vprsr.2018.01.001>.
- Hässig, M., Sager, H., Reitt, K., Ziegler, D., Strabel, D., Gottstein, B., 2003. *Neospora caninum* in sheep: A herd case report. *Vet. Parasitol.* 117, 213–220. <https://doi.org/10.1016/j.vetpar.2003.07.029>.
- Hecker, Y.P., Mogaburu Masson, F., Armendano, J.I., Cora, J., Flores Olivares, C., Gual, I., et al., 2018. Evaluation of frequency of antibodies against *Toxoplasma gondii*, *Neospora caninum* and *Sarcocystis* spp. and transmission routes in sheep from Humid Pampa, Argentina. *Acta Parasitol.* 63, 416–421. <https://doi.org/10.1515/ap-2018-0048>.
- Hecker, Y.P., Moore, D.P., Manazza, J.A., Unzaga, J.M., Spath, E.J.A., Pardini, L.L., et al., 2013. First report of seroprevalence of *Toxoplasma gondii* and *Neospora caninum* in dairy sheep from Humid Pampa, Argentina. *Trop. Anim. Health Prod.* 45, 1645–1647. <https://doi.org/10.1007/s11250-013-0396-1>.
- Hecker, Y.P., Morrell, E.L., Fiorentino, M.A., Gual, I., Rivera, E., Fiorani, F., et al., 2019. Ovine abortion by *Neospora caninum*: First case reported in Argentina. *Acta Parasitol.* 64, 950–955. <https://doi.org/10.2478/s11686-019-00106-z>.
- Howe, L., Collett, M.G., Pattison, R.S., Marshall, J., West, D.M., Pomroy, W.E., 2012. Potential involvement of *Neospora caninum* in naturally occurring ovine abortions in New Zealand. *Vet. Parasitol.* 185, 64–71. <https://doi.org/10.1016/j.vetpar.2011.10.033>.
- Hughes, J.M., Williams, R.H., Morley, E.K., Cook, D.A.N., Terry, R.S., Murphy, R.G., et al., 2005. The prevalence of *Neospora caninum* and co-infection with *Toxoplasma gondii* by PCR analysis in naturally occurring mammal populations. *Parasitology* 32, 29–36. <https://doi.org/10.1017/S0031182005008784>.
- Innes, E.A., Bartley, P.M., Buxton, D., Katzer, F., 2009. Ovine toxoplasmosis. *Parasitology* 136, 1887–1894. <https://doi.org/10.1017/S0031182009991636>.
- Jolley, W.R., McAllister, M.M., McGuire, A.M., Wills, R.A., 1999. Repetitive abortion in *Neospora*-infected ewes. *Vet. Parasitol.* 82, 251–257. [https://doi.org/10.1016/s0304-4017\(99\)00017-5](https://doi.org/10.1016/s0304-4017(99)00017-5).
- Lindsay, D.S., Dubey, J.P., 2020. Neosporosis, toxoplasmosis, and sarcocystosis in ruminants: An update. *Vet. Clin. North Am. Food Anim. Pract.* 36, 205–222. <https://doi.org/10.1016/j.cvfa.2019.11.004>.
- Moraes, E.P.B.X., da Costa, M.M., Medeiros Dantas, A.F., Ramos da Silva, J.C., Mota, R.A., 2011. *Toxoplasma gondii* diagnosis in ovine aborted fetuses and stillborns in the State of Pernambuco, Brazil. *Vet. Parasitol.* 183, 152–155. <https://doi.org/10.1016/j.vetpar.2011.06.023>.
- Moré, G., Bacigalupe, D., Basso, W., Rambeaud, M., Beltrame, F., Ramirez, B., et al., 2009. Frequency of horizontal and vertical transmission for *Sarcocystis cruzi* and *Neospora caninum* in dairy cattle. *Vet. Parasitol.* 160, 51–54. <https://doi.org/10.1016/j.vetpar.2008.10.081>.
- Moré, G., Pardini, L., Basso, W., Machuca, M., Bacigalupe, D., Villanueva, M.C., et al., 2010. Toxoplasmosis and genotyping of *Toxoplasma gondii* in *Macropus rufus* and *Macropus giganteus* in Argentina. *Vet. Parasitol.* 169, 57–61. <https://doi.org/10.1016/j.vetpar.2009.12.004>.
- Moreno, B., Collantes-Fernández, E., Villa, A., Navarro, A., Regidor-Cerrillo, J., Ortega-Mora, L.M., 2012. Occurrence of *Neospora caninum* and *Toxoplasma gondii* infections in ovine and caprine abortions. *Vet. Parasitol.* 187, 312–318. <https://doi.org/10.1016/j.vetpar.2011.12.034>.
- Nayeri, T., Sarvi, S., Moosazadeh, M., Daryani, A., 2021. Global prevalence of *Toxoplasma gondii* infection in the aborted fetuses and ruminants that had an abortion: A systematic review and meta-analysis. *Vet. Parasitol.* 290, 109370. <https://doi.org/10.1016/j.vetpar.2021.109370>.
- Odeón, A.C., Risatti, G., Kaiser, G.G., Leunda, M.R., Odriozola, E., Campero, C.M., Donis, R.O., 2003. Bovine viral diarrhoea virus genomic associations in mucosal disease, enteritis and generalized dermatitis outbreaks in Argentina. *Vet. Microbiol.* 96, 133–144. [https://doi.org/10.1016/s0378-1135\(03\)00210-4](https://doi.org/10.1016/s0378-1135(03)00210-4).
- Paolicchi, F.A., Nuñez, M., Fiorentino, M.A., Malena, R.C., Trangoni, M., Cravero, S., Estein, S.M., 2013. Immune response and reproductive consequences in experimentally infected ewes with *Brucella ovis* during late pregnancy. *Rev. Argent. Microbiol.* 45, 13–20.

- Pereira, K.A.G., Silva de Sousa, R., Varaschin, M.S., Becker, A.P.B.B., Monteiro, A.L.G., de Oliveira Koch, M., et al., 2021. Transplacental transmission of *Neospora caninum* to lambs in successive pregnancies of naturally infected sheep in Southern Brazil. *Vet. Parasitol. Reg. Stud. Reports* 23, 100537. <https://doi.org/10.1016/j.vprsr.2021.100537>.
- Razmi, G., Naseri, Z., 2017. Molecular detection of *Neospora caninum* infection in ovine aborted foetuses in the Mashhad area, Iran. *Ann. Parasitol.* 63, 45–47. <https://doi.org/10.17420/ap6301.84>.
- Regidor-Cerrillo, J., Arranz-Solís, D., Benavides, J., Gómez-Bautista, M., Castro-Hermida, J.A., Mezo, M., Pérez, V., et al., 2014. *Neospora caninum* infection during early pregnancy in cattle: How the isolate influences infection dynamics, clinical outcome and peripheral and local immune responses. *Vet. Res.* 45, 10. <https://doi.org/10.1186/1297-9716-45-10>.
- Reichel, M.P., Ayanequi-Alcérrec, M.A., Gondim, L.F.P., Ellis, J.T., 2013. What is the global economic impact of *Neospora caninum* in cattle - the billion dollar question. *Int. J. Parasitol.* 43, 133–142. <https://doi.org/10.1016/j.ijpara.2012.10.022>.
- Sachse, K., 2004. Specificity and performance of PCR detection assays for microbial pathogens. *Mol. Biotechnol.* 26, 61–80. <https://doi.org/10.1385/MB:26:1:61>.
- Sah, R.P., Dey, A.R., Rahman, A.K.M.A., Alam, M.Z., Talukder, M.d.H., 2019. Molecular detection of *Toxoplasma gondii* from aborted fetuses of sheep, goats and cattle in Bangladesh. *Vet. Parasitol. Reg. Stud. Reports* 18, 100347. <https://doi.org/10.1016/j.vprsr.2019.100347>.
- Trees, A.J., Williams, D.J., 2005. Endogenous and exogenous transplacental infection in *Neospora caninum* and *Toxoplasma gondii*. *Trends Parasitol.* 21, 558–561. <https://doi.org/10.1016/j.pt.2005.09.005>.
- Van Maanen, C., Wouda, W., Schares, G., Von Blumröder, D., Conraths, F.J., Norton, R., et al., 2004. An interlaboratory comparison of immunohistochemistry and PCR methods for detection of *Neospora caninum* in bovine foetal tissues. *Vet. Parasitol.* 126, 351–364. <https://doi.org/10.1016/j.vetpar.2004.08.016>.
- West, D.M., Pomroy, W.E., Collett, M.G., Hill, F.I., Ridler, A.L., Kenyon, P.R., et al., 2006. A possible role for *Neospora caninum* in ovine abortion in New Zealand. *Small Rumin. Res.* 62, 135–138. <https://doi.org/10.1016/j.smallrumres.2005.07.041>.
- Weston, J.F., Howe, L., Collett, M.G., Pattison, R.S., Williamson, N.B., West, D.M., et al., 2009. Dose-titration challenge of young pregnant sheep with *Neospora caninum* tachyzoites. *Vet. Parasitol.* 164, 183–191. <https://doi.org/10.1016/j.vetpar.2009.05.013>.