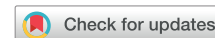

Delayed cardiac tamponade in catheter ablation for paroxysmal atrial fibrillation induced by a subacute hemorrhage



Hironori Ishiguchi, MD, PhD,* Masaaki Yoshida, MD, PhD,*
Tetsuya Kawabata, MD, PhD,* Yasuhiro Yoshiga, MD, PhD,[†] Akihiko Shimizu, MD, PhD,[‡]
Tsuyoshi Oda, MD, PhD*

From the *Division of Cardiology, Shimane Prefectural Central Hospital, Izumo, Japan, [†]Division of Cardiology, Department of Medicine and Clinical Science, Yamaguchi University Graduate School of Medicine, Ube, Japan, and [‡]Department of Cardiology, Ube-Kohsan Central Hospital, Ube, Japan.

Introduction

Delayed cardiac tamponade (DCT) is a rare (0.2%) complication of catheter ablation for atrial fibrillation (AF).¹ A previous worldwide survey showed that the occurrence of DCT ranged from 0.2 to 45 days (median 12 days) after catheter ablation. However, occurrence of DCT more than 3 months after the procedure is particularly rare.² Information regarding the time and mechanism of development of this complication remains unknown. Here, we present a patient who developed DCT as a complication 3 months after catheter ablation with subacute hemorrhage as the possible contributing factor.

Case report

A 66-year-old man was admitted to our facility to undergo catheter ablation for symptomatic paroxysmal AF. He had a history of diabetes mellitus and took oral hypoglycemic agents. He was also administered edoxaban 60 mg daily for primary prevention of thromboembolic events. The preprocedural transthoracic echocardiography (TTE) showed left ventricular ejection fraction of 64%, left atrial diameter of 40 mm, and left atrial volume of 63 mL. After transesophageal echocardiography ruled out an intracardiac thrombus, he received pulmonary vein isolation (PVI), superior vena cava isolation (SVCI), and cavotricuspid isthmus (CTI) ablation. On the day of the procedure, edoxaban was switched to dabigatran 350 mg daily. PVI was performed using a 3.5 mm open-irrigated tip ablation catheter (Thermocool SF; Biosense Webster, Diamond Bar, CA) with the guidance of an electroanatomical mapping system (CARTO3; Biosense

KEY TEACHING POINTS

- This is the first case to demonstrate delayed cardiac tamponade (DCT) that developed 3 months after catheter ablation and was induced by subacute hemorrhage.
- High hemoglobin concentration and aggregation of hemosiderin-laden macrophages in pericardial effusion indicated subacute hemorrhage.
- This report highlights that patients who undergo catheter ablation for atrial fibrillation can develop DCT in the chronic phase during completion of ablation-induced scar formation, even if pericardial effusion is not detected in the periprocedural period or even 1 month after the procedure.
- Early awareness of symptomatic changes can help manage patients before development of hemodynamic collapse.

Webster). Total time of ablation attempts was 30, 20, 16, and 20 minutes for right PVI, left PVI, SVCI, and CTI ablations, respectively. The radiofrequency power in the right PVI was 30 W for the roof, bottom, and posterior segments, and 40 W for the anterior segment. The power in the left PVI was 30 W for the roof and bottom segments, 40 W for the anterior segment, and 25 W for the posterior segment. The power in SVCI was 20 W. The power in CTI ablation was 35 and 30 W for the tricuspid and inferior vena cava side, respectively. The mean contact force (CF) in the right PVI was 8 ± 2 g, 17 ± 6 g, 10 ± 5 g, and 19 ± 10 g for the roof, anterior, bottom, and posterior segments, respectively. The CF in the left PVI was 18 ± 7 g, 12 ± 8 g, 15 ± 5 g,

KEYWORDS Atrial fibrillation; Catheter ablation; Delayed cardiac tamponade; Hemosiderin-laden macrophage; Pulmonary vein isolation (Heart Rhythm Case Reports 2020;6:419–422)

Address reprint requests and correspondence: Dr Hironori Ishiguchi, Division of Cardiology, Shimane Prefectural Central Hospital, 4-1-1 Himebara, Izumo, Shimane 693-8555, Japan. E-mail address: nilebros@gmail.com.

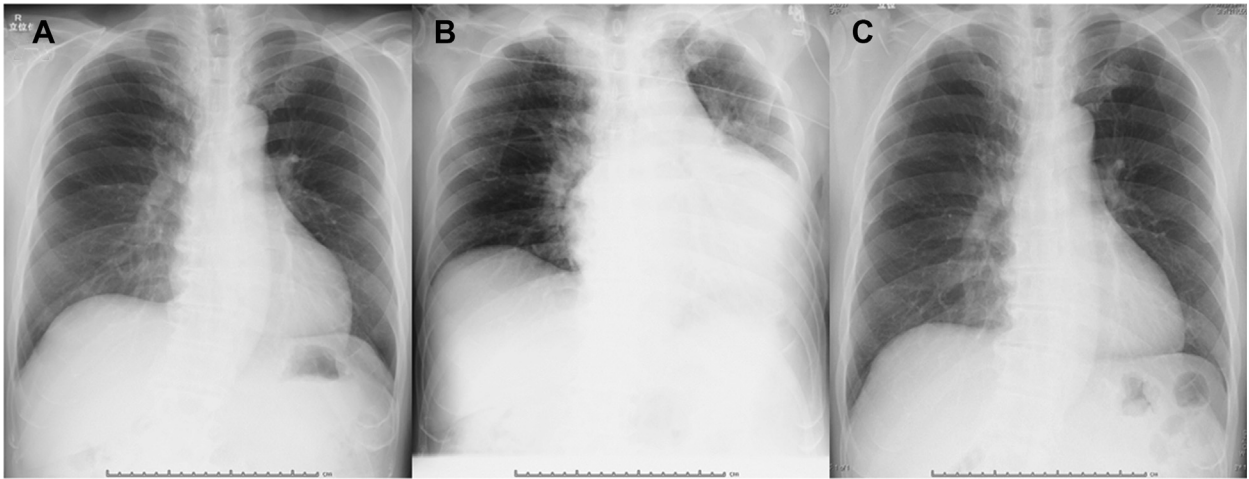


Figure 1 A, B: Chest radiographs taken 29 days (A) and 95 days (B) after the procedure. C: Chest radiograph taken 1 month after pericardiocentesis.

and 22 ± 12 g for the roof, anterior, bottom, and posterior segments, respectively. The CF in SVCI and CTI ablations were 14 ± 5 g and 13 ± 11 g, respectively. The procedure was completed uneventfully. Doubtful findings for perforation such as excessive CF and decreasing fluoroscopic cardiac silhouette excursion were not detected. No audible pop was identified during the procedure. No pericardial effusion was detected by intraprocedural and postprocedural intracardiac echocardiography. He was discharged 2 days after the procedure and continued anticoagulation therapy using edoxaban. Twenty-nine days after the procedure, he had no recurrence of arrhythmia, and the chest radiograph showed normal width of the cardiac silhouette (Figure 1A). Although he had been progressing satisfactorily in ambulatory care, 90 days after the procedure, he required an unscheduled visit to our facility for sudden chest discomfort. He had no traumatic episodes leading up to this episode. Auscultation indicated no friction rub and normal heart sounds. The electrocardiograph showed normal sinus rhythm with no significant ST-T change. The blood analysis showed within normal ranges of C-reactive protein (0.14 mg/dL), creatinine kinase (111 IU/L), and creatinine kinase-MB (11 IU/L), and a negative high-sensitive troponin I (less than 10 pg/mL). The TTE showed pericardial effusion of a maximum of 17 mm at the posterior side of the left ventricle and 11 mm at the anterior side of the right ventricle at end-diastole (Figure 2A). The M-mode echocardiographic assessment at the apical 4-chamber view showed collapse of the right atrium at both systole and diastole (Figure 2B). For further assessment, he was scheduled to receive a cardiac computed tomography (CCT) scan 5 days later. Immediately after the CCT, he complained of exacerbation of chest pain and developed dyspnea. His vital signs showed a blood pressure of 90/54 mm Hg, pulse rate of 154 beats per minute of irregular (AF) rhythm, respiratory rate of 26 breaths per minute, and an SpO₂ of 98% at room air. The chest radiograph showed enlargement of the cardiac silhouette (Figure 1B). The CCT scan revealed that pericardial effusion had increased to 25–30 mm around the left atrium and ventricle (Figure 2C and D) compared to 5

days before. The blood analysis showed a positive result for high-sensitive troponin I (29.9 pg/L), and that the serum hemoglobin concentration had dropped from 11.8 g/dL (5 days before) to 9.8 g/dL. Urgent pericardiocentesis was performed, and 600 mL of effusion was collected. Drainage of the effusion was smooth, and no clot was obtained. The effusion appeared bloody (Figure 3A), with a hemoglobin concentration of 14.1 g/dL. A smear revealed aggregated macrophages containing hemosiderin (hemosiderin-laden macrophages), indicating recent hemorrhage (Figure 3B, right; arrows: macrophage, asterisks: hemosiderin). Based on the aforementioned findings, we diagnosed the patient as having DCT developed owing to subacute hemorrhage. After patient admission, we continued pericardial drainage and stopped anticoagulation therapy. Although 300 mL of effusion was obtained from the indwelling catheter at the pericardium on the second hospital day, the hemoglobin concentration of the effusion was drastically decreased to 3.1 g/dL. On the third hospital day, the catheter was removed because no further effusion was observed. He took acetaminophen 400 mg on 2 occasions (the first and fourth hospital days) for relieving pain of the drainage wound. After catheter removal, his symptoms completely resolved, and no effusion was observed by TTE. On the fourth hospital day, AF spontaneously returned to sinus rhythm. He resumed taking edoxaban and was discharged on the ninth hospital day. One month later, his chest radiograph showed complete recovery of the size of the cardiac silhouette (Figure 1C). He followed an uneventful clinical course during the subsequent 4 months of follow-up.

Discussion

DCT is defined as a tamponade, which occurs more than 1 hour after catheter ablation.¹ When reviewing previous cases where DCT developed within 2 months after the procedure, researchers speculated that the mechanisms behind the complication might be ablation-induced sealed myocardial injury, intense anticoagulation therapy, or subacute

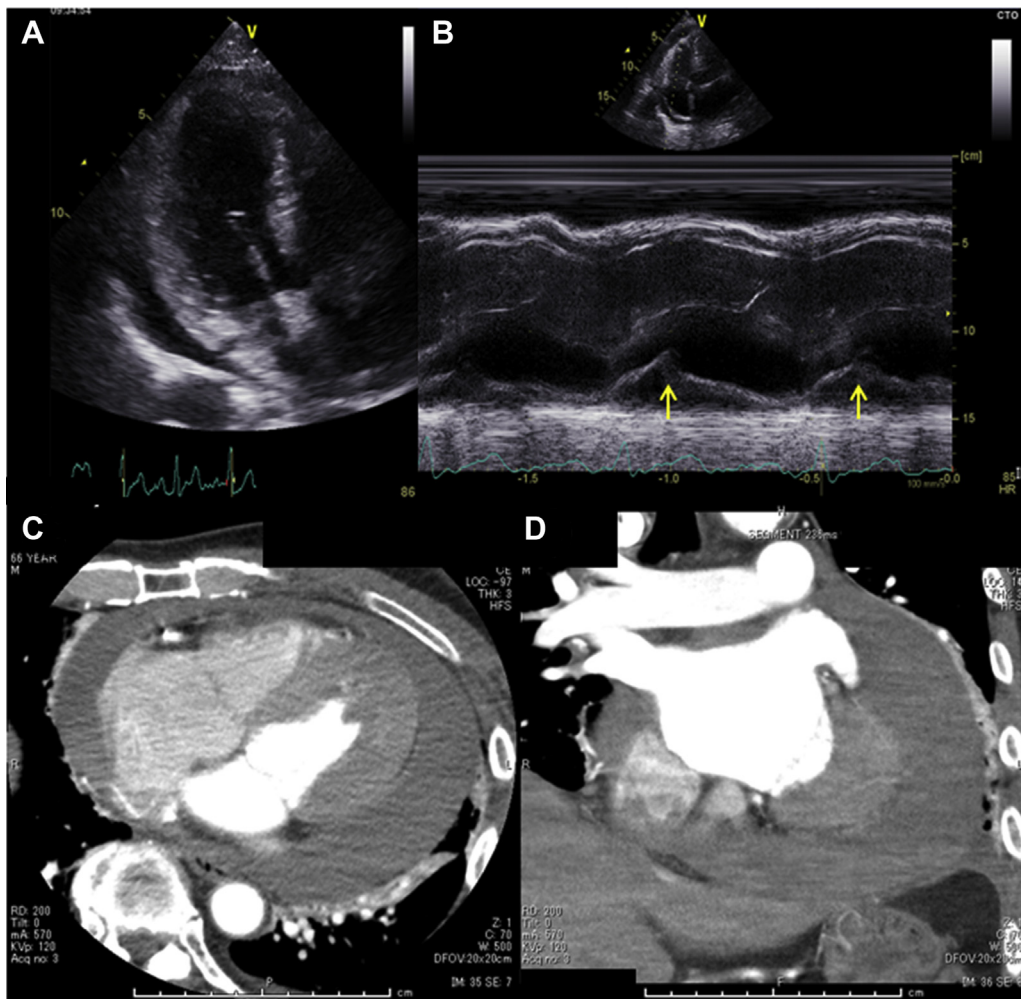


Figure 2 **A:** The apical 3-chamber view of transthoracic echocardiography (TTE) at end-diastole showing pericardial effusion of maximum 17 mm at the posterior side of the left ventricle. **B:** The M-mode TTE assessment at apical 4-chamber view showing collapse of right atrium (arrows). **C, D:** The axial (**C**) and coronal (**D**) views of cardiac computed tomography scan showing pericardial effusion of 25–30 mm around the left atrium and ventricle.

pericarditis following pericardial hemorrhage.^{3–5} However, clinicians are still uncertain regarding whether the mechanism could be extrapolated to cases of DCT that developed more than 3 months after the procedure, because ablation-induced scar formation is usually completed within 3 months.⁶ Yamanaka and colleagues² described a 55-year-old man who developed DCT 8 months after PVI without anticoagulant administration. However, when the patient in this case developed DCT is unknown, because assessments by imaging modalities, such as chest radiograph and echocardiography, were not performed until the onset of symptoms. Furthermore, the hemoglobin concentration of the pericardial effusion was low (4.4 g/dL). In contrast, our case demonstrated no enlargement of the cardiac silhouette 1 month after the procedure, suggesting that the pericardial effusion might not have accumulated at that point. In addition, pericardial effusion showed a high concentration of hemoglobin (14.1 g/dL) and aggregating hemosiderin-laden macrophages. Hemosiderin-laden macrophages are commonly detected from bronchoalveolar lavage fluid in patients with diffuse alveolar hemorrhage, providing evidence of a subacute

hemorrhage.⁷ An in vitro experimental model of human alveolar macrophages revealed that hemosiderin-laden macrophages appeared 50 hours after the onset of hemorrhage, peaked at 7 days, and disappeared within 2–4 weeks.⁷ We presume that the pericardial effusion was accumulated by a subacute hemorrhage; however, the significance of hemosiderin-laden macrophages in the pericardium remains unexplained owing to the paucity of previous literature. We also postulated that the origin of hemorrhage might be the posterior side of left atrium owing to the following findings. At first, the mean CF was relatively high in the posterior side of the bilateral pulmonary vein where the myocardial wall was thin. Second, the effusion predominantly accumulated around the left atrium and ventricle when the increase in the effusion occurred. However, suspicious findings indicating perforation could not be detected by CCT.

The patient in our case took 5 days from the onset of symptoms to develop hemodynamic collapse, which indicated that the speed of blood accumulation in the pericardium was relatively slow. This suggests that early awareness of symptomatic change could allow us to

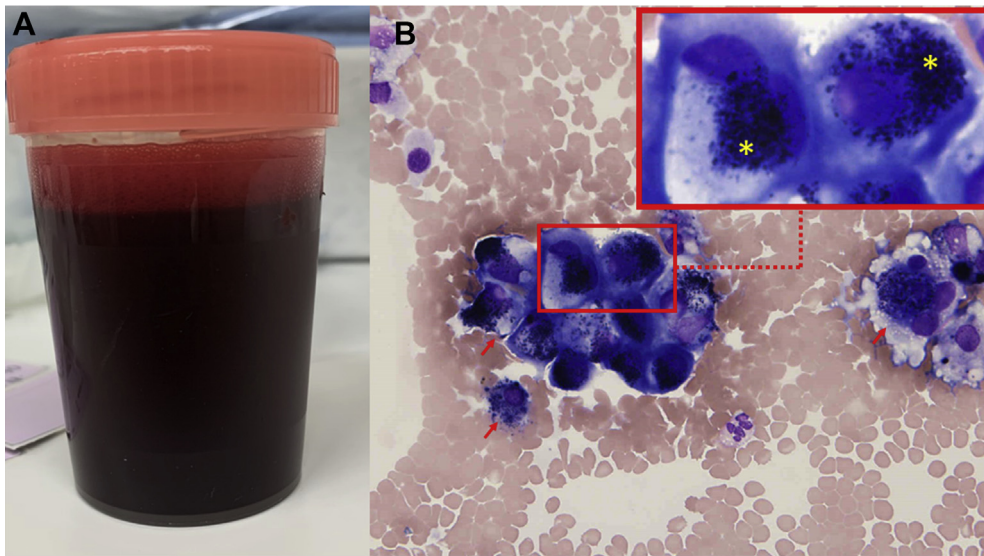


Figure 3 A: Bloody pericardial effusion. B: The smear of pericardial effusion showing many macrophages containing hemosiderin (hemosiderin-laden macrophages), suggesting subacute hemorrhage (arrows, hemosiderin-laden macrophages; asterisks, hemosiderin).

manage patients (eg, assessment using imaging modalities, early pericardiocentesis, and hospitalization) before they developed hemodynamic collapse. However, the course of the development of DCT in patients after more than 3 months remains to be elucidated because these cases are extremely rare. We also underscore that the anticoagulant might be involved in the development or exacerbation of a subacute hemorrhage. There is a reported case of a patient developing DCT 55 days after catheter ablation, for which maintenance anticoagulation therapy of rivaroxaban was prescribed.³ Our case was exposed to both edoxaban and dabigatran during the periprocedural period. Although anticoagulation management may have contributed to the development of effusion, we could not clarify which agent was related to this effect. Furthermore, information regarding the relationship between anticoagulation therapy and DCT developing more than 3 months after catheter ablation remains unavailable and warrants further study from other similar cases.

Conclusion

Our case is the first to demonstrate the development of DCT 3 months after catheter ablation, which was induced by subacute hemorrhage based on the high hemoglobin concentration and aggregation of hemosiderin-laden macrophages in the pericardial effusion. This highlights that patients who underwent catheter ablation for AF can develop DCT in the chronic phase in which ablation-induced scar formation

was completed, even if pericardial effusion was not detected in the periprocedural period or even 1 month after the procedure. Our case also suggests that early awareness of symptomatic changes could allow us to manage patients before they develop hemodynamic collapse because the speed of blood accumulation in the pericardium is relatively slow (a few days).

Acknowledgments

The authors thank Editage (www.editage.jp) for English language editing.

References

1. Cappato R, Calkins H, Chen SA, et al. Delayed cardiac tamponade after radiofrequency catheter ablation of atrial fibrillation: a worldwide report. *J Am Coll Cardiol* 2011;58:2696–2697.
2. Yamanaka T, Fukatsu T, Kamon T, et al. Delayed cardiac tamponade 8 months after pulmonary vein isolation. *J Cardiol Cases* 2017;16:22–25.
3. Kitamura T, Fukamizu S, Sakurada H, Hiraoka M. Development of delayed cardiac tamponade 55 days after catheter ablation for atrial fibrillation with a new oral anticoagulant. *J Interv Card Electrophysiol* 2014;41:135.
4. Lambert T, Steinwender C, Leisch F, Hofmann R. Cardiac tamponade following pericarditis 18 days after catheter ablation of atrial fibrillation. *Clin Res Cardiol* 2010;99:595–597.
5. Torihashi S, Shiraishi H, Hamaoka T, et al. Two cases of delayed cardiac tamponade due to pericarditis after pulmonary vein (PV) isolation for atrial fibrillation. *Intern Med* 2015;54:791–796.
6. Badger TJ, Oakes RS, Daccarett M, et al. Temporal left atrial lesion formation after ablation of atrial fibrillation. *Heart Rhythm* 2009;6:161–168.
7. Sherman JM, Winnie G, Thomassen MJ, Abdul-Karim FW, Boat TF. Time course of hemosiderin production and clearance by human pulmonary macrophages. *Chest* 1984;86:409–411.