



Contents lists available at ScienceDirect

## International Journal of Surgery Case Reports

journal homepage: [www.casereports.com](http://www.casereports.com)

# Management of a jejunal obstruction caused by the migration of a laparoscopic adjustable gastric banding. A case report



Julien Lemaire<sup>a,\*</sup>, Olivier Dewit<sup>b</sup>, Benoît Navez<sup>c</sup>

<sup>a</sup> Department of Abdominal Surgery, CHU Ucl Namur, University of Louvain, B-5530, Yvoir, Belgium

<sup>b</sup> Department of Hepato-Gastro-Enterology, Cliniques Universitaires Saint-Luc, University of Louvain, B-1200, Woluwe-Saint-Lambert, Belgium

<sup>c</sup> Department of Abdominal and Transplantation Surgery, Cliniques Universitaires Saint-Luc, University of Louvain, B-1200, Woluwe-Saint-Lambert, Belgium

## ARTICLE INFO

## Article history:

Received 17 August 2016

Received in revised form

16 November 2016

Accepted 17 November 2016

Available online 19 November 2016

## Keywords:

Bariatric surgery

Laparoscopic adjustable gastric banding

Band migration

Small bowel obstruction

## ABSTRACT

**INTRODUCTION:** We present a rare case of jejunal obstruction due to the migration of a laparoscopic adjustable gastric band (LAGB) that occurred 10 years after surgery and was successfully treated by laparoscopy. This report is compliant with the SCARE guidelines.

**PRESENTATION OF CASE:** A 42-year-old woman who underwent LAGB for morbid obesity 10 years ago was admitted with a small bowel obstruction due to the migration of a LAGB in the proximal small bowel. An attempt to endoscopic removal was unsuccessful and resulted in a laparoscopic extraction of the band. The post-operative course was uneventful.

**DISCUSSION:** Formerly, LAGB was considered the safest technique in bariatric surgery. However, the rate of complication increases in long-term studies. When the IGM of the band is diagnosed, removal is the only issue. Small bowel obstruction caused by a migrated band appears to be a rare complication following IGM, and the only therapeutic option is surgery because an endoscopic procedure is not reliable. Furthermore, LAGB appears to be a less effective technique for weight loss than the sleeve gastrectomy and the gastric bypass.

**CONCLUSION:** Small bowel obstruction caused by LAGB migration is a rare but serious complication following IGM. In such cases, endoscopy has to be avoided because of the risk of jejunal disruption. The only way to treat it properly is surgery. This type of late complication reinforces the interest in the techniques currently used in bariatric surgery such as sleeve gastrectomy and gastric bypass, providing also a better weight loss than the LAGB.

© 2016 The Authors. Published by Elsevier Ltd on behalf of IJS Publishing Group Ltd. This is an open access article under the CC BY-NC-ND license (<http://creativecommons.org/licenses/by-nc-nd/4.0/>).

## 1. Introduction

In the 90s, laparoscopic adjustable gastric banding (LAGB) became the most popular bariatric procedure in Europe, producing effective results in terms of weight loss [1,2]. However, in the long-term studies on LAGB, an overall complication rate of up to 34% has been reported [3]. Among these complications, the rate of intragastric migration (IGM) of the band is estimated to range between 0.3 and 11.1% [4,5]. This complication usually occurs during the first three years after surgery [5].

The diagnosis of IGM of the band must lead to the removal of the material [4].

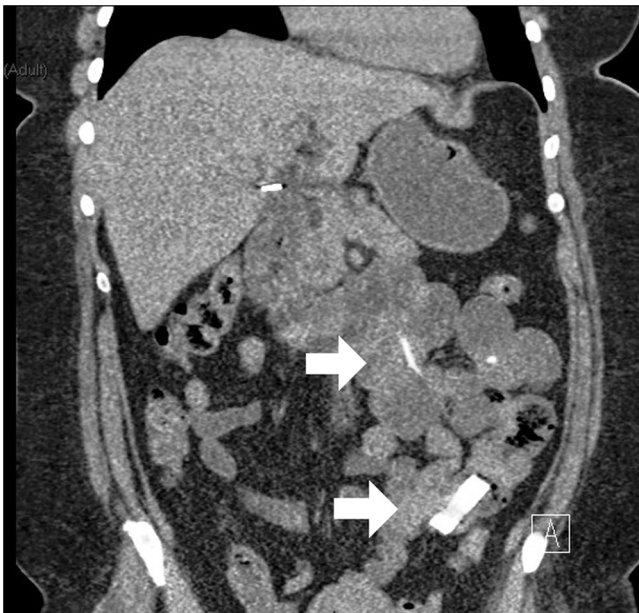This case report is compliant with the SCARE guidelines [6].

## 2. Presentation of case

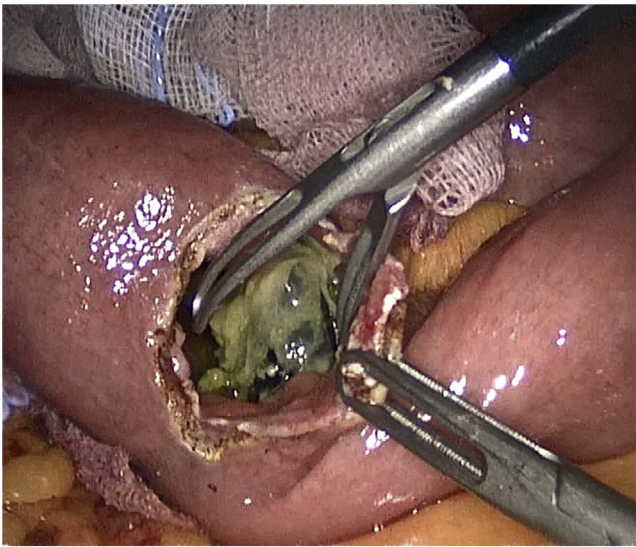
Here, we describe the case of a 42-year-old woman who underwent an LAGB procedure for morbid obesity in another institution 10 years ago. BMI at that time was not available. There were no other co-morbidities. Medical history mentioned a nervous breakdown. Symptoms of dyspepsia and weight regain four years after the surgery led to the diagnosis of IGM of the band. The material was not removed at the time.

The patient was admitted for acute abdominal pain located in the left flank, nausea, vomiting and ileus. The weight on admission was 115 kg for a height of 174 cm and a BMI of 38. The clinical examination revealed a mild distension of the abdomen, a pain in the left flank but no peritoneal signs. The blood sample showed an inflammatory syndrome with a CRP of 3.2 mg/dl and a white-blood cell count of 16940 / $\mu$ L (87% of neutrophils). LDH levels were normal. There were no biological signs of dehydration. The abdominal CT showed an obstruction of the upper gastrointestinal tract due to an intra-jejunal location of the LAGB, without intra-abdominal fluid. The jejunum distal to the band was flat (Fig. 1). We unsuccessfully tried to remove the band under upper endoscopy. Surgical

\* Corresponding author at: Department of Abdominal Surgery, CHU Ucl Namur, Université Catholique de Louvain, Avenue Gaston Thérèse 1, 5530 Yvoir, Belgium.  
E-mail address: [lemaire.julien@yahoo.fr](mailto:lemaire.julien@yahoo.fr) (J. Lemaire).

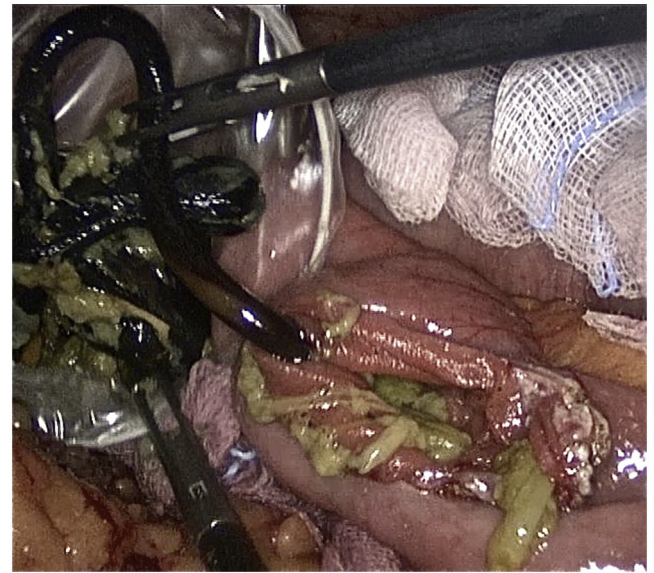


**Fig. 1.** Abdominal CT showing the intrajejunal location of the band. The superior arrow shows the connecting tube while the lower arrow shows the banding.



**Fig. 2.** and 3: Peroperative picture showing the removal of the band by laparoscopic jejunotomy.

exploration was required. Laparoscopy revealed three proximal dilated small bowel loops. There were multiple adhesions between the stomach wall, the greater omentum and the abdominal wall. The LAGB location was identified by following the dilated loops from the duodeno-jejunal junction. There were no signs of bowel ischemia or perforation. The connecting tube was cut off at its entry into the abdominal cavity. The band and the connecting tube were removed by transversal jejunotomy after two bowel clamps had been placed above and below the site of enterotomy to avoid abdominal contamination (Figs. 2 and 3). The jejunal incision was closed transversally with a running suture of PDS 2/0. The port-chamber was also removed during the procedure. The patient was discharged one week after admission and is free of symptoms.



**Fig. 3.** Peroperative picture showing the removal of the band by laparoscopic jejunotomy.

### 3. Discussion

LAGB has been considered the safest and least invasive technique in bariatric surgery, as it is reversible and has a low complication rate [1,2,5]. However, long-term experience of this procedure demonstrates an overall complication rate of up to 34%; 18% of those complications are directly related to the band itself. Recent studies have shown a rate of gastric erosion and IGM of 0.3–5% [1–5,7]. Rates of IGM up to 11% reported in some series seemed to be linked to an overfilling of the banding [4]. Other technical aspects may modify the rate of IGM. The two classical techniques are the perigastric and the pars flaccida approach. The first one involves a dissection of the lesser curvature close to the stomach wall. The second approach entails opening the pars flaccida of the lesser omentum, followed by the opening of the peritoneal sheet at the bottom of the right diaphragmatic crus, proceeding along the left crus to the gastrophrenic ligament to create a passage between the diaphragmatic pillars and the gastroesophageal junction. The dissection is less close to the stomach wall than in the perigastric approach. The pars flaccida approach could actually minimize the risk of erosion and IGM by avoiding possible microtraumas to the gastric wall which can occur during the perigastric approach [4,7], but these considerations are not clearly demonstrated in the literature. In addition, some authors have described a higher migration rate when using the Lapband® device (Lapband®, Allergan/Inamed, Santa Barbara, CA, USA, developed by Kuzmak), arguing that erosion is the result of a higher pressure applied to the stomach [8]. Usually, the Lapband® is indicated in both approaches, while the SAGB® (Swedish Adjustable gastric Banding, Obtech, Ethicon Endosurgery, Stockholm, Sweden, developed by Hallberg and Forsell) is most often used in the pars flaccida approach.

The diagnosis of IGM is generally made during the first three years of follow-up [5]. In the vast majority of cases, the symptoms of IGM are weight regain or epigastric pain, nausea, vomiting and sometimes signs of port-chamber site infection [7]. The diagnosis is generally confirmed by upper endoscopy which allows one to assess the stage of migration. Stage I corresponds to a small part of the band being visible in the gastric lumen, stage II to a partial migration with more than half of the band being visible in the gas-

tric lumen while stage III corresponds to a complete migration of the band and connecting tube into the stomach [4].

Whatever the stage, the implanted material must be removed because of the risk of more severe complications. The choice between either endoscopy and laparoscopy depends on the stage of migration [5]. In the case of an asymptomatic patient, some authors recommend waiting for a full migration of the band into the stomach, facilitating the endoscopic removal of the band [4,9].

The endoscopic and intraluminal approach is elegant, but unfortunately rarely successful due to the lack of appropriate endoscopic instruments [2,10].

Small bowel obstruction related to band migration is very rare. Five similar cases have been identified in the literature [9,11–13], three of them leading to jejunal pressure necrosis [8,9,11]. In these five cases, two authors attempted endoscopic removal of the band [8,9], but it was unsuccessful. They concluded that the endoscopic approach must be considered in cases of intragastric location of the band [9,11]. The passage beyond the pylorus makes the endoscopic removal hazardous because of possible jejunal pressure ulcers and the risk of perforation [9,11]. All cases required surgical exploration, two of them by laparoscopic approach [8,9]. One of these two cases was converted because of multiple jejunal ulcers [9]. The other case was completed laparoscopically despite the existence of a walled-off perforation of the jejunum, closed by jejunorrhaphy [8]. Some authors suggested an intraoperative methylene blue-dye test to exclude any residual gastric leakage [8,9]. The post-operative course in all those cases was uneventful.

Another important point in bariatric surgery remains the weight loss and the improvement of comorbidities. Recent series tend to show better results with a sleeve gastrectomy or a gastric bypass, with an acceptable rate of complications compared to LAGB [14].

#### 4. Conclusion

Small bowel obstruction related to band migration is a rare but serious situation. This is the reason why in cases of complete IGM, the band has to be removed rapidly. In cases of small bowel obstruction, endoscopic removal is not recommended because of the risk of jejunal disruption and possible perforation [8,9,11]. This is why a surgical approach has to be considered. A laparoscopic procedure adhering to the same safety rules as those applying to open surgery is a good option, because intestinal distension involves only the proximal jejunum. Anyway, once IGM has been diagnosed, removal of the LAGB is the only therapeutic option.

Also, the endpoint of an effective bariatric procedure is a greater weight loss and a better improvement of comorbidities with an acceptable rate of late complications. All these elements invite to question the use of LAGB in current bariatric practice.

#### Conflict of interest disclosure statement

Julien Lemaire, Olivier Dewit and Benoît Navez have no conflicts of interest to declare.

#### Sources of funding

This research did not receive any specific funding.

#### Ethical approval

Not necessary for case reports in our hospital.

#### Consent

Considering the use of entirely and anonymised images such as xrays and laparoscopic images without any identifying marks that could permit to identify the individual concerned and following the rules of Elsevier, no informed consent is attached.

#### Author contribution

Julien Lemaire did the literature review and drafted the manuscript. Benoît Navez et Oliver Dewit reviewed it and helped in the design. All authors read and approved the final manuscript.

#### Guarantor

Julien Lemaire.

#### References

- [1] Y. Van Nieuwenhove, W. Ceelen, A. Stockman, H. Vanommeslaeghe, E. Snoeck, K. Van Renterghem, et al., Long-term results of a prospective study on laparoscopic adjustable gastric banding for morbid obesity, *Obes. Surg.* 21 (2011) 582–587.
- [2] M. Naef, U. Naef, W.G. Mouton, H.E. Wagner, Outcome and complications after laparoscopic Swedish Adjustable Gastric Banding: 5-year results of a prospective clinical trial, *Obes. Surg.* 17 (2007) 195–201.
- [3] C. Boza, C. Gambao, G. Perez, F. Crovari, A. Escalona, F. Pimentel, et al., Laparoscopic adjustable gastric banding (LAGB): surgical results and 5-year follow-up, *Surg. Endosc.* 25 (2011) 292–297.
- [4] D. Nocca, V. Frering, B. Gallix, C. de Seguin des Hons, P. Noël, M.A. Pierredon Foulonge, et al., Migration of adjustable gastric banding from a cohort study of 4236 patients, *Surg. Endosc.* 19 (2005) 947–950.
- [5] J.M. Chevallier, F. Zinzindohoué, R. Douard, J.P. Blanche, J.L. Berta, J.J. Altman, et al., Complications after laparoscopic adjustable gastric banding for morbid obesity: experience with 1000 patients over 7 years, *Obes. Surg.* 14 (2004) 407–414.
- [6] R.A. Agha, A.J. Fowler, A. Saetta, I. Barai, S. Rajmohan, D.P. Orgill, for the SCARE group the SCARE statement: consensus-based surgical case report guidelines, *Int. J. Surg.* (2016) (in press).
- [7] C. Owers, R. Ackroyd, A study examining the complications associated with gastric banding, *Obes. Surg.* 23 (2013) 56–59.
- [8] M. Bueter, A. Thalheimer, D. Meyer, M. Fein, Band erosion and passage, causing small bowel obstruction, *Obes. Surg.* 16 (2006) 1679–1682.
- [9] L. Lantsberg, B. Kirshtein, A. Leytzin, V. Makarov, Jejunal obstruction caused by migrated gastric band, *Obes. Surg.* 18 (2008) 225–227.
- [10] C. Meyenberger, C. Gubler, P.M. Hengstler, Endoscopic management of a penetrated gastric band, *Gastrointest. Endosc.* 60 (2004) 480–481.
- [11] D.M. Edgebaere, A.F. Myers, R.J. Lawrance, Small bowel obstruction secondary to intragastric erosion and migration of a gastric band, *J. Gastrointest. Surg.* 12 (2008) 983–984.
- [12] K.G. Shah, E.P. Molmenti, J. Nicastro, Gastric band erosion and intraluminal migration leading to biliary and small bowel obstruction: case report and discussion, *Surg. Obes. Relat. Dis.* 7 (2011) 117–118.
- [13] M. Taskin, K. Zengin, E. Unal, Intraluminal duodenal obstruction by a gastric band following erosion, *Obes. Surg.* 11 (2001) 90–92.
- [14] J.L. Colquitt, K. Pickett, E. Loveman, G.K. Frampton, Surgery for weight loss in adults, *Cochrane Database Syst. Rev.* 8 (2014) CD003641, <http://dx.doi.org/10.1002/14651858.cd003641.pub4>.

#### Open Access

This article is published Open Access at [scimedirect.com](http://scimedirect.com). It is distributed under the [IJSCR Supplemental terms and conditions](#), which permits unrestricted non commercial use, distribution, and reproduction in any medium, provided the original authors and source are credited.