

# Posterior cardiac compression from a large hiatal hernia—A novel cause of ventricular tachycardia



Sonali R. Gnanenthiran, MBBS, FRACP,\* Christopher Naoum, MBBS, FRACP, PhD,\*  
Michael J. Kilborn, MBBS, FRACP, PhD, FHRS,†  
John Yiannikas, MBBS, FCCF, FACC, FESC, FCSANZ, FRACP\*

From the \*Department of Cardiology, Concord Repatriation General Hospital, Sydney, Australia, and  
†Department of Cardiology, Royal Prince Alfred Hospital, Sydney, Australia.

## Introduction

Large hiatal hernia (HH) can cause extensive posterior cardiac compression, including frequent compression of the basal inferior left ventricular (LV) wall, with such changes resolving post HH repair. We present the first case of ventricular tachycardia (VT) associated with HH-induced compression.

## Case report

A 78-year-old man with diabetes, hypertension, and recurrent dizziness presented with syncope in 2008. His cardiac monitoring demonstrated paroxysmal episodes of VT. His electrocardiogram demonstrated monomorphic VT with positive precordial QRS concordance, atypical right bundle branch block pattern, and inferior axis (Figure 1). The electrocardiogram was consistent with a basal LV origin, either from the aortomitral continuity, as suggested by the qR complex in V1, or in the nearby basal left septal/para-Hisian region, as suggested by positive aVL and the QRS ratio of lead II to lead III being greater than lead I. He was treated with lidocaine infusion and later oral sotalol. LV ejection fraction was normal with no regional wall motion abnormalities. Coronary angiography demonstrated a small distal right coronary artery 70% stenosis, which was treated with balloon angioplasty despite the absence of ischemic symptoms.

Electrophysiology study (EPS) demonstrated a spontaneous repetitive monomorphic pattern of VT with the same morphology as the clinical VT and with ventricular-atrial dissociation. Burst right ventricular pacing was able to initiate the VT, suggesting that triggered activity may

play a role in its mechanism. The VT was not induced with programmed stimulation, suggesting a nonentrant mechanism. A supraventricular tachycardia, atrioventricular junctional reentrant tachycardia, was also induced. The atrioventricular junctional reentrant tachycardia was ablated at the slow pathway. Only limited activation and pace mapping was performed owing to poor patient tolerance and technical difficulties, including tortuosity of iliac arteries and abdominal aorta preventing retrograde aortic access to the left ventricle or coronary cusps. This limited VT mapping suggested that earliest activation occurred in the anterior aortomitral continuity region, but we suspect there may have been an area of the basal left septum that was not reached by the catheter. Catheter ablation was attempted at sites of earliest activation, although pace mapping did not elicit perfect QRS matches to the tachycardia. Owing to poor patient tolerance, the procedure was eventually abandoned, with incomplete VT ablation.

Repeat EPS under general anesthesia 1 day later and 2 weeks later could not induce VT despite isoproterenol and adrenaline infusion, and reduction in sedation. The patient subsequently had further sustained VT requiring lidocaine infusion. A fourth EPS again could not induce VT, and mexiletine was commenced.

He continued to have multiple admissions for presyncope, with frequent nonsustained and sustained VT. Again, repeat EPS demonstrated no inducible VT despite programmed extrastimulation, burst pacing, and isoproterenol infusion. A defibrillator (implantable cardioverter-defibrillator) was implanted. Mexiletine dosing was increased, but this medication was later changed to amiodarone owing to poor tolerance and ongoing arrhythmia. However, VT persisted despite amiodarone 200 mg daily for 5 years.

Importantly, the patient also had a 10-year history of severe postprandial gastroesophageal reflux and exertional dyspnea, subsequently diagnosed in 2014 to be caused by a large HH. Echocardiography demonstrated severe extrinsic left atrial (LA) compression and basal inferior LV wall dyskinesia (Figure 2; Supplemental Videos 1 and 2).

**KEYWORDS** Arrhythmia; Compression; Hiatal hernia; Syncope; Ventricular tachycardia  
(Heart Rhythm Case Reports 2018;4:362–366)

**Address reprint requests and correspondence:** Dr John Yiannikas, Concord Hospital, Hospital Rd, Concord West, 2139 NSW, Australia. E-mail address: [john.yiannikas@sydney.edu.au](mailto:john.yiannikas@sydney.edu.au).

**KEY TEACHING POINTS**

- Large hiatal hernia can cause extensive posterior cardiac compression including frequent compression of the basal inferior left ventricular wall, with such changes resolving post hernia repair.
- The implications of hiatal hernia–induced cardiac distortion on arrhythmia pathogenesis are poorly recognized.
- Atrial arrhythmias have been described, which are likely attributable to left atrial compression.
- Hiatal hernia–induced posterior cardiac compression and associated mitral annular region distortion seems to have caused a propensity to frequent symptomatic ventricular tachycardia (VT) in our case, with postoperative resolution of compression correlating with VT resolution.
- Early recognition of this association with arrhythmogenesis is imperative, as hiatal hernia may be a treatable cause of such arrhythmias.

He proceeded to laparoscopic HH repair, where the mediastinal sac contained >75% of his stomach with associated volvulus. Postoperatively, there was echocardiographic resolution of LA compression and LV dyskinesia ([Supplemental Video 3](#)) and improved performance on stress echocardiography (10 versus 5 minutes). His episodes of presyncope and VT also ceased after HH repair. Three years later, there has been no further VT on implantable cardioverter-defibrillator checks, and all antiarrhythmic therapy has now been ceased for 2 years ([Supplemental Figures 1 and 2](#)).

**Discussion**

Large HH, containing >30% of the stomach intrathoracically, can have important hemodynamic effects on cardiac function. Dyspnea and exercise impairment are common, likely arising from compression of the LA, which is anatomically adjacent to an enlarging hernia.<sup>1</sup> Computed tomography and magnetic resonance imaging studies have confirmed that these hernias compress other inflow structures, including the inferior pulmonary veins, coronary sinus along the atrioventricular groove, and, often, the basal posterior LV wall, as seen in the aforementioned patient.<sup>1,2</sup> The obstructive effects of these hernias are further exacerbated by feeding and the Valsalva maneuver.<sup>2,3</sup> This dynamic nature of cardiac compression has been demonstrated on cardiac magnetic resonance imaging, with feeding inducing an increase in hernia size and reduction in LA volumes.<sup>2</sup>

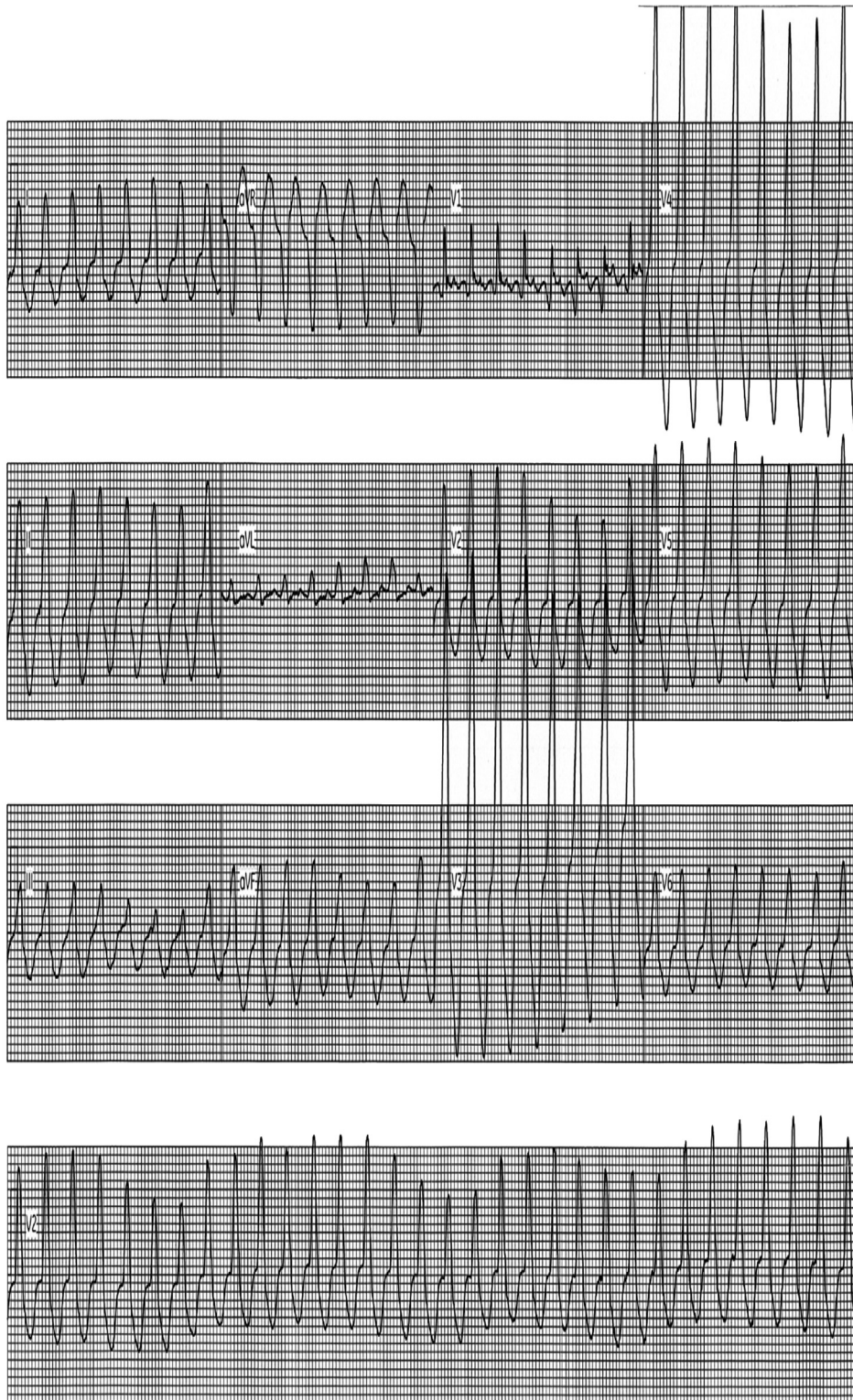
This is particularly relevant in our case, as the EPSs were performed fasting, which may have contributed to the noninducibility of the VT.

The implications of HH-induced cardiac distortion on arrhythmia pathogenesis are poorly recognized. Atrial arrhythmias have been described, which are likely attributable to LA compression. A large observational study demonstrated that there is a higher prevalence of atrial fibrillation (AF) at all ages with HH compared to the general population, with a higher magnitude of difference in those aged <55 years despite a reduced prevalence of AF risk factors (17.5-fold higher in men and 19-fold higher in women compared with an age- and gender-matched population).<sup>4</sup> Moreover, patients with more frequent gastroesophageal reflux symptoms and/or esophagitis seem to have an increased risk of AF.<sup>5</sup> Similarly, there have been case reports of atrial flutter,<sup>6</sup> junctional bradycardias,<sup>7</sup> anterior T-wave inversion,<sup>8</sup> and ST elevation that have resolved post hernia repair or even after initiation of anti-reflux therapy.<sup>9,10</sup>

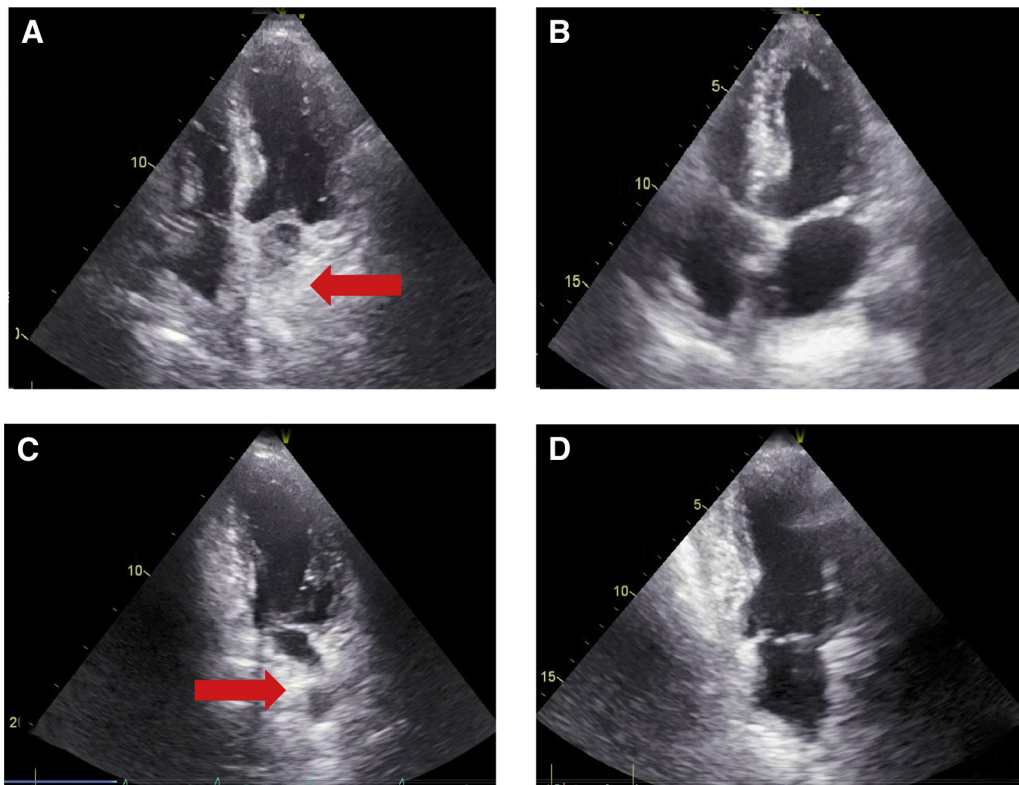
In our case, we postulate that hernia-induced cardiac compression resulted in distortion of the mitral annular ring, which is a continuous fibrous ring adjacent to the basal structures of the left ventricle including the aortomitral continuity ([Figure 3](#)). This appears to have aggravated the propensity to VT, with the postoperative resolution of this compression correlating with resolution of the VT. While mechanical compression is likely to be the main mechanism of VT, gastroesophageal reflux may also contribute to arrhythmias by releasing local and systemic cytokines and thus resulting in local heat and myocardial inflammation.<sup>5,11</sup> Additionally, there may be associated sympathetic nerve and vagal nerve stimulation through either local heat or compression, which may further induce and perpetuate arrhythmogenesis. We speculate that these factors create a proarrhythmic environment that may induce abnormal automaticity and triggered activity, and thus produce VT. This nonreentrant mechanism is consistent with the initial EPS, in which VT was not induced with programmed stimulation. In particular, triggered activity is likely to be a key process in the VT pathogenesis, as burst right ventricular pacing was able to initiate the VT.

**Conclusion**

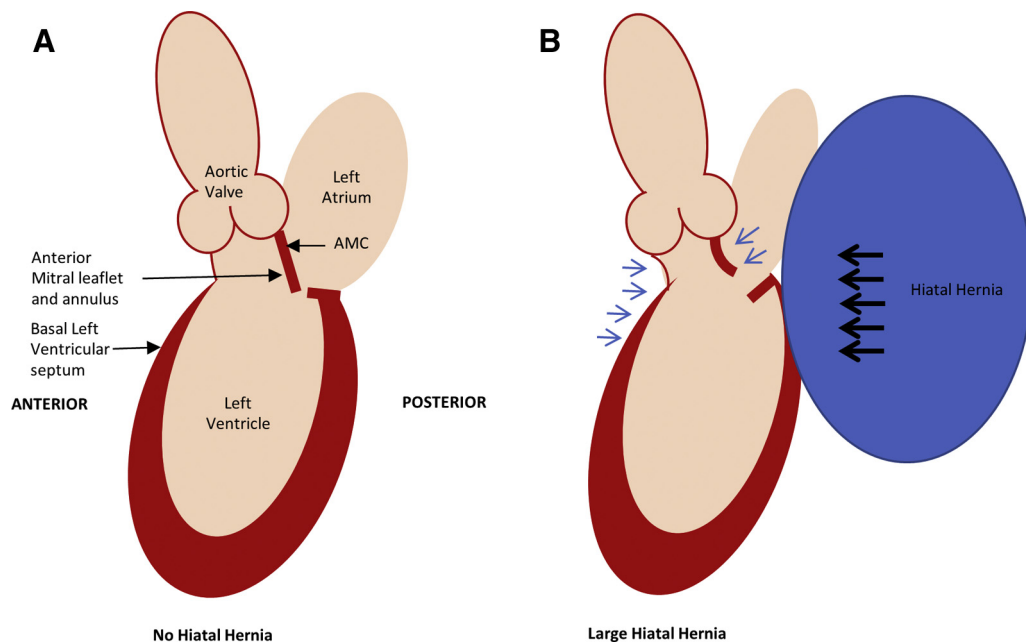
The compressive effect of hiatal hernias and their arrhythmogenic potential are often not recognized clinically, which can profoundly impact upon patient care. In our case, hernia-induced posterior cardiac compression and associated mitral annular region distortion seems to have caused a propensity to frequent symptomatic VT, with postoperative resolution of compression correlating with VT resolution. To our knowledge, this is the first case of HH-associated VT to be reported. Early recognition of this association with arrhythmogenesis is thus imperative, as our case demonstrates that HH may be a treatable cause of such arrhythmias.



**Figure 1** Electrocardiogram: ventricular tachycardia.



**Figure 2** Transthoracic echocardiography: 4-chamber and 2-chamber views, preoperative (A, B) and postoperative (C, D). Preoperative views demonstrating left atrial compression (red arrow) and dyskinesia of the basal inferior left ventricular wall on resting echocardiography, with such changes resolving post hernia repair.



**Figure 3** Proposed mechanism of ventricular tachycardia (VT) secondary to posterior cardiac compression from a large hiatal hernia (long axis view). **A:** The mitral annulus is a saddle-shaped continuous fibrous ring that is adjacent to the aortomitral continuity (AMC). **B:** Direct posterior cardiac compression from the hiatal hernia (black arrows) may have resulted in indirect distortion of the anterior mitral annulus and/or the basal left septum (blue arrows), aggravating the propensity to VT.

## Appendix Supplementary data

Supplementary data associated with this article can be found in the online version at <https://doi.org/10.1016/j.hrcr.2018.05.003>.

## References

1. Naoum C, Falk G, Ng AC, Lu T, Ridley L, Ing AJ, Kritharides L, Yiannikas J. Left atrial compression and the mechanism of exercise impairment in patients with a large hiatal hernia. *J Am Coll Cardiol* 2011;58:1624–1634.
2. Naoum C, Puranik R, Falk GL, Yiannikas J, Kritharides L. Postprandial left atrial filling is impaired in patients with large hiatal hernia and improves following surgical repair. *Int J Cardiol* 2015;182:291–293.
3. Naoum C, Kritharides L, Gnanenthiran SR, Martin D, Falk GL, Yiannikas J. Valsalva maneuver exacerbates left atrial compression in patients with large hiatal hernia. *Echocardiography* 2017;34:1305–1314.
4. Roy RR, Sagar S, Bunch TJ, Aman W, Crusan DJ, Srivathsan K, Asirvatham SJ, Shen WK, Jahangir A. Hiatal hernia is associated with an increased prevalence of atrial fibrillation in young patients. *J Atr Fibrillation* 2013;6:11–15.
5. Bunch TJ, Packer D, Jahangir A, Locke GR, Talley NJ, Gersh BJ, Roy RR, Hodge DO, Asirvatham SJ. Long-term risk of atrial fibrillation with symptomatic gastroesophageal reflux disease and esophagitis. *Am J Cardiol* 2008;102:1207–1211.
6. Patel A, Shah R, Nadavaram S, Aggarwal A. Hiatal hernia squeezing the heart to flutter. *Am J Emerg Med* 2014;32:e1–2.
7. Patel N, Baker SM, Ulveling K. The way to a man's heart is through his stomach. *J Gen Intern Med* 2013;28:1674–1675.
8. Zanini G, Seresini G, Racheli M, Bortolotti M, Virgillo A, Novali A, Benetello C, Pasini GF. Electrocardiographic changes in hiatal hernia: a case report. *Cases J* 2009;15:8278.
9. Gard JJ, Bader W, Enriquez-Sarano M, Frye RL, Michelena HI. Uncommon cause of ST elevation. *Circulation* 2011;123:e259–261.
10. Cristian DA, Constantin A, Barbu M, Spătaru D, Burcoş T, Grama FA. Paroxysmal postprandial atrial fibrillation suppressed by laparoscopic repair of a giant paraesophageal hernia compressing the left atrium. *J Gastrointest Liver Dis* 2015;24:113–116.
11. Li J, Solus J, Chen Q, Tho YH, Milne G, Stein CM, Darbar D. Role of inflammation and oxidative stress in atrial fibrillation. *Heart Rhythm* 2010;7:438–444.