

# Bone transport for limb reconstruction following severe tibial fractures

Julian Fürmetz,<sup>1</sup> Chris Soo,<sup>1</sup>  
 Wolf Behrendt,<sup>2</sup> Peter H. Thaller,<sup>1</sup>  
 Holger Siekmann,<sup>3</sup> Jörg Böhme,<sup>2</sup>  
 Christoph Josten<sup>2</sup>

<sup>1</sup>3D-Surgery, Department of Trauma Surgery, Munich University Hospital LMU, Munich; <sup>2</sup>Department of Trauma, Reconstructive and Plastic Surgery, University Hospital Leipzig;

<sup>3</sup>Department of Trauma and Reconstructive Surgery, Martin Luther University, Halle-Wittenberg, Germany

## Abstract

A common treatment of tibial defects especially after infections is bone transport via external fixation. We compare complications and outcomes of 25 patients treated with a typical Ilizarov frame or a hybrid system for bone reconstruction of the tibia. Average follow up was 5.1 years. Particular interest was paid to the following criteria: injury type, comorbidities, development of osteitis and outcome of the different therapies. The reason for segmental resection was a second or third grade open tibia fractures in 24 cases and in one case an infection after plate osteosynthesis. Average age of the patients was 41 years (range 19 to 65 years) and average defect size 6.6 cm (range 3.0 to 13.4 cm). After a mean time of 113 days 23 tibial defects were reconstructed, so we calculated an average healing index of 44.2 days/cm. Two patients with major comorbidities needed a below knee amputation. The presence of osteitis led to a more complicated course of therapy. In the follow up patients with an Ilizarov frame had better results than patients with hybrid systems. Bone transport using external fixation is suitable for larger defect reconstruction. With significant comorbidities, however, a primary amputation or other methods must be considered.

## Introduction

Compound fractures of the tibia are common. The most frequent mechanism of injury is high energy and over 50% may be classified as type III Gustilo-Anderson fractures.<sup>1,2</sup> Complications regularly occur, influenced by severity of soft tissue damage and degree of fracture site contamination. Infection (5-16%), non-union (5-30%), loss of fixation, and abnor-

mal biomechanics usually result in significant patient morbidity.<sup>2,4</sup>

Initial management of compound fractures normally involves significant surgical debridement and stabilization. Additionally, secondary complications may require subsequent resection of bone, potentially resulting in very large defects which may pose a significant challenge even to the experienced surgeon.<sup>5-9</sup>

There are now multiple options available for the management of large tibial defects. In recent times, the most widely utilized reconstructive approach has been external fixation with gradual limb lengthening or bone transport by distraction osteogenesis.<sup>5-8</sup> Distraction osteogenesis promotes physiological intramembranous bone formation under tension, and was largely pioneered in the 1950s-1960s by Ilizarov. Ilizarov's design consists of an external ring fixator, with a corresponding osteotomy and the application of gradual distraction to the two bone segments. This allows de novo bone and soft tissue formation to replace the missing bone.<sup>5-10</sup>

Normal fracture healing requires sufficient stability to permit appropriate apposition and alignment of the new bone.<sup>11,12</sup> Therefore, an effective fixation system must discourage off-axis forces, while still permitting a degree of dynamic axial load. Early monolateral fixators were considered too rigid, tending towards inadequate bone stimulation and resulting in nonunion or malunion; and also allowed asymmetrical axis motion, leading to asymmetrical axis deviation.<sup>6,8,12</sup>

The Ilizarov ring apparatus largely solved these two problems, permitting a symmetrical distribution of forces, while permitting a degree of axial load-sharing at the fracture site.<sup>10,12</sup> However, a significant complication rate remained, and obtaining additional soft-tissue access often proved difficult if further surgical intervention was required. Hybrid systems were developed in response for this need, attempting to combine the ability of the circular systems to adequately fix the healing fracture site, with the soft-tissue access permitted by a monolateral apparatus.<sup>12</sup>

The most common, and severe, complication of bone transport is non-union of the docking site.<sup>3,5,7,8</sup> Due to the relative avascularity of the leading edge of the transported bone segment, consolidation at these sites represent the longest phase of the entire process, and this prolongation of the healing process can substantially delay the removal of an external fixator.<sup>11,13,14</sup>

Studies have suggested the addition of a cancellous bone graft may assist with earlier union, shorten external fixation time, and minimize re-fracture risk.<sup>15,16</sup> Plate osteosynthesis has also been suggested to improve outcomes when combined with external fixation, but studies comparing this docking approach

Correspondence: Julian Fürmetz, Department of Surgery, 3D-Surgery, University of Munich (LMU), Nussbaumstr. 20, 80336 München, Germany.  
 Tel.: +49.89.4400.55401 - Fax: +49.89.4400.55402.  
 E-mail: julian.fuermetz@med.uni-muenchen.de

Key words: Bone transport; Ilizarov; fracture; tibia; distraction osteogenesis.

Contributions: JF conceived the study, was responsible for coordination of data acquisition, analysis and interpretation, as well as writing the manuscript; CS was involved in the analysis and interpretation of the data and in revising the manuscript; WB was responsible of screening the patients, review of patient records, final excel table and data analysis; PHT was involved in the interpretation of the data and in revising the manuscript; HS was involved in the analysis and interpretation of the data and in revising the manuscript. JB conceived the study, participated in its design and coordination and helped to draft the manuscript; CJ contributed to the design of the study, interpretation of data and critically revised the manuscript.

Conflict of interest: the authors declare no potential conflict of interest.

Conference presentation: presentation of the first results at the Congress of the German Society for Orthopaedics and Trauma, October 27th 2010, Berlin.

Received for publication: 28 December 2015.  
 Accepted for publication: 7 February 2016

This work is licensed under a Creative Commons Attribution NonCommercial 4.0 License (CC BY-NC 4.0).

©Copyright J. Fürmetz et al., 2016  
 Licensee PAGEPress, Italy  
 Orthopedic Reviews 2016;8:6384  
 doi:10.4081/or.2016.6384

are few and results inconclusive.<sup>17</sup>

This study presents our experience with hybrid and classic Ilizarov fixation systems in the reconstruction of complex tibial fractures by bone transport and limb lengthening after primary shortening. Our study aims to: i) evaluate and compare the clinical outcomes of the use of hybrid and classic Ilizarov fixation systems in the reconstruction of complex tibial fractures by bone transport and limb lengthening; ii) examine the effect of various docking methods on healing and treatment course.

## Materials and Methods

Between 2000 and 2010, patients were consecutively recruited at a level I trauma center.

The inclusion criteria for this study were as follows: patients aged a minimum of 18 years, with a bone defect of greater than 3 cm after tibial fracture, requiring secondary bone formation by callus distraction or bone transport. Patients were excluded from the study if they had not yet reached skeletal maturity, had neurological disorders affecting gait, or reported any systemic bone disease. Twenty-five patients fulfilled the inclusion criteria, and data from these cases were retrospectively reviewed (Table 1). Written consent was given by each of the patients.

Participants were aged between 21 and 65 years of age (5 women, 20 men), with a mean of 42 years. Patients consisted both of presentations via the emergency department, and those referred later. Using the Gustilo classification system, there were 19 grade IIIA and 3 grade IIIB fractures.<sup>9</sup> The remaining 3 patients had an internal fixation of a closed fracture with secondary infection (2 plate osteosynthesis, 1 intramedullary nail).

Details were recorded of patient demographics, initial cause of injury, number and severity of comorbidities, operative proce-

dures, additional antibiotic use required, initial fracture grading, pre-operative soft-tissue damage, and smoking status. Peripheral arterial diseases (PAD) were excluded by angiography. Details were recorded of the bone to be operated; type of injury; post-operative days to the end of the distraction; days to radiological bony consolidation; time to full weight-bearing without crutches; mean lengthening distance (mm); Bone Healing Index (days/cm); mean distraction time (days); mean time to patient discharge (days); mean duration of fixator application (days); limbs in which target lengthening was achieved (within 1 cm of target); Maryland Foot Score, a marker of post-operative pain and functional status; ADL score; radiological assessment of axial alignment; and clinical assessment of scar quality. Particular interest was paid to the effects of the different surgical techniques on the course of treatment and treatment outcome.

Complications were also recorded; particularly the number of superficial and deep infections, additional surgical interventions required, and docking failures.

A systemic antibiotic, cefuroxime, was given

empirically to all 25 patients immediately following hospital admission, and continued for a minimum of 72 hours.

All patients received standardized post-operative instructions about how to independently manage self-distraction, and careful pin-care. Partial weight-bearing of up to 20 kg was encouraged from the 1<sup>st</sup> post-operative day, and maintained until radiological evidence of consolidation was obtained. Weight-bearing was then increased gradually. Patients were permitted to return home following adequate initial wound healing, and were reviewed in out-patient clinic by the surgical team 1 week after initial post-operative discharge, then every week during bone transport, and then every second week until radiological consolidation was noted.

All 25 patients were followed up through to the end of the consolidation phase, with a mean follow-up of 46 months. 2 years after the completion of the consolidation phase, 20 patients (80%) re-presented for a final clinical assessment of lower limb power, range of motion, Activities of Daily Living scores, and Maryland Foot Scores; along with radiological

**Table 1. Patients and results.**

	Age	Sex	Infection	Fixator	Length of bone transport, mm	Time of bone distraction, days	Time of frame wearing, days	Healing index, days/cm	Region, type of final docking	Working capacity
1	65	m	yes	Hybrid	94	89	206	21.9	d, bone graft and plate	none
2	34	f	yes	Hybrid	57	155	255	44.7	m, external compression	full
3	39	m	yes	Hybrid	85	162	175	20.5	d, bone graft and plate	none
4	41	m	yes	Ilizarov	60	100	281	46.8	d, bone graft and plate	full
5	43	m	yes	Ilizarov	134	203	203	15.1	d, bone graft and plate	full
6	40	f	yes	Hybrid	110	189	426	38.7	m, external compression	none
7	28	m	yes	Hybrid	56	113	168	30.1	d, plate	unknown
8	54	m	yes	Ilizarov	112	154	443	39.5	amputation	none
9	48	m	yes	Ilizarov	31	52	152	49	d, bone graft and plate	full
10	54	m	yes	Hybrid	68	123	125	18.3	d, bone graft and plate	full
11	21	m	yes	Hybrid	70	92	288	41.1	d, bone graft and plate	full
12	48	m	yes	Hybrid	55	72	183	31.4	d, bone graft and plate	full
13	61	f	no	Hybrid	30	64	233	73.1	d, bone graft and plate	none
14	61	f	yes	Hybrid	30	46	455	151.6	d, bone graft	none
15	39	m	yes	Hybrid	50	210	210	42	d, bone graft	none
16	53	m	yes	Hybrid	40	60	230	57.5	d, bone graft and plate	none
17	34	m	yes	Ilizarov	80	129	137	17.1	d, bone graft	unknown
18	24	m	yes	Hybrid	80	70	342	42.7	d, plate	unknown
19	32	m	yes	Ilizarov	80	178	273	34.1	d, bone graft and plate	unknown
20	27	m	yes	Ilizarov	80	194	197	24.6	m, external compression	with limits
21	35	m	no	Hybrid	15	23	105	70	m, external compression	unknown
22	37	m	yes	Hybrid	80	114	324	40.5	d, plate	none
23	57	m	yes	Hybrid	35	62	215	61.4	m, external compression	with limits
24	39	f	yes	Ilizarov	61	76	636	99.3	d, bone graft	none
25	41	m	yes	Hybrid	108	104	148	13.8	amputation	none

m, metaphyseal; d, diaphyseal.

assessments of lower limb axial deviations, consolidation of the docking site and regenerate, and arthritic ankle joint changes.

### Surgical technique

Each patient initially received a surgical primary radical debridement of non-viable bone and other soft tissue, and external fracture stabilization. Surgical priority was given to soft tissue consolidation, with serial debridement and Vacsual usage. For larger soft tissue defects, flaps were used to provide adequate soft tissue coverage. On average, 4 preparatory surgical interventions were required per patient before there were suitable conditions for adequate callus distraction. 6 patients required preparatory flap reconstruction surgery.

The bone segment transport procedure was performed using Ilizarov's well-described methodology. Corticotomy was undertaken using chisels and drills, and distraction commenced after 7 days, with a target transport speed of 1mm per day. 8 patients were fitted with the classic Ilizarov ring fixation system (Figure 1), while 17 were fitted with a hybrid system (Figure 2); combining a distal joint-bridging ring construction with a proximal monolateral fixation system. Fixator correction and further therapeutic intervention were individually implemented as necessary.

Four different fixation docking systems were utilized: compression from an external fixator alone; compression from an external fixator combined with cancellous bone grafting; and plate osteosynthesis alone or in combination with cancellous bone grafting.

### Results

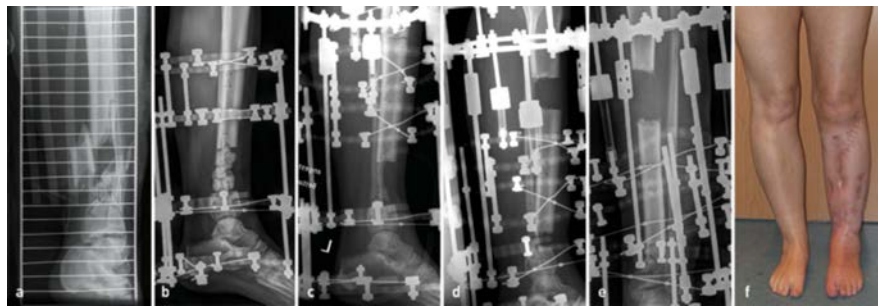
Both the Ilizarov and the Hybrid fixator patient groups were similar at baseline with regards to the initial fracture properties, bone transport distance, biometric characteristics and co-morbidities. Treatment course for both groups and fixator-related complications such as pin loosening, wound breakdown or infection were comparable ( $M=0.9$  vs  $M=1.0$ ).

All patients in the Ilizarov fixator group yielded good to very good Maryland Foot Scores, compared to only 75% with Hybrid fixators. Axial malalignment of greater than 5 degrees occurred more frequently in the Hybrid group ( $n=4$  vs  $n=1$ ), however, this was able to be remedied by a corrective osteotomy in every instance. The Ilizarov patient group reported better scar formation and less severe ankle osteoarthritis (12% vs 53%); 67% of the Ilizarov group had returned to work, compared to just 36% with Hybrid fixation (Table 1).

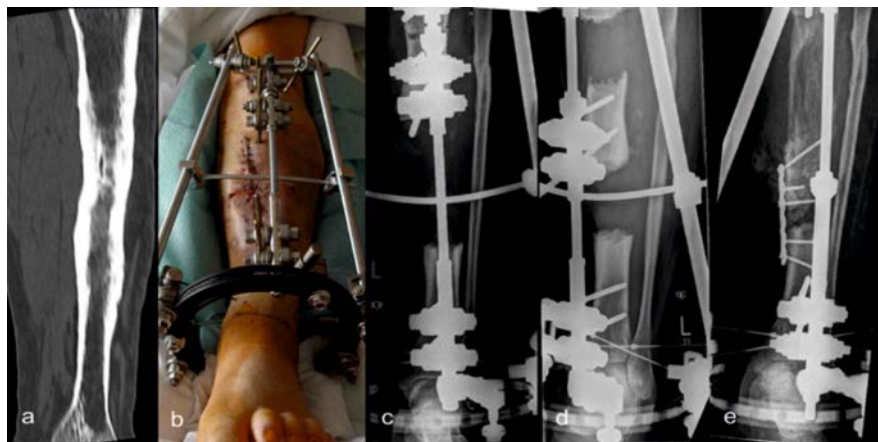Twenty-one bone defects were able to be successful reconstructed through bone trans-

port. 2 patients were successful managed with primary shortening of the lower leg and treated by subsequent callus distraction. The remaining 2 patients required lower limb amputation.

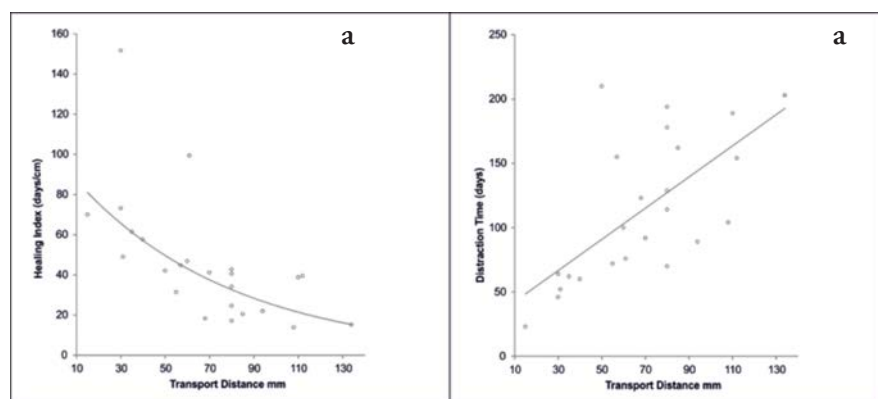
For all patients, the transport distance was on average 68 mm ( $SD\pm 29.69$ ), mean distraction time was 113 days ( $SD\pm 55$ ) and fixation apparatus were used for an average of 256 days. The correlation between transport dis-



**Figure 1.** A 39-year-old patient with a 6.1 cm tibial defect after open tibial fracture (IIIA); a) initial fracture type 43-A3, b) condition after segmental resection, implementation of local Antibiotics via PMMA and external fixation via a ilizarov ring fixator, c) corticotomy of the proximal tibia and enhancement of the ilizarov ring system d) during bone transport, e) docking site with external compression, f) clinical condition two years after completion of therapy.



**Figure 2.** A 50 year old patient with posttraumatic tibial shaft osteitis: a) computed tomography findings before segment resection; b) Hybrid fixator after segment resection; c) proximal tibia corticotomy; d) on-going segment transport; e) diaphyseal docking via plate osteosynthesis and bone graft.



**Figure 3.** a) Relationship between transport distance and distraction time; b) relationship between transport distance and Bone Healing Index.



tance and mean distraction time was highly significant ( $R=0.67$ ;  $P<0.001$ ).

The Bone Healing Index (BHI) was on average 45 days per cm of transport distance. BHI decreased proportionally with increasing bony defect length ( $R=-0.621$ ;  $P=0.001$ ; Figure 3).

Neither of the 2 subjects treated with primary shortening followed by simple callus distraction developed any post-operative osteitis. They did not require docking procedures, and compared to the bone transport group, had a lower complication rate ( $M=0.5$  vs  $M=1.1$ ); required far fewer subsequent operations ( $M=2.5$  vs  $M=10.8$ ); and had a much shorter stay in hospital ( $M=62.5$  vs  $M=116.7$ ). The other 23 patients developed osteitis requiring additional, subsequent surgical resection.

Patients with multiple, severe comorbidities ( $n=5$ ) had a significantly longer hospital stay and a more complicated course of treatment ( $M=147$  vs 88 days;  $P=0.03$ ). Two required amputation. In contrast, no significant correlation could be found between quality of the initial fracture site nor amount of soft tissue defect before treatment. Neither age nor smoking significantly influenced treatment outcome.

Fourteen patients required additional antibiotic beads or sponges, however there was no significant effect on infection control or treatment course. There were no gross neurovascular injuries or compartment syndrome.

Successful fixator docking was achieved in all patients. In the metaphyseal region, external compression alone via the fixator was successful in all 5 patients with metaphyseal docking.

In the diaphysis, all 18 patients received an additional planned docking site procedure. 7 docking maneuvers were not successful and needed further surgical intervention. In total, 25 interventions were completed for a union at the docking site in the diaphyseal region. Plate osteosynthesis ( $n=6$ ) or cancellous bone graft ( $n=8$ ) had a 50% success rate. Plate osteosynthesis and simultaneous bone grafting ( $n=11$ ) had a 100% success rate regardless of whether the procedure was primary or secondary.

## Discussion

Post-traumatic reconstruction of any tibial injury, with any large bone defect, is long and complex and requires enormous effort on behalf of both patient and surgeon. The decision on how best to attempt to salvage the limb is often difficult to make, and several issues need to be considered; defect size, comorbidities, patient expectation and compliance.

In our cohort, treatment was much more difficult for patients with multiple, significant comorbidities. In order to avoid a long and

debilitating course of treatment, amputation should be considered early for these patients.

A study published in 2005 by Baumgart *et al.* similarly noted a higher complication rate (2.3 vs 1.6) and a higher BHI (50.2 vs 40.8) following the development of osteitis.<sup>18</sup> Schmidt *et al.* (2002) also reported an increased BHI in patients with pre-existing osteitis.<sup>19</sup> Our results support these findings; pre-existing osteitis secondary to a tibial fracture was present prior to the commencement of treatment in 23 cases; and subjects who were treated initially with primary leg shortening and subsequent simple callus distraction, developed no osteitis and had a simpler treatment course and better overall outcomes.

We therefore believe that initial radical resection, to reduce the risk of healing site infection in tibial fractures with significant bone defects, may help to minimize complications and improve treatment course. The size of the resulting defect should distinctly be the second priority to minimizing infection risk; as the number of operations, amount of complications, length of hospital stay and BHI are all significantly increased in the case of infection.<sup>18,19</sup>

The BHI has been defined two separate ways in the literature. Some authors have described it, similarly to us, as the mean consolidation index; or the time to bony union (duration of external fixator use), divided by the amount of regenerated bone length in days per cm. Meanwhile, other studies define the BHI as the duration of treatment to full axial loading per cm length of regenerated bone. This has to be taken into account when interpreting our results.

We found that longer segment transport distances were not associated with a worse treatment course or overall patient outcome. In our study, BHI was on average 45 days per cm. Other authors report Bone Healing Indices of 42 to 50 days per cm.<sup>18,21</sup>

We also found that BHI decreased proportionally with increasing bony defect length, suggesting that larger defects necessitated less healing time to restore the length of the bone. Other authors have similarly achieved good results with long transport distances.<sup>21,22</sup> This further emphasizes that early segmental bony resection should certainly not be avoided or feared; as it is infection, rather than the defect length, which is the decisive factor for the further course of treatment.

Use of local antibiotic devices remains a controversial topic. A 1995 retrospective study by Ostermann *et al.* reported a significant reduction of infection rate following use of PMMA chains with higher grade open fractures.<sup>23</sup> However, there are still no prospective studies that have been able to demonstrate the efficacy of local antibiotic therapy in osteitis.<sup>24</sup> With the uncertainty in the literature,

Tiemann and Hoffman (2009) suggested that additional local antibiotic therapy should only be used in the setting of purulent bone infection or acute exacerbation of chronic osteitis.<sup>25</sup> Our findings support this.

When comparing the two distraction apparatus, no significant differences were observed during therapy with regards to operation count, hospital stay, BHI, or success of fixator docking procedures. Apparatus-related complication rate was similar for both groups. The ring construction of the Ilizarov fixator certainly offers more control and scope for fine correction during the transport phase, and this explains the lesser incidence of lower limb malalignment within this cohort.<sup>26</sup> Designs with hexapod technology, such as the Taylor Spatial frame, further improve the ability to simultaneously correct lower limb axis deviations with continual computer-assisted monitoring. But weight and costs of these systems have to be taken into account.<sup>6</sup> Our management protocols are comparable with other similar studies.<sup>21,22,27</sup> Similar to other studies, the classic Ilizarov fixator group demonstrated better functional outcomes than the Hybrid fixator group. Of concern, treatment with Hybrid systems also appears to result in a higher rate of post-treatment lower limb axial deviation.<sup>21,22,27</sup>

The current gold standard in external fixation is the ring fixator.<sup>6,28-31</sup> While monolateral fixation systems are highly rigid in the immediately vicinity to fixation apparatus, there is a propensity toward a higher degree of freedom of movement on the non-fixed, contralateral side. This can lead to an uneven distribution of compression and distraction forces within the bone.<sup>28</sup>

A ring fixator more uniformly distributes the weight around a central axis, with rigidity increasing directly in proportion to increasing load. Thus, a higher degree of stability may be theoretically achieved, and can form a better foundation through which micro movements may then be superimposed, to provide the appropriate stimulus required for adequate callus formation.<sup>28</sup> Thus, consolidation time may be less for ring systems than for monolateral fixation devices.<sup>27</sup> This biomechanical advantage is a possible explanation for the differences in functional outcomes between the two cohorts of our study.

In a comparison between hybrid and classic ring fixation apparatus, Lundy *et al.* suggested that there were no significant biomechanical advantage to either approach.<sup>29</sup> Meanwhile, Khalily *et al.* found the classic ring to be superior.<sup>12</sup>

As stated previously, successful docking of the fixator apparatus is crucial for successful bone transport. Our findings regarding the relative success of the metaphyseal approach are mirrored by current recommendations found

in the literature, that metaphyseal docking normally requires only external compression from the fixator alone, and additional bone grafts need only be recommended in the presence of anticipated instability.<sup>26,27,32</sup> Other authors support our findings, and have also recommend plate osteosynthesis with bone grafting in diaphysis docking.<sup>30</sup>

## Conclusions

The authors recognize that this study has limitations. It is retrospective and represents the experience of 2 surgeons from a single treatment facility. The study, like similar studies, suffers from a small number of study participants. Despite these limitations, this is an analysis of a reasonably homogenous group of patients with complex tibial fractures requiring large bone resection; and remains the only study to date which analyses the effect of a variety of fixator docking approaches as well as to compare the effectiveness of the classic Ilizarov ring fixator to hybrid apparatus. However, the authors recognize the need for higher power, prospective studies with larger sample sizes to draw more definitive conclusions.

In conclusion, our study finds that the Ilizarov apparatus yields better outcomes in limb reconstruction following severe, compound fractures of the tibia.

## References

- Hansen M, Mehler D, Voltmer W, Rommens PM. The extraarticular proximal tibial fractures. *Unfallchirurg* 2002;105:858-72.
- Court-Brown CM, Caesar B. Epidemiology of adult fractures: a review. *Int J Care Injured* 2006;37:691-7.
- Gaebler C, Berger U, Schandelmaier P, et al. Rates and odds ratios for complications in closed and open tibial fractures treated with unreamed, small diameter tibial nails: a multicenter analysis of 467 cases. *J Orthop Trauma* 2001;15:415-23.
- Giannoudis PV, Papakostidis C, Roberts C. A review of the management of open fractures of the tibia and femur. *J Bone Joint Surg Br* 2006;88:281-9.
- Paley D. Problems, obstacles, and complications of limb lengthening by the Ilizarov technique. *Clin Orthop Relat Res* 1990;250:81-104.
- Paley D. Progress in and from limb lengthening. In: Ashok L, Waddell K, Johari J, eds. *Current progress in orthopaedics*. 1<sup>st</sup> ed. Mumbai: Treelife Media; 2014.
- Hamdy RC, Rendon JS, Tabrizian M. Distraction osteogenesis and its challenges in bone regeneration. In: Haim T, ed. *Bone regeneration*. Rijeka: Intech; 2012.
- Rigal S, Merloz P, Le Nen D, et al. Bone transport techniques in posttraumatic bone defects. *Orthop Traumatol Surg Res* 2012;98:103-8.
- Gustilo RB, Anderson JT. Prevention of infection in the treatment of one thousand and twenty-five open fractures of long bones: retrospective and prospective analyses. *J Bone Joint Surg Am* 1976;58:453-8.
- Ilizarov GA. Clinical application of the tension-stress effect for limb lengthening. *Clin Orthop Rel Res* 1990;250:8-26.
- Gaston MS, Simpson AHRW. Inhibition of fracture healing. *J Bone Joint Surg Br* 2007;89:1553-60.
- Khalily C, Voor MJ, Seligson D. Fracture site motion with Ilizarov and "hybrid" external fixation. *J Orthop Trauma* 1998;12:21-6.
- Aronson J, Johnson E, Harp JH. Local bone transportation for treatment of intercalary defects by the Ilizarov technique. *Biomechanical and clinical considerations*. *Clin Orthop Relat Res* 1989;243:71-9.
- Rozbruch SR, Weitzman AM, Watson JT, et al. Simultaneous treatment of tibial bone and soft-tissue defects with the Ilizarov method. *J Orthop Trauma* 2006;20:197-205.
- Song HR, Cho SH, Koo KH, et al. Tibial bone defects treated by internal bone transport using the Ilizarov method. *Int Orthop* 1998;22:293-7.
- Loviseti G, Sala F. Clinical strategies at the docking site of distraction osteogenesis: are open procedures superior to the simple compression of Ilizarov? *Injury* 2013;44:S58-62.
- open tibial fractures. A comparison of results. *Clin Orthop Relat Res* 1983;178:54-63.
- Hofmann GO, Mückley T, Diefenbeck M. Knochenersatz durch Kallusdistraction an der unteren Extremität. *Trauma Berufskrankheit* 2005;7:282-9.
- Baumgart R, Hinterwimmer S, Kettler M, et al. Central bone transport system optimizes reconstruction of bone defects. Results of 40 treatments. *Unfallchirurg* 2005;108:1011-21.
- Schmidt HGK, Wurm M, Hadler D, Grosser V. Verlängerungstechniken und Möglichkeiten des Segmenttransports im Ringsystem nach Ilizarov. *Trauma Berufskrankheit* 2002;4:413-26.
- Dinah AF. Predicting duration of Ilizarov frame treatment for tibial lengthening. *Bone* 2004;34:845-8.
- Paley D, Maar DC. Ilizarov bone transport treatment for tibial defects. *J Orthop Trauma* 2000;14:76-85.
- Dendrinis GK, Kontos S, Lyritsis E. Use of the Ilizarov technique for treatment of non-union of the tibia associated with infection. *J Bone Joint Surg Am* 1995;77:835-46.
- Ostermann PA, Seligson D, Henry SL. Local antibiotic therapy for severe open fractures. A review of 1085 consecutive cases. *J Bone Joint Surg Br* 1995;77:93-7.
- Barth RE, Vogely HC, Hoepelman AIM, Peters EJG. To bead or not to bead? Treatment of osteomyelitis and prosthetic joint-associated infections with gentamicin bead chains. *Int J Antimicrob Agents* 2011;38:371-5.
- Tiemann AH, Hofmann GO. Principles of the therapy of bone infections in adult extremities. Are there any new developments? *Strategies Trauma Limb Reconstr* 2009;4:57-64.
- Josten C, Kremer M, Muhr G. Ilizarov procedure in pseudarthrosis. *Orthopade* 1996;25:405-15.
- Josten C, Muhr G. Tibial segment transport. *Unfallchirurg* 1999;102:514-24.
- Fragomen AT, Rozbruch SR. The mechanics of external fixation. *HSS J* 2007;3:13-29.
- Lundy DW, Albert MJ, Hutton WC. Biomechanical comparison of hybrid external fixators. *J Orthop Trauma* 1998;12:496-503.
- Kutscha-Lissberg F, Hopf, KF. Why do osteosyntheses fail? The problem with biomechanics and biology. *Unfallchirurg* 2003;106:708-21.
- Yilmaz E, Belhan O, Karakurt L, et al. Mechanical performance of hybrid Ilizarov external fixator in comparison with Ilizarov circular external fixator. *Clin Biomech (Bristol, Avon)* 2003;18:518-22.
- Kutscha-Lissberg F, Hebler U, Kälicke T, Arens S. Principles of surgical therapy concepts for postoperative and chronic osteomyelitis. *Orthopade* 2004;33:439-54.