



Contents lists available at ScienceDirect

International Journal of Surgery Case Reports

journal homepage: www.casereports.com

Silent sinus syndrome (First Case Report, Saudi Arabia with recommendation)

Nouf S. AlSaloom^a, Nahid Y. Ashri^{b,*}^a College of Dentistry, King Saud University, Riyadh, Saudi Arabia^b Department of Periodontics and Community Dentistry, College of Dentistry, King Saud University, Riyadh, Saudi Arabia

ARTICLE INFO

Article history:

Received 27 May 2020

Received in revised form 11 August 2020

Accepted 12 August 2020

Available online 18 August 2020

Keywords:

Case report

Silent sinus syndrome

SSS

CT

MRI

Functional endoscopic sinus surgery

ABSTRACT

INTRODUCTION: Silent sinus syndrome is a rare disorder that presents a diagnostic challenge, most of the patients with this syndrome present with ophthalmological complaints without any nasal sinus symptoms, and it has a painless course and slow development. The syndrome can be diagnosed clinically and confirmed radiologically, and CT imaging is considered the gold standard for its diagnosis. The classical radiographic findings are opacification and collapse of the sinus walls. Functional endoscopic sinus surgery (FESS) is the standard gold treatment of choice to arrest the progression of the disease.

PRESENTATION OF CASE: A case report of a 37-years-old-female who was complaining of severe throbbing pain since 2009, is presented here where the diagnosis of SSS was obtained in 2018, this delay in diagnosing the situation had affected the patient lifestyle tremendously.

DISCUSSION: Accordingly, knowledge of the signs and features of SSS can result in an accurate diagnosis. Suspected cases of silent sinus syndrome require prompt ear, nose, and throat referral for consideration of definitive diagnosis and surgical management. Nasal endoscopy and clinical evaluation are also essential for the diagnosis.

CONCLUSION: Our recommendation is to consider SSS as a differential diagnosis for patients with spontaneous enophthalmos and hypoglobus, even in the absence of maxillary sinus opacification. Moreover, encourage all the specialists in the medical and the dental field to communicate well together in cases like this.

© 2020 The Authors. Published by Elsevier Ltd on behalf of IJS Publishing Group Ltd. This is an open access article under the CC BY-NC-ND license (<http://creativecommons.org/licenses/by-nc-nd/4.0/>).

1. Introduction

Silent sinus syndrome (SSS) is defined as a spontaneous, asymptomatic collapse of the maxillary sinus with negative pressure [1]. It is a rare condition and considered idiopathic. It is usually unilaterally, with a slight predominance to the right maxillary sinus (57%) [2,3]. Although the patho-physiology of SSS remains unknown, some consider obstruction of the infundibulum, which leads to negative pressure over time as a causative factor [4].

Montgomery first described the syndrome in 1964; however, in 1994, Soparkar et al., was the first to use the term silent sinus syndrome. The syndrome typically occurs in individuals during their third and fifth decades and has no predilection for sex. There are only 105 cases that were reported in the English literature, with patients typically unaware of the disease [1,5–7]. Some patients may have spontaneous structural orbital changes with depression of the orbital floor, deepening of the superior sulcus, retraction of

the eyelid, and they may come with diplopia, facial asymmetry, drooping of the upper lid, facial paraesthesia, and numbness [8].

The syndrome can be diagnosed clinically and confirmed radiologically, where the radiographic picture includes ipsilateral enophthalmos and collapse of the maxillary sinus [9,10]. Silent sinus syndrome is a rare disorder that can pose a diagnostic challenge, most of the patients with this syndrome present with ophthalmological complaints without any nasal sinus symptoms, and it typically has a painless course and slow development, so they termed it “silent,” that’s why the diagnosis is difficult [3].

There is no history of trauma and no obvious clinical features of chronic sinusitis, but occasionally the patient complains of nose and sinuses symptoms, but mainly they are aware of some aesthetic and uncomfortable change in appearance like eyelid retraction, superior orbital sulcus deepening or unpleasant flattening of the malar region [2].

Parry-Romberg syndrome, linear scleroderma, congenital facial asymmetry, and trauma could be considered as differential diagnosis of SSS [4,11]. The definitive treatment of SSS is surgical with functional endoscopic sinus surgery (FESS) [12].

Up to our knowledge, there is no case report about SSS, neither in the kingdom of Saudi Arabia (KSA) or Arabian gulf countries,

* Corresponding author.

E-mail address: Nashri00@yahoo.com (N.Y. Ashri).

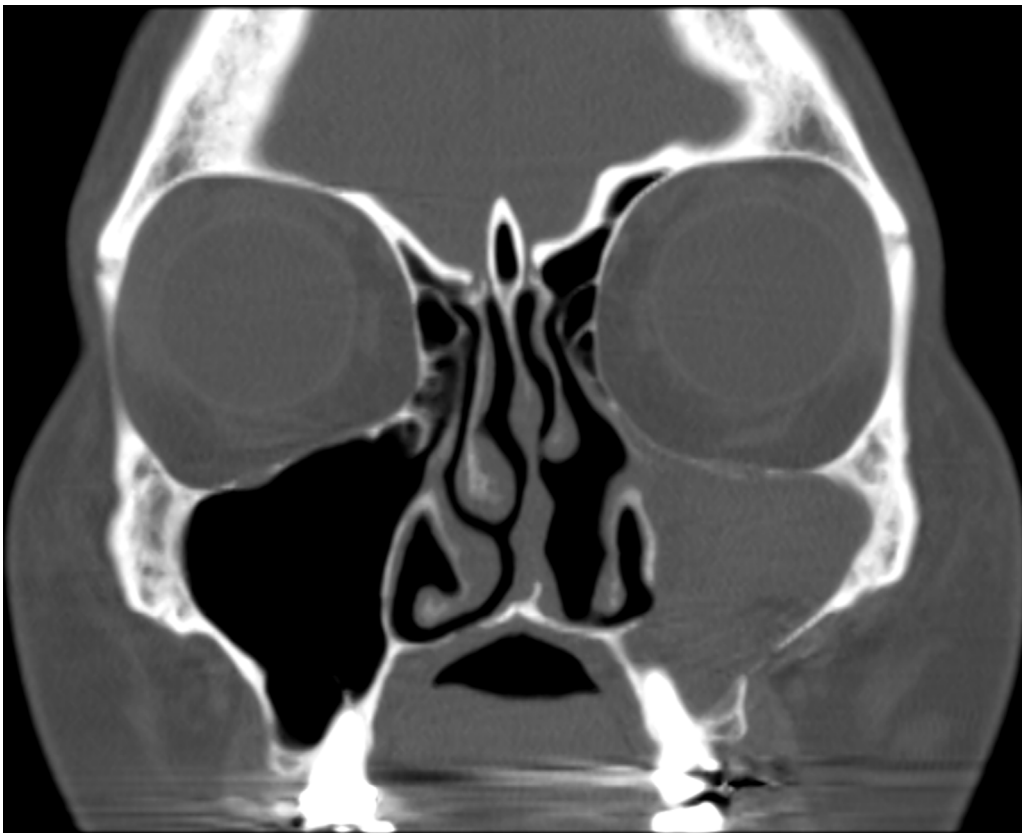


Fig. 1. Coronal CT Image of the skull showing complete opacification with hyperdense fluid content of the left maxillary sinus.

with the exception of one case report in Kuwait [13]. Accordingly, the case reported here is considered the first case to be reported in KSA. This paper has been reported in line with the SCARE criteria [14].

2. Case report

A 37-years-old-female with severe throbbing pain on the left upper jaw, depression of the orbital floor, lazy, droopy eyelid, and facial numbness related to the left side of the face showed up in the ER clinic in our institute in September 2018.

Her medical history included; mouth breathing and tonsillectomy at 9-years-old, she also had nasal septum deviation on the left side due to trauma in her nose, by the age of 35 this deviation reached 82% with blockage of the airway on the left side, and it was S-shaped from both sides. She has General Anxiety Disorder and she was not smoker. Family history include; her father has Blood pressure and her mother has cholesterol.

In 2004, she was diagnosed with irritable bowel syndrome IBS and stomach ulcer. In 2006, she underwent orthognathic surgery, in 2009, she had frequent severe headache attacks that usually last for one week, the frequency of the attack was almost every three months, accordingly, she went to a neurologist and diagnosed with migraine headache and prescribed Topamax (topiramate) 25 mg for her as a prophylactic regime.

In 2014, she fainted suddenly with no pain or any other symptoms, accordingly, other investigations with MRI were initiated, however, nothing relevant was found, so the neurologist diagnosis was “stress” in addition to her migraine and tension headaches. In 2016, deviated nasal septum surgery was performed.

In 2017, the frequency and duration of the headaches increased tremendously and were not controlled by medications. Her neuro-

logist increased the dose of the medication (Topamax 50 mg), and prescribed anti-anxiety for her with no other investigation.

In July 2018, the severity of the headache increased and was uncontrollable, even though she was on a daily dose of 500 mg Solpadein. The patient lifestyle was negatively affected on nearly every other aspect of her life, including mood and capacity to function in daily roles. Accordingly, her neurologist took a CT scan, which showed no acute intracranial pathology. Only one abnormality was found which is the presence of hyperdense opacification at the left maxillary sinus.

Accordingly, additional MRI investigation was performed which showed normal features; however, there was mild asymmetry regarding the size of the lateral ventricles being more prominent on the left side but still considered within normal limits.

On the other hand, in regards to the hyperdense opacification seen in CT scan at the left maxillary sinus, the MRI confirmed that there was complete opacification of the left maxillary antrum, although it was not seen in the tomography and OPG. Her physician kept her on the same medications regime without any change.

In September 2018, the patient encountered severe headache and severe throbbing pain related to tooth #24, especially during traveling by airplane mainly at landing, she took pain killers which relieved the pain. After two months in another trip, also during landing, she encountered severe pain which continued even after taking medications (pain killers, tramadol, and morphine). She then visited a maxillofacial surgeon who did Tomography for her and informed her that everything was within normal. Then she visited a Periodontist who referred the pain to the sinus blockage and advised her to go to ENT specialist. As the pain in the tooth continued she visited an Endodontist who after x-ray examination found that tooth # 24 had shallow class II composite restoration, it was vital with delayed response to cold, with no caries or recurrent caries and a dropping sinus. Accordingly, the endodontist did

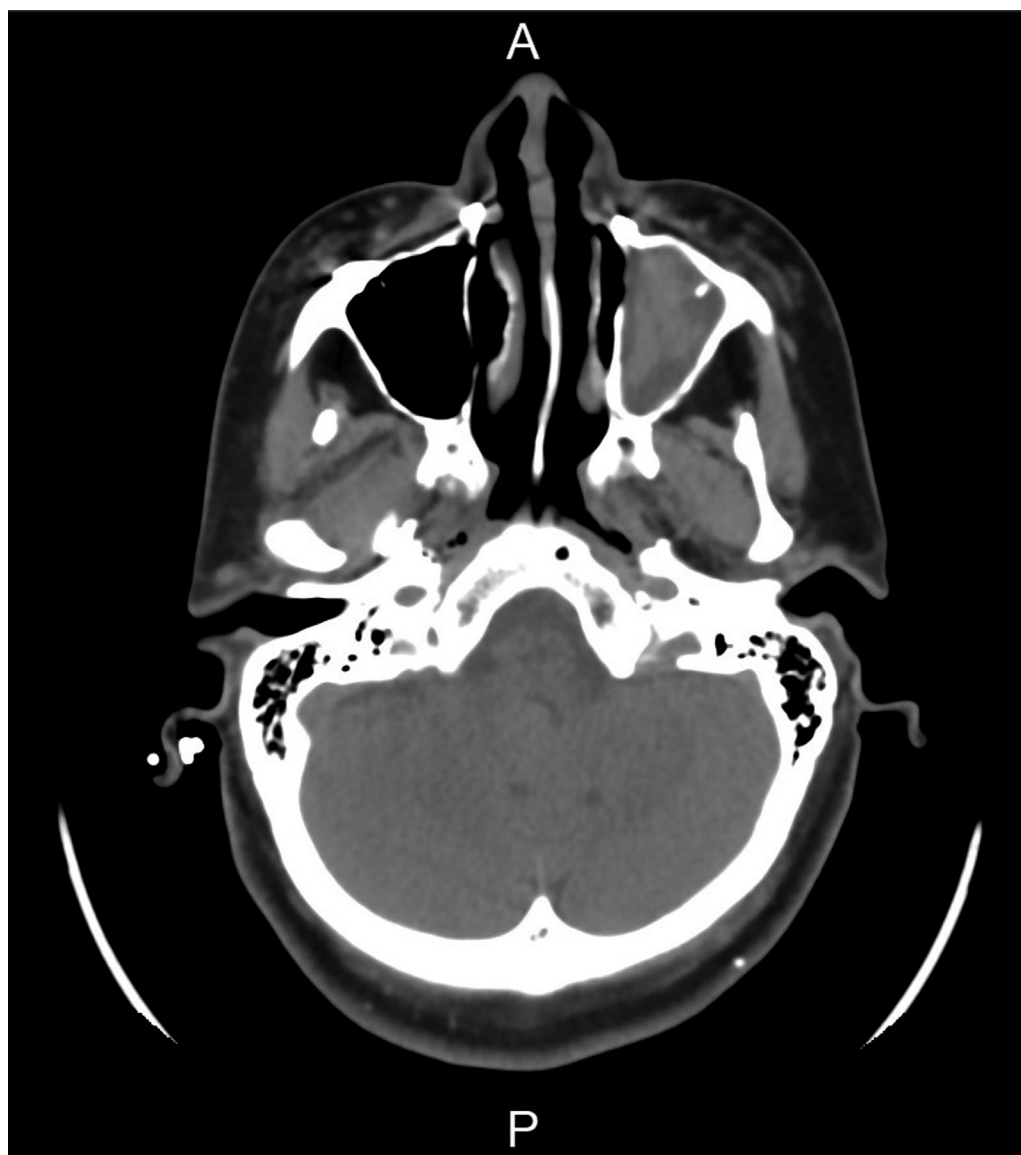

Fig. 2. Axial CT image of the skull showing complete opacification with hyperdense fluid content of the left maxillary sinus.

not initiate any treatment for her. However, tooth pain continued with severe headache that was not controlled neither by over the counter medications nor by controlled drugs. Therefore, Root Canal Treatment (RCT) was performed for tooth #24; however, the pain persisted so she was given steroids by the endodontist, although the pain subsided for one day; however, it returned and was continuous for another two weeks. The severity of the headache increased and persisted for 21 days. Then she went to the ER clinics in our institute, where a second CT was taken by the on-call neurologist that showed complete opacification with hyperdense fluid content of the left maxillary sinus (Figs. 1 and 2). However, both orbits appear symmetrical, with no definite abnormality on the left side. Both sinuses were blocked, but the left was completely obliterated. Accordingly, the on-call neurologist consulted the on-call ENT specialist, where both diagnosed the situation as Silent Sinus Syndrome SSS. Accordingly, the treatment of choice was Functional endoscopic sinus surgery (FESS), which was done to her under general anesthesia by ENT specialist in January 2019. Post-Operative instructions were given, which included; 2 weeks sick leave, no nasal trauma, regular diet, no heavy activity, and a follow up visit after seven days in the clinic. the medications: zinnat 500 mg tab

q12hrs for 7 days, panadol 500 mg to have 1000 mg 2 tabs q6hrs, sterimar nasal spray q12hrs for 14 days and rhinocort nasal spray q12hrs for 14 days.

Follow up was done after nine months of the FESS, CBCT was taken, and images reveal all paranasal sinuses to be clear with no evidence of enlargement of soft tissue lining or fluid accumulation.

3. Discussion

Silent Sinus Syndrome (SSS) is a spontaneous unilateral maxillary atelectasis with complete or partial opacification of the sinus [1]. It is considered a rare condition that is usually misdiagnosed because of the difficulty of recognition of sinus symptoms and complaints [1].

The Silent Sinus Syndrome progresses slowly, gradually, and progressively and could occur over weeks to years [4], as is the case in our patients here as she started her complained in 2009 and the final diagnosis was reached in 2018 with some signs of development of the situation. Although SSS has never been known to have a sudden or an immediate onset, some authors have reported progression occurring overnight [15]. The disease is typically presented

in adult in the third and fifth decade and has no predilection for sex [4]. However, some cases of children have also been reported; the youngest patient of the SSS described in the literature is seven years old [16].

The signs and symptoms of SSS include: Enophthalmos, hypoglobus, apparent retraction of the eyelid which is secondary to dystopia of the lid and globe, lid lag and lagophthalmos, ocular motility is usually preserved, but gaze can be restricted, headache, sinking of eye or pulling sensation of eye, orbital asymmetry, deepening of superior sulcus, diplopia, eyelid ptosis, exophthalmos of contralateral eye, audible clicking sound with blinking because air is trapped in the conjunctival recess, painless and mild non-specific ache in the orbital tissues, or dental pain [1,17]. The patient presented here, had some of the typical symptoms like; hypoglobus, headaches, sinking of the eye, eyelid ptosis, and dental pain.

The Endoscopic observation include: septal deviation toward the affected sinus, enlargement of the middle meatus and deformation of the medial maxillary wall Rose et al., had suggested that this nasal conformation might be a predisposing factor [18]. The patient presented here had nasal septum deviation on the left side, which increased by the age of 35, to be as S-shaped from both sides.

Radiographic evaluation of the paranasal sinuses and orbital characteristics is essential to confirm the diagnosis. The classical radiographic findings observed are a fully developed maxillary sinus with partial or complete opacification, an ostiomeatal occlusion with lateralisation of the uncinate process, enlargement of the ipsilateral middle meatus with or without lateralisation of the middle turbinate, and a loss of bone density in the sinus wall that ranges from thinning to dehiscence [2]. The patient presented here showed complete opacification with hyperdense fluid content of the left maxillary sinus. The most characteristic image feature of SSS is the inward retraction of the sinus wall, which is presented in here.

Functional endoscopic sinus surgery (FESS) is the standard gold treatment to arrest the progression of the disease, and the position of the orbital floor can improve following surgery, which was the treatment of choice for the patient present here. It is a minimally invasive technique which uses nasal endoscopes to enlarge the nasal drainage pathways of the paranasal sinuses and entails a maxillary antrostomy that's performed by completely removing the lateralized uncinate process and widely opening the natural sinus ostium, which improve maxillary sinus drainage and relieve obstruction to prevent disease progression and restore normal orbital anatomy. After the treatment, the patient stated that overall the procedure was comfortable and all the symptoms she was suffering from as headaches, teeth pain, facial numbness and droopy eye were resolved completely after 2 months postoperatively.

Although the patient presented here showed most of the symptoms exist in the literature, in addition, most of her CT scans and MRI indicated the possibility of SSS; however, she was not correctly diagnosed except after the complete obliteration of the sinus and frequent visits with numerous specialists which indicate the difficulty of obtaining the correct diagnosis by a single specialist.

4. Conclusion

Knowledge of the signs and features of SSS will result in accurate diagnosis. Suspected cases of silent sinus syndrome require prompt ear, nose and throat referral for consideration of definitive diagnosis and surgical management. Nasal endoscopy and clinical evaluation are essential for the diagnosis, while CT imaging consider the gold standard for its diagnosis. Deviated nasal septum surgery may consider a causative factor of obstruction of the sinus. In patients with visual or facial neurological symptoms, neurologists should seek imaging evidence of sinus inflammation and fluid collection. painless enophthalmos may be the presenting symptom of obstructive

maxillary sinus disease with secondary orbital floor destruction. FESS is the gold standard treatment to arrest the progression of the disease and the position of the orbital floor can improve following surgical treatment. The recurrence is high, So, the patient should be informed and reinforced to take protocol sinus protection: avoid dust, wearing the mask, using sinus wash and follow up every 6 months. Silent sinus syndrome should remain a diagnostic consideration for patients with spontaneous enophthalmos and hypoglobus, even in the absence of maxillary sinus opacification. In addition, all the specialist in the medical or the dental fields should communicate well together to reach an earlier diagnosis of the situation.

Declaration of Competing Interest

The authors report no declarations of interest.

Funding

None.

Ethical approval

Case Report, Approval.
(King Saud University (KSU) Institutional Review Board (IRB))
Ref. No. 20/0318/IRB.

Consent

Written informed consent was obtained from the patient for publication of this case report and accompanying images. A copy of the written consent is available for review by the Editor-in-Chief of this journal on request.

Author's contribution

Nahid Y. Ashri: Write, collect data, review.
Nouf S. Alsaloom: Write, collect data, follow up the patient.

Registration of research studies

1. Name of the registry: ClinicalTrials.gov.
2. Unique identifying number or registration ID: [NCT04388345](https://clinicaltrials.gov/ct2/show/NCT04388345).
3. Hyperlink to your specific registration (must be publicly accessible and will be checked): <https://clinicaltrials.gov/ct2/results?cond=Silent+Sinus+Syndrome&term=&cntry=&state=&city=&dist=,> <https://clinicaltrials.gov/ct2/show/NCT04388345?cond=Silent+Sinus+Syndrome&draw=2&rank=1>.

Guarantor

Nahid Ashri.

Provenance and peer review

Not commissioned, externally peer-reviewed.

References

- [1] Alistair R.M. Cobb, et al., Silent sinus syndrome, *Br. J. Oral Maxillofac. Surg.* 50 (6) (2012) e81–e85.
- [2] Paolo Bossolesi, et al., The silent sinus syndrome: diagnosis and surgical treatment, *Rhinology* 46 (4) (2008) 308.
- [3] Denisse E. Guillen, Paulette M. Pinargote, Juan C. Guarderas, The silent sinus syndrome: protean manifestations of a rare upper respiratory disorder revisited, *Clin. Mol. Allergy* 11 (1) (2013) 5.

- [4] Roula Hourany, et al., Silent sinus syndrome: an acquired condition, *Am. J. Neuroradiol.* 26 (9) (2005) 2390–2392.
- [5] C.N. Soparkar, J.R. Patrinely, M.J. Cuaycong, et al., The silent sinus syndrome. A cause of spontaneous enophthalmos, *Ophthalmology* 101 (4) (1994) 772–778.
- [6] Kaveh Vahdani, Geoffrey E. Rose, Bilateral silent sinus (imploding antrum) syndrome, *Ophthalm. Plast. Reconstr. Surg.* 35.3 (2019) e67–e69.
- [7] H. Babar-Craig, et al., Spontaneous silent sinus syndrome (imploding antrum syndrome): case series of 16 patients, *Rhinology* 49 (3) (2011) 315.
- [8] Samuel Tribich, Colin J. Mahoney, Nicholas W. Davies, Silent sinus syndrome: an unusual case of facial numbness, *Pract. Neurol.* 18 (6) (2018) 494–496.
- [9] William A. Numa, et al., Silent sinus syndrome: a case presentation and comprehensive review of all 84 reported cases, *Ann. Otol. Rhinol. Laryngol.* 114 (9) (2005) 688–694.
- [10] Jeffrey D. Suh, et al., Bilateral silent sinus syndrome, *Ear Nose Throat J.* 91 (12) (2012) E19–E21.
- [11] Salah Salman, et al., Chronic maxillary atelectasis, *Ann. Otol. Rhinol. Laryngol.* 106 (2) (1997) 109–116.
- [12] Clotilde De Dorlodot, et al., Chronic maxillary atelectasis and silent sinus syndrome: two faces of the same clinical entity, *Eur. Arch. Oto-rhino-laryngol.* 274 (9) (2017) 3367–3373.
- [13] Y. Najaf, A. AlTerki, A. Al-Buluoshi, The silent sinus syndrome: a collaborative approach between rhinologists and oculoplastics—case report and literature review, *Otolaryngol (Sunnyvale)* 5 (2015) 179, <http://dx.doi.org/10.4172/2161-119X.1000179> Page 2 of 4 *Otolaryngol (Sunnyvale)* ISSN: 2161-119X OCR, an open access journal Volume 5• Issue 1• 1000179, and painless [7, 9]. These orbital symptoms can suggest a possible neuro-ophthalmic disorder (2015): 3.
- [14] R.A. Agha, M.R. Borrelli, R. Farwana, K. Koshy, A. Fowler, D.P. Orgill, For the SCARE Group, The SCARE 2018 statement: updating consensus Surgical Case REport (SCARE) guidelines, *Int. J. Surg.* 60 (2018) 132–136.
- [15] Charles N.S. Soparkar, James R. Patrinely, Joseph K. Davidson, Silent sinus syndrome—new perspectives? *Ophthalmology* 111 (2) (2004) 414–415.
- [16] David T. Chang, Mai Thy Truong, A child with silent sinus syndrome and spontaneous improvement after sinus surgery, *Int. J. Pediatr. Otorhinolaryngol.* 78 (11) (2014) 1993–1995.
- [17] Geoffrey E. Rose, et al., Clinical and radiologic characteristics of the imploding antrum, or “silent sinus,” syndrome, *Ophthalmology* 110 (4) (2003) 811–818.
- [18] Geoffrey E. Rose, Valerie J. Lund, Clinical features and treatment of late enophthalmos after orbital decompression: a condition suggesting cause for idiopathic “imploding antrum”(silent sinus) syndrome, *Ophthalmology* 110 (4) (2003) 819–826.

Open Access

This article is published Open Access at [sciencedirect.com](https://www.sciencedirect.com). It is distributed under the [IJSCR Supplemental terms and conditions](#), which permits unrestricted non commercial use, distribution, and reproduction in any medium, provided the original authors and source are credited.