

# Subdural Metastasis of Prostate Cancer

Andre Nzokou<sup>1</sup> Elsa Magro<sup>1</sup> François Guilbert<sup>2</sup> Jean Yves Fournier<sup>1,3</sup> Michel W. Bojanowski<sup>1</sup>

<sup>1</sup> Department of Surgery, Section of Neurosurgery, Centre Hospitalier de l'Université de Montréal (CHUM), Montréal, Quebec, Canada

<sup>2</sup> Department of Radiology, Section of Neurology, Centre Hospitalier de l'Université de Montréal (CHUM), Montréal, Quebec, Canada

<sup>3</sup> Department of Neurosurgery, Hôpital Cantonal, St. Gall, Switzerland

Address for correspondence Michel W. Bojanowski, MS, FRCSC, Department of Surgery, Section of Neurosurgery, Centre Hospitalier de l'Université de Montréal (CHUM), Hôpital Notre-Dame, 1560 rue Sherbrooke Est, Montréal, QC, Canada H2L 4M1 (e-mail: michel.bojanowski.chum@ssss.gov.qc.ca).

J Neurol Surg Rep 2015;76:e123–e127.

## Abstract

Dural metastasis from prostate cancer is rare and may mimic a subdural hematoma (SDH). Preoperatively diagnosis may be difficult and only reveal its presence during surgery. We present such a case and review the literature to identify common characteristics. A 65-year-old man presented with headache, confusion, and progressive right upper limb weakness. Past history included a prostate adenocarcinoma with bone metastasis 3 years earlier. Head computed tomography (CT) scan without contrast revealed a multinodular bilateral hyperdense extra-axial lesion interpreted as acute SDH. At surgery planned for SDH drainage no blood was found; instead there was an *en plaque* subdural yellowish tumor. Histopathologic examination was consistent with metastatic adenocarcinoma of the prostate. We found 11 cases reported as dural metastasis of prostate cancer mimicking SDH. Surgery was performed on nine cases with no suspicion of dural metastasis. On preoperative nonenhanced CT scan images, three types of image patterns can be described: a nodule in SDH, multinodular metastasis surrounded by SDH, and large *en plaque* subdural tumor. The latter group consists of those cases where no blood but rather an *en plaque* subdural tumor was found at surgery. Even though rare, dural metastasis should be considered among the differential diagnoses in a patient known for prostate cancer.

## Keywords

- ▶ subdural hematoma
- ▶ metastasis
- ▶ prostate cancer
- ▶ dural
- ▶ surgical removal

## Introduction

Carcinomatous infiltration of the dura from nonneurologic cancer is rare. It has been found at autopsy in 8 to 9% of cases of extraneural malignancy.<sup>1</sup> Laigle-Donadey et al<sup>2</sup> found in a series of 198 cases of dural metastasis that the tumor types metastasizing to the dura mater are cancers of the prostate (19.5%), breast (16.5%), lung (11%), and stomach (7.5%); thus prostate cancer is evidently more susceptible to spread to the dura. Tremont-Luktas et al<sup>3</sup> reported that in 118 cases of brain metastasis of prostate cancer, 19 spread to the dura. In a few cases, the diagnosis of

dural metastasis was made following subdural bleeding. However, in other cases no blood was found during surgery, thus revealing the mimicking appearance of the subdural metastasis. Recognition of this latter occurrence may help determine the best management for each individual case.

## Material and Methods

We report a case of dural metastasis of prostate cancer mimicking subdural hematoma (SDH). We reviewed the English and French literature for cases presenting with

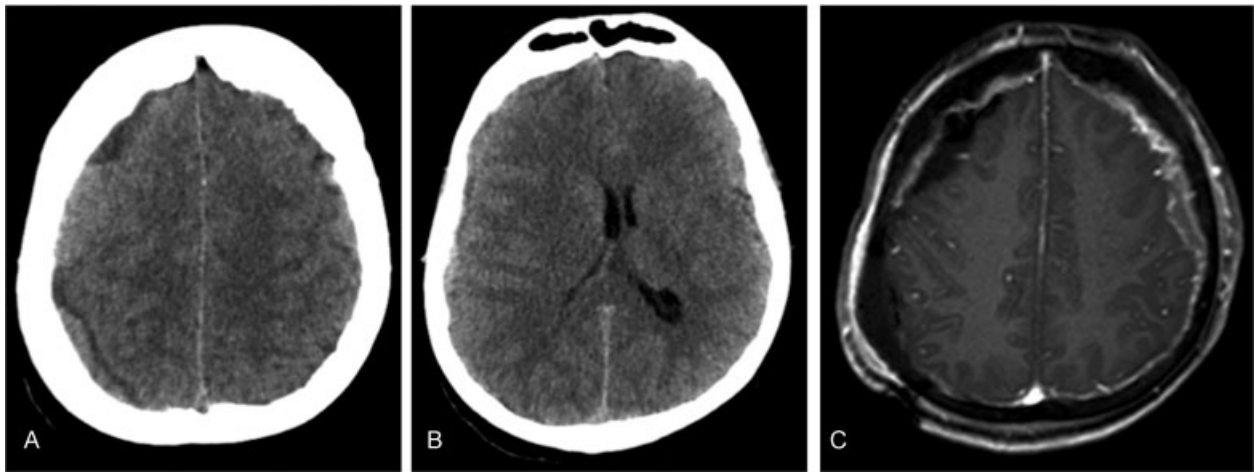
received  
November 13, 2014  
accepted after revision  
February 10, 2015  
published online  
May 13, 2015

DOI <http://dx.doi.org/10.1055/s-0035-1549224>.  
ISSN 2193-6366.

© 2015 Georg Thieme Verlag KG  
Stuttgart · New York

License terms





**Fig. 1** (A) Axial nonenhanced computed tomography scan of the head without contrast showing a multinodular bilateral hyperdense extra-axial lesion with (B) a midline shift of 4 mm to the right. This image was interpreted as an acute subdural hematoma. (C) Postoperative magnetic resonance imaging showed prominent irregular enhancing tissue along the dura consistent with bilateral dural metastasis.

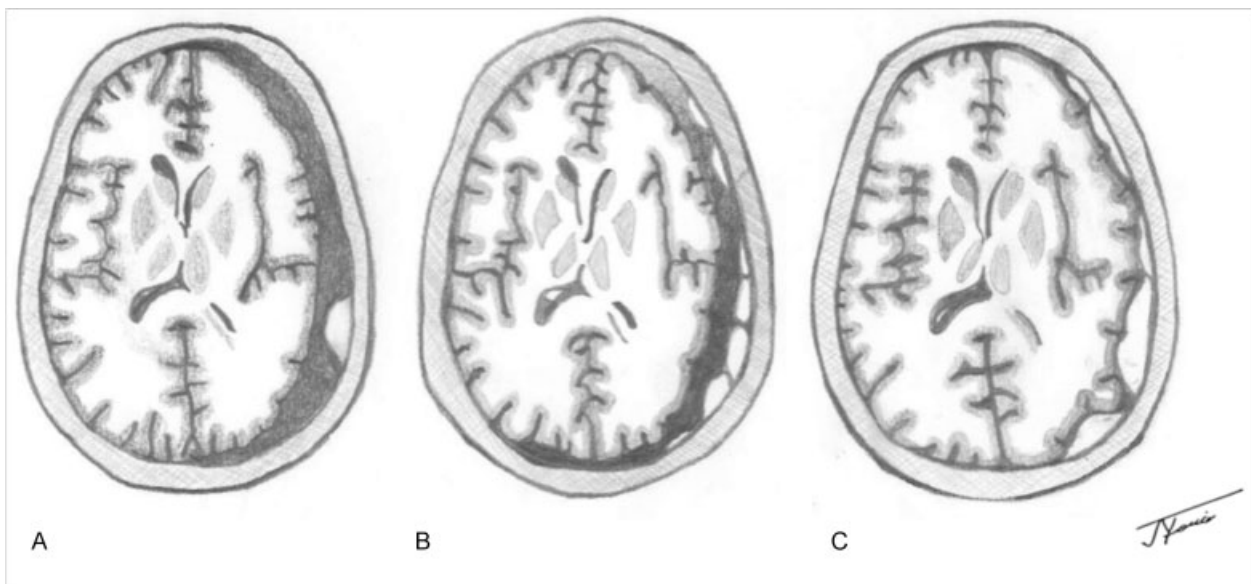
suspected SDH to ascertain common clinical and imagery characteristics of metastasis mimicking SDH.

## Results

### Illustrative Case

A 65-year-old man was admitted to the emergency department presenting with headache, confusion, and progressive right upper limb weakness. He also reported a recent fall at home. Past history included a metastatic prostate adenocarcinoma 3 years earlier, for which he underwent hormonal therapy. His prostate-specific antigen (PSA) fell from 377 to 190  $\mu\text{g/L}$ . Pelvic lymph nodes and bone metastasis were diagnosed 3 years ago. On initial examination he was mildly confused, with a drift of his left upper limb. Computed tomography (CT) scan of the head without contrast revealed a multinodular bilateral hyperdense extra-axial lesion ( $\rightarrow$  **Fig. 1A**) with a midline shift of 4 mm to the

right ( $\rightarrow$  **Fig. 2B**). This image was interpreted as acute SDH. The patient was initially observed. The next day he became more confused and progressively nonresponsive. A second CT scan showed progress of the midline shift to 7.8 mm. A left parietal burr hole was performed for SDH drainage. Upon opening the dura, no blood was found. Instead there was an obvious subdural tumor. A craniotomy was performed, revealing an *en plaque* frontoparietal temporal subdural yellowish tumor, with no cortical involvement. The bone had an abnormal appearance, suggesting bone metastasis. The tumor was excised as much as possible including the adjacent dura. The involved bone was not replaced. Postoperative magnetic resonance imaging (MRI) showed prominent irregular enhancing tissue along the dura consistent with bilateral dural metastasis ( $\rightarrow$  **Fig. 1C**). The patient progressively recovered and left the hospital at day 15 with little weakness of the arm. Retrospectively, we suspect that the clinical deterioration and the rapid increase of the midline shift might be



**Fig. 2** The three types of image patterns on computed tomography scan. (A) Nodule with subdural hematoma (SDH). (B) Multinodular metastasis with SDH. (C) Large *en plaque* subdural tumor.

**Table 1** Reported cases of dural metastasis of prostate cancer presenting as or mimicking subdural hematoma

Study	Age, y	History of trauma	Clinical signs	SDH description	CT scan	MRI	Other locations	Surgery	Surgery finding	Pathologic diagnosis	Type of image pattern <sup>a</sup>	Outcome
Meara et al <sup>9</sup>	62	No	Epistaxis; cognitive impairment	Acute on chronic	Nodular hyperdense and hypodense extra-axial collection	No	NA	Burr hole; collection evacuation	Hematoma and thickening of dura	On dura matter	A	Death 4 d postoperatively
George et al <sup>8</sup>	72	No	Confusion	Chronic	Hypodense lentiform extra-axial collection	Dural enhancement; nodular lesion	NA	Burr hole; collection evacuation	Hematoma	On hematoma membrane	B	Death 7 d postoperatively
Yu et al <sup>11</sup>	62	No	Upper limbs weakness; convulsion	Acute	Bilateral hyperdense to isodense extraaxial collection	Diffuse enhanced meningeal thickening; nodular areas; enhancing bilateral dural soft tissues	Bone, lung, liver	No surgery	-	-	C	NA
Dorsi et al <sup>7</sup>	71	Yes	Headaches; word-finding; instability; apraxia	Chronic	Hypodense lentiform extra-axial collection	Extensive dural enhancement; nodular lesions	NA	Craniotomy; tumor resection; collection evacuation	Yellow fluid under high pressure; thickening of dura with nodularity	On dura matter	B	NA
Dols et al <sup>6</sup>	54	No	Headaches; nausea; Facial palsy	Acute on chronic	Isodense extraaxial collection and edema	Extensive dural enhancement	Bone	No surgery	-	-	C	Death at day 3 of hospitalization
Patil et al <sup>10</sup>	71	Yes	Headaches; dizziness	Subacute on chronic	Isodense to hypodense collection	Postoperatively: homogeneous enhanced subdural lesion	NA	Burr hole transformed in craniotomy; tumor biopsy	<i>En plaque</i> diffuse subdural tumor; no blood	On subdural tumor	C	25 mo
Cheng et al <sup>5</sup>	72	No	Headaches; hemiparesis	Chronic	Hypodense extraaxial collection and edema	Postoperatively: enhancing lesion along the dura matter, extending bilaterally from the skull base	Bone	Surgery for hematoma (no precision)	Diffuse thickening; yellowish tumor; no blood	On subdural tumor and dura matter	C	4 mo
Tomlin and Alleyne <sup>13</sup>	61	Yes	Headaches; cognitive impairment	Subacute	Isodense extraaxial collection	Postoperatively: enhancing lesion along the dura matter	Bone, lymph node	Burr hole transformed in craniotomy; tumor biopsy	Diffuse thickening of dura; confluent epidural and subdural tumor; no blood	On subdural tumor and dura matter	C	3 mo
Oka et al <sup>12</sup>	60	No	Headaches; cognitive impairment; hemiparesis	Acute	Hypodense multilobular crescent	No	Bone	Craniotomy for acute hematoma	Subdural yellowish tumor; no blood	On subdural tumor	C	NA

(Continued)

**Table 1** (Continued)

Study	Age, y	History of trauma	Clinical signs	SDH description	CT scan	MRI	Other locations	Surgery	Surgery finding	Pathologic diagnosis	Type of image pattern <sup>a</sup>	Outcome
Bucci and Farhat <sup>4</sup>	62	No	Headaches; confusion	Subacute	Isodense fluid collection	No	NA	Craniotomy for subacute hematoma	Thin membrane-covered hematoma	On hematoma membrane	B	Dead at 4 d postoperatively
	63	No	Confusion; lower limb weakness	Chronic	Hypodense subdural collection	No	Bone	Craniotomy for chronic hematoma	Hematoma with membrane	On hematoma membrane	A	NA
Our case	65	Yes	Confusion; upper limb weakness	Subacute	Bilateral multinodular hyperdense extra-axial collection	Postoperatively: prominent enhancing lesion along the dura matter	Bone	Burr hole transformed in craniotomy	Diffuse thickening; yellowish tumor; no blood	On subdural tumor, dura matter, and bone	C	5 mo

Abbreviations: CT, computed tomography; NA, not available; NMR, nuclear magnetic resonance; SDH, subdural hematoma. <sup>a</sup>A, single nodular; B, multinodular; C, *en plaque*.

due to an impaired brain venous drainage secondary to the extensive dural metastasis. Histopathologic examination of the obtained tissue was consistent with metastatic adenocarcinoma of the prostate. Due to the extensive generalized bone metastasis that was nonresponsive to previous chemotherapy, no further treatment was undertaken. The patient died 5 months later.

**Review of Reported Cases**

In the literature we found 11 cases<sup>4-11</sup> (►Table 1) reported as dural metastasis of prostate cancer presenting as or mimicking an SDH. Between the first diagnosis of prostate cancer and the discovery of the dural metastasis, the time ranged from 3 months to 7 years (mean: 33 months); the mean age of these patients was 64.5 years. All patients (when data were known) presented in the advanced stage with metastasis. No correlation was found between an anterior history of head trauma and the finding of blood on surgery. Two cases were not operated on because of the obvious evidence of dural metastasis, seen on CT scan and MRI. In all the other cases surgery was performed with no suspicion of dural metastasis. In five cases no blood was found; there was an *en plaque* subdural tumor. In these cases the burr hole or craniotomy that had been preoperatively planned had to be converted into a larger craniotomy. When reviewing the preoperative nonenhanced CT scan images of all of the 11 patients, we can describe three types of image patterns (►Fig. 2A-C): a nodule in SDH (two cases),<sup>4,9</sup> multinodular metastasis surrounded by SDH (three cases),<sup>4,7,8</sup> and large *en plaque* subdural tumor (six cases).<sup>5,6,10-13</sup> This latter group consists of those cases where no blood was found at surgery.

**Discussion**

Brain metastasis secondary to prostate cancer is rare, as is dural metastasis. However, prostate cancer appears to be the most common origin of dural metastases.<sup>2,14</sup> In their large series on dural metastases, Laigle-Donadey et al<sup>2</sup> observed that dural metastasis originated from the direct extension of skull metastasis in 57% of cases and from a hematogenous route in 43% of cases. Another potential mechanism for skull and subdural metastases of prostate cancer could be retrograde spread through the vertebral venous plexus. It is also known that dural metastasis can present as, or mimic, SDH.<sup>4,5,7-10,12,13</sup> Including the present case, 12 cases have been reported.<sup>4-10,12,13</sup> Of the 10<sup>4,5,7-10,12,13</sup> operated cases, the preoperative diagnosis of subdural metastasis was missed. In five cases<sup>5,10-13</sup> no blood was found during surgery; instead there was an *en plaque* subdural tumor. All 12 cases were known for prostate cancer with most of them in an advanced stage with bone or lymph node metastasis. In fact, as shown in ►Table 1, prognosis was grim in all cases regardless of whether there was trauma or not, with survival ranging from a few days to 5 months, except for one patient who survived for 25 months.

The time between the first diagnosis of prostate cancer and the discovery of the dural metastasis was highly variable ranging from 3 months to 7 years.

The preoperative appearance on the CT scan of the subdural collection was nodular or multinodular, associated at times with

This document was downloaded for personal use only. Unauthorized distribution is strictly prohibited.

brain edema. The bone views often revealed diffuse sclerotic changes of the skull suggestive of bone metastasis. Including our case, only one other case<sup>11</sup> was bilateral. Also, on postoperative MRI, there were diffuse pachymeningeal thickening with enhancement and areas of nodular enhancing soft tissues.

Reexamining the CT scans provided in the literature of these 12 cases, we identified three patterns (► **Fig. 2**) that could lead us to a more accurate diagnosis upon admission: (1) a nodule in an SDH<sup>4,9</sup> (► **Fig. 2A**), (2) multinodular metastasis surrounded by an SDH<sup>4,7,8</sup> (► **Fig. 2B**), and (3) an extensive *en plaque* subdural tumor<sup>5,6,10–13</sup> (► **Fig. 2C**) as in our case. Types 1 and 2 may be particularly misleading because a burr hole to drain the blood may miss the tumor. In type 3 cases, where unexpectedly no blood is found, a larger craniotomy reveals an extensive tumor not amenable to surgical treatment.

Knowing these imagery features in advance helps us to be more vigilant and thus make a more accurate diagnosis to choose the right course of treatment and possibly avoid unnecessary surgery. Indeed, of the 10 patients who underwent surgery, 6 died within 4 days to 3 months.<sup>4,5,8–10</sup> This suggests that dural metastasis secondary to prostate cancer occurs at an end stage of advanced disease.

## Conclusion

Although rare, dural metastasis should be considered among the differential diagnoses in a patient known for prostate cancer, particularly with bone metastasis. The nodular features of the subdural collection on a nonenhanced CT scan should alert us to the possibility of subdural metastasis and prompt us to investigate further. This can lead to better management and possibly avoid unnecessary surgery. Simply being aware of the possibility that dural metastasis may mimic hematoma in cases of metastatic prostate cancer may help evaluate the indication for surgery, especially in this group of patients often harboring a poor prognosis.

## References

- 1 Meyer PC, Reah TG. Secondary neoplasms of the central nervous system and meninges. *Br J Cancer* 1953;7(4):438–448
- 2 Laigle-Donadey F, Taillibert S, Mokhtari K, Hildebrand J, Delattre JY. Dural metastases. *J Neurooncol* 2005;75(1):57–61
- 3 Bobustuc G, Lagos GK, Lolas K, Kyritsis AP, Puduvali VK. Brain metastasis from prostate carcinoma: The M.D. Anderson Cancer Center experience. *Cancer* 2003;98(2):363–368
- 4 Bucci MN, Farhat SM. Metastatic adenocarcinoma of the prostate as a cause of subdural hematoma. *J Urol* 1986;135(4):803–804
- 5 Cheng YK, Wang TC, Yang JT, Lee MH, Su CH. Dural metastasis from prostatic adenocarcinoma mimicking chronic subdural hematoma. *J Clin Neurosci* 2009;16(8):1084–1086
- 6 Dols MC, Calle SG, Chamorro EV, Díaz IA, Pino AM, García JA. Dural metastases with subdural hematoma from prostate cancer. *Onco- logia* 2005;28(8):407–411
- 7 Dorsi MJ, Zenonos G, Hsu W, Huang J. Dural prostate adenocarcinoma metastasis with subdural hematoma mimicking the appearance of an epidural hematoma. *Clin Neurol Neurosurg* 2010; 112(6):501–504
- 8 George KJ, Lau A, Ellis M, Kiehl TR, Fehlings MG. Metastatic coagulopathic subdural hematoma: A dismal prognosis. *Surg Neurol Int* 2012;3:60
- 9 Meara ACO, Mahasneh T, Wilson P, Ons BI, Alkhawaja D. Dural prostate metastasis resembling a chronic subdural haematoma. *J Surg Case Rep* 2012;5:7
- 10 Patil S, Veron A, Hosseini P, et al. Metastatic prostate cancer mimicking chronic subdural hematoma: a case report and review of the literature. *J La State Med Soc* 2010;162(4):203–205
- 11 Yu W, Sitt C, Cheung TCY. Dural metastases from prostate cancer mimicking acute sub-dural hematoma. *Emerg Radiol* 2012;19(6): 549–552
- 12 N'Dri Oka D, Varlet G, Boni N, Broalet E, Boukassa L, Zeze VBA. Métastase durale d'un adénocarcinome sous-dural aigu intracranien à propos d'une observation. *J Neuroradiol* 2013;27(4): 282–284
- 13 Tomlin JM, Alleyne CH. Transdural metastasis from adenocarcinoma of the prostate mimicking subdural hematoma: case report. *Surg Neurol* 2002;58(5):329–331; discussion 331
- 14 Nayak L, Abrey LE, Iwamoto FM. Intracranial dural metastases. *Cancer* 2009;115(9):1947–1953