



Occult Macular Dystrophy

Işıl Sayman Muslubaş, Serra Arf, Mümin Hocaoğlu, Hakan Özdemir, Murat Karaçorlu
İstanbul Retina Institute, İstanbul, Turkey

Summary

Occult macular dystrophy is an inherited macular dystrophy characterized by a progressive decline of bilateral visual acuity with normal fundus appearance, fluorescein angiogram and full-field electroretinogram. This case report presents a 20-year-old female patient with bilateral progressive decline of visual acuity for six years. Her visual acuity was 3-4/10 in both eyes. Anterior segment and fundus examination, fluorescein angiogram and full-field electroretinogram were normal. She could read all Ishihara pseudoisochromatic plates. Fundus autofluorescence imaging was normal. There was a mild central hyporeflectance on fundus infrared reflectance imaging in both eyes. Reduced foveal thickness and alterations of the photoreceptor inner and outer segment junction were observed by optical coherence tomography in both eyes. Central scotoma was also found by microperimetry and reduced central response was revealed by multifocal electroretinogram in both eyes. These findings are consistent with the clinical characteristics of occult macular dystrophy.

Keywords: Occult macular dystrophy, optical coherence tomography, microperimetry, multifocal electroretinogram

Introduction

Occult macular dystrophy (OMD) is an inherited macular dystrophy characterized by progressive bilateral vision loss despite normal fundus appearance.¹ Fundus fluorescein angiogram (FFA) and full-field electroretinogram (ERG) are normal, whereas results of multifocal ERG (mfERG) of the central retina are markedly reduced.^{1,2} Foveal thinning and disruptions of the photoreceptor inner and outer segment (IS/OS) junction are observed on spectral domain optical coherence tomography (SD-OCT). In many patients, disruptions of the photoreceptor layer detected by SD-OCT are correlated with visual acuity and disease progression.³ Microperimetry (MP) is a visual field technique used in macular diseases to determine retinal sensitivity.⁴ The method was developed to identify fixation alterations due to scotoma and vision loss in conditions involving the central retina, and can be utilized for this purpose in OMD patients.^{5,6,7} On fundus infrared reflectance (IR) imaging, OMD patients exhibit central hyporeflectance which becomes more pronounced with disease progression.⁸ Abnormalities are not apparent on fundus autofluorescence (FAF) imaging in most OMD patients, although mild central hyperautofluorescence can be observed in a minority of patients.^{8,9}

In this case report, we aimed to present the clinical characteristics and diagnostic methods of a patient we diagnosed with OMD.

Case Report

A 20-year-old female patient with a 6-year history of progressive bilateral vision loss was referred to our clinic. The patient had no known systemic disease, previous trauma, family history, history of drug or cigarette use, or consanguineous marriage in her family. Her visual acuity was 3-4/10 in both eyes; intraocular pressure was 11 mmHg in the right eye and 13 mmHg in the left eye. No pathologies were detected during anterior segment examination. Fundus examination revealed no pathologies other than mild retinal vessel tortuosity (Figure 1A and 1B). Both eyes appeared normal on FAF imaging (Figure 2A and 2B). Mild central hyporeflectance was observed in both eyes on fundus IR imaging (Figure 3A and 3B). FFA was normal. Foveal thickness was determined by OCT thickness profile analysis as 155 µm and 188 µm in the right and left eyes, respectively. Disruption of the photoreceptor IS/OS junction was observed. The extension of the IS/OS band disruption on the horizontal axis was measured as 696 µm in the right and 348

Address for Correspondence: Murat Karaçorlu MD, İstanbul Retina Institute, İstanbul, Turkey

Phone: +90 212 231 31 21 E-mail: mkaracorlu@gmail.com **Received:** 05.06.2014 **Accepted:** 03.09.2014

This article is also published in Turkish under doi:10.4274/tjo.26234 pages 2016;46:91-94

©Turkish Journal of Ophthalmology, Published by Galenos Publishing.

This is an open-access article distributed under the terms of the Creative Commons Attribution License, which permits unrestricted use, distribution, and reproduction in any medium, provided the original work is properly cited.

µm in the left eye (Figure 4A and 4B). On MP analysis both eyes exhibited relatively unstable fixation which was more pronounced in the right eye, and areas of absolute scotoma consistent with OCT were observed. Retinal sensitivity in the central 20° field of the macula was measured as 13.9 dB in the right and 13.5 dB in the left eye (Figure 5A and 5B). Full-field ERG was normal, but mfERG revealed a bilateral reduction in central response which was more pronounced in the right eye (Figure 6A and 6B).

Discussion

OMD is an inherited macular dystrophy, called occult because the fundus appears normal despite macular dysfunction. OMD was first described by Miyake et al.¹ and although it is autosomal dominantly inherited, sporadic cases have also been reported.

Many studies have reported that the age at onset for OMD ranges widely, from 6 to 81 years.⁹ In our case, the patient’s vision loss began at age 14 and she was diagnosed at age 20.

As OMD is a central retinal disease, patients’ full-field ERG results are normal, while responses in focal macular ERG and mfERG are markedly reduced.^{1,2} In addition, measuring central retinal sensitivity by MP may reveal scotoma or fixation loss in OMD patients.⁵ As described in the literature, our patient had normal full-field ERG results, but on mfERG she exhibited a bilateral reduction in central response that was more pronounced in the right eye. On MP we detected relatively unstable fixation in both eyes which was also more pronounced in the right eye. Reduced retinal sensitivity was observed in the central 8° field of the maculae of both eyes.

Structural changes in the photoreceptor layer in OMD patients are easily detected by SD-OCT. Many studies using

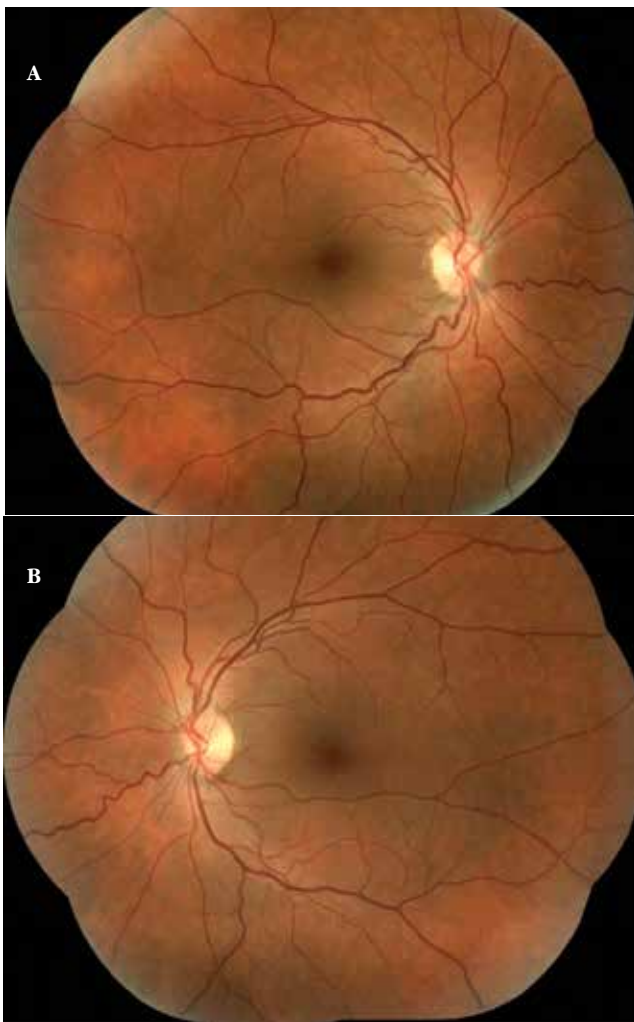


Figure 1. Fundus color image from right eye (A) and left eye (B)

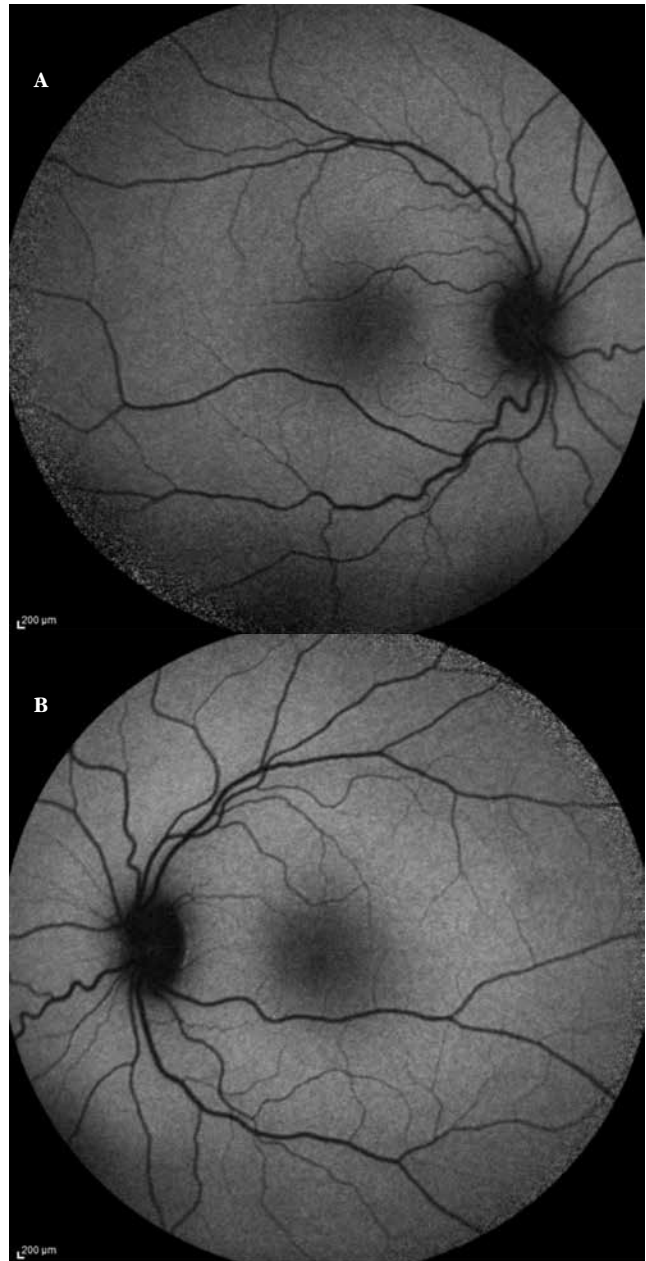


Figure 2. Fundus autofluorescence image from right eye (A) and left eye (B)

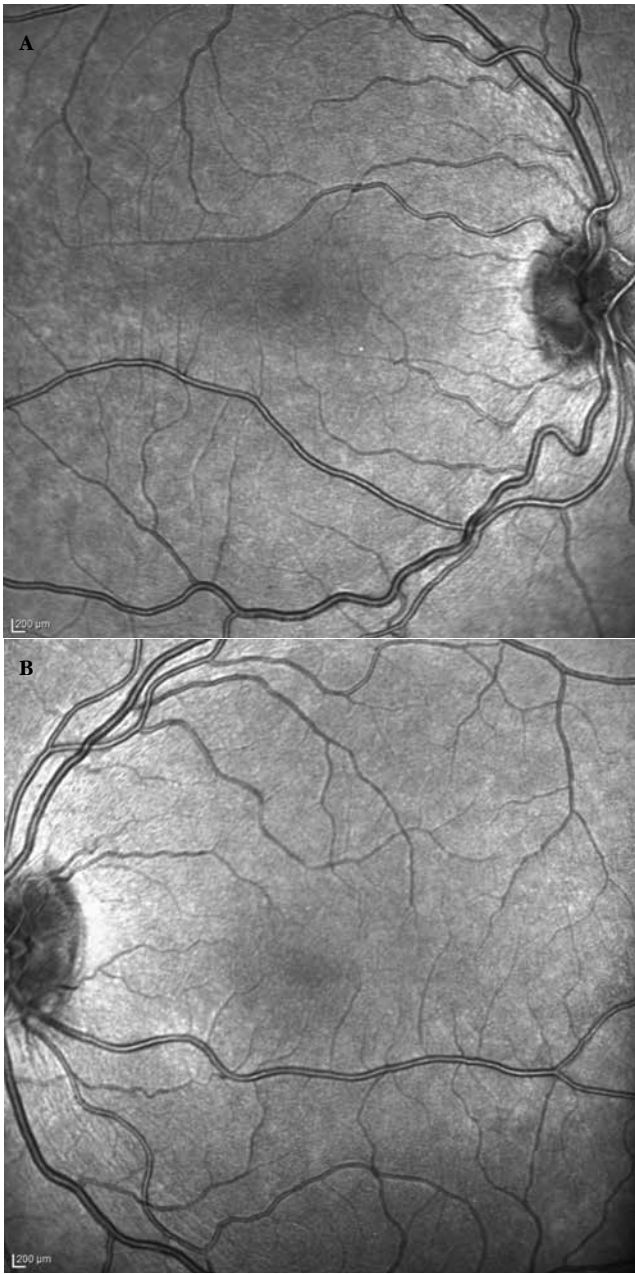


Figure 3. Infrared reflectance image from right eye (A) and left eye (B)

SD-OCT imaging have reported pronounced photoreceptor damage in the fovea, reduced foveal thickness and disruptions of the photoreceptor IS/OS junction in OMD patients.³

It has been demonstrated that the severity of photoreceptor layer disruption is correlated with visual acuity and disease progression.³ Similarly, in our patient we observed bilateral foveal thinning and disruption of the photoreceptor IS/OS junction, both of which were more pronounced in the right eye.

Because fundus IR imaging is easily performed and reveals central hyporeflectance in OMD patients which becomes more apparent as the disease progresses, it can be utilized as an

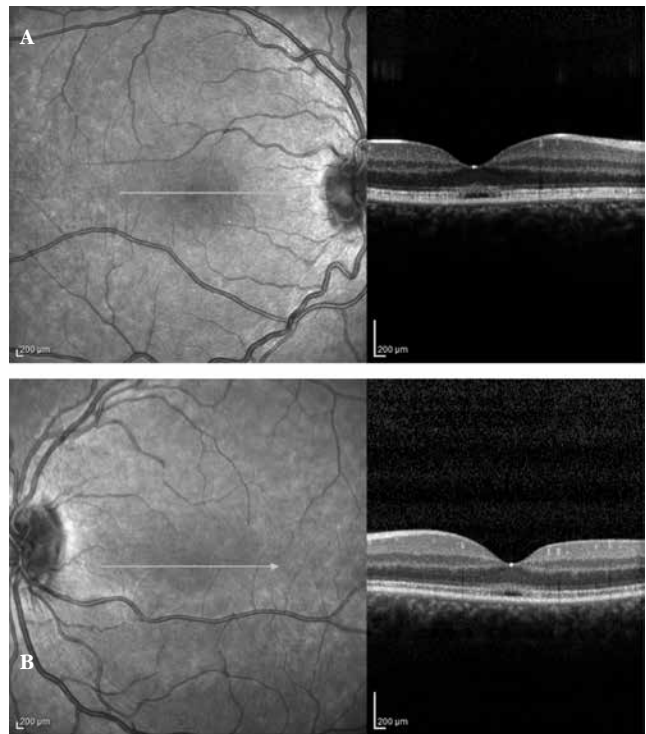


Figure 4. Optical coherence tomography image from right eye (A) and left eye (B)

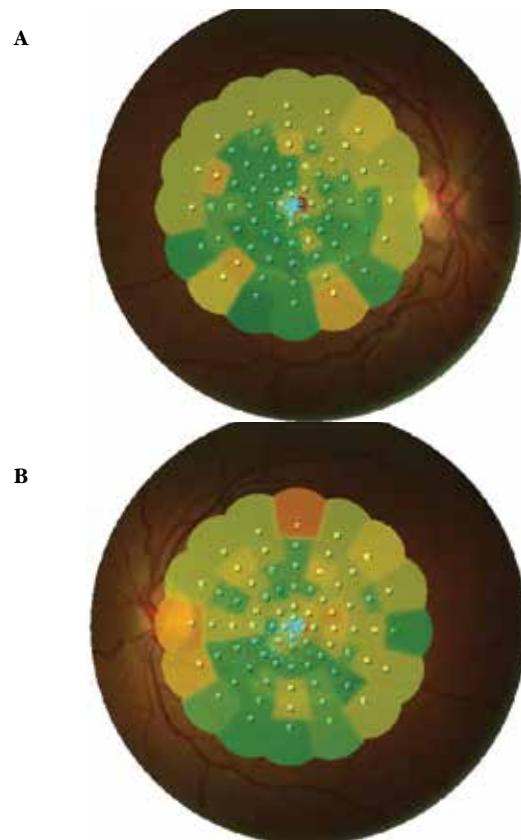


Figure 5. Microperimetry from right eye (A) and left eye (B)

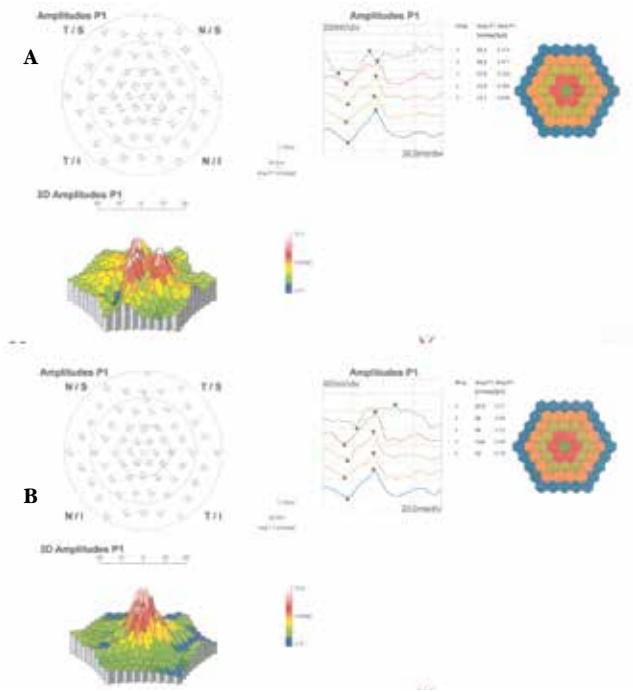


Figure 6. Multifocal electroretinogram from right eye (A) and left eye (B)

auxiliary diagnostic method.^{8,9,10,11} In OMD, no discernible abnormality can be detected by FAF because the condition primarily affects the photoreceptors and there is no evident damage to the retinal pigment epithelium.⁹ Our patient also appeared normal on FAF, while mild central hyporeflectance was observed on fundus IR imaging.

Conclusion

In summary, for patients with progressive vision loss and normal fundus appearance and FFA clinically consistent with OMD, SD-OCT is a primary tool which is non-invasive, easily performed, and clinically reliable. Fundus IR, mfERG and MP are other auxiliary diagnostic methods.

Ethics

Informed Consent: In accordance with the principles of the Declaration of Helsinki, patients were informed about their current status and natural course, consent was obtained.

Peer-review: Externally peer-reviewed.

Authorship Contributions

Surgical and Medical Practices: Serra Arf, Hakan Özdemir, Murat Karaçorlu, Concept: Işıl Sayman Muslubaş, Serra Arf, Hakan Özdemir, Murat Karaçorlu, Design: Işıl Sayman Muslubaş, Serra Arf, Murat Karaçorlu, Data Collection or Processing: Işıl Sayman Muslubaş, Mümin Hocaoğlu, Analysis or Interpretation: Işıl Sayman Muslubaş, Serra Arf, Murat Karaçorlu, Literature Search: Işıl Sayman Muslubaş, Mümin Hocaoğlu, Writing: Işıl Sayman Muslubaş, Mümin Hocaoğlu, Serra Arf, Hakan Özdemir, Murat Karaçorlu.

Conflict of Interest: No conflict of interest was declared by the authors.

Financial Disclosure: The authors declared that this study received no financial support.

References

1. Miyake Y, Ichikawa K, Shiose Y, Kwase Y. Hereditary macular dystrophy without visible fundus abnormality. *Am J Ophthalmol.* 1989;108:292-299.
2. Piao CH, Kondo M, Tanikawa A, Terasaki H, Miyake Y. Multifocal electroretinogram in occult macular dystrophy. *Invest Ophthalmol Vis Sci.* 2000;41:513-517.
3. Park SJ, Woo SJ, Park KH, Hwang JM, Chung H. Morphologic photoreceptor abnormality in occult macular dystrophy on spectral-domain optical coherence tomography. *Invest Ophthalmol Vis Sci.* 2010;51:3673-3679.
4. Rohrschneider K, Bültmann S, Springer C. Use of perimetry (microperimetry) to quantify macular sensitivity. *Prog Retin Eye Res.* 2008;27:536-548.
5. Freund PR, Macdonald IM. Microperimetry in a case of occult macular dystrophy. *Can J Ophthalmol.* 2013;48:101-103.
6. Şentürk F, Karaçorlu SA, Özdemir H, Karaçorlu M, Uysal Ö. Klasik ve gizli koroid neovaskülarizasyonlarında mikroperimetrik değişiklikler. *Ret-Vit.* 2007;15:277-281.
7. Şentürk F, Özdemir H, Karaçorlu S, Karaçorlu M. Stargardt hastalığında fiksasyon özelliklerinin MP-1 mikroperimetri ile değerlendirilmesi. *Turk J Ophthalmol.* 2008;38:134-138.
8. Ahn SJ, Ahn J, Park KH, Woo SJ. Multimodal imaging of occult macular dystrophy. *JAMA Ophthalmol.* 2013;131:880-890.
9. Fujinami K, Tsunoda K, Hanazono G, Shinoda K, Ohde H, Miyake Y. Fundus autofluorescence in autosomal dominant occult macular dystrophy. *Arch Ophthalmol.* 2011;129:597-602.
10. Akahori M, Tsunoda K, Miyake Y, Fukuda Y, Ishiura H, Tsuji S, Usui T, Hatase T, Nakamura M, Ohde H, Itabashi T, Okamoto H, Takada Y, Iwata T. Dominant mutations in RP1L1 are responsible for occult macular dystrophy. *Am J Hum Genet.* 2010;87:424-429.
11. Ahn SJ, Cho SI, Ahn J, Park SS, Park KH, Whoo SJ. Clinical and genetic characteristics of Korean occult macular dystrophy patients. *Invest Ophthalmol Vis Sci.* 2013;54:4856-4863.