

Diagnosis and treatment considerations of atypical oral pain in tuberous sclerosis

Lata Goyal¹, Padmanidhi Agarwal², Gosla S. Reddy², Kanav Jain²

¹Department of Dentistry, AIIMS, Bathinda, Punjab, ²Department of Dentistry and Craniomaxillofacial Surgery, AIIMS, Rishikesh, Uttarakhand, India

ABSTRACT

Diagnosis and management of non-specific, atypical, and non-dental pain are challenging. We hereby report a case of a 23-year-old female who presented with a complaint of intermittent dull ache over her lower front anterior teeth with no radiographic findings. She was diagnosed after history, imaging, and neurology consultation and treated conservatively with complete remission of symptoms. Proper history and counseling are mandatory for all patients. It is important to recognize patients with underlying neurological conditions and take adequate interdepartmental consultation before labeling complaints psychogenic or carrying out unwarranted dental treatment.

Keywords: Anxiety, counselling, dental care, neuropathic pain, referred pain

Introduction

Patients generally report to clinics with dental pain, which is diagnosed by clinical and radiographic findings. Etiology is commonly odontogenic or traumatic, which makes diagnosis and treatment straightforward, with a resolution of pain. Patients, however, also complain of non-specific pain in or around their teeth, the diagnosis of which is an arduous task.^[1] Such a challenge can be seen in a patient with tuberous sclerosis complex (TSC).

TSC is a multisystem disorder with multiorgan involvement associated with physical manifestations, various behavioral, psychiatric, and neuropsychological difficulties.^[2,3] Literature reveals a greater emphasis on physical treatment, with general ignorance towards neuropsychiatry and neurocognitive symptoms, while these patients need special consideration in

management.^[3] To the best of our knowledge, this is the first case report presenting neuropsychiatry symptoms of TSC as periodontal pain.

Case Report

A 23-year-old female reported to department of dentistry with the chief complaint of dull intermittent pain on lower anterior gingiva for 8 years. She gave a vague history of surgery performed in the same region 3 years prior with no respite. She also gave a history of the application of mustard oil, turmeric, sensitivity paste, and other home remedies for it, with no relief.

Her first dental visit showed gingival desquamation on her mandibular anterior gingiva [Figure 1a]. She had numerous pitting on her lower anterior teeth and fibromas on gingiva and tongue [Figure 1b, c]. No pus discharge, tenderness on percussion, or loss of clinical attachment was evident. Her radiographic examination revealed no significant findings [Figure 2].

Her medical history was contributory to a diagnosis of TSC when she was 10 years old. Her family history revealed that her

Address for correspondence: Dr. Lata Goyal, Assistant Professor, Department of Dentistry, AIIMS, Bathinda - 151 001, Punjab, India.
E-mail: latagoyal83@gmail.com

Received: 23-12-2019

Revised: 29-12-2019

Accepted: 02-03-2020

Published: 30-04-2020

Access this article online

Quick Response Code:



Website:
www.jfmpc.com

DOI:
10.4103/jfmpc.jfmpc_1213_19

This is an open access journal, and articles are distributed under the terms of the Creative Commons Attribution-NonCommercial-ShareAlike 4.0 License, which allows others to remix, tweak, and build upon the work non-commercially, as long as appropriate credit is given and the new creations are licensed under the identical terms.

For reprints contact: reprints@medknow.com

How to cite this article: Goyal L, Agarwal P, Reddy GS, Jain K. Diagnosis and treatment considerations of atypical oral pain in tuberous sclerosis. J Family Med Prim Care 2020;9:2121-4.

elder sister also had TSC and was undergoing treatment for the same. She was very anxious and depressed about her chronic tooth-related pain to the extent of having aborted her studies. Her neurological history was negative for seizures and mental retardation. Axial sections of T2-weighted magnetic resonance imaging of the brain revealed hypointensities in bilateral periventricular and occipital regions suggestive of subependymal calcified hamartomas with a heterogeneous appearing lesion in left lateral ventricle about 1.1 × 1.1 cm, suggestive of a cortical tuber in right post temporal region [Figure 3].

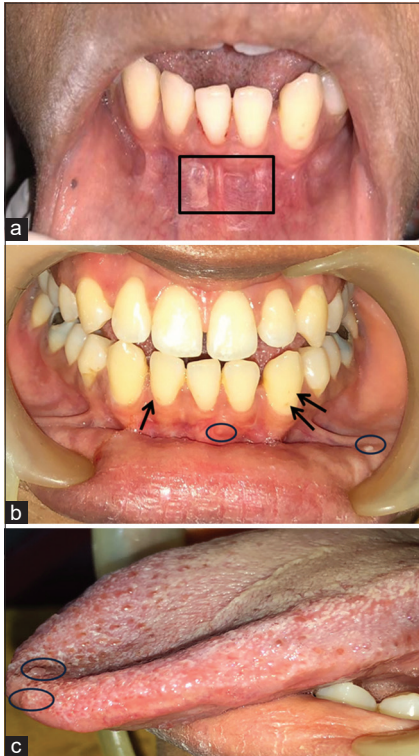


Figure 1: Clinical intraoral photographs of (a) anterior mandibular gingival desquamation (b) dental pitting (black arrows) and gingival fibromas (encircled) over the gingiva with healed gingival desquamation evident (c) fibromas over the tongue

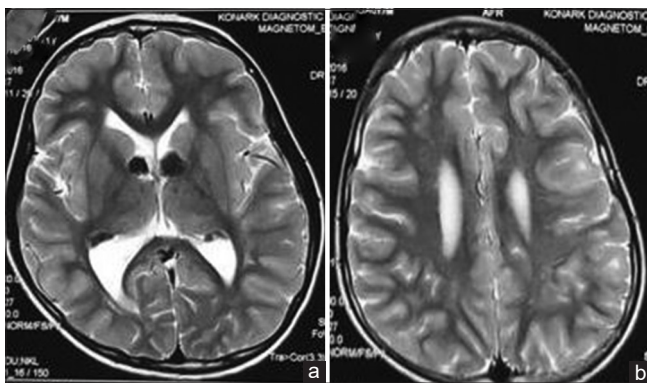


Figure 3: MRI revealing (a) hypointensities in bilateral periventricular and occipital regions suggestive of subependymal calcified hamartomas with (b) heterogenous appearing lesion in left lateral ventricle suggestive of a cortical tuber in right post temporal region

She also complained of constipation. Endoscopy revealed loss of folds of the stomach and video colonoscopy revealed colonic spasm up to terminal ileum. General examination revealed angiofibromas on the face and forehead [Figure 4]. An abdominal ultrasound revealed no kidney abnormality. Ophthalmic examination showed myopic fundus. Blood investigations were unremarkable.

She was advised to discontinue all local applications. The mandibular anterior gingiva showed satisfactory uneventful healing after 2 weeks but her unusual oral pain persisted. She was referred to Psychiatry and started on 25 mg amitryptalline tablet once daily. No dental/periodontal treatment was performed. After 2 months, she was found to be asymptomatic and has been happy and comfortable on regular follow-up for the past year.

Patient's informed consent was obtained for the use of photographs/radiographs for academic purposes.

Discussion

TSC is a neurocutaneous syndrome produced by genetic mutations that manifest as benign lesions of the skin, adnexa, central nervous system, heart, and kidneys.^[2] They present with some neurological problems like mental retardation,

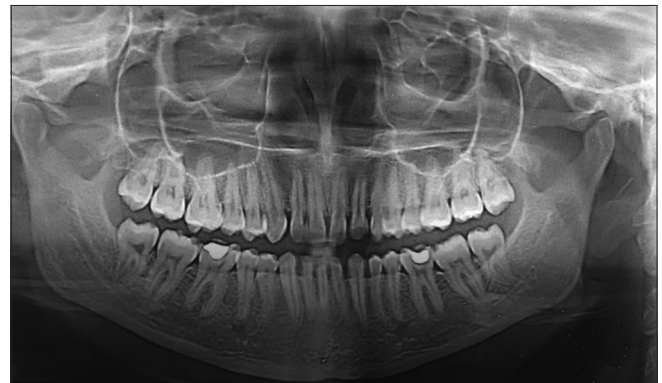


Figure 2: OPG with no significant finding in the region of dental complaints

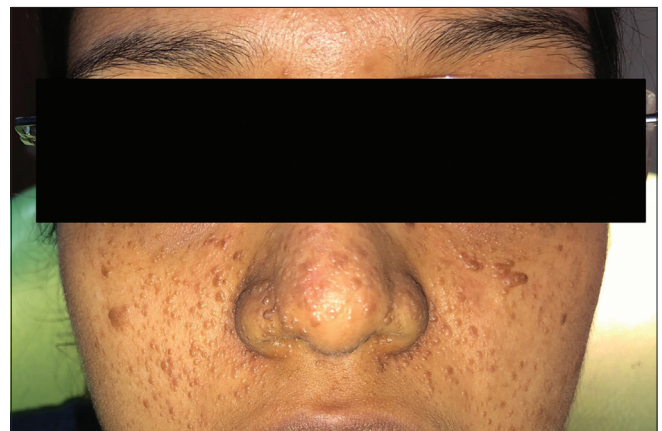


Figure 4: Angiofibromas on face and forehead

seizures, autism, and learning difficulties with angiofibromas in characteristic “butterfly” pattern on face and forehead.^[2,3]

Oral mucosal changes and neuropsychiatric features are diagnostic of TSC.^[4] The 2012 International TSC Diagnostic Criteria is the current method to establish the diagnosis [Table 1]^[5] with the presence of at least 2 major or 1 major with ≥ 2 minor features.^[6] Our patient presented with angiofibromas on the face and forehead, cortical tuber, gingival fibromas, and dental pitting.

The pain of non-dental origin was the main symptom in our patient. She was depressed about her chronic undiagnosed pain for which she had already undergone periapical surgery. This highlights the gap in treatment in managing this complex condition. Chronic/non-specific/generalized pain caused by such disorders can be mistaken for toothaches and unnecessary overzealous management provided to the suspected local tissues. It is important to recognize these patients and take adequate interdepartmental consultation before labeling their complaint psychogenic or carrying out the unwarranted dental treatment. It is reported that $\geq 90\%$ of patients with TSC present with some psychosocial problems during their lifetime. Sadly, almost 70% do not receive any treatment for their mental well-being.^[7]

A new term, Tuberous Sclerosis Associated Neuropsychiatric Disorders has been proposed to encompass all manifestations and consequences related to behavioral, psychological, and mental aspects.^[3,8] It does not imply to underrate individual components and highlights the need to fill the existing lacunae in treatment.

Preventive measures should be initiated early in suspected TSC individuals and mandatory skin and oral examination should be performed regularly. Careful oral and dental hygiene, with frequent dental visits, are needed for the prevention and early detection of oral lesions.^[3] Intervention may be indicated for lesions that are symptomatic, intercept function, bleed, or disfigure. Treatment modalities include the restoration of enamel defects and surgical excision of growths using lasers.^[9]

Table 1: Diagnostic criteria for tuberous sclerosis complex^[5]

Major Criteria	Minor Criteria
Hypomelanotic macule ≥ 3	Confetti skin lesions
Angiofibromas ≥ 3	Dental enamel pits (>3)
Ungual fibroma ≥ 2	Intraoral fibroma (≥ 2)
Shagreen patch	Retinal achromic patch
Multiple renal hamartomas	Multiple renal cysts
Cortical dysplasia	Non-renal hamartoma
Subependymal nodules	
Subependymal giant cell astrocytoma	
Cardiac rhabdomyoma	
Lymphangiomyomatosis	
Angiomyolipoma	
Hypomelanotic macule	

The cerebral manifestations and renal complications exert an important influence upon medical management and patient prognosis.^[3] Extreme caution should be exercised for pre- and postoperative medication, sedation, or general anesthesia due to the frequent renal, cardiac, and pulmonary alterations and the risk factors should be controlled.^[10] The mainstay of treatment is a regular medical and neurologic evaluation with holistic management.

This paper thus provides a general overview of TSC to enable primary care providers to effectively educate and provide care to patients and families. During their lifetime, the majority of patients present to basic practitioners rather than specialists. Awareness of TSC with associated neuropsychiatry and multisystem involvement is of paramount importance for primary care practitioners so that appropriate monitoring, follow-up, and referrals can be made and unwarranted treatment can be prevented.

Conclusions

Non-dental pain is difficult to diagnose and should be considered a possibility. Patients with diseases like TSC need holistic management. Proper detailed history and counseling are mandatory. Along with their chief complaints they should be treated for their neuropsychiatric components as well. Identification of oral features like dental enamel pits and angiofibromas aid in achieving early diagnosis and initiating early appropriate screening examinations, treatment, and genetic counseling.

Financial support and sponsorship

Nil.

Conflicts of interest

There are no conflicts of interest.

References

1. Fukuda KI. Diagnosis and treatment of abnormal dental pain. *J Dent Anesth Pain Med* 2016;16:1-8.
2. Fahmy MD, Gupta A, Padilla RJ, Segura A, Brookes CD. Desmoplastic fibroma associated with tuberous sclerosis: Case report and literature review. *Oral Surg Oral Med Oral Pathol Oral Radiol* 2019;128:e92-9.
3. de Vries PJ, Whittemore VH, Leclizio L, Byars AW, Dunn D, Ess KC, et al. Tuberous sclerosis associated neuropsychiatric disorders (TAND) and the TAND Checklist. *Pediatr Neurol* 2015;52:25-35.
4. Pinna R, Cocco F, Campus G, Conti G, Milia E, Sardella A, et al. Genetic and developmental disorders of the oral mucosa: Epidemiology; molecular mechanisms; diagnostic criteria; management. *Periodontol* 2000 2019;80:12-27.
5. Northrup H, Krueger DA, International Tuberous Sclerosis Complex Consensus Group. Tuberous sclerosis complex diagnostic criteria update: Recommendations of the 2012 international tuberous sclerosis complex consensus conference. *Pediatr Neurol* 2013;49:243-54.

6. Sparling JD, Hong CH, Brahim JS, Moss J, Darling TN. Oral findings in 58 adults with tuberous sclerosis complex. *J Am Acad Dermatol* 2007;56:786-90.
7. Teng JM, Cowen EW, Wataya-Kaneda M, Gosnell ES, Witman PM, Hebert AA, i. Dermatologic and dental aspects of the 2012 International Tuberous Sclerosis Complex Consensus Statements. *JAMA Dermatol* 2014;150:1095-101.
8. Toldo I, Brasson V, Miscioscia M, Pelizza MF, Manara R, Sartori S, *et al.* Tuberous sclerosis-associated neuropsychiatric disorders: A paediatric cohort study. *Dev Med Child Neurol* 2019;61:168-73.
9. Palavra F, Robalo C, Reis F. Recent advances and challenges of mTOR inhibitors use in the treatment of patients with tuberous sclerosis complex. *Oxid Med Cell Longev* 2017;2017:9820181.
10. Wheless JW, Klimo P Jr. Subependymal giant cell astrocytomas in patients with tuberous sclerosis complex: considerations for surgical or pharmacotherapeutic intervention. *J Child Neurol* 2014;29:1562-71.