

Length of MRI signal may predict outcome in advanced cervical spondylotic myelopathy

Amro F. Al-Habib, MD, FRCSC, Ahmed M. AlAqeel, MD, Abdulrahman S. Aldakkan, MD, Fahad B. AlBadr, MD, Shaffi A. Shaik, PhD.

ABSTRACT

الأهداف: تقييم العلاقة بين طول الإشارة في تصوير الرنين المغنطيسي بالإضافة الى العوامل الاكلينيكية والتصويرية الأخرى وقدرة المريض على المشي باستقلالية بعد العلاج الجراحي للحالات اعتلال الحبل الشوكي الناتج عن داء الفقار الرقبي المتقدم.

الطريقة: هي دراسة إستيعادية لكل المرضى الذين يعانون من اعتلال الحبل الشوكي الناتج عن داء الفقار الرقبي المتقدم (درجة 4، 5 حسب مقياس نوريك) والذين أجريت لهم عملية جراحية بمستشفى الملك خالد الجامعي في الفترة من 2003م-2010م. تضمنت الدراسة فقط المرضى الذين استمرت متابعتهم بعد العملية 6 أشهر أو أكثر. قام بدراسة وتحليل الأشعات طبيب أشعة لا يعرف الحالة الاكلينيكية للمرضى (مُعَمَي).

النتائج: اشتملت الدراسة على 43 مريض (83% رجال، ومتوسط فترة المتابعة بعد العملية 29 شهراً). وضحت النتائج أنه كلما كان الاعتلال العصبي للمرضى قبل العملية أقل كلما زادت امكانية المريض على المشي باستقلالية (85.7% لنوريك 4 مقابل 36.4% لنوريك 5، $p=0.001$). كانت قدرة المريض على المشي باستقلالية أقل عند وجود الدلائل التالية في تصوير الرنين المغنطيسي: طول زمن التغيرات في صور T2 ($p=0.001$)، وجود تغيرات محددة بشكل جيد في صور T2 ($p=0.028$)، وجود تغيرات قليلة التعزيز في صور T1 ($p=0.001$)، ووجود ضيق بالقناة الشوكية ($p=0.048$). وقد بين تحليل إحصائي تراجمي متعدد التغيرات أن كلا من زيادة تعزيز التغيرات في صور T2 وقلة التعزيز في صور T1 كانت بمثابة منبئات مستقلة، وقلت إمكانية مشي المريض باستقلالية بنسبة 1.35 كلما زاد طول الإشارة في صور T2 بمقدار 1 مم وبمقدار 14 مرة عند وجود قلة تعزيز في صور T1.

الخاتمة: تقل قدرة المرضى الذين يعانون من اعتلال الحبل الشوكي الناتج عن داء الفقار الرقبي على استعادة المشي باستقلالية بعد العملية الجراحية كلما زاد طول التغيرات الموجودة في صور T2 وعند وجود قلة تعزيز في صور T1 بأشعة الرنين المغنطيسي. تتضمن المنبئات الجيدة كلا من: قدرة المريض على المشي بصورة جيدة قبل العملية، تغيرات قليلة في صور T2 بأشعة الرنين المغنطيسي، وقلة التضيق بالقناة الشوكية.

Objective: To study clinical and radiological factors that may correlate with independent walking (IW) following advanced cervical spondylotic myelopathy (CSM) surgery.

Methods: A retrospective case series including all advanced CSM patients (Nurick 4 and 5) who underwent surgery from 2003-2010 in the Division of Neurosurgery, Department of Surgery, College of Medicine, King Saud University and King Khalid University Hospital, Riyadh, Saudi Arabia. Only patients with 6 months or more follow-up were included. A neuroradiologist who was blinded to the clinical data reviewed all MRI studies.

Results: Forty-three patients were included (83% males, mean follow-up 29 months). A better preoperative neurological status was a positive predictor of IW after surgery (85.7% Nurick 4 versus 36.4% Nurick 5, $p=0.001$). Independent walking was less likely in patients with the following MRI features: longer T2-weighted image (T2WI) signal changes ($p=0.001$), well-circumscribed T2WI signal changes ($p=0.028$), T1WI hypointensity ($p=0.001$), and narrow spinal canal diameter ($p=0.048$). Multivariate regression revealed that both an increased T2WI signal change length and T1WI hypointensity were independent predictors. The risk of dependent walking increased by 1.35 times as the T2WI signal intensity length increased by one mm, and by 14-times with T1WI hypointensity.

Conclusions: Regaining IW after surgery in patients with advanced CSM was less likely for cases showing MRI features of longer T2WI signal changes and T1WI hypointensity. Better baseline walking, less defined T2WI signal change, and a wider spinal canal were good prognostic factors.

Neurosciences 2015; Vol. 20 (1): 41-47

From the Division of Neurosurgery (Al-Habib, AlAqeel, Aldakkan), Department of Surgery, the Departments of Radiology (AlBadr), and Family and Community Medicine (Shaik), College of Medicine, King Saud University, Riyadh, Kingdom of Saudi Arabia.

Received 1st June 2014. Accepted 27th October 2014.

Address correspondence and reprint request to: Dr. Amro F. Al-Habib, Associate Professor and Head, Division of Neurosurgery, Department of Surgery, College of Medicine, King Saud University, PO Box 59220, Riyadh 11525, Kingdom of Saudi Arabia. E-mail: amro.alhabib@gmail.com

Disclosure. The authors declare no conflicting interests, support or funding from any drug company.

Cervical spondylotic myelopathy (CSM) may lead to significant disability.¹⁻³ Progressive compression of the spinal cord causes chronic ischemia, local inflammatory response, and endothelial cell loss that may result in permanent spinal cord damage.⁴ In addition, there is an enhanced permeability in the blood-spinal cord barrier, leading to contact between the peripheral immune system and the spinal cord. Subsequently, there is an increased inflammatory reaction, resulting in more adverse effects on the spinal cord.⁵ Eventually, the spinal cord develops cystic cavitation, gliosis, degeneration of the central grey and medial white matter, Wallerian degeneration of the posterior columns and posterolateral tracts, and a loss of anterior horn cells. These changes are reflected on the clinical presentation and MRI features of the patients. The ability to detect changes related to spinal cord compression plays an important role in predicting clinical and functional outcomes. Several clinical and radiological factors have been studied as potential predictors for functional outcome. Relevant clinical predictors include the patient's age at diagnosis, the duration of symptoms prior to surgery, medical comorbidities, the preoperative neurological status, and the surgical procedure performed.^{6,7}

The MRI predictors of unfavorable outcome include hypointensity on T1-weighted images (T1WI), the type of signal intensity on T2-weighted images (T2WI), and a reduction of the spinal canal diameter.^{6,8-12} The correlation between the length of signal change on T2WI MRI sequences and clinical outcome after surgery has not been established. Changes in the internal structure of the spinal cord could appear as alterations in the signal intensity on T1- and T2-weighted MRI sequences.^{8,13} Hyperintensity on T2WI corresponds to focal gliosis, myelomalacia, vascular ischemia, and edema. Therefore, it is possible that patients with longer MRI signals experience less favorable clinical recoveries after surgery, particularly if the changes correspond to hypointensity on T1WI. In the current study, our objective was to assess the correlation between clinical and MRI features and independent walking (IW) after surgery in an attempt to predict functional recovery. Only patients with advanced myelopathy were included to avoid any bias that may result from involvement of patients with different disease severity.

Methods. Study design. The present study is a retrospective case series conducted in the Division of Neurosurgery, Department of Surgery, College of Medicine, King Saud University and King Khalid University Hospital, Riyadh, Saudi Arabia. Approval was obtained from the King Saud University Research

Ethics board prior to the start of the study. All consecutive cases with advanced CSM (Nurick 4 and 5) who underwent a decompressive surgical procedure with or without stabilization between January 2003 and January 2010 were included. Only patients with follow-up of 6 months or more were included. The exclusion criteria were cervical myelopathy secondary to a non-degenerative etiology (for example, demyelination, trauma, tumor, and infection) and patients with a lower limb pathology that interferes with the ability to walk (for example, advanced osteoarthritis of the hips and knees). A detailed review of the medical files of all included patients was performed. A single neuroradiologist who was blinded to the clinical data reviewed all of the MRI studies using pre-established criteria.

The Nurick scale was first introduced in 1972 for the assessment of walking ability in CSM patients. This scale consists of 6 grades corresponding to the patient's disability (Table 1). Several studies have utilized the Nurick classification in CSM patients due to its validity and reliability.^{7,14,15} Based on Nurick grading, CSM patients were considered advanced if they were grades 4 or 5. However, patients who were able to walk independently were given Nurick grades of 0-3.

Data variables and outcome. Clinical variables. Descriptive data, including age, gender, body mass index, duration of neurological symptoms, preoperative disability status (according to the Nurick grade), comorbidities, and the type of surgical procedure performed (namely, anterior versus posterior), were obtained. A phone follow-up was achieved for 38% of patients. For all cases, including patients with phone re-assessment, the mean follow-up period was 29 months (range of 6-96 months).

Table 1 - Nurick classification of disability in cervical spondylotic myelopathy.

Grade 0	Root signs and symptoms. No evidence of spinal cord involvement
Grade 1	Signs of spinal cord involvement, but no difficulty walking
Grade 2	Slight difficulty walking that does not prevent full-time employment
Grade 3	Difficulty walking that prevents full-time employment or the ability to perform all housework, but that was not severe enough to require someone else help to walk
Grade 4	Able to walk with someone else's help or the aid of a frame
Grade 5	Chair bound or bedridden

Radiological variables. The MRI variables included the antero-posterior (AP) measurement of the cervical spinal canal at the area of maximum spinal cord compression (Figure 1), the presence of a signal change on the T1WI MRI sequence, and the length of the signal intensity change on T2WI. If there were non-contiguous regions of signal intensity change in a single cervical spine MRI study, their lengths were added and the total length was used for the analysis. Additionally, the type of signal change on the T2WI was classified into 3 types according to previous reports (Figure 2):⁹⁻¹¹ Type 0: no signal change; Type 1: hyperintensity with fuzzy borders; and Type 2: hyperintensity with sharp borders. The present study used a 1.5 Tesla MRI scanner, which acquired 3.5 mm thick slices on spin echo T1WI (TR 430 msec, TE 12 msec) and turbo spin echo T2WI (TR 3600 msec, TE 110 msec).

The main outcome was IW at the latest follow-up. The IW was assessed as a score of 0-3 using the Nurick grading system.

Statistical analysis. Statistical analysis was performed using the Statistical Package for Social Science, version 17.0 (SPSS Inc., Chicago, IL, USA). Descriptive statistics (mean, standard deviation, proportion, median, and inter-quartile range [IQR]) were used to describe the quantitative and categorical variables. Student t-test was utilized for continuous variables. Chi-square test was used for categorical variables. For the nonparametric data, the Mann-Whitney U-test was used for analyzing differences between 2 independent variables that were related to the binary outcome variable (postoperative ability to walk independently). Adjusted odds ratios with 95% confidence intervals were calculated. A p -value of <0.05 was considered to be statistically significant. A forward multivariate logistic regression was used to identify predictors of IW.

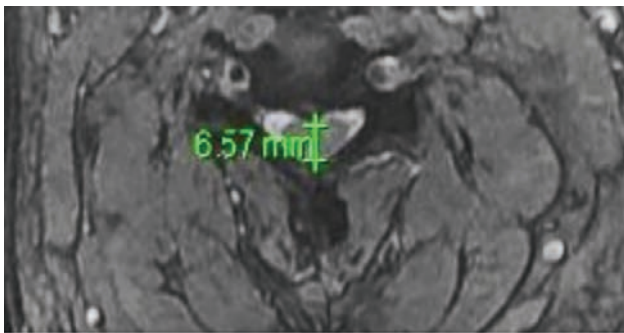


Figure 1 - Measurements for the anterior posterior diameter of the cervical spinal canal.

Results. Demographic and clinical information.

Forty-three patients underwent surgery during the study period: 21 with Nurick grade 4 (48.8%) and 22 with Nurick grade 5 (51.2%). The demographic and clinical data for these patients are presented in Table 2. The average age for the study group was 61.8 years (59.3 years for Nurick 4, and 64.3 years for Nurick 5 groups). There were more males in the study group ($p=0.054$). A shorter duration of symptoms in patients with Nurick grade 5 compared with Nurick grade 4 (4.23 months versus 6.7 months) was observed. This observation may have been due to a rapid deterioration in their condition, or it could also have been a result of recall bias, leading to inaccuracy in determining the onset of the symptoms. It is also possible that patients with Nurick grade 5 may have not included the period of walking with aid when considering their answers regarding their period of functional disability.

Clinical status following surgery. Eighteen patients (85.7%) with Nurick grade 4 walked independently after surgery; however, only 8 patients (36.4%) with Nurick grade 5 regained IW postoperatively ($p=0.001$, Table 2). Figure 3 illustrates the Nurick grade status for all patients at the final follow-up after surgery. There was no mortality in this case series.

Imaging variables on preoperative MRI. Character and type of signal change. Hypointensity on preoperative T1WI was present in 17 patients (39.5%). Only five of the 17 patients were able to walk independently after surgery ($p=0.001$). The analysis of preoperative spinal cord T2WI MRI images showed high signal intensity in 40 patients (93%) and was classified into 3 types. Type-0 was present in 2 patients (4.7%), all of whom could walk independently after surgery ($p=0.36$). Type-1 was present in 29 patients (67.4%), of which 20 patients could walk independently after surgery, compared with 9 patients who could not ($p=0.1$). Type-2 was present

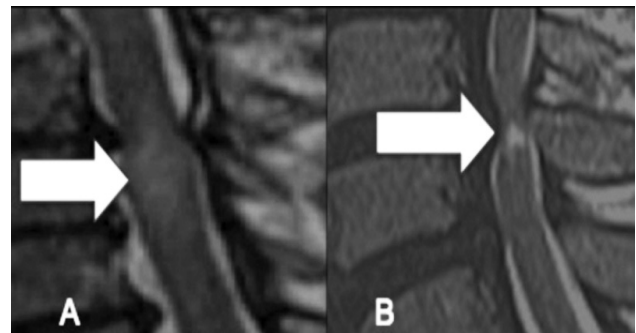


Figure 2 - Preoperative T2WI sagittal MRI showing increased signal intensity (ISI). A) Type 1: faint ISI with fuzzy border (arrow). B) Type 2: intense ISI with well-defined border (arrow).

Table 2 - Characteristics of advanced cervical spondylotic myelopathy patients (N=43).

Variable	Nurick 4 (n=21)	Nurick 5 (n=22)	P-value
Age (mean-years)	59.24	64.32	0.130
Surgical approach			
Anterior (n, %)	14 (66.7)	12 (54.5)	0.416
Posterior (n, %)	7 (33.3)	10 (45.5)	
Average BMI (kg)	27.61	22.66	0.584
Smoking (n, %)	14 (66.7)	5 (22.7)	0.004
Comorbidity* (n, %)	16 (76.2)	19 (86.4)	0.322
Mean duration of difficulty in walking prior to surgery (months)	6.71	4.23	0.008
Walking independently after surgery** (n, %)	18 (85.7)	8 (36.4)	0.001
Preoperative MRI features⁷⁻¹³:			
T1WI signal change (n, %)	6 (28.6)	11 (50.0)	0.151
Type of T2WI signal intensity: (n, %)			
Type 0	2 (9.5)	0 (0.0)	0.233
Type 1	13 (61.9)	16 (72.7)	0.449
Type 2	6 (28.6)	6 (27.3)	0.924
Average length of signal change on T2WI (mm)	8.55	18.00	0.005
Average AP spinal canal size (mm)***	7.238	6.955	0.152

*Comorbidity defined as a disease or condition that coexists with a primary disease but also stands on its own as a specific disease (for example, hypertension, diabetes mellitus), **Walking independently after surgery: Nurick grade 0-3.
***AP - Antero-posterior spinal canal size was calculated at the narrowest point of the space available for the cord at the site of maximum compression (mm).

in 12 patients (27.9%), of which 8 did not achieve IW after surgery compared with 4 patients who could ($p=0.028$). All patients with low signal intensity finding on T1WI had concomitant high signal on T2WI.

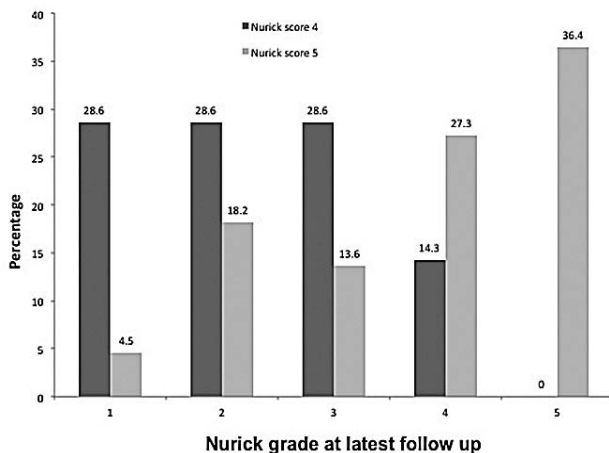


Figure 3 - Nurick grade for all advanced cervical spondylotic myelopathy patients at latest follow-up. Among patients with pre-operative Nurick grade 5, 36.4% remained the same, 27.3% improved to Nurick 4 grade, and the rest (36.3%) had a Nurick grade from 1 to 3. On the other hand, among those with pre-operative Nurick grade of 4, only 14.3% remained the same while 85.7% improved to Nurick grade 1-3.

Length of signal change. The signal change on preoperative T2WI MRIs was significantly longer in patients who could not walk independently postoperatively compared with those who could (21.6 ± 13.22 mm versus 8 ± 4.1 mm, $p=0.001$). While the same holds true for Nurick grade 5 patients (23.6 ± 13.7 mm versus 8.13 ± 2.29 mm, $p=0.001$), it was not significant for patients with Nurick grade 4 (12 ± 3.46 mm versus 7.9 ± 4.8 mm, $p=0.18$).

Reduction of the spinal canal antero-posterior diameter. The spinal canal AP diameter was significantly less on the preoperative MRIs of all patients who could not walk independently postoperatively compared with those who could (6.38 ± 1.6 mm versus 7.56 ± 1.98 mm, $p=0.048$). This finding approached significance when patients with Nurick grade 4 were assessed independently (4.83 ± 3.75 mm versus 7.64 ± 1.99 mm, $p=0.06$). For patients with Nurick grade 5, the spinal canal AP diameter was also smaller for those who could not walk independently postoperatively; however, it did not reach statistical significance (6.7 ± 0.6 mm versus 7.37 ± 2.1 mm, $p=0.4$).

Multivariate regression analysis for prediction of independent walking. A forward stepwise multivariate logistic regression analysis was used to identify the predictors of IW after surgery. Inclusion into the model

was dependent on the result of the binary outcome of individual variables. The factors included were the preoperative Nurick grade and the MRI features of hypointensity on T1WI, the length of the T2WI signal intensity, the type of change on T2WI, and the AP diameter of the spinal canal. Significant predictors were the presence of T1WI hypointensity (odds ratio [OR] 14.26, 95% confidence interval [CI] 1.78-113.9; $p=0.012$) and the length of the T2WI signal intensity change (OR 1.35, 95% CI 1.05-1.73; $p=0.019$). The risk for dependent walking in patients with hypointensity on T1WI increased 14-fold compared with patients without a T1WI signal intensity change. As the length of T2WI signal intensity increased by one mm, the risk of dependent walking increased by 1.35-times.

Discussion. Clinical predictors of outcome.

Patients with better preoperative neurological status are more likely to improve following surgery for CSM (Table 3).^{11,16} Early surgical results by Nurick in 1972¹⁷ revealed a poor outcome (no improvement or death in the hospital) for patients who had a laminectomy for advanced CSM. Scardino et al⁷ analyzed 9 CSM patients with Nurick grade 5. Six patients improved postoperatively at least one grade after surgery, and only 22.2% regained their ability to walk independently at a follow-up 53.4 months later. Similarly, Matsunaga et al¹⁵ evaluated 31 CSM patients with Nurick grade 5 and found improvement in 16.2% after surgery. Better results were reported by Macdonald et al¹⁸ with an improvement in the ability to walk independently in 50% of both grades 4 and 5 patients after surgical decompression. Rajshekhar and Kumar¹⁴ found an

improvement of one or more Nurick grades in all of their grade 5 patients and in 68.5% of grade 4 patients following surgical decompression at a follow-up 36.3 months later. The current study showed similar findings. The CSM patients with Nurick grade 4 had a better ability to walk independently postoperatively compared with patients with Nurick grade 5 (85.7% versus 36.4%). Several clinical variables have been addressed in the literature as being potential predictors for neurological and functional outcome after surgery. Many reports, including the current one, did not identify age, gender, duration of symptoms prior to surgery, medical comorbidities, or surgical approach (anterior or posterior) as significant predictors.^{19,20} However, a younger age group and a shorter duration of symptoms were good prognostic indicators in other studies.^{21,22}

Signal change on MRI and outcome. Understanding the role of MRI in predicting outcomes is evolving. The signal change in T2WI has been categorized into fuzzy (type 1) or sharp and intense (type 2; Figure 2).^{9,23} Type 1 was believed to indicate a milder form of spinal cord change that is likely reversible.^{9,23} In contrast, type 2 corresponds to cavitation within the spinal cord and is consequently irreversible.^{9,23} Several studies, including the current one, have identified type 2 changes as a predictor of a poorer clinical outcome postoperatively.^{9,23} Vedantam et al⁹ assessed both types of MRI changes in 197 patients with CSM or ossification of the posterior longitudinal ligament (OPLL). After controlling for age (≥ 40 versus < 40 years of age), the duration of symptoms (≤ 1 versus > 1 year) and the Nurick grade (grades 1 to 3 versus grades 4 and 5), it was found that type 2 changes

Table 3 - Previous studies on the surgical results of patients with advanced cervical myelopathy.

Study	Nurick grade	n	Mean follow-up (months)	Improvement rate (%)*	Ability to walk independently after surgery (%)**
Ebersold et al 1995 ³⁶	4	7	88.2	57.14	57.1
Macdonald et al 1997 ¹⁸	4	8	31.0	50.0	50.0
	5	8	31.0	50.0	50.0
Matsunaga et al 2004 ¹⁵	4	39	211.2	-	-
	5	31	211.2	16.2	-
Rajshekhar and Kumar 2005 ¹⁴	4	55	36.3	68.5	68.5
	5	17	36.3	100.0	47.0
Scardino et al 2010 ⁷	5	9	53.4	66.6	22.2
Current study	4	21	26.0	85.7	85.7
	5	22	32.0	63.6	36.3

*Improvement rate - percentage of patients improving by at least one Nurick grade. ** Walk independently - Nurick scores 0-3

were associated with a decreased likelihood of recovery in patients with CSM or OPLL after anterior surgical decompression.⁹ Additionally, the findings of Vedantam et al⁹ agreed with other studies that when type 2 changes are combined with low signal on T1WI, the outcome is less favorable.^{8,9}

Prior studies have demonstrated that signal change on T2WI was associated with a poor baseline clinical and functional condition.²⁴ The involvement of more than one segment of the spinal cord has also been reported to indicate a poor postoperative prognosis.^{3,25} However, no previous study has provided a quantitative assessment of the length of the signal change on T2WI and its correlation to the functional outcome. The current study demonstrated that independent walking postoperatively was less likely in patients with a longer signal change on T2WI when Nurick grades 4 and 5 were considered together (namely, as one severe group; $p=0.001$) and for the more severe group (Nurick 5; $p=0.001$).

The current study agreed with previous literature that hypointensity on T1WI indicates a poor prognosis. Ohshio et al²⁶ reported histopathological correlation of various spinal cord pathologies with signal intensity on MRI. They described that the combination of T2WI hyperintensity and T1WI hypointensity indicated a severe cord involvement with necrosis and myelomalacia. Ramanusakas et al²⁷ and Fox²⁸ associated low signal intensity on T1WI with late stages of myelomalacia, cystic necrosis, and syrinx formation. Other reports have agreed that hypointensity on T1WI is a predictor for poor clinical outcome in patients with CSM.^{24,29}

Reduction in the AP diameter of the spinal cord and outcome. The effect of direct compression on the spinal cord has long been considered to play a role in the pathogenesis of CSM.³⁰⁻³² This is seen on MRIs as a reduction in the AP diameter of the spinal canal (Figure 1), which was confirmed in the autopsy studies of patients with CSM.²² However, the correlation of this measure with the severity of myelopathy and functional outcomes has been controversial.^{10,34} Bucciero et al³⁵ found that the neurological outcome was poorer for patients with a lower ratio of AP diameter to transverse diameter in the spinal cord at the area of maximum compression. The current study found that a reduction in the spinal cord AP diameter is a poor predictor for independent walking postoperatively for all patients, regardless of the Nurick grade ($p=0.012$).

Study limitations. Our study should be interpreted within its retrospective design and limited sample size. There could be bias related to the patients' recall of symptoms or their own assessment of IW. On MRI, it

remains unknown if the entire signal change represents gliosis and neuronal loss or oedematous changes. The current study generates the hypothesis that patients with a longer signal change on preoperative MRIs have a poorer outcome. Studies that could correlate this finding to histopathological assessment are needed. Advancement in MRI technology could address neuronal loss more accurately in the spinal cord. While previous reports indicated that multi-segment T2WI involvement is a sensitive indicator of a poorer clinical outcome, adding multi-segment lengths may not be the same as a single lesion of a given length. However, the regression analysis has controlled for other factors that may account for poorer spinal cord involvement (hypointensity on T1WI, type 2 signal change on T2WI, and narrowness of the AP diameter of the spinal canal).

In conclusion, the current study demonstrated that patients with advanced CSM (Nurick 4 and 5) who had a better baseline walking ability, a shorter signal change on T2WI MRI, reduced signal change on T1WI MRI and a wider AP spinal canal diameter were more likely to regain the ability to walk independently after surgery.

References

1. Matz PG, Anderson PA, Holly LT, Groff MW, Heary RF, Kaiser MG, et al. The natural history of cervical spondylotic myelopathy. *J Neurosurg Spine* 2009; 11: 104-111.
2. Holly LT, Matz PG, Anderson PA, Groff MW, Heary RF, Kaiser MG, et al. Clinical prognostic indicators of surgical outcome in cervical spondylotic myelopathy. *J Neurosurg Spine* 2009; 11: 112-118.
3. Chatley A, Kumar R, Jain VK, Behari S, Sahu RN. Effect of spinal cord signal intensity changes on clinical outcome after surgery for cervical spondylotic myelopathy. *J Neurosurg Spine* 2009; 11: 562-567.
4. Kalsi-Ryan S, Karadimas SK, Fehlings MG. Cervical spondylotic myelopathy: the clinical phenomenon and the current pathobiology of an increasingly prevalent and devastating disorder. *Neuroscientist* 2013; 19: 409-421.
5. Baron EM, Young WF. Cervical spondylotic myelopathy: a brief review of its pathophysiology, clinical course, and diagnosis. *Neurosurgery* 2007; 60 (1 Supp 1 1): S35-S41.
6. Ahn JS, Lee JK, Kim BK. Prognostic factors that affect the surgical outcome of the laminoplasty in cervical spondylotic myelopathy. *Clin Orthop Surg* 2010; 2: 98-104.
7. Scardino FB, Rocha LP, Barcelos AC, Rotta JM, Botelho RV. Is there a benefit to operating on patients (bedridden or in wheelchairs) with advanced stage cervical spondylotic myelopathy? *Eur Spine J* 2010; 19: 699-705.
8. Fernandez de Rota JJ, Meschian S, Fernandez de Rota A, Urbano V, Baron M. Cervical spondylotic myelopathy due to chronic compression: the role of signal intensity changes in magnetic resonance images. *J Neurosurg Spine* 2007; 6: 17-22.

9. Vedantam A, Jonathan A, Rajshekhar V. Association of magnetic resonance imaging signal changes and outcome prediction after surgery for cervical spondylotic myelopathy. *J Neurosurg Spine* 2011; 15: 660-666.
10. Avadhani A, Rajasekaran S, Shetty AP. Comparison of prognostic value of different MRI classifications of signal intensity change in cervical spondylotic myelopathy. *Spine J* 2010; 10: 475-485.
11. Shin JJ, Jin BH, Kim KS, Cho YE, Cho WH. Intramedullary high signal intensity and neurological status as prognostic factors in cervical spondylotic myelopathy. *Acta Neurochir (Wien)* 2010; 152: 1687-1694.
12. Mummaneni PV, Kaiser MG, Matz PG, Anderson PA, Groff M, Heary R, et al. Preoperative patient selection with magnetic resonance imaging, computed tomography, and electroencephalography: does the test predict outcome after cervical surgery? *J Neurosurg Spine* 2009; 11: 119-129.
13. Papadopoulos CA, Katonis P, Papagelopoulos PJ, Karampekios S, Hadjipavlou AG. Surgical decompression for cervical spondylotic myelopathy: correlation between operative outcomes and MRI of the spinal cord. *Orthopedics* 2004; 27: 1087-1091.
14. Rajshekhar V, Kumar GS. Functional outcome after central corpectomy in poor-grade patients with cervical spondylotic myelopathy or ossified posterior longitudinal ligament. *Neurosurgery* 2005; 56: 1279-1285.
15. Matsunaga S, Sakou T, Taketomi E, Komiya S. Clinical course of patients with ossification of the posterior longitudinal ligament: a minimum 10-year cohort study. *J Neurosurg* 2004; 100 (3 Suppl Spine): 245-248.
16. Alaffi T, Kern R, Fehlings M. Clinical and MRI predictors of outcome after surgical intervention for cervical spondylotic myelopathy. *J Neuroimaging* 2007; 17: 315-322.
17. Nurick S. The natural history and the results of surgical treatment of the spinal cord disorder associated with cervical spondylosis. *Brain* 1972; 95: 101-108.
18. Macdonald RL, Fehlings MG, Tator CH, Lozano A, Fleming JR, Gentili F, et al. Multilevel anterior cervical corpectomy and fibular allograft fusion for cervical myelopathy. *J Neurosurgery* 1997; 86: 990-997.
19. Choi S, Lee SH, Lee JY, Choi WG, Choi WC, Choi G, et al. Factors affecting prognosis of patients who underwent corpectomy and fusion for treatment of cervical ossification of the posterior longitudinal ligament: analysis of 47 patients. *J Spinal Disord Techn* 2005; 18: 309-314.
20. Uchida K, Nakajima H, Sato R, Kokubo Y, Yayama T, Kobayashi S, et al. Multivariate analysis of the neurological outcome of surgery for cervical compressive myelopathy. *J Orthop Sci* 2005; 10: 564-573.
21. Yamazaki T, Yanaka K, Sato H, Uemura K, Tsukada A, Nose T. Cervical spondylotic myelopathy: surgical results and factors affecting outcome with special reference to age differences. *Neurosurgery* 2003; 52: 122-126.
22. Fujiwara K, Yonenobu K, Ebara S, Yamashita K, Ono K. The prognosis of surgery for cervical compression myelopathy. An analysis of the factors involved. *J Bone Joint Surg Br* 1989; 71: 393-398.
23. Singh A, Choi D, Crockard A. Use of walking data in assessing operative results for cervical spondylotic myelopathy: long-term follow-up and comparison with controls. *Spine (Phila Pa 1976)* 2009; 34: 1296-1300.
24. Karpova A, Arun R, Davis AM, Kulkarni AV, Massicotte EM, Mikulis DJ, et al. Predictors of surgical outcome in cervical spondylotic myelopathy. *Spine (Phila Pa 1976)* 2013; 38: 392-400.
25. Yukawa Y, Kato F, Yoshihara H, Yanase M, Ito K. MR T2 image classification in cervical compression myelopathy: predictor of surgical outcomes. *Spine (Phila PA 1976)* 2007; 32: 1675-1679.
26. Ohshio I, Hatayama A, Kaneda K, Takahara M, Nagashima K. Correlation between histopathologic features and magnetic resonance images of spinal cord lesions. *Spine* 1993; 18: 1140-1149.
27. Ramanauskas WL, Wilner HI, Metes JJ, Lazo A, Kelly JK. MR imaging of compressive myelomalacia. *J Comput Assist Tomogr* 1989; 13: 399-404.
28. Fox JL, Wener L, Drennan DC, Manz HJ, Won DJ, Al-Mefty O. Central spinal cord injury: magnetic resonance imaging confirmation and operative considerations. *Neurosurgery* 1988; 22: 340-347.
29. Morio Y, Teshima R, Nagashima H, Nawata K, Yamasaki D, Nanjo Y. Correlation between operative outcomes of cervical compression myelopathy and mri of the spinal cord. *Spine (Phila Pa 1976)* 2001; 26: 1238-1245.
30. Nurick S. The pathogenesis of the spinal cord disorder associated with cervical spondylosis. *Brain* 1972; 95: 87-100.
31. Payne EE, Spillane JD. The cervical spine; an anatomico-pathological study of 70 specimens (using a special technique) with particular reference to the problem of cervical spondylosis. *Brain* 1957; 80: 571-596.
32. Burrows EH. The sagittal diameter of the spinal canal in cervical spondylosis. *Clin Radiol* 1963; 14: 77-86.
33. Tsurumi T, Goto N, Shibata M, Goto J, Kamiyama A. A morphological comparison of cervical spondylotic myelopathy: MRI and dissection findings. *Okajimas Folia Anat Jpn* 2005; 81: 119-122.
34. Chiewvit P, Tritrakarn SO, Phawjinda A, Chotivichit A. Predictive value of magnetic resonance imaging in cervical spondylotic myelopathy in prognostic surgical outcome. *J Med Assoc Thai* 2011; 94: 346-354.
35. Bucciero A, Vizioli L, Tedeschi G. Cord diameters and their significance in prognostication and decisions about management of cervical spondylotic myelopathy. *J Neurosurg Sci* 1993; 37: 223-228.
36. Ebersold MJ, Pare MC, Quast LM. Surgical treatment for cervical spondylitic myelopathy. *J Neurosurg* 1995; 82: 745-751.

Related articles

Othman W. An overview of degenerative disease of the spine. *Neurosciences* 2008; 13 Suppl 1: 29.

Douglas Orr R. Options for management of cervical spondylotic myelopathy. *Neurosciences* 2008; 13 Suppl 1: 29.

Azzam N, Erfan M. Cervical spondylotic myelopathy. *Prognostic Significance and Fate of Myelomalacia*. *Neurosciences* 2004; 9 (1 Suppl 1): 39.