

# Clinical presentation, management and follow-up of 83 patients with Leydig cell tumors of the testis: a prospective case-cohort study

Carlotta Pozza<sup>1</sup>, Riccardo Pofi<sup>1</sup>, Marta Tenuta<sup>1</sup>,  
Maria Grazia Tarsitano<sup>1</sup>, Emilia Sbardella<sup>1</sup>, Giorgio Fattorini<sup>1</sup>,  
Vito Cantisani<sup>2</sup>, Andrea Lenzi<sup>1</sup>, Andrea M. Isidori<sup>1,\*</sup>,  
Daniele Gianfrilli<sup>1</sup>, and the TESTIS UNIT

<sup>1</sup>Department of Experimental Medicine, Sapienza University of Rome, 00161, Rome, Italy <sup>2</sup>UOS Innovazioni Diagnostiche e Ultrasonografiche, Azienda Ospedaliera Universitaria Policlinico Umberto I, Sapienza University of Rome, 00161, Rome, Italy

\*Correspondence address. Department of Experimental Medicine, Sapienza University of Rome, Viale del Policlinico 155, 00161, Rome, Italy. Tel: +39 0649970540; Fax: +39 0649970598; E-mail: andrea.isidori@uniroma1.it

Submitted on November 22, 2018; resubmitted on March 13, 2019; editorial decision on April 17, 2019

**STUDY QUESTION:** When should 'not so rare' Leydig cell tumors (LCTs) of the testis be suspected, diagnosed, and treated?

**SUMMARY ANSWER:** LCTs are more frequent than generally believed, are associated with male infertility, cryptorchidism and gynecomastia, and should be treated conservatively (in compliant patients) with active surveillance, which appears to be a safe alternative to surgical enucleation.

**WHAT IS KNOWN ALREADY:** Increasing referrals for testicular imaging have led to an increase in findings of LCTs. The features and natural history of these tumors remain largely unknown, as the available studies are small and heterogeneous. LCTs were previously treated aggressively and follow-up data are lacking.

**STUDY DESIGN, SIZE, DURATION:** A case-cohort study of consecutive patients diagnosed with LCTs over a 10-year period was prospectively enrolled from 2009 to 2018 and compared to matched cohorts of patients with seminomas or no testicular lesions screened in the same timeframe.

**PARTICIPANTS/MATERIALS, SETTING, METHODS:** Of the 9949 inpatients and outpatients referred for scrotal ultrasound, a total of 83 men with LCTs were included. Enrolled subjects underwent medical history and clinical examination and were asked to undergo routine blood tests, hormone investigations (FSH, LH, total testosterone, estradiol, inhibin B, sex hormone-binding globulin (SHBG), prolactin), and semen analysis. Patients who consented also underwent contrast-enhanced ultrasound, elastography, gadolinium-enhanced scrotal magnetic resonance imaging, and hCG stimulation test (5000 IU i.m.) with serum total testosterone and estradiol measured at 0, 24, 48, and 72 hours.

**MAIN RESULTS AND THE ROLE OF CHANCE:** In total, 83 patients diagnosed with LCTs were compared against 90 patients diagnosed with seminoma and 2683 patients without testicular lesions (NoL). LCTs were diagnosed by enucleation (48.2%), orchiectomy (13.3%), or clinical surveillance (38.5%). Testicular volume, sperm concentration, and morphology were lower ( $P = 0.001$ ,  $P = 0.001$ , and  $P < 0.001$ , respectively) in patients with LCTs than in the NoL group. FSH, LH, and SHBG were higher and the testosterone/LH ratio was lower in LCTs than in the NoL group ( $P < 0.001$ ). The LCT group showed higher SHBG ( $P = 0.018$ ), lower sperm concentration ( $P = 0.029$ ), and lower motility ( $P = 0.049$ ) than the seminoma group. Risk factors for LCTs were cryptorchidism ( $\chi^2 = 28.27$ ,  $P < 0.001$ ), gynecomastia ( $\chi^2 = 54.22$ ,  $P < 0.001$ ), and low testicular volume ( $\chi^2 = 11.13$ ,  $P = 0.001$ ). Five cases were recurrences or bilateral lesions; none developed metastases during follow-up (median, 66 months).

**LIMITATIONS, REASONS FOR CAUTION:** This study has some limitations. First, hCG and second-line diagnostic investigations were not available for all tumor patients. Second, ours is a referral center for infertility, thus a selection bias may have altered the baseline features

of the LCT population. However, given that the comparison cohorts were also from the same center and had been managed with a similar protocol, we do not expect a significant effect.

**WIDER IMPLICATIONS OF THE FINDINGS:** LCTs are strongly associated with male infertility, cryptorchidism, and gynecomastia, supporting the hypothesis that testicular dysgenesis syndrome plays a role in their development. Patients with LCTs are at a greater risk of endocrine and spermatogenesis abnormalities even when the tumor is resected, and thus require long-term follow-up and prompt efforts to preserve fertility after diagnosis.

LCTs have a good oncological prognosis when recognized early, as tissue-sparing enucleation is curative and should replace orchiectomy. Conservative surgery and, in compliant patients, active surveillance through clinical and radiological follow-up are safe options, but require monitoring of testicular failure and recurrence.

**STUDY FUNDING/COMPETING INTEREST(S):** The project was funded by the Ministry of University and Research Grant MIUR 2015ZTT5KB. There are no conflicts of interest.

**TRIAL REGISTRATION NUMBER:** ALCeP trial ([ClinicalTrials.gov](https://clinicaltrials.gov) Identifier: NCT01206270).

**Key words:** Leydig cell tumors / testicular dysgenesis syndrome / organ-sparing surgery / Leydig cell failure / testicular cancer

## Introduction

Leydig cell tumors (LCTs) are the most common form of testicular stromal tumor. Although once considered rare, in the most recent series, they accounted for 3–22% of all testicular neoplasms (Isidori et al., 2014; Lagabrielle et al., 2018; Paffenholz et al., 2018). Most LCTs are benign, with an exceptionally low number of metastasizing cases reported to date (Nason et al., 2017). However, the limited number of available studies prevents an understanding of the true natural history of the disease. The management of LCTs in terms of treatment, clinical implications, and follow-up thus remains controversial.

As the therapeutic options for LCTs differ from those for the more common—and more aggressive—germ cell tumors, preoperative distinction of benign from malignant tumors is crucial. In addition, the increasing routine use of ultrasound (US) has substantially increased the number of testicular incidentalomas requiring work-up and treatment.

The few clinical features proposed as suggestive of LCTs include gynecomastia and precocious puberty (Mameli et al., 2016; Santos-Silva et al., 2014). To our knowledge, few studies describe the clinical characteristics of LCTs, and they involved small series, different institutions, and different protocols, and mainly dealt with the surgical management of these tumors (Borghesi et al., 2015; Bozzini et al., 2013; Bozzini et al., 2017; Carmignani et al., 2003; Djaladat, 2015; Giannarini et al., 2008; Giannarini et al., 2007; Laclergerie et al., 2017; Leonhartsberger et al., 2014; Leonhartsberger et al., 2011; Loeser et al., 2009; Maxwell et al., 2016; Nason et al., 2017; Nicolai et al., 2015; Scandura et al., 2018). None reported clinical data from long-term follow-up.

We therefore felt the need to analyze the clinical, biochemical, and radiological features of all patients with LCTs referred to our department over a 10-year period and describe the outcome of the various treatment options. A distinctive feature of the present analysis is that all patients were investigated prospectively on the basis of an established protocol using novel diagnostic techniques and were surgically treated and followed up in the same unit, thus minimizing biases in data accrual, analytical methods, and therapeutic outcome.

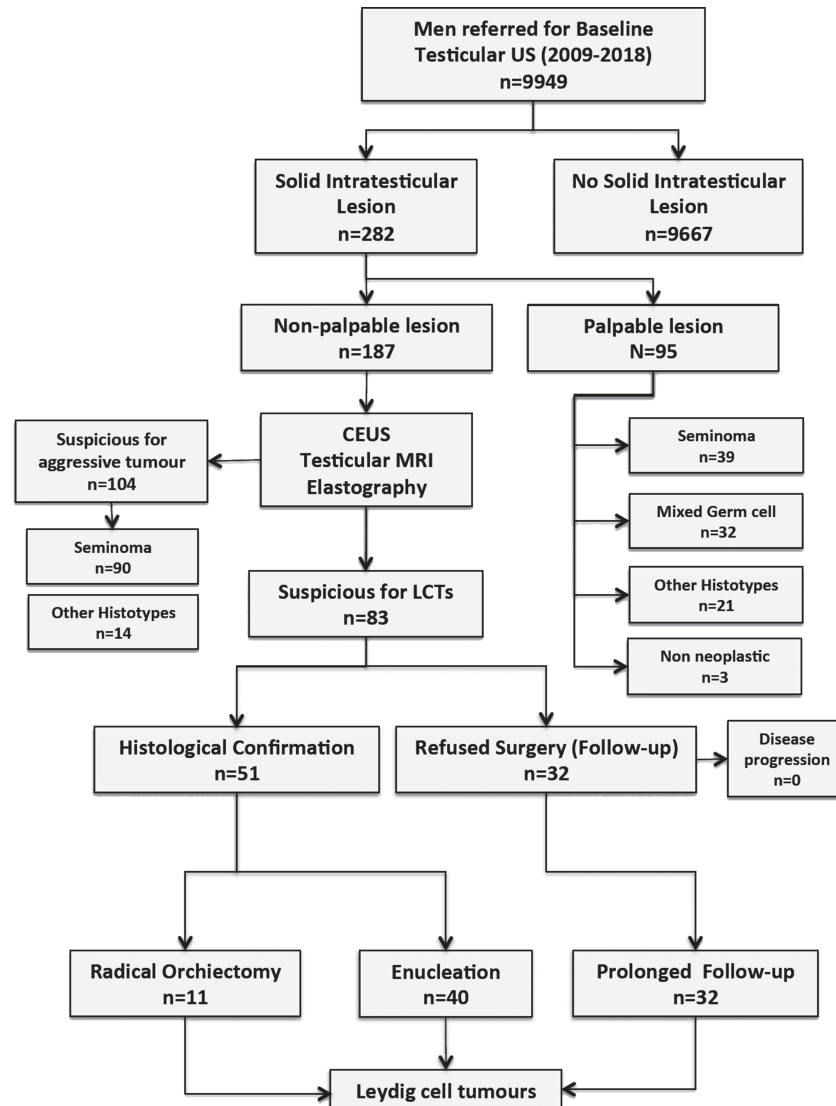
## Materials and Methods

### Patients and protocol

The study was carried out from June 2009 to June 2018 at the Sapienza University of Rome using the STARD (STAndards for the Reporting of Diagnostic accuracy studies) checklist flow diagram. Of the 9949 inpatients and outpatients referred for scrotal US, 282 were diagnosed with at least one solid testicular lesion (inclusion criterion). Of these, 95 had a palpable lesion and underwent surgical exploration because of the high pre-test probability of malignancy (exclusion criterion); the nodule was malignant in 92 patients (96%; the remaining three patients had non-neoplastic lesions). The remaining 187 men with incidental, nonpalpable testicular lesions were included in the study.

The study design is shown in Fig. 1. The local review board approved the protocol, which was conducted in accordance with the Declaration of Helsinki, and all patients provided written informed consent. We included all the patients screened for the ALCeP trial ([ClinicalTrials.gov](https://clinicaltrials.gov) Identifier: NCT01206270).

The enrolled subjects underwent medical history and clinical examination and were asked to undergo routine blood tests, hormone investigations [FSH, LH, total testosterone, estradiol, inhibin B, sex hormone-binding globulin (SHBG), prolactin (PRL)], and semen analysis. Serum FSH, LH, and PRL were measured in duplicate with the chemiluminescent microparticle immunoassay (CMIA, Architect System) (Abbott Laboratories, IL, USA), with limits of detection (LOD) of 0.05 U/l, 0.07 U/l, and 0.6 ng/ml, respectively; the intra- and inter-assay coefficients of variation for our laboratory were 2.9% and 3.7% at 4.1 U/l (FSH); 3.2% and 4.6% at 3.7 U/l (LH); and 3.5% and 4.2% at 5.8 ng/ml (PRL). The normal reference ranges were 1.38–9.58 mIU/ml for FSH, 1.8–8.16 mIU/ml for LH, and 2.6–13.13 nh/ml for PRL. SHBG was analysed by CMIA (Abbott Laboratories, IL, USA); the LOD was  $\leq 0.1$  nmol/l, the intra-assay and inter-assay coefficients of variation for our laboratory were 5.65% and 9.54% at 8.8 nmol/l, respectively, and the normal reference range for adulthood was 11.2–78.1 nmol/l. Serum inhibin B was measured using an enzymatically amplified two-site, two-step sandwich immunoassay (ELISA) (Diagnostic Systems



**Figure 1** Flow diagram for study of patients with lesions of the testis. US: ultrasound; CEUS: contrast enhanced ultrasonography; MRI: magnetic resonance imaging; LCTs: Leydig cell tumors.

Laboratories, Inc. Webster, TX, USA). The LOD was 7.0 pg/ml, the intra and interassay coefficients of variation were 3.3% and 7.2%, respectively, at 122 pg/ml, and the normal post-pubertal range was 80–380 pg/ml. Steroid hormones were evaluated by liquid chromatography–mass spectrometry (triple-quadrupole AGILENT series 1290 INFINITY II/6495MSD at BioL&endo LAB Sapienza, University of Rome). The method's precision for pools at low, medium, and high concentrations was 2.7–2.9% for testosterone and 3.3–5.3% for estradiol.

Semen samples were collected by masturbation directly into a sterile plastic container after 2–7 days of sexual abstinence. They were examined by light microscope and were then assessed according to World Health Organization guidelines (World Health Organization, 1999; World Health Organization, 2010). The following variables were taken into consideration: volume (ml), sperm concentration (n/ml),

total sperm number ( $n \times 10^6$ /ejaculate), progressive motility (%), and morphology (% abnormal forms).

Patients who consented also underwent contrast-enhanced ultrasound (CEUS), elastography, gadolinium-enhanced scrotal magnetic resonance imaging (MRI), and hCG stimulation test (5000 IU i.m., IBSA Pharmaceuticals, Italy) with serum total testosterone and estradiol measured at 0, 24, 48, and 72 hours. The comparison cohorts consisted of the 90 patients diagnosed with seminoma (from the 187 with nonpalpable lesions, Fig. 1) and patients without testicular nodules (NoL group) matched for age and body mass index (BMI), selected from patients screened for infertility using a similar protocol. The seminoma cohort was chosen because this is the most common 'pure' histotype (Albers *et al.*, 2015) and has US features closest to those of LCTs, as previously shown (Isidori *et al.*, 2014; Manganaro *et al.*, 2018; Manganaro *et al.*, 2015; Pozza *et al.*, 2016). Data on some of the

included patients have been presented in part in previous publications (Isidori et al., 2014; Manganaro et al., 2018; Manganaro et al., 2015; Pozza et al., 2016).

## Diagnosis of LCTs, reference standard, and follow-up

After US diagnosis of a testicular lesion, tumor markers ( $\beta$ -HCG, placental alkaline phosphatase, alpha-fetoprotein, carcinoembryonic antigen, ferritin, and lactate dehydrogenase) were investigated in all patients and the following additional tests were offered to attempt pre-operatively to distinguish LCTs from malignant neoplasms: CEUS, testicular elastography, and scrotal MRI with gadolinium contrast enhancement. All patients with solid lesions were sent for tissue sparing surgery (TSS) with the awareness that some lesions might turn out to be benign, as current guidelines do not address the management of solid, potentially neoplastic lesions. On histology, signs of malignancy in LCTs were reported according to Kim's criteria (tumor size, necrosis, presence of nuclear atypia, angiolymphatic invasion, infiltrating margins, and number of mitotic features) (Kim et al., 1985). On immunohistochemistry, inhibin and calretinin were used as confirmatory markers for the diagnosis of LCTs.

If the lesion was malignant on frozen section, the procedure was converted to a radical orchiectomy (RO). When patients declined surgery and the clinical and US findings allowed a 'watchful-waiting' approach, they were followed up with serial US every 3 months for a minimum of 12 months, provided they had had a previous negative abdominal computed tomography (CT) scan or MRI and a negative chest X-ray or CT scan, thus excluding distant metastasis.

For diagnosis, we considered LCT as any histologically confirmed lesion or any single, hypoechoic, vascularized solid lesion showing resolution, no growth, no elevated tumor markers, and no other relevant clinical events (gynecomastia, flushes, sweating, polycythemia, etc.) at repeated follow-up, according to a previously validated protocol (Isidori et al., 2014; Manganaro et al., 2015).

## Statistical analysis

Groups were compared using the Mann-Whitney test for continuous variables or odds ratio with 95% confidence intervals (CIs) for categorical variables. Relationships between the qualitative data were examined by chi-square test or Fisher's exact tests.

Statistical analyses were performed with SPSS 17.0 [SPSS, Chicago, IL, USA] and SigmaPlot 12.0 [Systat Software Inc., CA, USA] by using two-tailed significance tests, with  $P < 0.05$  considered indicative of statistical significance.

## Results

Nonpalpable testicular tumors were found in 2.72% of the nearly 10 000 consecutive unselected patients referred to the Testis Unit over a 10-year period. Of these, 1.89% had a malignant, and 0.84% a benign, testicular lesion. Eighty-three patients were diagnosed with LCTs and 194 with malignant testicular lesions demonstrating a high prevalence of LCTs among nonpalpable masses in our cohort (30%, Table I). The reasons for referral for the entire set of patients diagnosed with a tumor are reported in Table II. The majority of patients with LCT was

referred for infertility (48.2%), general andrological screening (10.8%), or varicocele (9.6%).

The comparison cohort consisted of an age- and BMI-matched group ( $n = 2683$ ) selected from the 9678 subjects without solid testicular lesions, who had a normal karyotype and underwent semen and hormone evaluation. The clinical features of all subjects are shown in Table III, while baseline hormone and semen parameters are shown in Table IV. Patients with Klinefelter syndrome are presented separately in Table III.

## Clinical characteristics

Age at referral was similar for both patient groups ( $P = 0.183$ ), as were height, weight, BMI, and mother's age at delivery. The seminomas were larger than the LCTs ( $P = 0.049$ ). Global testicular volume (GTV = right + left volume) was similar in both patient groups ( $P = 0.081$ ), with a trend toward smaller testes in the LCT group [23.1 (18.2–29.7) versus 26.0 (21.4–33.4)]. Compared to the NoL group, patients with LCTs had significantly smaller GTV ( $P = 0.017$ ).

In the seminoma group, 11 patients (12.2%) had a previous contralateral malignant tumor compared to none in the LCT group ( $P = 0.001$ ). Conversely, five of the patients with LCT (6%) had a previous contralateral LCT, compared to none in the seminoma group ( $P = 0.024$ ). The groups had a similar history of undescended testis ( $P = 0.680$ ) and gynecomastia ( $P = 0.196$ ). Both cryptorchidism and gynecomastia were more common in LCT patients than in the NoL group ( $P < 0.001$ ).

## Laboratory data

Patients with LCTs showed lower sperm concentration ( $P = 0.029$ ) and lower total sperm number ( $P = 0.011$ ) than the seminoma and NoL groups (Table IV). Total sperm motility in the LCT group was lower than in the seminoma group ( $P = 0.049$ ) and normal morphology was lower than in the NoL group ( $P < 0.001$ ) (Table IV). SHBG was higher in the LCT group than in the seminoma group ( $P = 0.018$ ) or NoL group ( $P < 0.001$ ). There was no statistically significant difference in gonadotrophins, total testosterone, or inhibin B between the two tumor groups. Compared to the NoL group, patients with LCTs showed higher levels of FSH ( $P < 0.001$ ) and LH ( $P < 0.001$ ) and a lower testosterone/LH ratio ( $P < 0.001$ ).

## Diagnostic features of LCTs

The majority of LCTs (68, 81.9%) appeared hypoechoic, while 13 were weakly hypoechoic (14.5%) and two inhomogeneous (3.6%). Internal vascularization was seen in 54 LCTs (65.1%). The margins were well-defined in 59 cases (71.1%), ill-defined in 17 (20.5%), and irregular in 7 (8.4%). None of the lesions presented intralesional calcifications; parenchymal microlithiasis was present in 14 cases (16.8%) (Fig. 2).

Of the 59 patients who underwent CEUS, 50 showed features suggestive of LCTs according to the published criteria (Isidori et al., 2014), characterized by a rapid enhancement of the lesion (wash-in) and a delayed wash-out compared with that of the surrounding parenchyma. Five cases showed synchronous wash-in and wash-out and the remaining four lesions showed a rapid wash-in and wash-out pattern. Elastography was performed in 54 patients. Nine lesions (10.8%) were soft (ES1), 24 (28.9%) had a medium elasticity (ES2), and the remaining 21 (25.3%) were hard (ES3). Scrotal MRI data were avail-

**Table 1** Summary of the existing literature on prevalence of Leydig cell tumors among non-palpable lesions.

Reference	Study	Study population (n)	Age (yrs)	Histologically confirmed lesions (n)	Lesion size (cm)	Number of malignant lesions	Prevalence of malignancies among histologically confirmed lesions (%)	Number of LCTs	Prevalence of LCTs among histologically confirmed lesions (%)
Elert <i>et al.</i> , 2002	Retrospective 1974–2000	354	28.9 (mean)	354	1.3 (mean)	317/354	89.5%	14/354	4%
Hopps and Goldstein, 2002	Retrospective 1995–2001	65	/	4	0.7 (mean)	2/4	50%	2/4	50%
Carmignani <i>et al.</i> , 2003	Prospective 2000–2002	1320	41 (mean)	27	1.7–2.4 (range)	9/17	53%	2/17	14.8%
Leroy <i>et al.</i> , 2003	Retrospective 1996–2002	15	34.3 (mean)	15	0.75 (mean)	0/10	100%	2/10	60%
Carmignani <i>et al.</i> , 2004	Retrospective 2000–2003	560	37 (mean)	8	0.4–2.6 (range)	4/15	27%	9/15	60%
Colpi <i>et al.</i> , 2005	Retrospective	6	38.5 (mean)	6	0.43 (mean)	2/8	25%	3/8	37.5%
Muller <i>et al.</i> , 2006	Prospective 2000–2005	20	36.4 (mean)	20	0.35 (mean)	1/6	16.7%	1/6	16.7%
Mancini <i>et al.</i> , 2007	Retrospective 2000–2003	145	34 (mean)	9	0.3–2.6 (range)	4/20	20%	11/20	55%
Eiffler <i>et al.</i> , 2008	Retrospective 1995–2006	145	34 (mean)	14	0.5–1.0 > 1.0	4/9	44.4%	3/9	33.3%
Shilo <i>et al.</i> , 2012a	Prospective 1995–2008	131	34 (mean)	131	≤ 1.0   1–20	0/14	/	2/14	22.2%
De Stefani <i>et al.</i> , 2012	Retrospective 2004–2011	23	30 (mean)	23	1.4 (mean)	1/14	7.2%	2/14	7.6%
Shilo <i>et al.</i> , 2012b	Retrospective 1997–2012	16	23–65 (range)	16	0.8–3.0 (range)	4/8	50%	2/8	7.6%
						26/31	84%	1/31	21.7%
						2/23	8.7%	5/23	21.7%
						5/16	31.2%	4/16	25%

(Continued)

Table 1 Continued

Reference	Study	Study population (n)	Age (yrs)	Histologically confirmed lesions (n)	Lesion size (cm)	Number of malignant lesions	Prevalence of malignancies among histologically confirmed lesions (%)	Number of LCTs	Prevalence of LCTs among histologically confirmed lesions (%)
Gentile et al., 2013	Retrospective 2009–2013	15	44.3 (mean)	15	0.95 (mean)	2/15	23%	5/15	33%
Isidori et al., 2014	Prospective 2006–2012	115	34 (median)	90	0.7 (median)	44/90	49%	21/90	23%
Ates et al., 2016	Retrospective 2010–2014	15	22 (median)	15	1.6 (mean)	1/15	7%	1/15	7%
Drudi et al., 2016	Prospective 2011–2014	18	31 (mean)	19	0.8 (mean)	8/19	42%	3/19	15.7%
Galosi et al., 2016	Prospective	28	38 (mean)	28	0.93 (mean)	6/28	21.4%	5/28	17.8%
Pozza et al., 2016	Prospective 2009–2014	106	34.5 (median)	64	0.6 (median)	37/64	58%	20/64	31%
Ma et al., 2017	Retrospective 2006–2011	1250	43 (mean)	42	0.7 (median)	23/42	54.7%	4/42	9.5%
Paffenholz et al., 2018	Retrospective 2000–2017	522	/	522	/	494/522	95%	9/522	1.7%
Lagabrielle et al., 2018	Retrospective	32	36 (mean)	32	0.85 (mean)	8/32	25%	23/32	72%
Scandura et al., 2018	Retrospective 2003–2016	81	40 (mean)	81	≤ 1.0	25/81	31%	23/81	28%

LCT: Leydig cell tumor

**Table II** Reasons for referral in patients with LCTs and seminoma.

Reason for referral	Reason for referral		P*
	LCTs	Seminomas	
<b>Infertility</b>	40/83 (48.2)	23/90 (25.6)	0.002
<b>General andrological screening</b>	9/83 (10.8)	19/90 (21.1)	0.110
<b>Varicocele</b>	8/83 (9.6)	7/90 (7.8)	0.663
<b>Klinefelter's syndrome</b>	6/83 (7.2)	0/90 (0)	0.001
<b>Testicular pain</b>	6/83 (7.2)	6/90 (6.7)	1.000
<b>Gynecomastia</b>	2/83 (2.4)	0/90 (0)	0.228
<b>Not known</b>	2/83 (2.4)	18/90 (20.0)	/
<b>Hypogonadism</b>	2/83 (2.4)	0/90 (0)	0.228
<b>Inguinal lymphadenopathy</b>	0/83 (0)	1/90 (1.1)	1.000
<b>Microlithiasis</b>	0/83 (0)	1/90 (1.1)	1.000
<b>Hydrocele</b>	1/83 (1.2)	0/90 (0)	0.479
<b>Previous cryptorchidism</b>	1/83 (1.2)	0/90 (0)	0.479
<b>Erectile dysfunction</b>	1/83 (1.2)	2/90 (2.2)	1.000
<b>Follow-up of a previous contralateral malignant tumor</b>	0/83 (0)	11/90 (12.2)	0.001
<b>Follow-up of a previous LCT</b>	5/83 (6.0)	0/90 (0)	0.041

\*LCTs versus seminomas. Relations between the qualitative data were examined by chi-square test or Fisher's exact tests.

able for 37 patients: 25 lesions (67.6%) showed a markedly hypointense signal on T2-WI and a rapid and marked wash-in followed by a prolonged washout, all features suggestive of LCT (Manganaro *et al.*, 2015). Five (13.5%) showed an uncertain response and the remaining seven lesions (18.9%) showed a weak and progressive wash-in.

Some studies (Bandak *et al.*, 2017; Zarrilli *et al.*, 2000) suggest that response to hCG may be helpful in the diagnosis of LCT. In our cohorts, hCG data were available for 10 patients with LCTs and 14 patients without testicular lesions. After hCG injection, serum total testosterone and estradiol increased significantly against baseline in both groups. Peak testosterone (48 h) and estradiol (24 h) levels were slightly higher in the LCT group than in the control group (respectively  $P = 0.001$  and  $P = 0.021$ , Fig. 3). Consistent with the increased steroidogenic production in LCT, the AUC values were higher in LCT patients than in the NoL group for testosterone ( $P = 0.003$ ), but not estradiol ( $P = 0.070$ ).

## Management and follow-up

Histological confirmation was proposed to all patients with a testicular solid lesion. TSS or RO was recommended according to the patient's history, size of the lesion, and specific individual needs. Intrasurgical US was used to locate nonpalpable tumors during surgery. LCTs were diagnosed surgically in 51 cases (40 by TSS and 11 by RO) and, in the 32 patients (38.5%) who declined surgery, by the lack of change in symptoms during surveillance. The lesion affected the right testis in 46 cases and the left in 37. No operated LCTs showed histological signs of malignancy (Kim *et al.*, 1985), except for two cases that showed a higher mitotic index and higher MIB-1 activity (a proliferation marker) and for this reason were considered 'high-grade' LCTs.

The median duration of follow-up was 66 months, ranging from 12 to 144 months for the whole cohort, 6 to 120 months (median, 60) for those treated with TSS, 24 to 144 months (median, 96) for those treated with orchiectomy, and 22 to 144 months (median, 60) for the surveillance group. During the prospective observational period, no patient had a distant metastasis and all patients were alive without evidence of disease at last data cut-off. Two patients were found to have high-grade LCTs on histology (mitotic index,  $> 10$ ); they were both treated with TSS (tumor size, 0.5 cm and 0.6 cm, respectively) and were disease-free at their last follow-up visit (60 and 84 months).

Five patients had a previous history of LCTs (recurrence rate 6.0%); two of these had undergone orchiectomy 21 and 7 years, respectively, before study entry, and three had undergone TSS 6, 6m and 4 years, respectively, before study entry. Four of these recurrences were contralateral and one was ipsilateral. The recurrence rate for malignant tumors was 12.2% (11/90 patients).

The changes in hormone and semen parameters in relation to treatment strategy are reported in Table V. No major differences were found in response to treatment comparing the baseline with follow-up at 6 or 12 months, suggesting that enucleation was not superior to active surveillance in improving biochemical and semen parameters. However, of the four patients with gynecomastia, two reported an improvement after enucleation of the lesion. One of the remaining two patients underwent surgical correction.

Follow-up reproductive data was available for 28 of the 40 LCT patients initially referred for infertility. Four patients reported fathering a natural pregnancy (one patient in the surveillance group and three in the TSS group) and four reported successful ART (one RO, two TSS, one in the surveillance group). Of the remaining patients, four failed ICSI (one RO, two TSS, one surveillance), and 16 were not seeking

**Table III Clinical features of all patients.**

	LCT			KS	Seminoma		P-value LCT versus seminoma	Normal karyotype	P-value LCT versus NoL
	Normal karyotype					NoL			
<b>N</b>	<b>77/83</b>	<b>6/83</b>	<b>90</b>		<b>2683</b>				
Clinical features, median values (25th–75th percentile)									
<b>Age at diagnosis (years)</b>	35.5 (30.2–42.0)*	31.0 (23.7–37.2)	34.0 (30.0–38.2)		32.0 (24.0–37.0)§	0.183			<0.001
<b>Mother's age at delivery (years)</b>	28.5 (26.0–32.0)	26.5 (24.0–33.5)	27.0 (22.7–31.0)		28.0 (24.0–32.0)	0.523			0.706
<b>Height (m)</b>	1.76 (1.74–1.80)	1.78 (1.74–1.84)	1.79 (1.75–1.85) <sup>o</sup>		1.78 (1.73–1.83)	0.046			0.524
<b>Weight (Kg)</b>	76.0 (70.7–88.0)	81.8 (71.0–92.5)	82.5 (75.0–90.0)		76.0 (70.0–85.0)§	0.058			0.467
<b>BMI (kg/m<sup>2</sup>)</b>	24.7 (22.8–26.0)	27.8 (24.8–29.3)	25.7 (23.7–27.6)		24.6 (22.6–27.7)	0.056			0.526
<b>Lesion volume (cm)</b>	0.6 (0.5–0.8)	0.7 (0.4–0.8)	1.2 (0.8–1.5) <sup>o</sup>		/	0.049			/
<b>Right testis volume (ml)</b>	11.4 (8.7–17.4)*	2.1 (1.6–2.7)	14.0 (9.5–19.3) <sup>o</sup>		15.0 (11.4–18.4)	0.016			<0.001
<b>Left testis volume (ml)</b>	12.0 (8.3–14.9)*	2.2 (1.7–2.8)	14.0 (9.3–18.3) <sup>o</sup>		13.9 (10.6–17.0)	0.004			<0.001
<b>Global testicular volume (ml)</b>	23.1 (18.2–29.7)*	4.4 (3.5–5.7)	26.0 (21.4–33.4)		28.8 (22.4–35.0)	0.081			0.017
Clinical feature, n (%)									
<b>Gynecomastia</b>	3/77 (3.9*)	1/6 (16.7)	1/90 (1.1)		0/2683 (0)§	0.196			<0.001
<b>Cryptorchidism</b>	12/77 (15.6*)	0/6 (0)	16/90 (17.8)		29/2683 (1.1)§	0.680			<0.001
<b>Previous contralateral malignant tumor</b>	0/77 (0)	0/6 (0)	11/90 (12.2) <sup>o</sup>		11/2683 (0.4)§	0.001			1.000
<b>Previous contralateral LCT</b>	5/77 (5.2)*	0/6 (0)	0/90 (0)		0/2683 (0)	0.024			<0.001

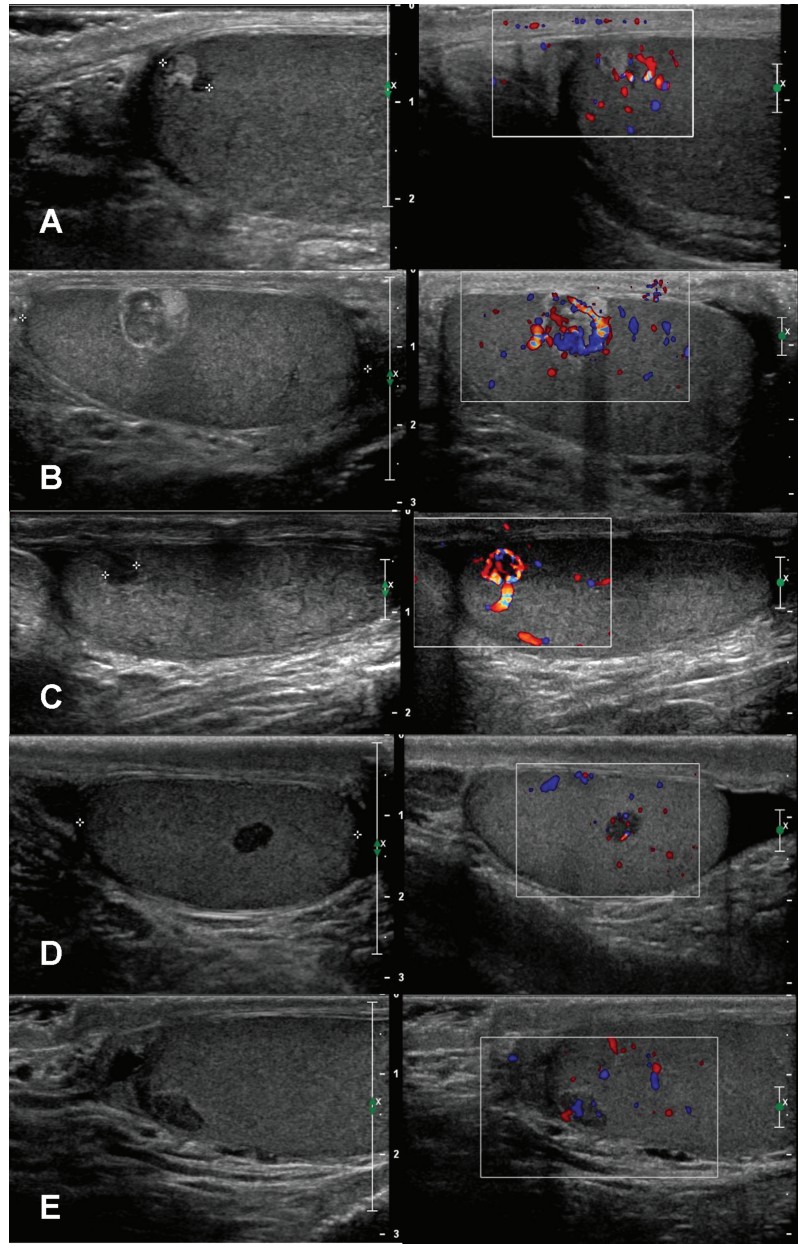
Values are expressed as median and interquartile ranges and in numbers and percentage. KS: Klinefelter Syndrome; NoL: patients without testicular lesions. Mann–Whitney comparisons between groups with normal karyotype: \*LCT versus Controls, <sup>o</sup>LCT versus Seminoma, §Seminoma versus Controls. Groups were compared using the Mann–Whitney test for continuous variables or odds ratio (OR) for categorical variables.



**Table IV** Hormone and semen analysis data and histological diagnosis for all patients.

	LCT		Seminoma		NoL	
	n.r.	77	90	2683	P-value versus Seminoma	P-value versus NoL
<b>Hormone Data</b>						
FSH (mIU/ml)	1.38–9.58	7.3 (3.6–15.9)*	7.0 (3.7–11.7)	4.0 (2.5–7.2)§	0.703	0.001
LH (mIU/ml)	1.8–8.16	4.7 (2.9–7.0)*	3.9 (2.5–6.7)	3.2 (2.3–4.6)§	0.190	0.004
Te (nmol/l)	10.4–38.2	16.8 (13.9–20.8)	15.5 (13.7–19.9)	19.2 (15.5–23.9)§	0.423	0.007
SHBG (nmol/l)	11.2–78.1	43.3 (34.8–49.3)*	33.1 (28.5–45.6) <sup>o</sup>	32.3 (23.0–43.4)	0.018	0.280
E <sub>2</sub> (pg/ml)	25–107	25.0 (19.0–34.7)	28.5 (19.7–34.2)	26.0 (19.8–32.0)	0.584	0.240
InhB (pg/ml)	80–380	60.3 (10.9–128.8)	83.1 (54.6–123.5)	76.9 (32.2–128.0)	0.237	0.634
Prolactin (ng/ml)	2.6–13.13	10.1 (7.9–17.6)	8.2 (5.8–12.4)	/	0.074	0.682
Te/LH ratio	/	3.4 (1.9–6.2)*	4.2 (2.0–7.3)	6.0 (3.9–8.8) §	0.383	<0.001
Te/E <sub>2</sub> ratio	/	0.7 (0.5–0.9)	0.6 (0.5–0.8)	0.8 (0.6–1.0)	0.387	0.029
<b>Semen Analysis Data</b>						
Volume (ml)	3.7 (1.5–6.8)	2.8 (2.0–3.5)	3.1 (2.2–4.0)	2.9 (2.0–4.0)§	0.049	0.049
pH	>7.2	7.5 (7.4–7.7)*	7.5 (7.4–7.6)	7.4 (7.3–7.5)§	0.319	0.002
Sperm concentration (10 <sup>6</sup> /ml)	73 (15–213)	13.5 (0–47.7)*	30.0 (7.8–65.0) <sup>o</sup>	25.0 (3.0–60.0)	0.029	0.607
Total sperm number (10 <sup>6</sup> /ejaculate)	255 (39–802)	31.5 (0–102.3)*	102.4 (32.0–200.0) <sup>o</sup>	66.0 (7.6–176.0)	0.011	0.979
Total motility (%)	61 (40–78)	20.0 (0–50)	45.0 (16.5–50.0) <sup>o</sup>	30.0 (10.0–50.0)	0.049	0.072
Normal morphology (%)	15 (4–44)	10.0 (0–22.0)*	17.0 (7.7–23.0)	23.0 (12.0–32.0)§	0.137	0.004
Leukocyte count (10 <sup>6</sup> /ml)	<1.0	0.5 (0.3–1.00)	0.6 (0.4–0.8)	0.6 (0.4–0.9)	0.563	0.200

Values are expressed as median and interquartile ranges. n.r. = normal range; Te = total testosterone; SHBG = sex hormone-binding globulin; E<sub>2</sub> = estradiol; InhB = inhibin B. Mann–Whitney comparisons between groups with normal karyotype: \*LCT versus NoL; <sup>o</sup>LCT versus Seminoma; §Seminoma versus NoL.



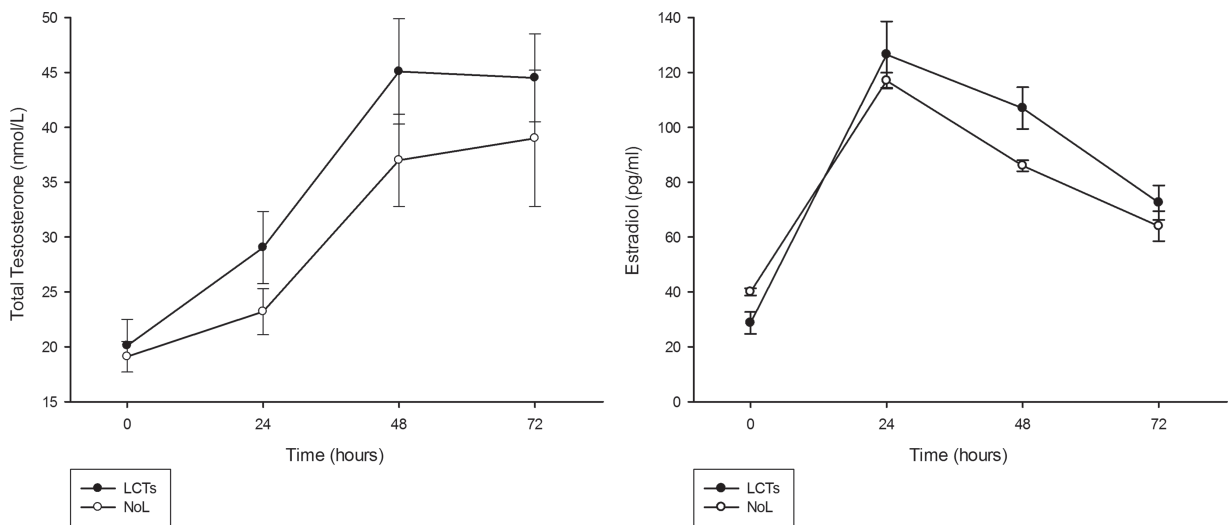
**Figure 2** Examples of the appearance of LCTs. B-mode images are shown on the left side of each panel and correspondent color Doppler appearance is shown on the right. Panel **A** shows a 0.5 cm hyperechoic lesion; panel **B** shows an inhomogeneous lesion of 1.1 cm; panels **C**, **D**, and **E** show three hypoechoic LCTs, respectively, 0.4 cm, 0.5 cm, and 0.8 cm; all the lesions show internal vascularization (see right side), identified as LCTs at histology.

children. Twenty-two patients (26.5%) started testosterone therapy following the development of symptomatic subclinical hypogonadism (6 patients) or manifest hypogonadism (16 patients).

## Discussion

The present study reports the clinical, hormonal, seminal, and radiological features and long-term follow-up data of the largest cohort of patients with LCTs evaluated prospectively using a uniform protocol from a single referral center.

The main findings were as follows: LCTs are strongly associated with male infertility, cryptorchidism, and gynecomastia, supporting the hypothesis that testicular dysgenesis syndrome (TDS) plays a role in the development of these tumors; the impairment in the tubular and stromal compartment observed in the testes of patients with LCTs seems independent of the tumor itself, as it does not improve after surgery and appears worse than in the seminoma group; no single test is 100% accurate in preoperatively distinguishing LCTs from germ cell tumors, but the novel diagnostic techniques CEUS and MRI proved reliable; management of patients



**Figure 3** Changes in patient serum hormone levels measured at 0, 24, 48, and 72 hours before and after hCG injection. hCG (5000 IU) was administered i.m. Peak testosterone (48 h) and estradiol (24 h) levels were slightly higher in the LCT group than in the control group. Consistent with the increased steroidogenic production in LCT, the AUC values were higher in LCT patients than in the NoL (patients without testicular lesions) group for testosterone, but not estradiol. hCG test data were available for 10 patients with LCTs and 14 patients without testicular lesions. Data are mean  $\pm$  SD.

with LCTs requires attention to preserving fertility, and TSS should therefore replace RO; in compliant patients, active surveillance through clinical and radiological follow-up is a safe alternative option for small LCTs.

In the infertile population, testicular tumors have been reported as 20-fold more frequent than in the general population, due to screening and related disorders identified as risk factors (cryptorchidism, Klinefelter's syndrome, or gonadal dysgenesis syndrome) (Raman *et al.*, 2005). The recent literature includes several series of small incidental, asymptomatic, non-palpable testicular tumors discovered due to the increase in referrals for scrotal US (Ates *et al.*, 2016; Bozzini *et al.*, 2013; Carmignani *et al.*, 2004; Colpi *et al.*, 2005; De Stefani *et al.*, 2012; Djaladat, 2015; Drudi *et al.*, 2016; Eifler *et al.*, 2008; Galosi *et al.*, 2016; Gentile *et al.*, 2013; Giannarini *et al.*, 2007; Hopps and Goldstein, 2002; Isidori *et al.*, 2014; Lagabrielle *et al.*, 2018; Leroy *et al.*, 2003; Ma *et al.*, 2017; Mancini *et al.*, 2007; Muller *et al.*, 2006; Paffenholz *et al.*, 2018; Powell and Tarter, 2006; Raman *et al.*, 2005; Scandura *et al.*, 2018; Sheynkin *et al.*, 2004; Shilo *et al.*, 2012a; Shilo *et al.*, 2012b). Most of these studies demonstrated a high prevalence of LCTs among nonpalpable masses, with an overall mean prevalence value of 26.6% [18.3–34.9 95% CI] (Table I), in contrast to large palpable testicular tumors, which are malignant in >90% of cases (Bozzini *et al.*, 2013, Elert *et al.*, 2002; Giannarini *et al.*, 2008; Sheynkin *et al.*, 2004). Paffenholz *et al.* (2018) reported the lowest prevalence of LCTs (1.7%) in 9 of 522 patients operated on for testicular lesions. However, only lesion volume (cm<sup>3</sup>) was reported and therefore it is likely that the larger sizes inflated the number of malignancies. In line with these reports, even using the most conservative approach—i.e. considering only histologically confirmed lesions and excluding all follow-up diagnoses—the prevalence of LCTs in our series was 26% (51 of all the 187 nonpalpable lesions detected in the entire

study period). These data make it imperative to study the origin, related symptoms, and natural history of this 'not-so-rare' endocrine tumor.

It is hypothesized that many cases of abnormal spermatogenesis, cryptorchidism, penile malformations, and testicular cancer may have a common etiology, such as an irreversible developmental disorder originating in early fetal life and resulting in TDS (Joensen *et al.*, 2008). Leydig cell hyperplasia is a frequent finding in patients with impaired spermatogenesis and other TDS-related disorders, often in the form of large clusters called micronodules (Joensen *et al.*, 2008; Soerensen *et al.*, 2016; Tarsitano *et al.*, 2018). Leydig cell micronodules, defined as more than 15 Leydig cells in a cross-section, have previously been associated with a low testosterone/LH ratio, reflecting an endocrine dysfunction (Joensen *et al.*, 2008). Hormone impairment was observed in our cohort in both LCT and seminoma groups when compared to the NoL group. The reason for the growth of Leydig cell micronodules in hypogonadal men is unknown, but it has been speculated that it reflects primary Leydig cell failure as a result of TDS. This could in turn raise LH levels to compensate for impaired testosterone synthesis, causing chronic Leydig cell compartment hyperstimulation, a mechanism that was described by Christensen *et al.* as inducing Leydig cell hyperplasia/adenoma in rats (Christensen and Peacock, 1980). Although LH plays an important role in Leydig cell proliferation, the maturation and proliferation of these cells is also affected by many other paracrine and endocrine signals, including anti-Müllerian hormone, inhibin, and other growth factors (Joensen *et al.*, 2008). Samson *et al.* (2004) found that endocrine gland-derived vascular endothelial growth factor (EG-VEGF), a human angiogenic mitogen, is expressed in the Leydig cells of human fetal testes from 14 weeks' gestation, and that EG-VEGF-mediated angiogenesis at this stage is induced by LH and appears critical for normal testicular homeostasis. Furthermore,

**Table V** Changes in hormone and semen measures after surgical enucleation or during active surveillance.

	LCTs				n.r.
	Enucleation Group		Surveillance Group		
	Baseline	6–12 months follow-up	Baseline	6–12 months follow-up	
n	40	40	32	32	
<b>FSH (mIU/ml)</b>	4.9 (2.4–32.1)	6.8 (5.3–24.22)	10.1 (6.6–29.6)	16.4 (6.0–25.3)	1.38–9.58
<b>LH (mIU/ml)</b>	5.8 (2.7–7.2)	5.5 (3.6–6.9)	4.9 (3.5–7.4)	6.4 (3.5–9.8)	1.8–8.16
<b>Te (nmol/l)</b>	20.5 (13.0–24.7)	18.7 (9.0–25.7)	19.0 (14.4–20.1)	17.7 (13.0–25.8)	10.4–38.2
<b>SHBG (nmol/l)</b>	32.8 (26.4–40.0)	34.0 (25.4–34.0)	46.2 (39.6–55.7)	55.3 (36.3–67.7)	11.2–78.1
<b>E<sub>2</sub> (pg/ml)</b>	25.0 (12.5–25.0)	15.1 (9.2–46.7)	25.7 (19.8–37.5)	25.0 (16.0–25.0)	25–107
<b>InhB (pg/ml)</b>	/	/	80.6 (47.0–117.5)	85 (52.0–102.0)	80–380
<b>Prolactin (ng/ml)</b>	21.1 (8.4–35.1)	17.0 (8.5–48.5)	10.9 (5.1–16.5)	18.4 (9.0–18.4)	2.6–13.13
<b>Te/LH ratio</b>	4.1 (2.0–6.3)	2.7 (1.3–5.2)	3.2 (2.0–7.0)	1.4 (1.2–1.6)	/
<b>Te/E<sub>2</sub> ratio</b>	0.6 (0.4–0.8)	1.0 (0.4–2.0)	0.7 (0.5–0.9)	0.5 (0.5–0.7)	/
<b>Volume (ml)</b>	2.3 (1.6–3.4)	2.5 (1.3–3.8)	2.2 (1.2–2.7)	2.0 (1.6–2.3)	3.7 (1.5–6.8)
<b>pH</b>	7.5 (7.4–7.6)	7.5 (7.4–7.6)	7.4 (7.2–7.6)	7.5 (7.5–7.6)	>7.2
<b>Sperm concentration (10<sup>6</sup>/ml)</b>	4.5 (0.1–31.5)	3.0 (0.3–33.0)	12.0 (0.1–70.0)	8.0 (3.0–57.0)	73 (15–213)
<b>Total sperm number (10<sup>6</sup>/ejaculate)</b>	15.7 (0.4–57)	9.3 (1.2–58.5)	30.0 (0.4–57)	12.0 (6.0–136.0)	255 (39–802)
<b>Total motility (%)</b>	15.0 (0–40.2)	15.5 (0–28.7)	10.0 (0–50)	25.0 (7.5–42.5)	61 (40–78)
<b>Normal morphology (%)</b>	4.5 (0–22.5)	5.5 (0–17.7)	10.0 (0–22.0)	10.0 (4.0–18.5)	15 (4–44)
<b>Leukocyte count (10<sup>6</sup>/ml)</b>	0.4 (0.2–0.6)	0.6 (0.2–1.0)	0.8 (0.3–1.0)	0.6 (0.3–0.8)	<1.0

Values are expressed as median and interquartile ranges. Groups were compared using the Mann–Whitney test for paired data.

they found that EG-VEGF secretion can promote the growth of LCTs, suggesting a role for the LH signaling pathway in tumor progression.

Whether or not LCTs derive from degenerated islets of Leydig cell hyperplasia remains unknown, and the molecular steps leading to tumor transformation merit further study. Hormone evaluation in our cohort showed that patients with LCT had significantly higher gonadotrophin and lower testosterone levels than the controls, even if they were still within the ‘normal’ range. We also found higher levels of SHBG in the LCT group than in either the seminoma or NoL group. The latter finding may reflect abnormal estrogen secretion from LCTs, but could also mitigate some of the clinical symptoms of steroid excess, given that SHBG lowers levels of bioavailable androgens. Patients with LCTs had a lower sperm concentration, lower total sperm number, and reduced sperm motility and morphology compared to subjects without testicular lesions. Our findings point toward an impairment in the tubular and stromal compartments of the affected testes that persists even after removal of the tumor.

Testicular volume was reduced in 40% of patients with LCTs, confirming that these tumors tend to occur in morphologically and functionally compromised testes. The higher prevalence of cryptorchidism (15.6%) suggests that this risk factor, traditionally linked only to germ cell tumors, should also be considered in relation to LCTs, as hypothesized in the TDS model (Soerensen et al., 2016).

Most patients with LCTs were asymptomatic and the mass was discovered incidentally. The typical symptoms and signs associated with

LCTs, including gynecomastia, were less frequent in our series (4.8%) compared to literature reports (Narula and Carlson, 2014). In contrast with baseline values, hCG testing revealed a slightly higher stimulated testosterone and estradiol output in LCTs than in the NoL group.

The use of second-level investigations (namely CEUS and MRI) allowed us to correctly identify the majority of cases prior to surgery. Active surveillance is feasible only when both tests are consistent with a diagnosis of LCT and, conversely, RO should be considered when both are suggestive of seminoma. The rationale for an active surveillance strategy is reinforced by the fact that surgical resection—albeit associated with excellent results and very few side effects—did not significantly improve the biochemical and seminal output. A conservative approach is particularly important in infertile or monorchid patients.

The long follow-up period of up to 144 months (median 66 months) is a unique feature of the present study. All patients were disease-free at last visit regardless of the adopted therapeutic choice, reinforcing the fact that the conservative approach appears safe in LCTs. Interestingly, a significant proportion of LCTs were recurrent or bilateral tumors, adding weight to the concept of ‘organ-disease’. The seminoma recurrence rate was also higher than previous literature reports (Alber et al., 2015), but was in line with the current epidemiological forecast, which predicts an increase in testicular tumors in southern European countries (Park et al., 2018). At the last follow-up visit, we observed that patients referred for infertility did not improve their fertility potential after tumor resection, and only 28% had

fathered children (whether naturally or through ART), while 26.5% of the entire cohort had started testosterone therapy due to the development of symptomatic subclinical hypogonadism (6/22) or manifest hypogonadism (16/22). This supports the TDS hypothesis and the need for prevention strategies (Olesen *et al.*, 2018). In this respect, cryopreservation could be considered in these patients straight after diagnosis, and they should be monitored for hypogonadism later in life.

## Limitations

This study has some limitations. First, hCG and second-line diagnostic investigations were not available for all tumor patients. Second, ours is a referral center for infertility, thus a selection bias may have altered the baseline features of the LCT population. However, given that the comparison cohorts were also from the same center and had been managed with a similar protocol, we do not expect a significant effect. In contrast, the study also has several advantages: it is the largest cohort of LCTs prospectively observed for a long period, it reports full data on seminal, hormonal, imaging, and surgical outcome, and it has two comparison cohorts.

## Conclusion

LCTs are the most common stromal tumor of the testis and account for a significant proportion of incidentally found small testicular tumors. They have an excellent oncological prognosis. Active surveillance appears a safe option, once the diagnosis is ascertained using the latest imaging approaches. However, patients with LCTs are at greater risk of endocrine and spermatogenesis abnormalities even when the tumor is resected, and thus require long-term follow-up and prompt efforts to preserve fertility after diagnosis.

## Acknowledgments

We wish to acknowledge Policlinico Umberto I—Sapienza University ‘Testis Unit’, a multidisciplinary team of dedicated testicular cancer specialists working as a cohesive group with access to all the facilities required to deliver high-quality care throughout the testicular cancer pathway: Prof. Emanuela Anastasi, Prof. Antonio Ciardi, Prof. Mauro Ciccariello, Prof. Enrico Cortesi, Prof. Cristiano Cristini, Prof. Giorgio Franco, Dr. Alain Gelibter, Dr. Andrea Lemma, Prof. Costantino Leonardo, Prof. Francesco Lombardo, Prof. Massimo Magliocca, Prof. Lucia Manganaro, Prof. Giovanni Martino, Prof. Donatella Paoli, Prof. Antonio Radicioni, Prof. Francesco Romanelli, Prof. Iolanda Speranza, and Prof. Vincenzo Tombolini.

We also wish to thank Marie-Hélène Hayles for her linguistic revision services.

## Authors’ roles

C.P.—substantial contributions to conception and design, acquisition of data, analysis and interpretation of data; drafting the article and revising it critically for important intellectual content; and final approval of the version to be published. R.P.—substantial contributions to conception and design, acquisition of data, analysis and interpretation of data;

drafting the article and revising it critically for important intellectual content; and final approval of the version to be published. M.T.—substantial contributions to acquisition of data, analysis of data and final approval of the version to be published. M.G.T.—substantial contributions to acquisition of data, analysis of data and final approval of the version to be published. E.S.—substantial contributions to interpretation of data; drafting the article and revising it critically; and final approval of the version to be published. G.F.—substantial contributions to acquisition of data; critical revision of the article; and final approval of the version to be published. V.C.—substantial contributions to conception and design and final approval of the version to be published. A.L.—substantial contributions to the critical revision of the article for important intellectual content; and final approval of the version to be published. A.M.I.—substantial contributions to conception and design, acquisition of data, analysis and interpretation of data; drafting the article and revising it critically for important intellectual content; and final approval of the version to be published. D.G.—substantial contributions to conception and design, acquisition of data, analysis and interpretation of data; drafting the article and revising it critically for important intellectual content; and final approval of the version to be published.

## Funding

Ministry of Education, University and Research (MIUR) (Research Grant MIUR 2015ZTT5KB).

## Conflict of interest

The authors report no conflicts of interest.

## References

- Albers P, Albrecht W, Algaba F, Bokemeyer C, Cohn-Cedermark G, Fizazi K, Horwich A, Laguna MP, Nicolai N, Oldenburg J *et al.* Guidelines on testicular cancer: 2015 update. *Eur Urol* 2015;**68**:1054–1068.
- Ates F, Malkoc E, Zor M, Demirel Z, Alp BF, Basal S, Guragac A, Yildirim I. Testis-sparing surgery in small testicular masses not suspected to be malignant. *Clin Genitourin Cancer* 2016;**14**:e49–e53.
- Bandak M, Jorgensen N, Juul A, Lauritsen J, Gundgaard Kier MG, Mortensen MS, Daugaard G. Preorchietomy Leydig cell dysfunction in patients with testicular cancer. *Clin Genitourin Cancer* 2017;**15**:e37–e43.
- Borghesi M, Brunocilla E, Schiavina R, Gentile G, Dababneh H, Della Mora L, del Prete C, Franceschelli A, Colombo F, Martorana G. Role of testis sparing surgery in the conservative management of small testicular masses: oncological and functional perspectives. *Actas Urol Esp* 2015;**39**:57–62.
- Bozzini G, Picozzi S, Gadda F, Colombo R, Decobelli O, Palou J, Colpi G, Carmignani L. Long-term follow-up using testicle-sparing surgery for Leydig cell tumor. *Clin Genitourin Cancer* 2013;**11**:321–324.
- Bozzini G, Ratti D, Carmignani L, en representación de Young Academic Urologists Men’s Health Group. Treatment of leydig cell tumours of the testis: can testis-sparing surgery replace radical orchidectomy? Results of a systematic review. *Actas Urol Esp* 2017;**41**:146–154.

- Carmignani L, Gadda F, Gazzano G, Nerva F, Mancini M, Ferruti M, Bulfamante G, Bosari S, Coggi G, Rocco F et al. High incidence of benign testicular neoplasms diagnosed by ultrasound. *J Urol* 2003;**170**:1783–1786.
- Carmignani L, Gadda F, Mancini M, Gazzano G, Nerva F, Rocco F, Colpi GM. Detection of testicular ultrasonographic lesions in severe male infertility. *J Urol* 2004;**172**:1045–1047.
- Christensen AK, Peacock KC. Increase in Leydig cell number in testes of adult rats treated chronically with an excess of human chorionic gonadotropin. *Biol Reprod* 1980;**22**:383–391.
- Colpi GM, Carmignani L, Nerva F, Guido P, Gadda F, Castiglioni F. Testicular-sparing microsurgery for suspected testicular masses. *BJU Int* 2005;**96**:67–69.
- De Stefani S, Isgro G, Varca V, Pecchi A, Bianchi G, Carmignani G, Derchi LE, Micali S, Maccio L, Simonato A. Microsurgical testis-sparing surgery in small testicular masses: seven years retrospective management and results. *Urology* 2012;**79**:858–862.
- Djaladat H. Organ-sparing surgery for testicular tumours. *Curr Opin Urol* 2015;**25**:116–120.
- Drudi FM, Maghella F, Martino G, Messineo D, Ciccariello M, Cantisani V, Malpassini F, Liberatore M, D'Ambrosio F. Detection of small testicular masses in monorchid patients using US, CPDUS, CEUS and US-guided biopsy. *J Ultrasound* 2016;**19**:25–28.
- Effler JB Jr, King P, Schlegel PN. Incidental testicular lesions found during infertility evaluation are usually benign and may be managed conservatively. *J Urol* 2008;**180**:261–264 discussion 265.
- Elert A, Olbert P, Hegele A, Barth P, Hofmann R, Heidenreich A. Accuracy of frozen section examination of testicular tumors of uncertain origin. *Eur Urol* 2002;**41**:290–293.
- Galosi AB, Fulvi P, Fabiani A, Servi L, Filosa A, Leone L, Marronaro A, Caraceni E, Montironi R. Testicular sparing surgery in small testis masses: a multinstitutional experience. *Arch Ital Urol Androl* 2016;**88**:320–324.
- Gentile G, Brunocilla E, Franceschelli A, Schiavina R, Pultrone C, Borghesi M, Romagnoli D, Cevenini M, Dababneh H, Corcioni B et al. Can testis-sparing surgery for small testicular masses be considered a valid alternative to radical orchiectomy? A prospective single-center study. *Clin Genitourin Cancer* 2013;**11**:522–526.
- Giannarini G, Mogorovich A, Bardelli I, Manassero F, Selli C. Testis-sparing surgery for benign and malignant tumors: a critical analysis of the literature. *Indian J Urol* 2008;**24**:467–474.
- Giannarini G, Mogorovich A, Menchini Fabris F, Morelli G, De Maria M, Manassero F, Loggini B, Pingitore R, Cavazzana A, Selli C. Long-term followup after elective testis sparing surgery for Leydig cell tumors: a single center experience. *J Urol* 2007;**178**:872–876 quiz 1129.
- Hopps CV, Goldstein M. Ultrasound guided needle localization and microsurgical exploration for incidental nonpalpable testicular tumors. *J Urol* 2002;**168**:1084–1087.
- Isidori AM, Pozza C, Gianfrilli D, Giannetta E, Lemma A, Pofi R, Barbagallo F, Manganaro L, Martino G, Lombardo F et al. Differential diagnosis of nonpalpable testicular lesions: qualitative and quantitative contrast-enhanced US of benign and malignant testicular tumors. *Radiology* 2014;**273**:606–618.
- Joensen UN, Jorgensen N, Rajpert-De Meyts E, Skakkebaek NE. Testicular dysgenesis syndrome and Leydig cell function. *Basic Clin Pharmacol Toxicol* 2008;**102**:155–161.
- Kim I, Young RH, Scully RE. Leydig cell tumors of the testis. A clinicopathological analysis of 40 cases and review of the literature. *Am J Surg Pathol* 1985;**9**:177–192.
- Laclergerie F, Mouillet G, Frontczak A, Balssa L, Eschwege P, Saussine C, Larre S, Cormier L, Vuillemin AT, Kleinclauss F. Testicle-sparing surgery versus radical orchiectomy in the management of Leydig cell tumors: results from a multicenter study. *World J Urol* 2017.
- Lagabrielle S, Durand X, Droupy S, Izard V, Marcelli F, Huyghe E, Ferriere JM, Ferretti L. Testicular tumours discovered during infertility workup are predominantly benign and could initially be managed by sparing surgery. *J Surg Oncol* 2018;**118**:630–635.
- Leonhartsberger N, Pichler R, Stoehr B, Horninger W, Steiner H. Organ-sparing surgery is the treatment of choice in benign testicular tumors. *World J Urol* 2014;**32**:1087–1091.
- Leonhartsberger N, Ramoner R, Aigner F, Stoehr B, Pichler R, Zangerl F, Fritzer A, Steiner H. Increased incidence of Leydig cell tumours of the testis in the era of improved imaging techniques. *BJU Int* 2011;**108**:1603–1607.
- Leroy X, Rigot JM, Aubert S, Ballereau C, Gosselin B. Value of frozen section examination for the management of nonpalpable incidental testicular tumors. *Eur Urol* 2003;**44**:458–460.
- Loeser A, Vergo DC, Katzenberger T, Brix D, Kocot A, Spahn M, Gerharz EW, Riedmiller H. Testis-sparing surgery versus radical orchiectomy in patients with Leydig cell tumors. *Urology* 2009;**74**:370–372.
- Ma W, Sarasohn D, Zheng J, Vargas HA, Bach A. Causes of avascular hypoechoic testicular lesions detected at scrotal ultrasound: can they be considered benign? *AJR Am J Roentgenol* 2017;**209**:110–115.
- Mameli C, Selvaggio G, Cerini C, Bulfamante G, Madia C, Riccipetroni G, Zuccotti GV. Atypical Leydig cell tumor in children: report of 2 cases. *Pediatrics* 2016;**138**.
- Mancini M, Carmignani L, Gazzano G, Sagone P, Gadda F, Bosari S, Rocco F, Colpi GM. High prevalence of testicular cancer in azoospermic men without spermatogenesis. *Hum Reprod* 2007;**22**:1042–1046.
- Manganaro L, Saldari M, Pozza C, Vinci V, Gianfrilli D, Greco E, Franco G, Sergi ME, Scialpi M, Catalano C et al. Dynamic contrast-enhanced and diffusion-weighted MR imaging in the characterisation of small, non-palpable solid testicular tumours. *Eur Radiol* 2018;**28**:554–564.
- Manganaro L, Vinci V, Pozza C, Saldari M, Gianfrilli D, Pofi R, Bernardo S, Cantisani V, Lenzi A, Scialpi M et al. A prospective study on contrast-enhanced magnetic resonance imaging of testicular lesions: distinctive features of Leydig cell tumours. *Eur Radiol* 2015;**25**:3586–3595.
- Maxwell F, Izard V, Ferlicot S, Rachas A, Correias JM, Benoit G, Bellin MF, Rocher L. Colour Doppler and ultrasound characteristics of testicular Leydig cell tumours. *Br J Radiol* 2016;**89**:20160089.
- Muller T, Gozzi C, Akkad T, Pallwein L, Bartsch G, Steiner H. Management of incidental impalpable intratesticular masses of  $\leq 5$  mm in diameter. *BJU Int* 2006;**98**:1001–1004.
- Narula HS, Carlson HE. Gynaecomastia—pathophysiology, diagnosis and treatment. *Nat Rev Endocrinol* 2014;**10**:684–698.
- Nason GJ, Redmond EJ, Considine SW, Omer SI, Power D, Sweeney P. The natural history of Leydig cell testicular tumours: an analysis of the National Cancer Registry. *Ir J Med Sci* 2017.
- Nicolai N, Necchi A, Raggi D, Biononi D, Catanzaro M, Piva L, Stagni S, Maffezzini M, Torelli T, Fare E et al. Clinical outcome in tes-

- ticular sex cord stromal tumors: testis sparing vs. radical orchiectomy and management of advanced disease. *Urology* 2015;**85**:402–406.
- Olesen IA, Joensen UN, Petersen JH, Almstrup K, Rajpert-De Meyts E, Carlsen E, McLachlan R, Juul A, Jorgensen N. Decrease in semen quality and Leydig cell function in infertile men: a longitudinal study. *Hum Reprod* 2018;**33**:1963–1974.
- Paffenholz P, Held L, Loosen SH, Pfister D, Heidenreich A. Testis sparing surgery for benign testicular masses: diagnostics and therapeutic approaches. *J Urol* 2018;**200**:353–360.
- Park JS, Kim J, Elghiaty A, Ham WS. Recent global trends in testicular cancer incidence and mortality. *Medicine* 2018;**97**:e12390.
- Powell TM, Tarter TH. Management of nonpalpable incidental testicular masses. *J Urol* 2006;**176**:96–98 discussion 99.
- Pozza C, Gianfrilli D, Fattorini G, Giannetta E, Barbagallo F, Nicolai E, Cristini C, Di Pierro GB, Franco G, Lenzi A *et al*. Diagnostic value of qualitative and strain ratio elastography in the differential diagnosis of non-palpable testicular lesions. *Andrology* 2016;**4**:1193–1203.
- Raman JD, Nobert CF, Goldstein M. Increased incidence of testicular cancer in men presenting with infertility and abnormal semen analysis. *J Urol* 2005;**174**:1819–1822 discussion 1822.
- Samson M, Peale FV Jr, Frantz G, Rioux-Leclercq N, Rajpert-De Meyts E, Ferrara N. Human endocrine gland-derived vascular endothelial growth factor: expression early in development and in Leydig cell tumors suggests roles in normal and pathological testis angiogenesis. *J Clin Endocrinol Metab* 2004;**89**:4078–4088.
- Santos-Silva R, Bonito-Vitor A, Campos M, Fontoura M. Gonadotropin-dependent precocious puberty in an 8-year-old boy with leydig cell testicular tumor. *Horm Res Paediatr* 2014;**82**:133–137.
- Scandura G, Verrill C, Protheroe A, Joseph J, Ansell W, Sahdev A, Shamash J, Berney DM. Incidentally detected testicular lesions <10 mm in diameter: can orchidectomy be avoided? *BJU Int* 2018;**121**:575–582.
- Sheynkin YR, Sukkariéh T, Lipke M, Cohen HL, Schulsinger DA. Management of nonpalpable testicular tumors. *Urology* 2004;**63**:1163–1167 discussion 1167.
- Shilo Y, Zisman A, Lindner A, Raz O, Strauss S, Siegel YI, Segal M, Sandbank J, Leibovici D. The predominance of benign histology in small testicular masses. *Urol Oncol* 2012a;**30**:719–722.
- Shilo Y, Zisman A, Raz O, Lang E, Strauss S, Sandbank J, Segal M, Siegel YI, Leibovici D. Testicular sparing surgery for small masses. *Urol Oncol* 2012b;**30**:188–191.
- Soerensen RR, Johannsen TH, Skakkebaek NE, Rajpert-De Meyts E. Leydig cell clustering and Reinke crystal distribution in relation to hormonal function in adult patients with testicular dysgenesis syndrome (TDS) including cryptorchidism. *Hormones* 2016;**15**:518–526.
- Tarsitano MG, Bandak M, Jorgensen N, Skakkebaek NE, Juul A, Lenzi A, Daugaard G, Rajpert-De Meyts E. Quantification of the Leydig cell compartment in testicular biopsies and association with biochemical Leydig cell dysfunction in testicular cancer survivors. *Andrology* 2018;**6**:748–755.
- World Health Organization DoRHaR. *WHO Laboratory Manual for the Examination of Human Semen and Sperm-Cervical Mucus Interaction*. 1999.
- World Health Organization DoRHaR. *WHO Laboratory Manual for the Examination and Processing of Human Semen*. 2010.
- Zarrilli S, Lombardi G, Paesano L, Di Somma C, Colao A, Mirone V, De Rosa M. Hormonal and seminal evaluation of Leydig cell tumour patients before and after orchiectomy. *Andrologia* 2000;**32**:147–154.