

# Physéal-Sparing Transosseous-Equivalent Arthroscopic Rotator Cuff Repair



Paul E. Caldwell III, M.D., Adam J. Heisinger, D.O., and Sara E. Pearson, Ph.D.

**Abstract:** Rotator cuff injuries in the skeletally immature population are uncommon, with most tears resulting from trauma or overuse in throwing athletes. Although the literature has referenced multiple repair methods in the pediatric population, an arthroscopic physéal-sparing technique has yet to be described. Given the proximity of the proximal humerus growth plate to the typical anchor placement during rotator cuff repair, we advocate a technique that avoids violation of the proximal humeral physis. Our technique shows an arthroscopic physéal-sparing repair using standard arthroscopic equipment and fluoroscopy.

Rotator cuff injuries in the pediatric population are infrequent. As opposed to degenerative rotator cuff tears that occur in the adult population, adolescent tears typically result from traumatic injuries. Contact sports such as football have been documented to carry a high risk of rotator cuff tears in the pediatric population.<sup>1</sup> Adolescent athletes in overhead sports also have a higher incidence of rotator cuff tears, and throwing has been implicated in overuse tears resulting from the significant forces to the developing shoulder.<sup>2</sup> Repetitive microtrauma is thought to precipitate undersurface tears of the supraspinatus, which may progress to full-thickness tears. We report our preferred technique to address traumatic pediatric rotator cuff tears using an arthroscopic physéal-sparing transosseous-equivalent approach.

## Surgical Technique

Physéal-sparing transosseous-equivalent arthroscopic rotator cuff repair is performed in the lateral decubitus position but is certainly amenable to the beach chair position as well. A standard posterior portal is created, and a diagnostic arthroscopy is performed. Additional intra-articular pathology may be addressed in the same setting. The undersurface of the rotator cuff is evaluated to establish the size and depth of the tear, as well as any fracture of the greater tuberosity (Fig 1, Video 1). This assessment may determine whether the tear is amenable to a transtendinous (all-inside) repair or completion of the tear with traditional repair. Although a spinal needle and marking stitch were not used in this particular case, it is common practice to mark the tear to be inspected on the bursal side. Once the undersurface of the tear has been thoroughly inspected, attention is then turned to the subacromial space.

The posterior portal is again used to redirect the arthroscope into the subacromial space, and anterior and lateral portals are created using a spinal needle and outside-in technique. A bursectomy is performed to expose the lateral footprint of the supraspinatus. A probe (Smith & Nephew, Andover, MA) is used to palpate the bursal surface of the supraspinatus tendon to confirm the location for completion of the tear. A shaver (Smith & Nephew) is used to complete the tear and remove any remaining tendon from the footprint on the greater tuberosity.

The arthroscope is moved to the lateral portal for additional inspection of the tear and the bony fragment (Fig 2). An 18-gauge spinal needle is used to localize the insertion point of the medial row

*From Orthopaedic Research of Virginia (P.E.C., A.J.H., S.E.P.) and Tuckahoe Orthopaedic Associates, Ltd. (P.E.C.), Richmond, Virginia, U.S.A.*

*The authors report the following potential conflicts of interest or sources of funding: The following entities have provided grant funding to Orthopaedic Research of Virginia for Fellowship support: Arthrex, Bon Secours, ConMed/Linvcac, DJO, DePuy-Mitek, and Smith & Nephew. Full ICMJE author disclosure forms are available for this article online, as [supplementary material](#).*

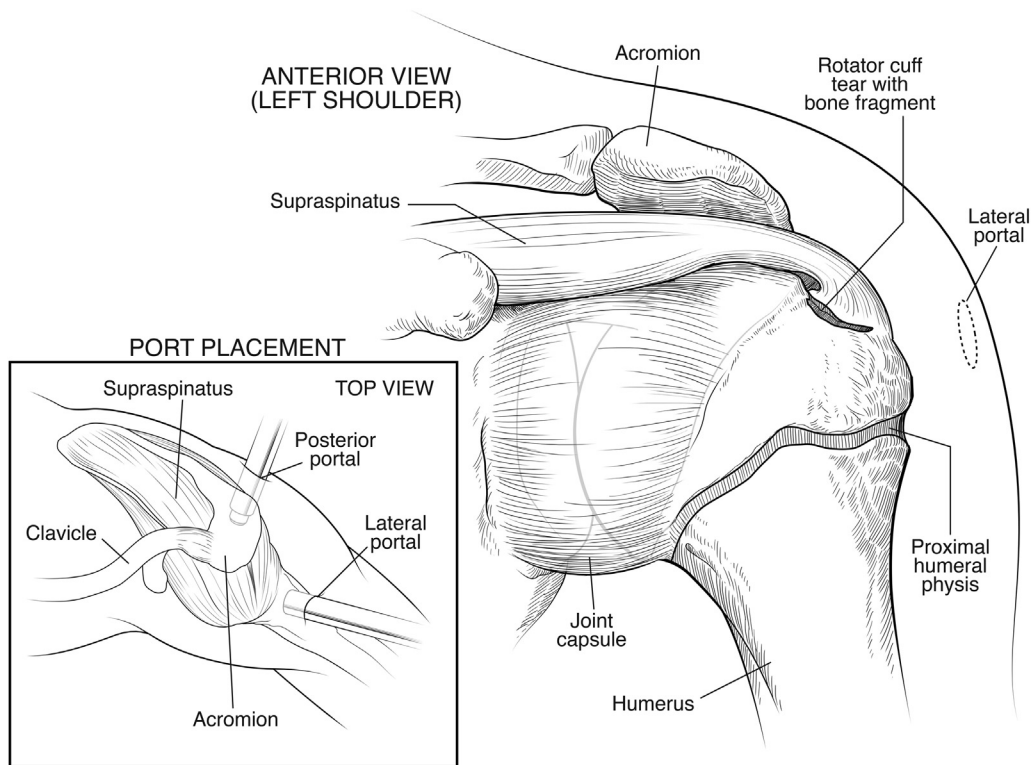
*Received December 15, 2018; accepted February 25, 2019.*

*Address correspondence to Paul E. Caldwell III, M.D., 1501 Maple Ave, Ste 200, Richmond, VA 23226, U.S.A. E-mail: [fellowship@orv.com](mailto:fellowship@orv.com)*

*© 2019 by the Arthroscopy Association of North America. Published by Elsevier. This is an open access article under the CC BY-NC-ND license (<http://creativecommons.org/licenses/by-nc-nd/4.0/>).*

*2212-6287/181518*

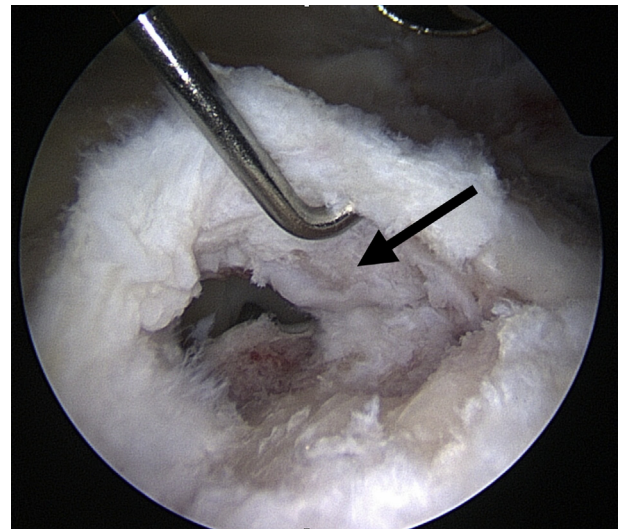
*<https://doi.org/10.1016/j.eats.2019.02.012>*



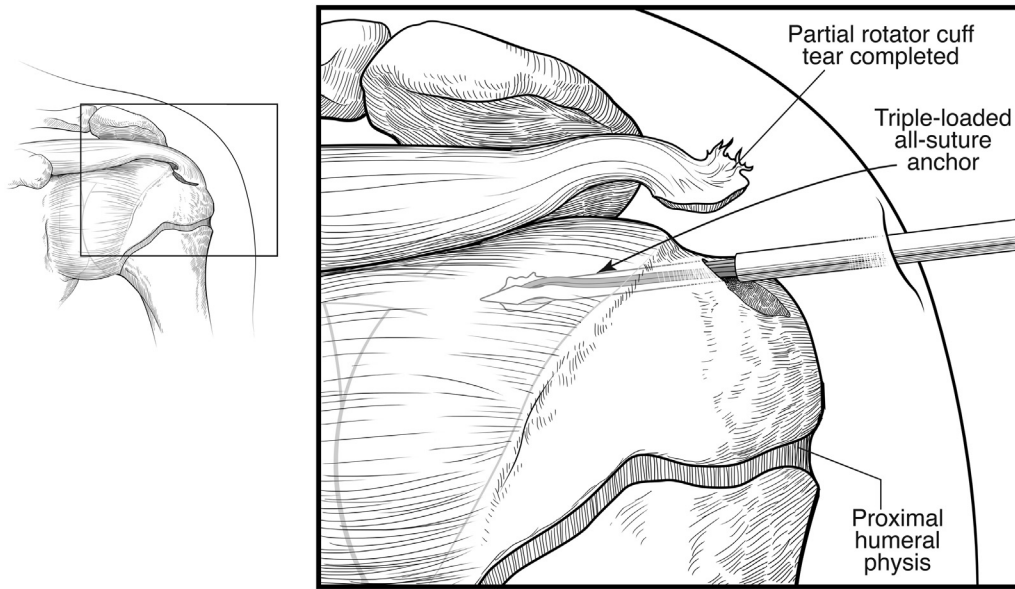
**Fig 1.** Anterior view of the left shoulder joint in a pediatric patient shows an arthroscopic setup along with a partially avulsed supraspinatus tendon and accompanying bony fragment from the greater tuberosity. The proximal humeral physis is also shown. Inset: Top view of arthroscopic portal placement.

anchor, and a percutaneous skin incision is made following the course of the spinal needle. A hooded Helicut burr (Smith & Nephew) is used to lightly decorticate the exposed footprint of the supraspinatus. A 2.8-mm self-punching all-suture triple-loaded Y-knot anchor (ConMed, Largo, FL) is inserted just lateral to the articular margin as the medial row anchor (Figs 3 and 4). Fluoroscopy is used to confirm placement of the anchor proximal to the proximal humeral physis (Fig 5). Sutures are passed in a retrograde fashion using a 60° suture passer (Depuy Mitek, Raynham, MA) in a horizontal mattress configuration. Sutures are retrieved and tied through a 5.0-mm cannula (Smith & Nephew) using an arthroscopic sliding locking knot and backed up with 3 reverse half-hitches (Fig 6). The arthroscope is switched to the posterior portal to better visualize the lateral footprint and tuberosity in preparation for lateral row anchor insertion. The free ends of the sutures are left uncut and incorporated into a 3.5-PushLock anchor (Arthrex, Naples, FL) to be inserted proximal to the physis and lateral to the supraspinatus footprint. This position is confirmed under fluoroscopy before insertion of the anchor (Fig 7). The sutures are tensioned under direct visualization to provide compression to the rotator cuff tear, and the anchor

is inserted to be flush with the cortical surface. The remaining free ends of the suture are cut, and the arthroscope is positioned back in the lateral portal to visualize the completed physal-sparing



**Fig 2.** Arthroscopic view of the right shoulder in the lateral decubitus position from the lateral portal in the subacromial space with a 30° arthroscope visualizing a full-thickness tear of the supraspinatus tendon with associated bone fragment (arrow).



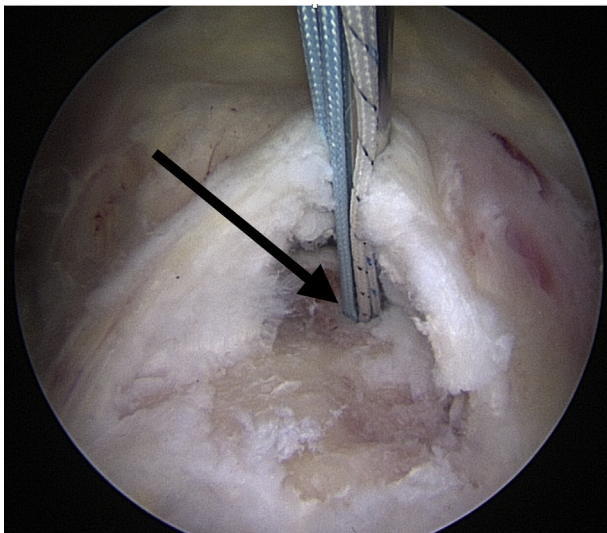
**Fig 3.** Anterior view of the left shoulder joint in a pediatric patient shows an arthroscopic setup along with a completed tear of the supraspinatus tendon and insertion of the medial row all-suture triple-loaded anchor into the greater tuberosity proximal humeral physis. Inset: Anterior view of the partially avulsed supraspinatus tendon before tear completion.

transosseous-equivalent arthroscopic rotator cuff repair (Figs 8 and 9).

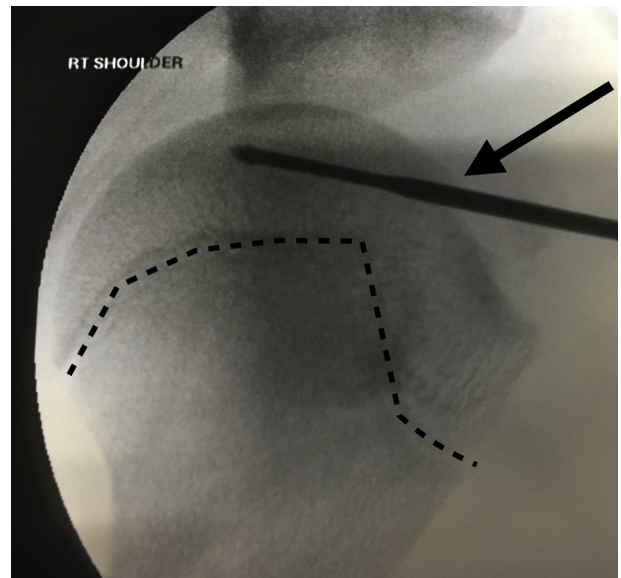
**Discussion**

Overuse injuries of the shoulder in adolescent sports are well documented and treated conservatively with excellent outcomes.<sup>1</sup> Traumatic injuries to

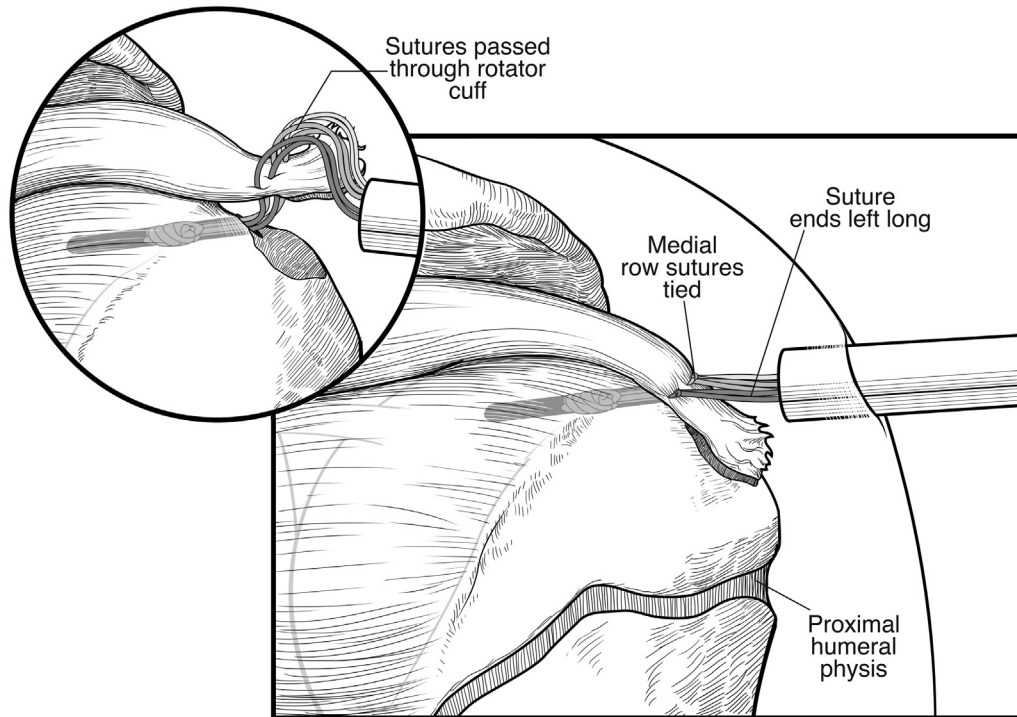
the shoulder are less common but carry the risk of more serious injury to the rotator cuff. Contusions to the rotator cuff are reported in contact athletes and can present with a short-term loss of muscle strength and function.<sup>3</sup> Fortunately, traumatic rotator cuff tears in this population are rare, and the literature contains predominantly case reports and small series



**Fig 4.** Arthroscopic view of the right shoulder in the lateral decubitus position from the lateral portal in the subacromial space with a 30° arthroscope visualizing a full-thickness tear of the supraspinatus tendon with insertion of an all-suture triple-loaded medial row anchor (arrow).



**Fig 5.** Intraoperative fluoroscopic view of the right shoulder during rotator cuff repair visualizing medial row anchor placement (arrow) proximal to the proximal humeral physis (dotted line).



**Fig 6.** Anterior view of the left shoulder joint in a pediatric patient shows an arthroscopic setup along with repair of the supraspinatus tendon after the medial row knots have been tied; the free ends of the suture are left long in preparation for incorporation into the lateral row anchor. Inset: Anterior view of the supraspinatus tendon during repair after suture passage but before knot tying.

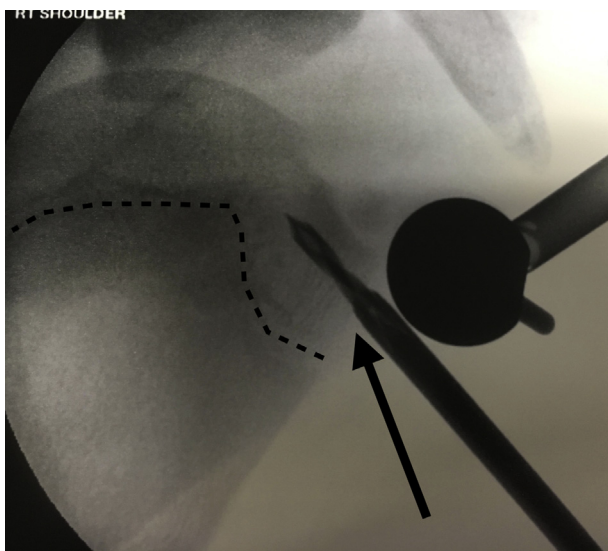
without attention to physeal-sparing repair techniques.<sup>2,4-7</sup>

The remodeling potential of the proximal humeral growth plate after traumatic injury has been well

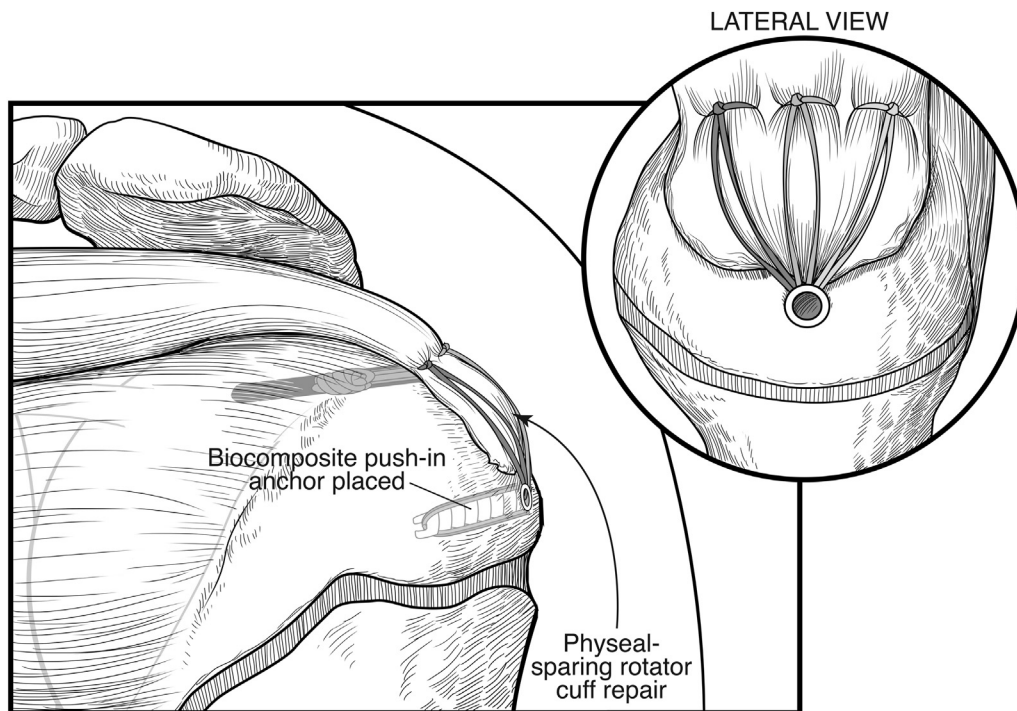
documented.<sup>8</sup> Although physeal-sparing approaches in pediatric anterior cruciate ligament reconstruction have received considerable emphasis; very little attention has been devoted to rotator cuff repair techniques. Pediatric rotator cuff repair should be approached using a physeal-sparing technique to avoid potential growth disturbances. Although the literature is sparse, previously described techniques underemphasize physeal-sparing techniques and use an open approach.<sup>2,6</sup> Our technique highlights an arthroscopic approach with fluoroscopic confirmation of preservation of the physis.

Recent trends in rotator cuff repair techniques have underscored the importance of bone preservation in consideration of potential future surgery. This concept is particularly important in the pediatric population. We endorse using small implants such as a 2.8-mm self-punching all-suture triple-loaded Y-knot anchor (ConMed) for a medial row anchor and 3.5-mm PushLock anchor (Arthrex) for the lateral row for bone preservation. Fluoroscopy is also helpful to confirm placement of small implants proximal to the physis, ensuring that the physis is not traumatized.

Although this technique offers many advantages (Table 1), it is not without inherent limitations. Fluoroscopy does require extra time during setup



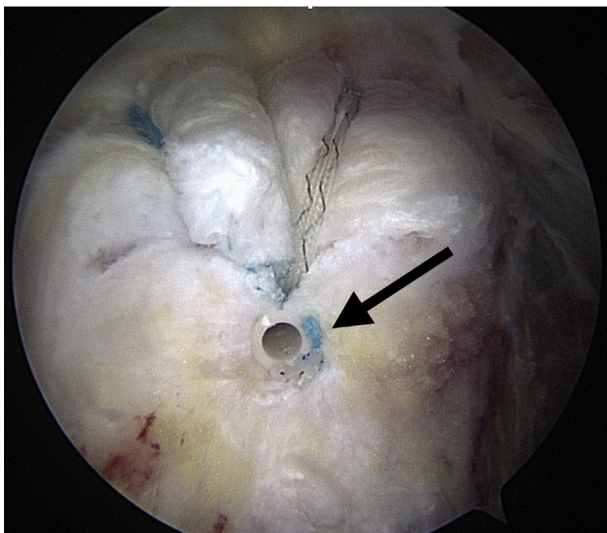
**Fig 7.** Intraoperative fluoroscopic view of the right shoulder during rotator cuff repair visualizing lateral row anchor placement (arrow) proximal to the proximal humeral physis (dotted line).



**Fig 8.** Anterior view of the left shoulder joint in a pediatric patient shows an arthroscopic setup along with completed repair of the supraspinatus tendon after the medial row knots have been tied and the free ends of the suture have been incorporated into a lateral row biocomposite push-in anchor proximal to the humeral physis. Inset: Lateral view of the shoulder after completed repair.

and patient positioning, as well as time during the case. The risks associated with additional radiation to the pediatric patient should not be unappreciated. A

modified double row repair technique with smaller implants may be well served for physéal sparing, but increased cost and lower pullout strength are also potential concerns (Table 2).



**Fig 9.** Arthroscopic view of the right shoulder in the lateral decubitus position from the lateral portal in the subacromial space with a 30° arthroscope visualizing a completed rotator cuff repair using a lateral row 3.5-mm biocomposite push-in anchor (arrow).

## Conclusions

After considering the potential shortcomings, the benefits of this technique far exceed those of the previously described open procedures without radiographic guidance.

**Table 1.** Advantages and Disadvantages of a Physéal-Sparing Transosseous-Equivalent Arthroscopic Rotator Cuff Repair

### Advantages

1. Standard arthroscopic setup, portals, and repair techniques
2. Small implants used for bone preservation
3. Fluoroscopic verification of physéal-sparing anchor placement
4. Compression of rotator cuff and bony fragment
5. Low-profile repair

### Disadvantages

1. Need for fluoroscopy and extra setup time
2. Smaller implants provide less fixation strength
3. Cost of implants for modified double-row repair technique
4. Potential for physéal penetration and growth disturbance
5. Additional radiation to the pediatric patient

**Table 2.** Pearls and Pitfalls of a Physeal-Sparing Transosseous-Equivalent Arthroscopic Rotator Cuff Repair

Pearls

1. Ensure fluoroscopic visualization of the shoulder before final patient positioning
2. Incorporate bony fragments into the repair when possible
3. Use smaller implants to reduce risk of physeal penetration
4. Lateral portal viewing for medial anchor placement and posterior viewing for lateral anchor placement

Pitfalls

1. Physeal penetration
2. Smaller implant pullout and repair failure
3. Improper suture tensioning and poor rotator cuff compression

## References

1. Robinson TW, Corlette J, Collins CL, Comstock RD. Shoulder injuries among US high school athletes, 2005/2006–2011/2012. *Pediatrics* 2014;133:272-279.
2. Alley MC, Banerjee S, Papaliadis D, Tsitos K, Zanaros GS. Transosseous physeal-sparing rotator cuff repair in an adolescent football player. *Orthopedics* 2016;39:e353-e358.
3. Cohen SB, Towers JD, Bradley JP. Rotator cuff contusions of the shoulder in professional football players: Epidemiology and magnetic resonance imaging findings. *Am J Sports Med* 2007;35:442-447.
4. Rickert M, Loew M. Traumatic rupture of the rotator cuff in an adolescent: Case report. *Z Orthop Ihre Grenzgeb* 2000;138:340-343 [in German].
5. Tarkin IS, Morganti CM, Zillmer DA, McFarland EG, Giangarra CE. Rotator cuff tears in adolescent athletes. *Am J Sports Med* 2005;33:596-601.
6. Turman KA, Anderson MW, Miller MD. Massive rotator cuff tear in an adolescent athlete: A case report. *Sports Health* 2010;2:51-55.
7. Azzam MG, Dugas JR, Andrews JR, et al. Rotator cuff repair in adolescent athletes. *Am J Sports Med* 2018;46:1084-1090.
8. Baxter MP, Wiley JJ. Fractures of the proximal humeral epiphysis: Their influence on humeral growth. *J Joint Bone Surg Br* 1986;68:570-573.