



Case report

Lacrimal gland enlargement as an early clinical or radiological sign in thyroid orbitopathy

James Khu^a, Kenn A. Freedman^{b,*}^a Kaiser Permanente, 4601 Dale Rd, Modesto, CA 95356, USA^b Department of Ophthalmology and Visual Sciences, Texas Tech University Health Sciences Center, Lubbock, TX 79439, USA

ARTICLE INFO

Article history:

Received 14 June 2016

Received in revised form

23 September 2016

Accepted 13 October 2016

Available online 15 October 2016

Keywords:

Lacrimal gland
Thyroid orbitopathy
Graves disease

ABSTRACT

Purpose: Characteristic ophthalmic signs of Thyroid Orbitopathy (TO) include exophthalmos, eyelid retraction, eyelid edema, restrictive extraocular myopathy, and optic neuropathy. In addition lacrimal gland (LG) enlargement can be observed in these patients. However TO has not usually been considered in the differential diagnosis of cases of isolated LG enlargement.

Observations: A female patient at our institution (Texas Tech) was seen over a period from 2006 to 2012. This patient presented initially with LG enlargement as the primary clinical or radiologic sign of what later was diagnosed as TO. Computerized tomography and/or magnetic resonance imaging of the orbits were obtained and demonstrated isolated LG enlargement.

Conclusions and importance: This case represents, to our knowledge, the first report of LG enlargement as an initial presenting sign of TO. Further clinical and radiological studies looking at the natural history of TO would be useful to better understand the timing of LG involvement. In patients presenting with lacrimal gland enlargement, thyroid orbitopathy should be strongly considered in the differential diagnosis together with other causes of dacryoadenitis and LG tumors. This may save unnecessary and extensive diagnostic testing or even LG biopsies.

© 2016 The Authors. Published by Elsevier Inc. This is an open access article under the CC BY-NC-ND license (<http://creativecommons.org/licenses/by-nc-nd/4.0/>).

1. Introduction

Thyroid Orbitopathy (TO) is the most common cause of proptosis and orbital inflammation in adults. Characteristic ophthalmic signs include exophthalmos, eyelid retraction, eyelid edema, restrictive extraocular myopathy, and optic neuropathy associated with thyroid dysfunction. Clinical signs of TO can sometime precede any laboratory evidence of thyroid dysfunction. The lacrimal gland (LG) can be affected in TO, though not commonly discussed.^{1–5} We present a case of TO where unilateral LG enlargement was the predominate early clinical sign.

2. Case report

A 52-year-old female presented with complaints of right eye swelling and protrusion. She was seen at another institution and

Computerized Tomography (CT) and Magnetic Resonance Imaging (MRI) scans of the orbits revealed right LG enlargement as the only orbital abnormality (Fig. 1). There was no improvement with a course of oral steroids and she subsequently underwent a lacrimal gland biopsy. Biopsy was negative for malignancy, showing a mild chronic inflammatory infiltrate composed of plasma cells without evidence for lymphoma. Graves' ophthalmopathy was suspected, but the patient was euthyroid on laboratory testing. She was referred to our clinic for a second opinion.

On examination nine months after her symptom began pinhole visual acuities were 20/25 in both eyes. External exam showed right upper eyelid fullness and right side proptosis of 4mm. Motility testing demonstrated a mild elevation deficit of the right eye and a 4 prism diopter right Hypotropia. Mild punctate staining of the cornea was noted bilaterally. The remainder of her eye exam was unremarkable. Her examination was consistent with a clinical diagnosis of Euthyroid Thyroid Orbitopathy (Fig. 2). Laboratory testing including erythrocyte sedimentation rate and antinuclear antibody were negative. However, a thyroid stimulating immunoglobulin level was ordered and found to be elevated at a level of 308%. This further supported the diagnosis of TO.

* Corresponding author. Department of Ophthalmology and Visual Sciences - MS 7217, Texas Tech University Health Sciences Center, Lubbock, TX 79430, USA.

E-mail addresses: jamesmykhu@gmail.com (J. Khu), kenn.freedman@ttuhsc.edu (K.A. Freedman).

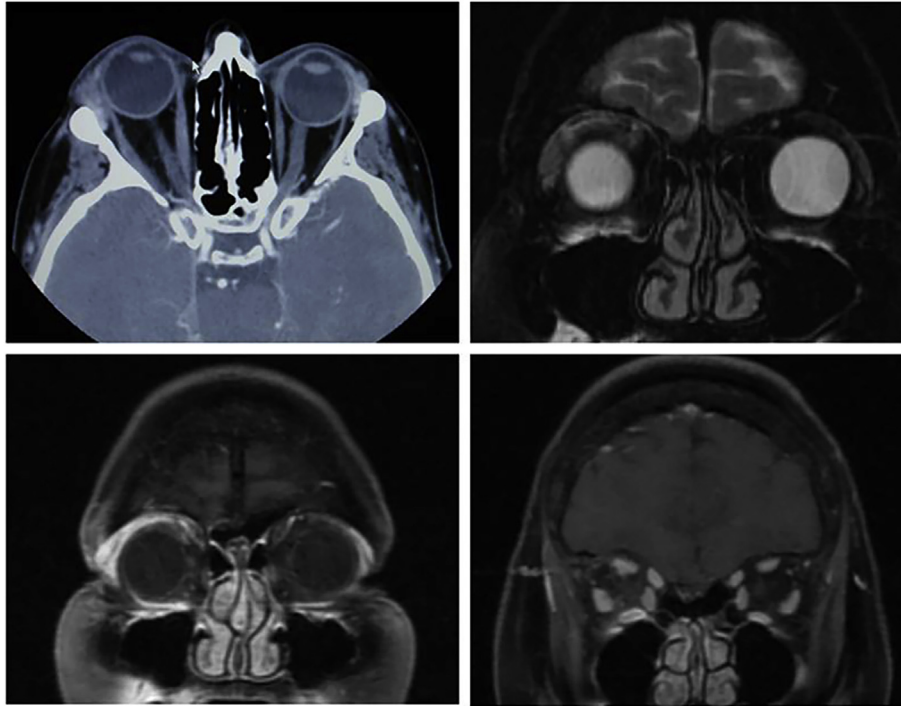


Fig. 1. Computerized Tomography and Magnetic Resonance Imaging (T2–Fast Spin Echo and T1 with Gadolinium Contrast) scans reveal isolated right lacrimal gland enlargement.

The patient subsequently developed a progressive restrictive myopathy of the right inferior rectus muscle and right eyelid retraction stabilizing over a 7 month period. She was referred to an endocrinologist and eventually over time was diagnosed with Graves' disease. She eventually underwent radioactive iodide thyroid ablation and also had strabismus surgery and eyelid retraction surgery.

3. Discussion

TO is primarily a clinical diagnosis. When the characteristic ophthalmic signs coincide with a hyperthyroid state, the diagnosis can often be made with confidence and without further workup or imaging studies. In the absence of thyroid dysfunction, the grouping of proptosis, restrictive myopathy, and eyelid retraction can allow for a presumptive diagnosis of TO until thyroid dysfunction ultimately develops. Orbital imaging studies

demonstrating extraocular muscle enlargement can further support the diagnosis.

Lacrimal gland involvement is generally not included in the discussion of Graves' ophthalmopathy; however it can be quite common. Trokel¹ noted that second behind involvement of the extraocular muscles, the only other tissue in the orbit consistently involved in Graves' disease was the lacrimal gland. Other radiological series have also noted frequent LG anterior displacement² and LG enlargement.^{3–5} Most recently, Huang⁵ noted that the LG was enlarged in TO patients as compared to controls and the LG was even larger in patients with increased inflammatory cytokines in tears.

The case presented in this report represent, to our knowledge, the first report of LG enlargement as an initial presenting sign of TO. Further clinical and radiological studies looking at the natural history of TO would be useful to better understand the frequency and timing of lacrimal gland involvement.

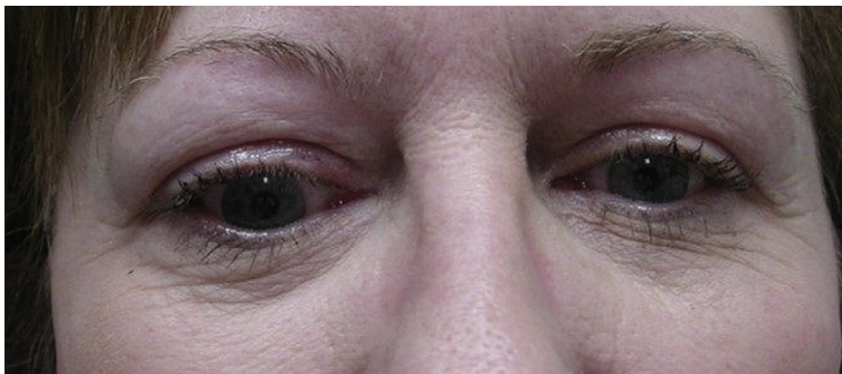

Fig. 2. Clinical photograph of the patient demonstrating right upper lid fullness together with a right Hypotropia and mild lid lag on downgaze.

In summary for patients presenting with lacrimal gland enlargement, TO should be strongly considered in the differential diagnosis together with other causes of dacryoadenitis and LG tumors. This may save unnecessary and extensive diagnostic testing or even LG biopsies.

4. Patient consent

Informed consent was obtained in writing from the patient for the use of their health information.

Funding

No Funding or Grant Support.

Conflict of interest

The following authors have no financial disclosures: JK, KF.

Authorship

All authors attest that they meet the current ICMJE criteria for Authorship.

Acknowledgements

None.

References

1. Trokel S, Jakobiec F. Correlation of CT scanning and pathologic features of ophthalmic Graves' disease. *Ophthalmology*. 1981;88(6):553–564.
2. Nugent R, Belkin R, Neigel J, et al. Graves Orbitopathy: correlation of CT and clinical findings. *Radiology*. 1990;177(3):675–682.
3. Bingham C, Harris M, Realini T, Nguyen J, Sivak-Callcott J. Calculated computer tomography volumes of lacrimal glands and comparison to clinical findings with thyroid eye disease. *Ophthal Plast Reconstr Surg*. 2014;30(2):116–118.
4. Harris M, Realini T, Hogg J, Sivak-Callcott J. CT dimensions of the lacrimal gland in Graves orbitopathy. *Ophthal Plast Reconstr Surg*. 2012;28(1):69–72.
5. Huang D, Luo Q, Yang H, Mao Y. Changes of lacrimal gland and tear inflammatory cytokines in thyroid associated ophthalmopathy. *Investig Ophthalmol Vis Sci*. 2014;55:4935–4943.