





# Chorioretinal Atrophic Lesions Evolution in Patients with Quiescent Myopic Choroidal Neovascularization Followed for More Than 10 Years

Ana Margarida Ferreira <sup>1</sup>, Rodrigo Vilares-Morgado <sup>1,2</sup>, Mário Lima-Fontes <sup>1,3</sup>, Manuel Falcão <sup>1,2</sup>, Fernando Falcão-Reis <sup>1,2</sup>, Ângela Carneiro <sup>1,2</sup>

<sup>1</sup>Department of Ophthalmology, Local Health Unit of São João, Porto, Portugal; <sup>2</sup>Department of Surgery and Physiology, Faculty of Medicine of University of Porto, Porto, Portugal; <sup>3</sup>Department of Biomedicine, Faculty of Medicine of University of Porto, Porto, Portugal

Correspondence: Ana Margarida Ferreira, Department of Ophthalmology of Local Health Unit of São João, Avenida Prof. Hernâni Monteiro, Porto, 4202 – 451, Portugal, Tel +351 912 605 085, Fax +351 225 512 100, Email amargaridapferreira@gmail.com

**Purpose:** To evaluate the progression of chorioretinal atrophic areas associated with myopic choroidal neovascularization (CNV) in high myopic patients followed by a minimum period of 10 years.

**Patients and Methods:** Patients with myopic CNV lesions that achieved clinical and structural remissions over 10 years of follow-up were included. Medical records were reviewed for CNV characterization and treatment, best-corrected visual acuity at baseline (BCVA0), immediately after the last treatment (BCVA1) and at the latest visit (BCVA2). Fundus autofluorescence (FAF) was used to quantify the amount of atrophic area increase per year associated with the treated myopic CNV lesion. The first FAF performed after treatment suspension (FAF1) was compared with the most recent exam (FAF2).

**Results:** Thirty-six eyes from 36 patients were included. Mean total follow-up was  $12.38 \pm 2.68$  years. Mean number of intravitreal injections (IVI) was  $12.50 \pm 12.40$  and 25% of the eyes had previous treatment with photodynamic therapy (PDT). Mean improvement between BCVA0 and BCVA1 was  $5.58 \pm 15.98$  letters ( $p < 0.001$ ). However, a drop of  $8.03 \pm 12.25$  letters was noticed between BCVA1 and BCVA2. FAF1 was  $6.34 \pm 4.92\text{mm}^2$  and increased to  $9.88 \pm 7.56\text{mm}^2$  ( $3.54 \pm 3.79\text{mm}^2$  variation  $p < 0.001$ ). The mean growth rate of the atrophic area was  $0.89 \pm 0.84\text{mm}^2$  per year. BCVA2 negatively correlated with FAF2 ( $k = -0.498$ ,  $p = 0.002$ ) being worse in patients with higher atrophic area growth rate ( $k = -0.341$ ,  $p = 0.042$ ). Eyes treated with PDT needed less IVI ( $5.89 \pm 5.21$  vs  $14.70 \pm 13.36$ ,  $p = 0.008$ ) but had larger FAF1 ( $9.80 \pm 5.33$  vs  $5.19 \pm 4.27$ ,  $p = 0.013$ ) and FAF2 ( $16.05 \pm 7.10$  vs  $7.83 \pm 6.63$ ,  $p = 0.003$ ). Hypothyroidism was associated with higher atrophy growth rate ( $1.55 \pm 1.15$  vs  $0.73 \pm 0.67$ ,  $p = 0.016$ ).

**Conclusion:** This research demonstrates the importance of chorioretinal atrophy progression after myopic CNV lesions regression and its impact on visual prognosis, reporting a mean yearly growth of  $0.89\text{mm}^2$  in atrophic areas. Previous treatment with PDT and hypothyroidism were identified as risk factors associated with larger atrophic areas and worse visual outcomes.

**Keywords:** chorioretinal atrophic lesions, myopic choroidal neovascularization

## Introduction

Pathologic myopia and its associated excessive axial length elongation result in structural changes in the posterior segment of the eye that can cause permanent visual loss.<sup>1</sup> Pathologic myopia affects up to 3% of the world's population, being one of the most frequent causes of blindness, particularly in Asian countries.<sup>2</sup> One of its most feared complications is the development of myopic choroidal neovascularization (CNV), which represents a well-established cause of CNV among patients younger than 50 years.<sup>3</sup> If left untreated, myopic CNV can cause scarring with enlargement of macular atrophy, which ultimately leads to irreversible visual loss.<sup>4</sup> Numerous treatment options have been applied for myopic CNV, including focal thermal laser photocoagulation, photodynamic therapy (PTD) with verteporfin, and intravitreal anti-

VEGF therapy, the latter being considered the “gold standard treatment” for myopic CNV.<sup>5</sup> Treatment with both bevacizumab, ranibizumab and aflibercept is associated with anatomical and functional improvements of myopic CNV.<sup>5,6</sup> However, even after successful treatment of myopic CNV, myopic maculopathy continues to progress, with the development and increase of chorioretinal atrophic areas and, invariably, progressive visual loss.<sup>7–9</sup> There is still no consensus regarding which factors may predict the growth of these atrophic areas. Age, degree of myopia/axial length, fellow eye status, presence of staphyloma and peripapillary atrophy, CNV location, and the use of cholesterol-lowering or diuretic medication were all pointed as predictors of myopic maculopathy progression.<sup>7,9–11</sup>

The purpose of this study was to evaluate the progression of atrophic areas associated to myopic CNV in a population of high myopic patients followed by a period of 10 or more years.

## Materials and Methods

A retrospective study was conducted at the Ophthalmology Department of the Local Health Unit of São João, in Porto, Portugal. The study was conducted ethically in accordance with the tenets of the Declaration of Helsinki, and it was approved by the local Ethics Committee. Informed consent was waived in this retrospective study as there are no identity elements linked to single patients.

Clinical records of patients with high myopia followed in our department were assessed. The inclusion criteria were as follows: (1) having a spherical equivalent (SE) refractive error equal or more negative than  $-6.00$  diopters (D) (2) CNV treated with anti-VEGF intravitreal injections; (3) a minimum total follow-up of 10 years; (4) a minimum follow-up of 1 year after anti-VEGF treatment suspension; (5) identifiable atrophic areas contiguous to the previous CNV using fundus autofluorescence (FAF); (6) at least two FAF exams, with at least 6 months between them, after treatment suspension. In cases where both eyes met the inclusion criteria, only the right eye was selected. The exclusion criteria were amblyopia, glaucoma, intraocular inflammation of the anterior and posterior segment, dense cataract, diabetic retinopathy, retinal vascular abnormalities, intravitreal injection of triamcinolone, previous vitrectomy, and scleral buckling procedure.

Electronic medical records were reviewed, and data were collected, including demographics, medical comorbidities, refractive error, CNV lesion's location and classification, and treatment modality implemented.

All patients with myopic CNV included in this study were diagnosed and monitored based on a multimodal examination (best corrected visual acuity evaluation, funduscopy performed under pharmacological dilation, spectral domain-optical coherence tomography (SD-OCT) and fluorescein angiography (FA)). Active CNV was angiographically and tomographically defined as the presence of leakage and fluid in the external retina. Inactive CNV implies the presence of CNV but no signs of activity on FA, SD-OCT or fundoscopic examination. Location of CNV was defined as subfoveal (CNV extending at the centre of the foveal avascular zone (FAZ)), juxtafoveal (CNV extending to  $199\ \mu\text{m}$  from the centre of the FAZ) and extrafoveal (CNV extending beyond  $200\ \mu\text{m}$  from the foveal centre). Treatment is initiated in all patients with active and exudative membranes who agree to receive anti-VEGF intravitreal injections. Treatment started with a loading dose of 3 intravitreal injections every 4 to 6 weeks, with a follow-up appointment 4 weeks after the last treatment is scheduled. Treatment periodicity is later adjusted based on clinical and structural response (treat and extend regimen).

Best-corrected visual acuity evaluated with Early Treatment of Diabetic Retinopathy Study (ETDRS) was collected at three time points: before the first treatment (BCVA 0), immediately after the last treatment (BCVA 1) and at the latest appointment (BCVA 2). FAF images were used to quantify the area (in  $\text{mm}^2$ ) of the atrophic lesions associated with previously active myopic CNV lesion. Chorioretinal atrophy was defined as retinal pigment epithelium (RPE) attenuation and atrophy. FAF images were obtained with a Spectralis HRA+OCT (Heidelberg Engineering, Germany) and manually evaluated by two graders using the Heidelberg Eye Explorer software. Manual delineation of the areas was performed using the region overlay tool of the Heidelberg software. In the presence of patchy chorioretinal atrophic areas, we delineated, measured, and added the multiple macular patchy hypofluorescent areas encountered, related to CNV lesion. In cases where the treated CNV lesions lied contiguous with one of the edges of the chorioretinal atrophic area, the CNV lesion was included, and the total area was considered. The first FAF performed after anti-VEGF treatment suspension (FAF1) was compared with the most recent exam (FAF2) and the atrophic area growth rate per year was calculated.

Several variables were collected and tested for potential association with chorioretinal atrophy progression: sex, age, degree of myopia, systemic comorbidities (such as hypertension, diabetes mellitus, obesity, hypothyroidism, malignancy, and its respective treatment), CNV lesion's baseline characteristics and treatment modality and regimen (including the interval and number of treatments with anti-VEGF agents).

The data's normal distribution was verified by skewness, kurtosis, and Kolmogorov–Smirnov test. Parametric or non-parametric tests were used for variables comparison, according to the data distribution. Correlations between the potential predictors of outcome were investigated using Pearson's correlation coefficient, with a level of significance established at a p-value <0.05, considered to be supportive of the correlation. In the case of concordance analyzes, kappa statistics were used. Kappa values from 0.00 to 0.20 were considered as slight agreement, from 0.21 to 0.40 as reasonable agreement, from 0.41 to 0.60 as moderate agreement, from 0.61 to 0.80 as substantial agreement and from 0.81 to 1 as almost perfect agreement. Statistical analysis was performed using the IBM® SPSS® Statistics software (version 27.0 for Windows; SPSS Inc., Chicago, IL, USA).

## Results

### Sample Characteristics

Thirty-six eyes from 36 patients were included. About 72.2% (n = 26) were female patients and the mean age of the sample was  $62.11 \pm 15.12$  years old. About 55.6% (n = 20) were left eyes. Mean spherical equivalent was  $-11.81 \pm 3.55$  D. Mean total follow-up, treatment time and suspension time were  $12.38 \pm 2.68$ ,  $3.32 \pm 3.30$  and  $7.72 \pm 2.88$  years, respectively. The mean number of anti-VEGF injections per eye was  $12.50 \pm 12.40$ . The most frequent systemic comorbidities were dyslipidemia (41.7%, n = 15), systemic hypertension (33.3%, n = 12), thyroid disease with hypothyroidism (19.4%, 7), diabetes and malignancy (13.9%, n = 5, each). All patients with dyslipidemia, systemic hypertension and hypothyroidism were being treated with statins, diuretics, and levothyroxine, respectively.

### CNV Features and Treatment

The majority of the CNV lesions were predominantly classic (88.9%, n = 32), with the remaining being minimally classic (8.3%, n = 3) and occult (2.8%, n = 1). Concerning the location, 75.0% (n = 27) were subfoveal, 19.4% (n = 7) juxtafoveal and 5.6% (n = 2) extrafoveal.

In addition to anti-VEGF intravitreal injections, 25.0% of the eyes (n = 9) had been previously treated with PDT. The mean number of intravitreal injections per eye was  $12.50 \pm 12.40$ . Sixteen eyes (44.4%) were treated with bevacizumab, 7 (19.4%) with ranibizumab and 13 (36.1%) with both bevacizumab and ranibizumab. Table 1 presents demographics, CNV characterization and respective implemented treatment. When comparing eyes treated only with bevacizumab or only with ranibizumab, BCVA0 was worse, and the number of intravitreal injections was higher in the bevacizumab group (p = 0.035 and p = 0.015, respectively). No differences were found in BCVA1 or BCVA2 between groups. Eyes with subfoveal CNV lesions had more anti-VEGF injections than the others ( $15.0 \pm 13.3$  vs  $5.0 \pm 3.7$ , p = 0.001). Higher

**Table 1** Demographics, CNV Characterization and Respective Implemented Treatment

Parameter	Total Subjects (n = 36)
Age, years	$62.11 \pm 15.12$
Gender, female	26 (72.2%)
Involved eye, left	20 (55.6%)
Spherical equivalent, diopters	$-11.81 \pm 3.55$
Total follow-up time, years	$12.38 \pm 2.68$

(Continued)

**Table 1** (Continued).

Parameter	Total Subjects (n = 36)
Systemic comorbidities	
Dyslipidemia	15 (41.7%)
Systemic hypertension	12 (33.3%)
Thyroid disease with hypothyroidism	7 (19.4%)
Diabetes	5 (13.9%)
Malignancy	5 (13.9%)
CNV lesions classification	
Classic	32 (88.9%)
Minimally classic	3 (8.3%)
Occult	1 (2.8%)
CNV lesions location	
Subfoveal	27 (75%)
Juxtafoveal	7 (19.4%)
Extrafoveal	2 (5.6%)
Total treatment time, years	3.32 ± 3.30
Number of intravitreal injections per eye	12.50 ± 12.40
Bevacizumab	16 (44.4%)
Ranibizumab	7 (19.4%)
Both bevacizumab and ranibizumab	13 (36.1%)
Previous treatment with PDT	9 (25%)
Total suspension of treatment time, years	7.72 ± 2.88

**Notes:** Categorical data are presented as n (%). Continuous data are presented as mean ± standard deviation (SD), or median ± interquartile range for skewed data.

**Abbreviations:** CNV, choroidal neovascularization; PDT, photodynamic therapy.

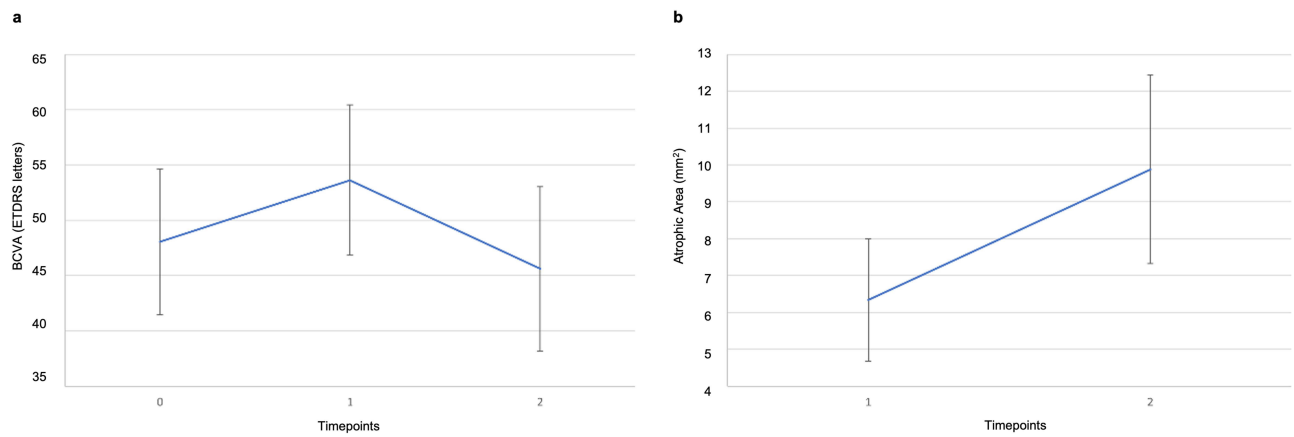
absolute spherical equivalent correlated with longest treatment time ( $k = -0.472$ ,  $p = 0.020$ ) but not with the number of injections ( $k = -0.259$ ;  $p = 0.221$ ).

## Visual Acuity and Chorioretinal Atrophy Evolution

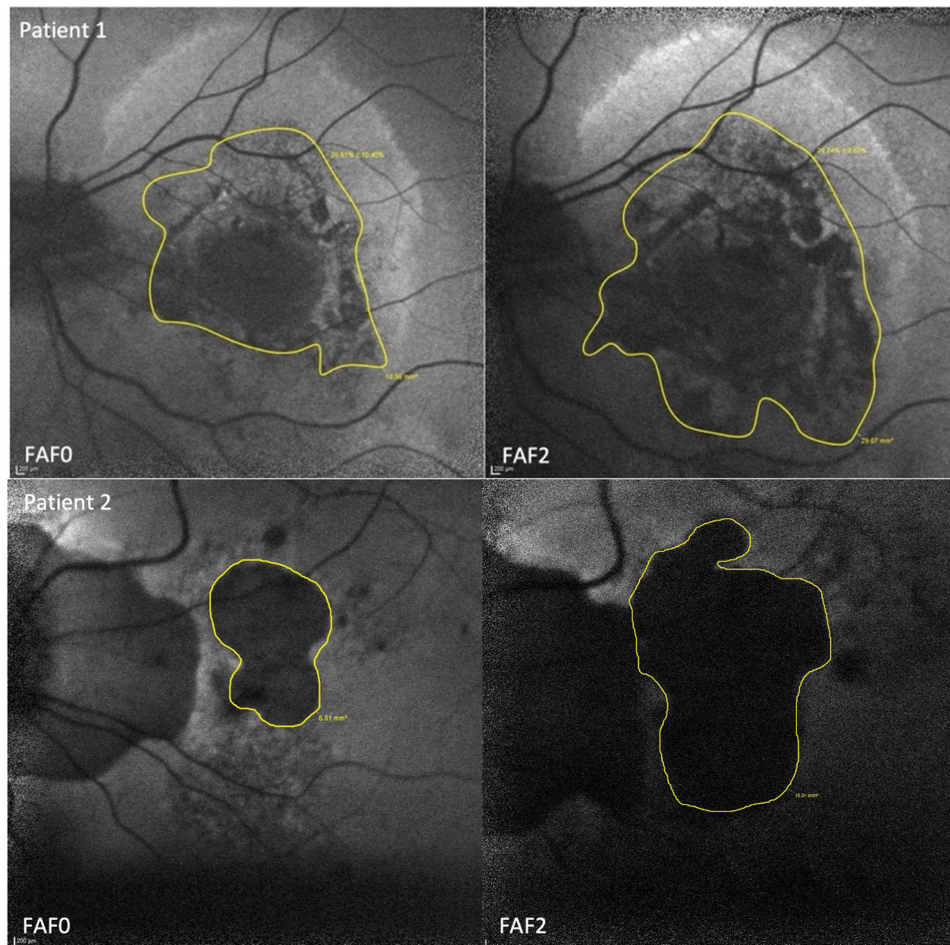
BCVA0 was  $48.06 \pm 19.45$  EDTRS letters and improved to  $53.64 \pm 20.16$  letters when treatment was suspended (BCVA1). Mean improvement per eye was  $5.58 \pm 15.98$  letters ( $p < 0.001$ ). However, BCVA dropped  $8.03 \pm 12.25$  letters from the treatment suspension to the final evaluation ( $p < 0.001$ ). BCVA 2 was  $45.61 \pm 21.98$  letters.

FAF1 was  $6.34 \pm 4.92$  mm<sup>2</sup> and increased to  $9.88 \pm 7.56$  mm<sup>2</sup> (a variation of  $3.54 \pm 3.79$  mm<sup>2</sup> per eye,  $p < 0.001$ ). Mean time between the two evaluations was  $4.94 \pm 2.74$  years so the mean growth rate was  $0.89 \pm 0.84$  mm<sup>2</sup> per year. [Figure 1](#) graphically presents BCVA and FAF variations. [Figure 2](#) depicts the FAF area measurements (at baseline and at the last visit) of two illustrative patients of our cohort. No correlation was found between BCVA and atrophic area at any time point and age, gender, spherical equivalent, number of injections, and type and location of CNV.

All BCVAs positively correlated with each other (BCVA0 vs BCVA1,  $r = 0.675$ ,  $p < 0.001$ ; BCVA1 vs BCVA2,  $r = 0.835$ ,  $p < 0.001$ ; BCVA0 vs BCVA2,  $r = 0.437$ ,  $p = 0.008$ ). Larger FAF 1 correlated with larger FAF2 and with higher atrophic area growth rate ( $r = 0.901$ ,  $p < 0.001$ ; and  $r = 0.673$ ,  $p < 0.001$ , respectively). BCVA1 negatively correlated with FAF1 ( $r = -0.410$ ,  $p = 0.013$ ) and BCVA2 negatively correlated with FAF2 ( $r = -0.498$ ,  $p = 0.002$ ). BCVA2 was worse in patients with higher atrophic area growth rate ( $r = -0.341$ ,  $p = 0.042$ ). No correlation was found between the anti-VEGF used and the atrophic area. Significant correlations are represented in [Figures 3–5](#). Regarding concordance analysis, all variables presented moderate to substantial agreement (kappa values superior do 0.41).



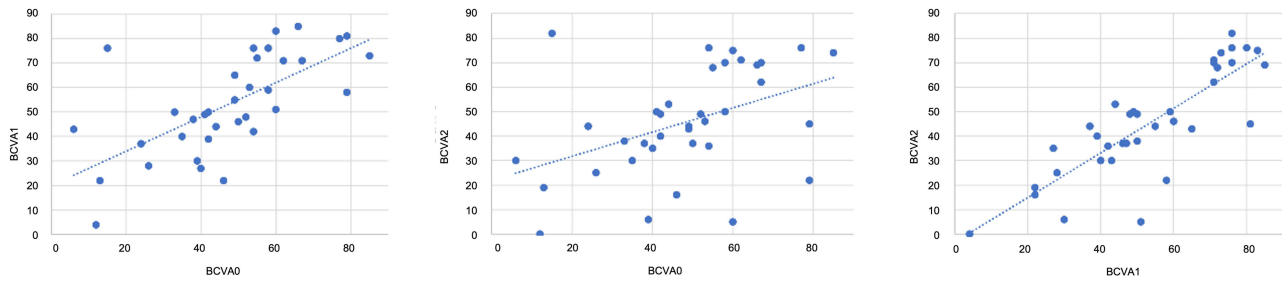
**Figure 1** Graphic representation of the BCVA variation (on the right, (a)) at baseline (0), when anti-VEGF was suspended (1) and at last visit (2). On the left (b), the evolution of chorioretinal atrophic areas is displayed at the two last time points (1 and 2).



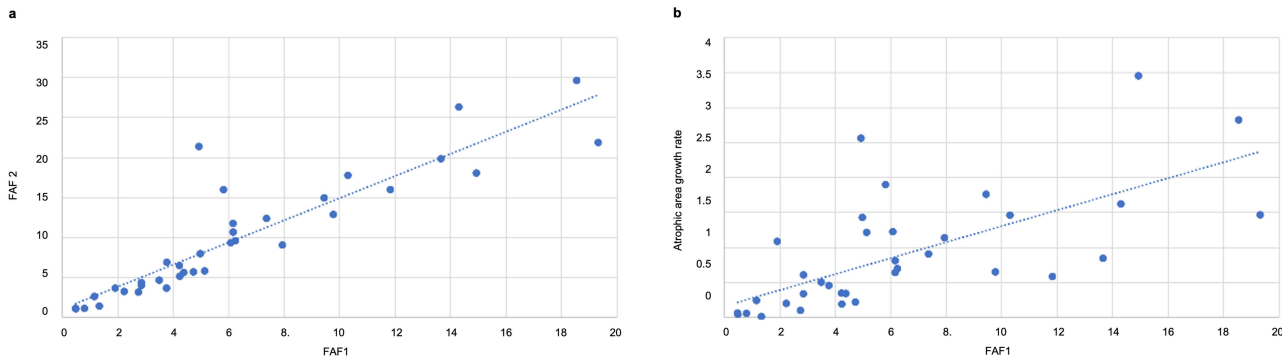
**Figure 2** FAF images of two illustrative example patients from our cohort. FAF area at baseline (FAF0) and at the last visit (FAF2).

## PDT Effect

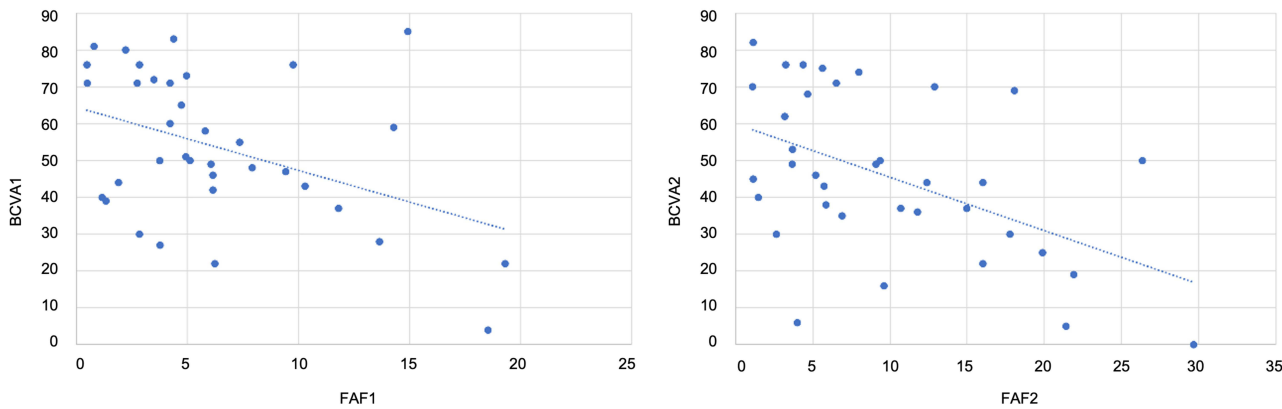
Eyes treated with PDT needed less intravitreal injections ( $5.89 \pm 5.21$  vs  $14.70 \pm 13.36$ ,  $p = 0.008$ ) but had larger FAF1 and FAF2 ( $9.80 \pm 5.33$  vs  $5.19 \pm 4.27$ ,  $p = 0.013$ ;  $16.05 \pm 7.10$  vs  $7.83 \pm 6.63$ ,  $p = 0.003$ ; respectively). There was also



**Figure 3** Correlations between BCVA at baseline (0), when anti-VEGF was suspended (1) and at last visit (2). We found a substantial positive correlation between BCVA0 and BCVA1 (0.675,  $p < 0.001$ ), a moderate positive correlation between BCVA0 and BCVA2 (0.437,  $p = 0.008$ ), and an almost perfect positive correlation between BCVA1 and BCVA2 (0.835,  $p < 0.001$ ). BCVA in ETDRS letters.



**Figure 4** Linear correlation between atrophic area after anti-VEGF treatment suspension (FAF 1) and at last visit (FAF 2) on the right (a), and between FAF 1 and atrophic area growth rate ( $\text{mm}^2/\text{year}$ ) on the left (b). We found an almost perfect positive correlation between FAF1 and FAF2 (0.901,  $p < 0.001$ ) and a substantial positive correlation between FAF1 and atrophic area growth rate (0.673,  $p < 0.001$ ). FAF area in  $\text{mm}^2$ ; atrophic area growth rate in  $\text{mm}^2/\text{year}$ .



**Figure 5** Linear correlation BCVA and atrophic area after anti-VEGF treatment suspension (BCVA1 vs FAF 1) and at last visit (BCVA2 vs FAF 2). We found a moderate negative correlation between BCVA1 and FAF1 ( $-0.410$ ,  $p = 0.013$ ) and a reasonable correlation between BCVA2 and FAF2 ( $-0.341$ ,  $p = 0.042$ ). BCVA in ETDRS letters; FAF area in  $\text{mm}^2$ .

a tendency for lower BCVA in all time points and higher atrophic area growth rate in these eyes, however without statistical significance (BCVA0:  $43.89 \pm 18.88$  vs  $49.44 \pm 43.89$ ,  $p = 0.466$ ; BCVA1:  $48.89 \pm 19.72$  vs  $55.22 \pm 20.42$ ,  $p = 0.422$ ; BCVA2:  $40.22 \pm 22.96$  vs  $47.41 \pm 21.79$ ,  $p = 0.404$ ; area increase/year:  $1.13 \pm 0.76$  vs  $0.81 \pm 0.86$ ,  $p = 0.323$ ).

### Comorbidities Effect

Patients with systemic hypertension presented lower BCVA1 and BCVA2 ( $44.33 \pm 24.61$  vs  $58.29 \pm 16.15$ ,  $p = 0.049$ ;  $34.25 \pm 25.73$  vs  $51.29 \pm 17.83$ ,  $p = 0.026$ ; respectively). The number of anti-VEGF injection was higher in dyslipidemic

patients ( $17.27 \pm 15.31$  vs  $9.10 \pm 8.71$ ,  $p = 0.05$ ). Hypothyroidism was associated with higher atrophic areas growth rate ( $1.55 \pm 1.15$  vs  $0.73 \pm 0.67$ ,  $p = 0.016$ ).

## Discussion

This study aimed to analyze the long-term evolution of chorioretinal atrophic areas in high myopic patients with quiescent myopic CNV lesions followed over a minimum period of 10 years since the time of the CNV diagnosis. We observed that the treatment of myopic CNV with anti-VEGF intravitreal injections resulted in a functional gain of approximately 6 EDTRS letters. However, after treatment suspension, patients lost 8 letters during follow-up, due to the increase of chorioretinal atrophic areas. Farinha et al evaluated the long-term progression of myopic maculopathy after treatment of myopic CNV with PDT and/or intravitreal ranibizumab and found an increase in the prevalence of diffuse, patchy, and macular atrophy over time. The progression of macular atrophy was predictive of visual acuity.<sup>7</sup>

We found a mean atrophic area growth rate of  $0.89 \text{ mm}^2$  per year. To our knowledge, this is the first report of the growth rate of chorioretinal atrophy in the setting of myopic patients under prolonged monitoring. In the case of AMD, a meta-analysis published in 2021 described a growth rate of geographic atrophy in the range of  $0.65$  to  $2.60 \text{ mm}^2/\text{year}$ , with a pooled overall mean growth rate of  $1.66 \text{ mm}^2/\text{year}$ .<sup>12</sup> The apparently slower growth rate in the high myopic patients may be explained by its younger age (mean age of the sample was 63 years old), as well as the absence of other stress factors, such as oxidative stress and excessive accumulation of lipofuscin, besides the progressive thinning of the posterior sclera, choroid and retina.<sup>1,13,14</sup> The only predictor factor found for this growth rate was hypothyroidism. Interestingly, it was reported last year that the levels of thyroid hormones may affect the responses of RPE and photoreceptors to damage triggers, such as oxidative stress. High levels of thyroid hormones seem to increase the risk of AMD, particularly its dry form.<sup>15–19</sup> For this reason, we question if the results we found are related to the hypothyroidism itself or the hormone replacement therapy.

Regarding other systemic conditions, patients with systemic hypertension presented lower BCVA, and dyslipidemia was associated with higher number of anti-VEGF intravitreal injections. These possible associations may be explained by the medications used to treat these conditions. Several studies in the literature show contradictory results regarding the effect of systemic medications on AMD. Shen et al linked higher geographic atrophy growth rate to cholesterol-lowering and diuretic medication.<sup>10</sup> Song et al did not find any association between ACE inhibitors, beta-blockers, or diuretics and GA incidence or growth.<sup>14</sup> However, in this study calcium channel blockers demonstrated a significant association with faster GA growth, resembling The Women's Health Initiative Sight Exam Ancillary Study that indicated higher risk of late AMD and GA in patients under calcium channel blockers.<sup>20</sup>

Moreover, eyes treated with PDT showed higher atrophic areas and, consequently, lower BCVA. Atrophic growth rates also tended to be faster in these eyes. Farinha et al found no significant differences between the 3 types of implemented treatment (PDT, intravitreal ranibizumab, and a combination of both) regarding long-term morphological and functional outcomes of myopic maculopathy, emphasizing that the structural changes in treated eyes were more likely associated with the natural progression of the disease, rather than the treatment implemented.<sup>7</sup> The long-standing anatomical and functional outcomes associated with PDT are controversial.<sup>21</sup> Some series showed improved and sustained vision in myopic CNV patients after PDT for up to 2 to 3 years,<sup>22–27</sup> while a randomized clinical trial reported that PDT performed better than placebo regarding visual outcomes after 2 years.<sup>28</sup> PDT, specifically standard-fluence, may also contribute to the development of chorioretinal atrophy over time.<sup>29,30</sup> For these reasons, PDT is usually performed as a second-line treatment in patients with myopic CNV resistant to previous treatment with intravitreal anti-VEGF - the recommended first-line therapy.<sup>21</sup>

Furthermore, we found no differences in functional and anatomical outcomes between treatments with bevacizumab or ranibizumab. Sayanagi et al compared the anatomical outcomes between intravitreal treatment with ranibizumab or aflibercept and observed more subfoveal choroid thinning in eyes treated with ranibizumab. However, this did not correlate with differences in chorioretinal atrophy progression.<sup>11</sup>

Other factors such as the interval and number of treatments with anti-VEGF agents, age, and degree of myopia were described as risk factors for the development of chorioretinal atrophy.<sup>7,9,31–33</sup> In our cohort, they did not demonstrate an association with chorioretinal atrophy progression.

Interestingly, the development of a myopic CNV itself may be associated with slower rate of expansion of the atrophic areas, although the reports are contradictory.<sup>31,34</sup>

Our work presents some limitations. We cannot neglect the possibility of some loss of information as this is a retrospective study. Second, the inclusion of patients with a minimum follow-up of 10 years allows a considerable long-term study of the natural history of the disease but invariably limits the sample size. Third, an important fraction of patients was excluded due to the absence of FAF exams during follow-up, further reducing the final sample size. Fourth, the large standard deviation values observed in several results reflect the heterogeneity of the sample and the presence of individual differences between patients, warranting careful interpretation of the results in the appropriate context. Finally, the degree of myopia was classified using the spherical equivalent. However, other measures such as the axial length could have more accurately represent the geometry of the eye and, consequently, correlated with the remaining variables. The axial length was not evaluated in this study since it was not possible to measure the baseline value and accurately estimate the axial elongation over time. Finally, this is a single-center study, representing the results of the internal treatment protocol applied. It would be interesting to compare these data with other centers.

In conclusion, this research demonstrates the importance of chorioretinal atrophy progression after myopic CNV regression and its impact on visual prognosis, reporting a mean yearly growth of 0.89 mm<sup>2</sup> in atrophic areas related with quiescent CNVs. It also identifies risk factors associated with the development of larger atrophic areas and, consequently, worse visual outcomes, such as previous treatment with PDT and hypothyroidism. However, further studies are needed to better elucidate the risk factors associated with chorioretinal atrophy progression and its pathophysiological meaning, to shed some light on the preventive mechanisms of this silent but devastating progression.

## Abbreviations

BCVA, best corrected visual acuity; CNV, choroidal neovascularization; ETDRS, Early Treatment of Diabetic Retinopathy Study; FA, fluorescein angiography; FAF, fundus autofluorescence; FAZ, foveal avascular zone; PDT, photodynamic therapy; SD-OCT, spectral domain-optical coherence tomography; SE, spherical equivalent; VEGF, vascular endothelial growth factor.

## Data Sharing Statement

Access to any supplemental information is available upon reasonable request.

## Ethics/Ethical Approval

The study was approved by the Institutional Ethics Review Board of the Local Health Unit of São João, Porto, Portugal. The protocol conformed with the canons of the Declaration of Helsinki for research involving human participants, and the European Union's - General Data Protection Regulation. Informed consent was waived as this is a retrospective study. The recommendations of The Reporting of studies Conducted using Observational Routinely-collected health Data (RECORD) were followed in this article redaction.

## Acknowledgments

Named authors have collaborated in the writing of this paper.

## Author Contributions

All authors made a significant contribution to the work reported, whether that is in the conception, study design, execution, acquisition of data, analysis and interpretation, or in all these areas; took part in drafting, revising or critically reviewing the article; gave final approval of the version to be published; have agreed on the journal to which the article has been submitted; and agree to be accountable for all aspects of the work.

## Funding

The authors have no financial disclosures to declare. No funding or sponsors were undertaken in the preparation of the manuscript.



## Disclosure

The authors have no conflicts of interest to declare in this work.

## References

1. Flitcroft DI, He M, Jonas JB, et al. IMI - defining and classifying myopia: a proposed set of standards for clinical and epidemiologic studies. *Invest Ophthalmol Vis Sci.* 2019;60(3):M20–M30. doi:10.1167/iovs.18-25957
2. Wong TY, Ferreira A, Hughes R, Carter G, Mitchell P. Epidemiology and disease burden of pathologic myopia and myopic choroidal neovascularization: an evidence-based systematic review. *Am J Ophthalmol.* 2014;157(1):9–25.e12. doi:10.1016/j.ajo.2013.08.010
3. Tan CS, Sadda SR. Anti-vascular endothelial growth factor therapy for the treatment of myopic choroidal neovascularization. *Clin Ophthalmol.* 2017;11:1741–1746. doi:10.2147/OPTH.S124518
4. Yoshida T, Ohno-Matsui K, Yasuzumi K, et al. Myopic choroidal neovascularization: a 10-year follow-up. *Ophthalmology.* 2003;110(7):1297–1305. doi:10.1016/S0161-6420(03)00461-5
5. Ohno-Matsui K, Ikuno Y, Lai TYY, Gemmy Cheung CM. Diagnosis and treatment guideline for myopic choroidal neovascularization due to pathologic myopia. *Prog Retin Eye Res.* 2018;63:92–106. doi:10.1016/j.preteyeres.2017.10.005
6. El Matri L, Chebil A, Kort F. Current and emerging treatment options for myopic choroidal neovascularization. *Clin Ophthalmol.* 2015;9:733–744. doi:10.2147/OPTH.S49437
7. Farinha CL, Baltar AS, Nunes SG, et al. Progression of myopic maculopathy after treatment of choroidal neovascularization. *Ophthalmologica.* 2014;231(4):211–220. doi:10.1159/000357290
8. Hayashi K, Ohno-Matsui K, Shimada N, et al. Long-term pattern of progression of myopic maculopathy: a natural history study. *Ophthalmology.* 2010;117(8):1595–611, 611.e1–4. doi:10.1016/j.ophtha.2009.11.003
9. Fang Y, Yokoi T, Nagaoka N, et al. Progression of myopic maculopathy during 18-year follow-up. *Ophthalmology.* 2018;125(6):863–877. doi:10.1016/j.ophtha.2017.12.005
10. Shen LL, Xie Y, Sun M, et al. Associations of systemic health and medication use with the enlargement rate of geographic atrophy in age-related macular degeneration. *Br J Ophthalmol.* 2021;107(2):261–266.
11. Sayanagi K, Uematsu S, Hara C, et al. Effect of intravitreal injection of aflibercept or ranibizumab on chorioretinal atrophy in myopic choroidal neovascularization. *Graefes Arch Clin Exp Ophthalmol.* 2019;257(4):749–757. doi:10.1007/s00417-018-04214-w
12. Wang J, Ying GS. Growth rate of geographic atrophy secondary to age-related macular degeneration: a meta-analysis of natural history studies and implications for designing future trials. *Ophthalm Res.* 2021;64(2):205–215. doi:10.1159/000510507
13. Ohno-Matsui K, Wu PC, Yamashiro K, et al. IMI pathologic myopia. *Invest Ophthalmol Vis Sci.* 2021;62(5):5. doi:10.1167/iovs.62.5.5
14. Song D, Hua P, VanderBeek BL, et al. Systemic medication use and the incidence and growth of geographic atrophy in the comparison of age-related macular degeneration treatments trials. *Retina.* 2021;41(7):1455–1462. doi:10.1097/IAE.0000000000003075
15. Ma H, Yang F, Ding X-Q. Inhibition of thyroid hormone signaling protects retinal pigment epithelium and photoreceptors from cell death in a mouse model of age-related macular degeneration. *Cell Death Dis.* 2020;11(1):24. doi:10.1038/s41419-019-2216-7
16. Ma H, Yang F, Ding X-Q. Deficiency of thyroid hormone receptor protects retinal pigment epithelium and photoreceptors from cell death in a mouse model of age-related macular degeneration. *Cell Death Dis.* 2022;13(3):255. doi:10.1038/s41419-022-04691-2
17. Gopinath B, Liew G, Kifley A, Mitchell P. Thyroid dysfunction and ten-year incidence of age-related macular degeneration. *Invest Ophthalmol Visual Sci.* 2016;57(13):5273–5277. doi:10.1167/iovs.16-19735
18. Chaker L, Buitendijk GH, Dehghan A, et al. Thyroid function and age-related macular degeneration: a prospective population-based cohort study--the Rotterdam Study. *BMC Med.* 2015;13(1):94. doi:10.1186/s12916-015-0329-0
19. Xu Z, Zhang M, Zhang Q, Xu T, Tao L. Thyroid disease is associated with higher age-related macular degeneration risk: results from a meta-analysis of epidemiologic studies. *Ophthalm Res.* 2021;64(5):696–703. doi:10.1159/000515273
20. Klein R, Deng Y, Klein BE, et al. Cardiovascular disease, its risk factors and treatment, and age-related macular degeneration: Women's Health Initiative Sight Exam ancillary study. *Am J Ophthalmol.* 2007;143(3):473–483. doi:10.1016/j.ajo.2006.11.058
21. Chen Y, Han X, Gordon I, et al. A systematic review of clinical practice guidelines for myopic macular degeneration. *J Glob Health.* 2022;12:04026. doi:10.7189/jogh.12.04026
22. Pece A, Vadalà M, Isola V, Matranga D. Photodynamic therapy with verteporfin for juxtafoveal choroidal neovascularization in pathologic myopia: a long-term follow-up study. *Am J Ophthalmol.* 2007;143(3):449–454. doi:10.1016/j.ajo.2006.11.037
23. Pece A, Isola V, Vadalà M, Matranga D. Photodynamic therapy with verteporfin for subfoveal choroidal neovascularization secondary to pathologic myopia: long-term study. *Retina.* 2006;26(7):746–751. doi:10.1097/01.iae.0000244256.60524.c0
24. Hayashi K, Ohno-Matsui K, Shimada N, et al. Long-term results of photodynamic therapy for choroidal neovascularization in Japanese patients with pathologic myopia. *Am J Ophthalmol.* 2011;151(1):137–47.e1. doi:10.1016/j.ajo.2010.06.046
25. Coutinho AM, Silva RM, Nunes SG, Cachulo ML, Figueira JP, Murta JN. Photodynamic therapy in highly myopic eyes with choroidal neovascularization: 5 years of follow-up. *Retina.* 2011;31(6):1089–1094. doi:10.1097/IAE.0b013e3181ff9546
26. Giansanti F, Virgili G, Donati MC, et al. Long-term results of photodynamic therapy for subfoveal choroidal neovascularization with pathologic myopia. *Retina.* 2012;32(8):1547–1552. doi:10.1097/IAE.0b013e3182411cee
27. Schnurrbusch UE, Jochmann C, Wiedemann P, Wolf S. Quantitative assessment of the long-term effect of photodynamic therapy in patients with pathologic myopia. *Graefes Arch Clin Exp Ophthalmol.* 2005;243(8):829–833. doi:10.1007/s00417-005-1147-4
28. Blinder KJ, Blumenkranz MS, Bressler NM, et al. Verteporfin therapy of subfoveal choroidal neovascularization in pathologic myopia: 2-year results of a randomized clinical trial--VIP report no. 3. *Ophthalmology.* 2003;110(4):667–673.
29. Rishi P, Rishi E, Bhende M, et al. Comparison of photodynamic therapy, ranibizumab/bevacizumab or combination in the treatment of myopic choroidal neovascularisation: a 9-year-study from a single centre. *Br J Ophthalmol.* 2016;100(10):1337–1340. doi:10.1136/bjophthalmol-2015-307802

30. Postelmans L, Pasteels B, Coquelet P, El Ouardighi H, Verougstraete C, Schmidt-Erfurth U. Severe pigment epithelial alterations in the treatment area following photodynamic therapy for classic choroidal neovascularization in young females. *Am J Ophthalmol.* 2004;138(5):803–808. doi:10.1016/j.ajo.2004.06.033
31. Airaldi M, Corvi F, Cozzi M, Nittala MG, Staurengi G, Sadda SR. Differences in long-term progression of atrophy between neovascular and nonneovascular age-related macular degeneration. *Ophthalmol Retina.* 2022;6(10):914–921. doi:10.1016/j.oret.2022.04.012
32. Eshtiaghi A, Issa M, Popovic MM, Muni RH, Kertes PJ. Geographic atrophy incidence and progression after intravitreal injections of anti-vascular endothelial growth factor agents for age-related macular degeneration: a meta-analysis. *Retina.* 2021;41(12):2424–2435. doi:10.1097/IAE.0000000000003207
33. Bae KW, Kim DI, Kim BH, et al. Risk factors for myopic choroidal neovascularization-related macular atrophy after anti-VEGF treatment. *PLoS One.* 2022;17(9):e0273613. doi:10.1371/journal.pone.0273613
34. Siedlecki J, Koch C, Schworm B, et al. Enlargement rate of geographic atrophy before and after secondary CNV conversion with associated anti-VEGF treatment. *BMC Ophthalmol.* 2021;21(1):4. doi:10.1186/s12886-020-01766-6

## Clinical Ophthalmology

Dovepress

### Publish your work in this journal

Clinical Ophthalmology is an international, peer-reviewed journal covering all subspecialties within ophthalmology. Key topics include: Optometry; Visual science; Pharmacology and drug therapy in eye diseases; Basic Sciences; Primary and Secondary eye care; Patient Safety and Quality of Care Improvements. This journal is indexed on PubMed Central and CAS, and is the official journal of The Society of Clinical Ophthalmology (SCO). The manuscript management system is completely online and includes a very quick and fair peer-review system, which is all easy to use. Visit <http://www.dovepress.com/testimonials.php> to read real quotes from published authors.

Submit your manuscript here: <https://www.dovepress.com/clinical-ophthalmology-journal>