

Two mechanisms of termination of idiopathic reentrant ventricular tachycardia originating from the left coronary cusp/right coronary cusp commissure with nonglobal capture

Takekuni Hayashi, MD, Takeshi Mitsuhashi, MD, PhD, Yoshitaka Sugawara, MD, Shin-ichi Momomura, MD, PhD

From the Division of Cardiovascular Medicine, Saitama Medical Center, Jichi Medical University, Saitama, Japan.

Introduction

Nonglobal capture identifies sites that are critical components for the reentrant circuit in ventricular tachycardia (VT). Idiopathic reentrant VT originating from the aortic sinus cusp is rare. We present a case of idiopathic reentrant VT originating from the aortic sinus that was terminated with nonglobal capture.

Case report

A 74-year-old man with symptomatic idiopathic VT that was refractory to multiple antiarrhythmic agents was referred to our hospital for electrophysiologic study. On admission, a 12-lead ECG showed atrial fibrillation. Transthoracic echocardiography revealed normal left ventricular systolic function with a dilated left atrium. The His–ventricular interval at baseline was 45 ms. A sustained hemodynamically tolerated monomorphic VT was reproducibly induced by burst pacing and 3 extrastimuli from the right ventricular apex (RVA). An inverse relationship was observed between the burst pacing cycle length (CL) and the interval from the last stimulus to the first beat of the induced VT. During VT (CL = 370 ms), pacing from the RVA at a constant rate (360 and 340 ms) was faster than the rate of the VT and failed to interrupt it. This was reflected in the constant fusion beats in the electrogram (Figures 1A and 1B). The degree of constant fusion differs between Figures 1A and 1B, and the morphology of fusion was more similar to that of the RVA pacing complexes when the pacing CL was decreased from 360 to 340 ms (progressive fusion is demonstrated). The tachycardia was not terminated by administration of adenosine triphosphate (40 mg) or verapamil (5 mg). Interestingly, it was terminated by

overdrive pacing and a single extrastimulus from the left coronary cusp (LCC)/right coronary cusp (RCC) commissure (Figures 2 and 3).

Discussion

Idiopathic VT originating from the aortic sinus cusp has been encountered in clinical settings.^{1,2} This form of VT typically terminates in response to adenosine, verapamil, and enhanced vagal tone, all of which lower the increased levels of intracellular calcium. It can be cured by radiofrequency catheter ablation as well. Termination of VT in response to adenosine is thought to depend on a cyclic adenosine monophosphate–dependent mechanism mediated by triggered activity of delayed afterdepolarizations. In contrast, few studies have described an idiopathic reentrant VT originating from the aortic cusp. In the present case, the mechanism of the VT was not triggered activity but reentry, because of the observations of entrainment pacing and the ineffectiveness of adenosine triphosphate/verapamil.

For hemodynamically tolerated reentrant VT, catheter ablation strategies are generally used in combination with entrainment pacing and 3-dimensional electroanatomic mapping, and radiofrequency catheter ablation usually is performed at sites with mid-diastolic potentials, where pacing entrains the VT with concealed fusion and the postpacing interval is ≤ 30 ms of the VT cycle length.³ Moreover, termination with nonglobal capture during entrainment pacing is defined as termination of a reentrant VT by a pacing stimulus that does not result in global ventricular capture.⁴ Two possible mechanisms may underlie this phenomenon, as described previously. First, local capture of the isthmus without global ventricular capture terminates VT by resulting in a block in both directions within the isthmus. Second, an impulse delivered during the refractory period may prolong the repolarization and refractoriness of tissue, resulting in termination of VT. Nonglobal capture identifies sites that are critical components of the reentrant circuit, and these sites are optimum ablation sites. However,

KEYWORDS Ventricular tachycardia; Termination with nonglobal capture
ABBREVIATIONS CL = cycle length; LCC = left coronary cusp; RCC = right coronary cusp; RVA = right ventricular apex; VT = ventricular tachycardia (Heart Rhythm Case Reports 2015;1:2–5)

Address reprint requests and correspondence: Dr. Takekuni Hayashi, Division of Cardiovascular Medicine, Saitama Medical Center, Jichi Medical University, 1-846, Amanuma, Oomiya-ku, Saitama 330-8503, Japan. E-mail address: hayashi1979@yahoo.co.jp.

KEY TEACHING POINTS

- The mechanism of the ventricular tachycardia (VT) was not triggered activity but reentry, because of the observations of entrainment pacing and the ineffectiveness of adenosine triphosphate/verapamil.
- Termination with nonglobal capture identifies sites that are critical components of the reentrant VT circuit, and these sites are optimum ablation sites.
- Two possible mechanisms of VT termination with nonglobal capture were observed in this rare case of idiopathic reentrant VT originating from the left coronary cusp/right coronary cusp commissure.

in the case of idiopathic reentrant VT originating from the aortic cusp, identification of these sites is difficult because the ventricular potential is small, pacing threshold is high, and pacing easily captures the His–Purkinje system. In the present case, the ventricular potential recorded in the aortic cusp was very small, and the pacing threshold was very high (20 mA at 10 ms).

As seen from the overdrive pacing from the LCC/RCC commissure during the VT shown in [Figure 2A](#), the timing of the first to eighth stimulus was between the mid-diastolic phase and the early diastolic phase. However, the first 7 stimuli were not captured, and the eighth stimulus terminated the VT with

nonglobal capture. Furthermore, the ninth stimulus captured the entrance site of the VT circuit and was proven to be a stimulus to QRS/VT CL ratio of 0.59 (200/340). A possible mechanism underlying VT termination with nonglobal capture is that the eighth stimulus captured the early diastolic potential (ie, the entrance site of the VT circuit) and resulted in 2-way block within the isthmus. However, in the present case, confirmation of local capture was difficult because only an electrophysiologic sign of the local capture was obtained. This is because a very low ventricular fractionated potential was recorded in the LCC/RCC commissure in the diastolic phase during the VT, and an artifact occurred because of the high-output pacing.

The major point of interest in the present case is that a single extrastimulus terminated the VT with nonglobal capture. The timing of the extrastimulus was on the QRS complex. In this phase, the impulse from the critical isthmus spread out from the reentrant circuit and resulted in a QRS complex. A single extrastimulus is unable to terminate the VT if it captures the systolic potential. Therefore, the possible mechanism underlying VT termination by the single extrastimulus was not local capture of the isthmus resulting in 2-way block within the isthmus but prolongation of repolarization and refractoriness of tissue.

To the best of our knowledge, this is the first report of idiopathic reentrant VT originating from the LCC/RCC commissure that was terminated with nonglobal capture. Radio-frequency catheter ablation was applied at the LCC/RCC commissure during the VT, whereby the VT was successfully eliminated and no inducible tachycardia was noted.

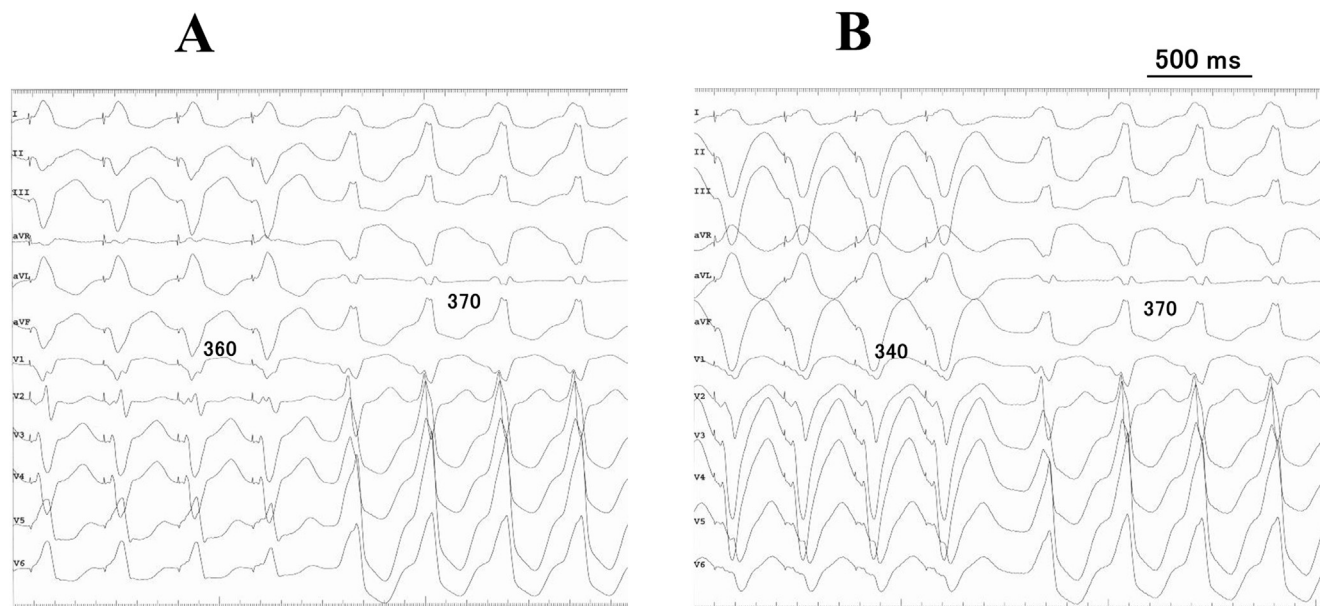


Figure 1 A: Twelve-lead ECG showing constant fusion during right ventricular apex (RVA) overdrive pacing (cycle length [CL] = 360 ms) of the ventricular tachycardia (VT; CL = 370 ms). B: ECG showing progressive fusion during RVA overdrive pacing (CL = 340 ms) of the VT.

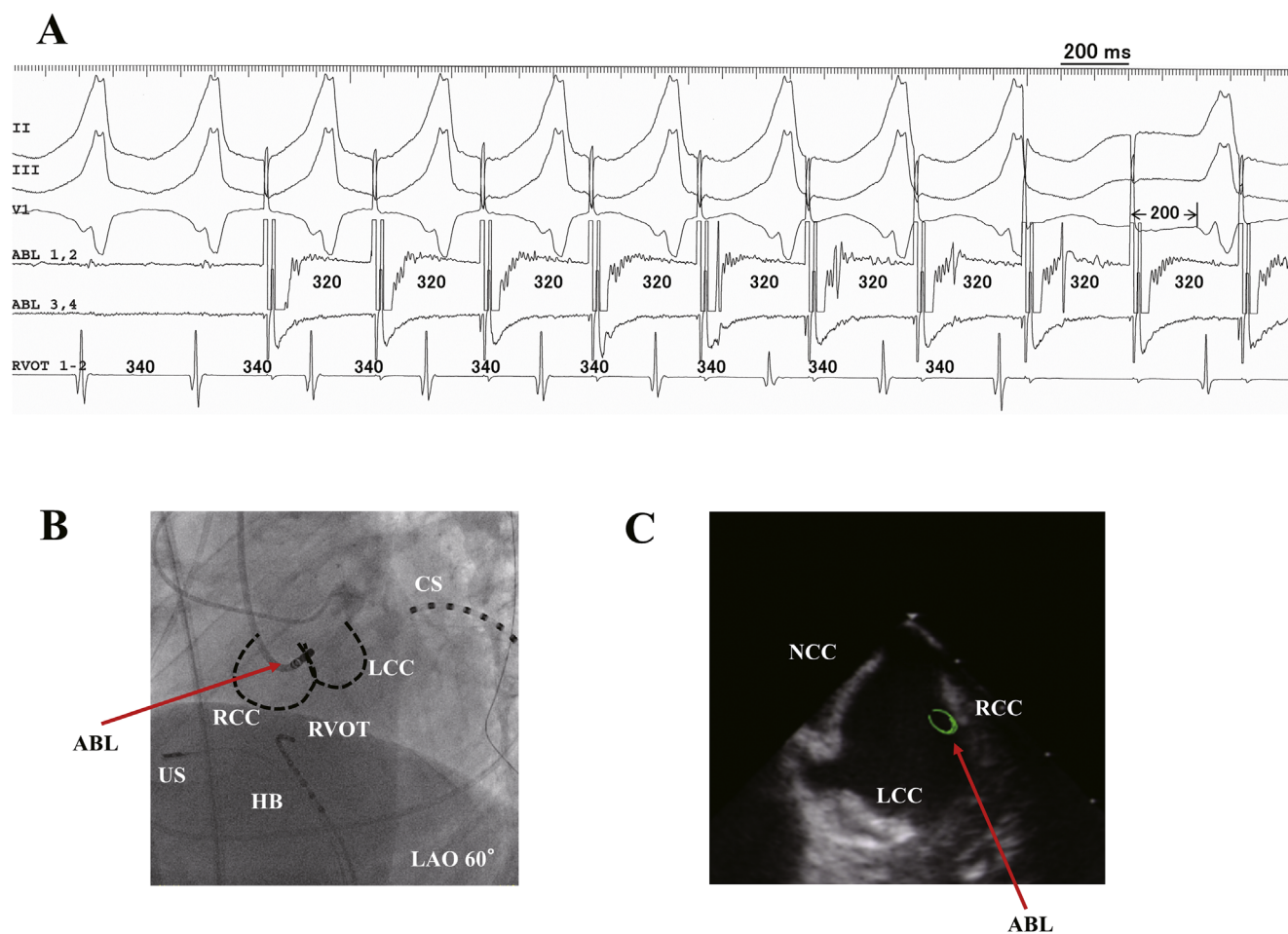


Figure 2 **A:** Intracardiac electrogram showing overdrive pacing from the LCC/RCC commissure during ventricular tachycardia (cycle length = 360 ms) at a paced cycle length of 340 ms. **B:** Catheter position under fluoroscopy. **C:** Catheter position under intracardiac ultrasonography (Soundstar, Biosense Webster, Diamond Bar, CA). The tip of the ablation catheter is positioned in the LCC/RCC commissure. ABL = ablation catheter; CS = coronary sinus; HB = His bundle; LAO = left anterior oblique; LCC = left coronary cusp; NCC = noncoronary cusp; RCC = right coronary cusp; RVOT = right ventricular outflow tract; US = ultrasonography.

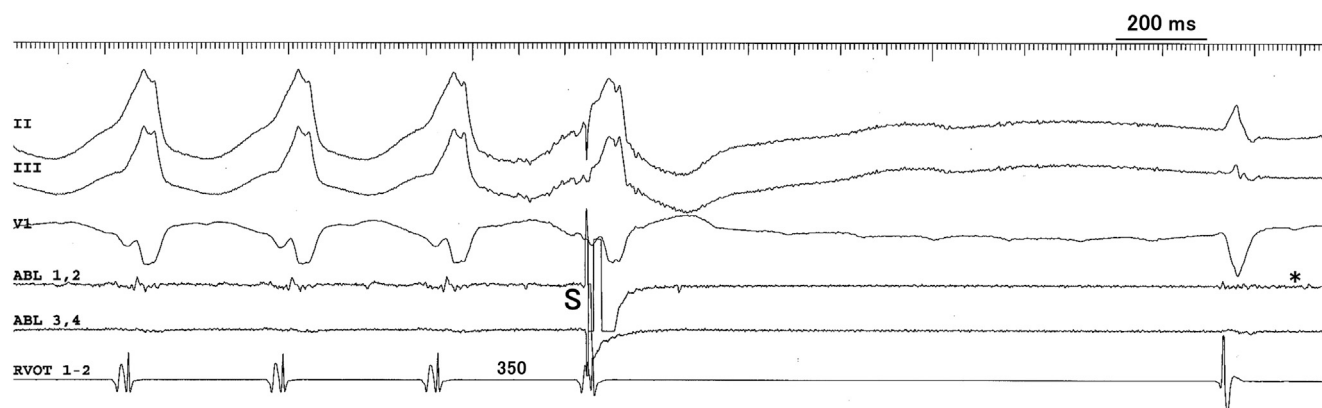


Figure 3 Intracardiac electrogram showing that the single extrastimulus terminated the ventricular tachycardia (VT). A potential in the mid-diastolic phase during the VT is observed that persisted even after the VT terminated. However, this mid-diastolic potential more likely is a mechanical valve artifact as a result of a tiny potential, such as the mid-diastolic potential recorded, after the last QRS complex (*asterisk*).

References

1. Kanagaratnam L, Tomassoni G, Schweikert R, et al. Ventricular tachycardias arising from the aortic sinus of Valsalva: an under-recognized variant of left outflow tract ventricular tachycardia. *J Am Coll Cardiol* 2001;37:1408–1414.
2. Hachiya H, Aonuma K, Yamauchi Y, Igawa M, Nogami A, Iesaka Y. How to diagnose, locate, and ablate coronary cusp ventricular tachycardia. *J Cardiovasc Electrophysiol* 2002;13:551–556.
3. Soejima K, Stevenson WG, Maisel WH, Sapp JL, Epstein LM. Electrically unexcitable scar mapping based on pacing threshold for identification of the reentry circuit isthmus: feasibility for guiding ventricular tachycardia ablation. *Circulation* 2002;106:1678–1683.
4. Bogun F, Krishnan SC, Marine JE, et al. Catheter ablation guided by termination of postinfarction ventricular tachycardia by pacing with nonglobal capture. *Heart Rhythm* 2004;1:422–426.