


CASE REPORT

Open Access



Sudden extensive bloody pleural and pericardial effusion in a subject with untreated known hypothyroidism after total thyroidectomy, triggered by pneumonia

Yuichiro Iwamoto, Fuminori Tatsumi, Yukino Katakura, Kazunori Dan, Ryo Wamata, Tomohiko Kimura, Masashi Shimoda, Shuhei Nakanishi, Kohei Kaku, Tomoatsu Mune and Hideaki Kaneto 

Abstract

Background: In subjects with hypothyroidism, edema is often observed, and pleural effusion and pericardial fluid could be also observed. The color of such fluid retention is usually yellow. Here we show a very rare case with hypothyroidism who had bloody pleural effusion and bloody pericardial fluid.

Case presentation: A 42-year-old male noticed chest pain and the aggravation of exertional dyspnea, and he was transported to our institution by emergency. He had Graves' disease and underwent total thyroidectomy about 4 years before. After then, he had been treated with 200 µg/day of levothyroxine sodium for the maintenance of thyroid function. However, he self-interrupted such medication about 2 years before. Thyroid function on admission was reduced as follows: free triiodothyronine, 1.60 pg/mL; free thyroxine < 0.40 ng/dL; thyroid-stimulating hormone 25.50 µU/mL. Inflammation markers were increased: white blood cells 25,280 /µL; C-reactive protein 18.66 mg/dL. A large amount of pericardial fluid and pleural effusion were observed in chest and abdominal computer tomography and echocardiography. In addition, we performed pleural effusion and pericardial fluid collection. Pleural effusion in this subject showed bloody color, but not yellow. In cell block specimen of pleural effusion and pericardial fluid, red blood cells, neutrophils and lymphocyte component were observed. In this subject, however, we were unable to find any obvious background disease causing bloody pericardial effusion. Finally, we concluded that bloody pleural effusion and bloody pericardial fluid were brought about in a subject with untreated known hypothyroidism after total thyroidectomy, triggered by pneumonia.

Conclusions: In subjects with hypothyroidism, fluid and mucopolysaccharide are stored in interstitial space and protein osmolality is increased, thus leading to edema and fluid retention. It is noted here that pleural effusion and pericardial fluid in this subject showed bloody color and included red blood cells. There are no reports of bloody pericardial fluid with hypothyroidism. Therefore, it is important to keep in mind that a subject with some trigger, such as

*Correspondence: kaneto@med.kawasaki-m.ac.jp

Department of Diabetes, Endocrinology and Metabolism, Kawasaki Medical School, 577 Matsushima, Kurashiki 701-0192, Japan



© The Author(s) 2022. **Open Access** This article is licensed under a Creative Commons Attribution 4.0 International License, which permits use, sharing, adaptation, distribution and reproduction in any medium or format, as long as you give appropriate credit to the original author(s) and the source, provide a link to the Creative Commons licence, and indicate if changes were made. The images or other third party material in this article are included in the article's Creative Commons licence, unless indicated otherwise in a credit line to the material. If material is not included in the article's Creative Commons licence and your intended use is not permitted by statutory regulation or exceeds the permitted use, you will need to obtain permission directly from the copyright holder. To view a copy of this licence, visit <http://creativecommons.org/licenses/by/4.0/>. The Creative Commons Public Domain Dedication waiver (<http://creativecommons.org/publicdomain/zero/1.0/>) applies to the data made available in this article, unless otherwise stated in a credit line to the data.

infection, may have a hematologic fluid retention that is not seen when hypothyroidism is present alone, as observed in this subject.

Keywords: Hypothyroidism, Bloody pleural effusion, Bloody pericardial fluid, Case report

Background

Graves' disease is hyperthyroidism which is characterized by diffuse goiter, exophthalmos and palpitation. When a total thyroidectomy is performed for Graves' disease, thyroid hormone preparations such as levothyroxine sodium are commonly administered to maintain thyroid function. Chronic lack of thyroid hormone replacement therapy after total thyroidectomy increases the risk of mood disorders, cardiovascular disorders, and osteoporosis [1]. In addition, in subjects with hypothyroidism, edema is often observed and pleural effusion and pericardial fluid could be also observed. In hypothyroidism, fluid retention occurs along with mucopolysaccharides in the interstitium, resulting in edema and fluid retention. Fluid accumulation with mucopolysaccharides is often yellow in color because of the abundance of protein, and rarely bloody because of the absence of red blood cell components in the accumulation [2, 3]. In general, bloody pleural effusion is observed in subjects with malignancy, tuberculous pleural inflammation, pulmonary thrombosis and external wound [4].

Here, we present a patient who presented with sudden bloody pericardial effusion and bloody pleural effusion simultaneously with pneumonia in a background of hypothyroidism due to prolonged interruption of thyroid hormone preparations.

Case presentation

A 42-year-old male noticed chest pain and the aggravation of exertional dyspnea, and he was transported to our institution by emergency. He had Graves' disease accompanied by exophthalmos and palpitation and underwent total thyroidectomy about 4 years before. After then, he had been treated with 200 µg/day of levothyroxine sodium for the maintenance of thyroid function. However, he self-interrupted such medication about 2 years before. He sometimes had felt exertional dyspnea since 1 year before, and he finally noticed chest pain and the aggravation of exertional dyspnea about 2 weeks before. There was no family history of thyroid disease or heart disease. He had a smoking history with a Brinkman index of 440. He had no history of alcohol consumption.

On admission, his height, body weight and body mass index were 180 cm, 118 kg and 35.2 kg/m², respectively. Blood pressure, heart rate and body temperature were 155/103 mmHg, 79 /min and 36.3°C. Saturation of

percutaneous oxygen (SpO₂) was 78% at room air. Respiratory sounds were attenuated in bilateral lung fields. Heart sounds were weak, and no pericardial friction sounds were heard. There was no edema in the extremity, and there were no other physical findings of note. Table 1 shows the data on admission in this subject. The thyroid-stimulating hormone (TSH) was high and free triiodothyronine (FT₃) and free thyroxine (FT₄) were low, indicating hypothyroidism after total thyroidectomy. White blood cell (WBC) and C-reactive protein (CRP) levels were also increased. Increased liver enzymes, renal dysfunction and hyperglycemia were also present. In addition, pleural effusion was observed in chest X-ray (Fig. 1A). A large amount of pericardial fluid was observed in transthoracic echocardiography (Fig. 1B, arrow), although the ejection fraction (EF) was about 60%. A large amount of pericardial fluid and pleural effusion was observed in chest and abdominal computer tomography (CT) (Fig. 1C). In addition, there was a consolidation in the left lower lobe that was suspicious of pneumonia and a pressure-drain atelectasis due to pleural and pericardial effusions. Thyroid ultrasound was performed but no residual thyroid tissue was found. Based on these findings, we diagnosed him with hypothyroidism and subsequent fluid retention due to self-interruption of thyroid hormone replacement therapy with levothyroxine sodium. In addition, there was emphysematous change in the left lower lobe. The patient was treated for hypoxemia with nasal high flow and finally SpO₂ was increased up to 100%.

In addition, we performed pleural effusion collection. Pleural effusion in this subject showed bloody color, but not yellow. As shown in Fig. 2A, in cell block specimen of pleural effusion, red blood cells, neutrophils and lymphocyte component were observed. There were no malignancy findings in pleural effusion. The characteristics of pleural effusion are as follows: pH, 7.8; specific gravity, 1.035; total protein, 5.2 g/dL; glucose, 120 mg/dL; adenosine deaminase (ADA), 18.8 U/L; LDH, 292 U/L; amylase, 19 U/L; carcinoembryonic antigen (CEA), 3.2 ng/mL; carbohydrate antigen 19–9 (CA19–9), < 5.0 U/mL. We thought that characteristics of pleural effusion in this subject was exudative, but not transudative, based on Light's criteria. Furthermore, we performed pericardial fluid collection. Pericardial fluid also showed bloody color, but not yellow. Cell block specimen of pericardial fluid showed erythrocyte, neutrophil, and lymphocyte

Table 1 Clinical data on admission in this subject

Peripheral blood		Diabetes markers		Electrolytes	
Red blood cells	497 × 10 ⁴ /μL	Plasma glucose	247 mg/dL	Sodium	137 mEq/L
Hemoglobin	15.5 g/dL	HbA1c	6.4%	Potassium	3.2 mEq/L
White blood cells	25,280 /μL	Lipid markers		Chloride	97 mEq/L
Neutrophils	67.0%	LDL-cholesterol	138 mg/dL	Calcium	6.9 mg/dL
Eosinophils	0.0%	HDL-cholesterol	28 mg/dL	Phosphorous	8.7 mg/dL
Lymphocytes	15.0%	Triglyceride	104 mg/dL	Magnesium	2.3 mg/dL
Platelet	46.3 × 10 ⁴ /μL	Endocrine markers		Inflammation marker	
Blood biochemistry		TSH	25.50 μU/mL	CRP	18.66 mg/dL
Total protein	7.9 g/dL	FT3	1.60 pg/mL	Infection	
Albumin	3.6 g/dL	FT4	< 0.40 ng/dL	Adenovirus	< 4-fold
Total bilirubin	2.1 mg/dL	TSAb	498%	Coxsackievirus	< 4-fold
AST	90 U/L	TRAb	16.6%	Echovirus	< 4-fold
ALT	71 U/L	Intact-PTH	41 pg/mL	Influenza virus	< 10-fold
γ-GTP	134 U/L	Immune markers		C7-HRP	Negative
LDH	488 U/L	Anti-nuclear Ab	40-fold	T-SPOT	Negative
Creatinine	1.61 mg/dL	Rheumatoid factor	< 15 U/mL	HIV	Negative
BUN	19 mg/dL	PR3-ANCA	< 1.0 U/mL		
CK	888 U/L	MPO-ANCA	< 1.0 U/mL		
CK-MB	11 U/L				

Abbreviation: *AST* aspartate aminotransferase, *ALT* alanine aminotransferase, *γ-GTP* γ-glutamyl transpeptidase, *LDH* lactate dehydrogenase, *BUN* blood urea nitrogen, *CK* creatine kinase, *HbA1c* hemoglobin A1c, *LDL* low density lipoprotein, *HDL* high density lipoprotein, *TSH* thyroid-stimulating hormone, *FT3* free triiodothyronine, *FT4* free thyroxine, *TSAb* thyroid-stimulating antibody, *TRAb* thyrotropin receptor antibody, *PTH* parathyroid hormone, *Ab* antibody, *PR3-ANCA* proteinase 3 antineutrophil cytoplasmic antibody-associated vasculitis, *MPO-ANCA* myeloperoxidase antineutrophil cytoplasmic antibody-associated vasculitis, *CRP* C-reactive protein, *HIV* human immunodeficiency virus

components, but no evidence of malignancy. Culture results showed α-streptococcus in sputum culture. Blood, urine, pleural fluid, and pericardial fluid cultures were negative.

Further investigations were performed to determine the cause of the pericardial fluid. The results of the blood tests are listed in Table 1. Pericarditis due to viral pericarditis, tuberculous pericarditis and autoimmune diseases were excluded from the blood test results. The possibility of acute myocardial infarction was ruled out as the creatine kinase-MB (CK-MB) was within normal limits and the patient was asymptomatic on echocardiography after recovery. The WBC was elevated on admission, but we thought that this was due to pneumonia rather than hematological disease.

Regarding the treatment for hypothyroidism, we started 50 μg/day of levothyroxine sodium and gradually increased its dose up to 200 μg/day. In addition, since pneumonia was detected in the lower left lung and inflammation markers such as CRP and WBC were increased, we started antibiotics sulbactam/ampicillin and continued it for 7 days. Two days after admission, pericardial drainage was performed, and a total of drainage was as large as 950 mL. After then, dyspnea was substantially reduced. Therefore, 3 days later, pericardial

drainage was removed. Eighteen days later, pericardial fluid and pleural effusion disappeared almost completely in chest and abdominal CT. About 1 month later, thyroid function was normalized. After then, there was no recurrence of pericardial fluid and pleural effusion. Finally, based on the time course of this case in which the recurrence of fluid retention disappeared after thyroid hormone replacement therapy, we concluded that bloody pleural effusion and bloody pericardial fluid were brought about by hypothyroidism in this subject.

Discussion and conclusions

In this case report, we showed a subject with hypothyroidism with bloody pericardial effusion and bloody pleural effusion, as well as pneumonia, after thyroid hormone replacement therapy had been interrupted for 2 years. The patient developed pneumonia after self-interruption of the thyroid hormone levothyroxine sodium, which was complicated by dyspnea and fluid retention, and such symptoms and fluid retention were relieved after initiation of levothyroxine sodium and antimicrobial agents. Therefore, we thought that dyspnea and fluid retention were induced by hypothyroidism. It is noted here that his pleural effusion and pericardial fluid were both bloody color, but not yellow, and in cell block specimen

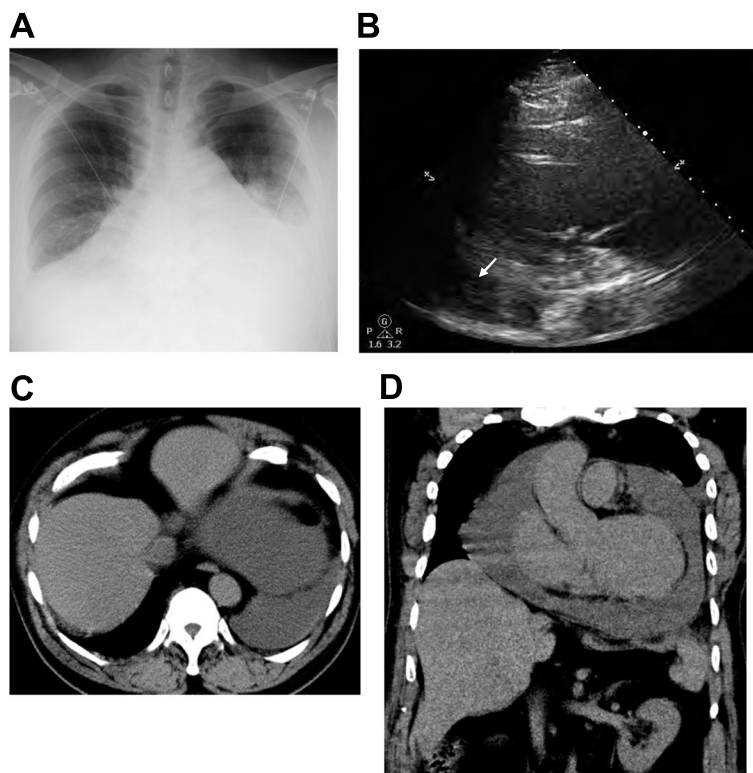
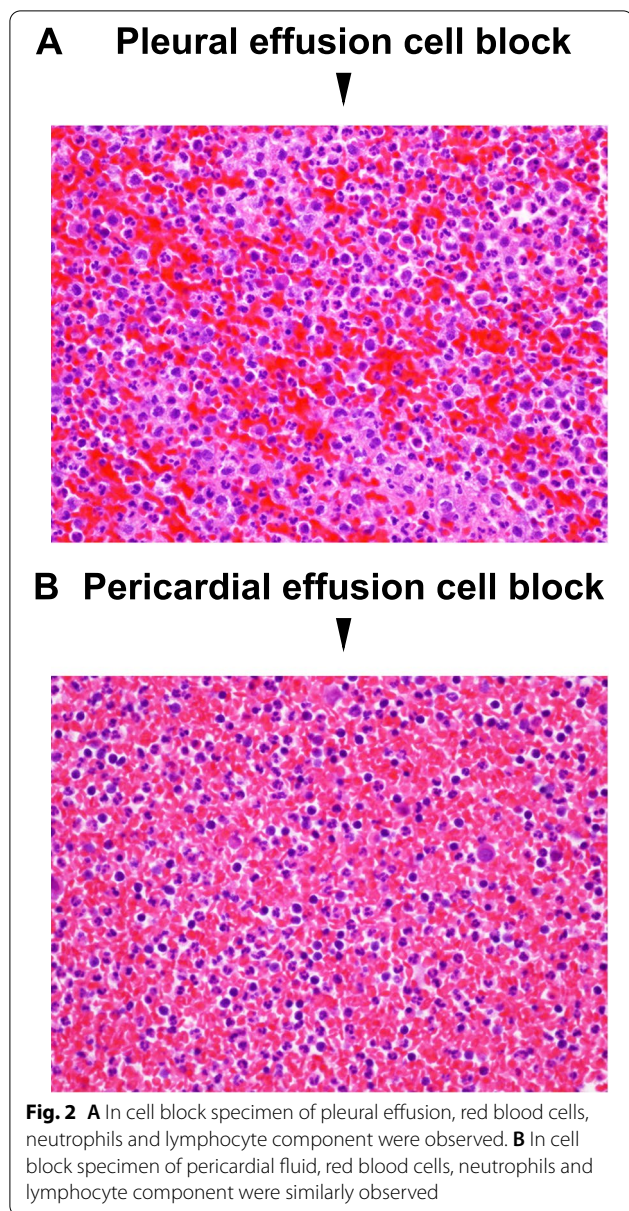


Fig. 1 **A** Pleural effusion was observed in chest X-ray. **B** A large amount of pericardial fluid was observed in echocardiography (arrow). **C, D** A large amount of pleural effusion and pericardial fluid were observed in chest and abdominal computer tomography (CT)

of a pleural effusion and pericardial fluid, red blood cells were observed. To the best of our knowledge, there are no reported cases of bloody pleural or pericardial effusions caused solely by hypothyroidism. Therefore, we think that hypothyroidism and another trigger may have caused the patient to present with bloody pleural and pericardial effusions.

Thyroid hormones are involved in metabolism, regulation of the sympathetic nervous system, and growth during childhood, and deficiency of thyroid hormones disrupts the metabolic mechanisms of the body. In subjects with hypothyroidism, fluid and mucopolysaccharide are stored in interstitial space and protein osmolality is increased, thus leading to edema and fluid retention. In addition, the characteristics of pleural effusion in this subject was exudative, which point is compatible with previous reports showing that characteristics of pleural effusion due to hypothyroidism is exudative, but not transudative [2, 3]. It is noted here that pleural effusion and pericardial fluid in this subject showed bloody color and included red blood cells. There is no report that pericardial fluid due to hypothyroidism shows bloody color. A flowchart of the diagnosis of a bloody pericardial

fluid and bloody pleural effusion in this case is shown in Fig. 3. Bloody pericardial fluid could be brought about by several diseases such as viral pericarditis, tuberculous pericarditis, acute myocardial infarction, malignancy, collagen disease, blood disease, uremia, pulmonary vein thrombosis, trauma and rupture of the aortic aneurysm [4]. In this subject, however, we excluded the possibility of having these diseases as described in case presentation section. Diseases that can bring about grossly bloody pleural effusion include malignancy, tuberculous pleurisy, pulmonary thromboembolism, and traumatic hemothorax, all of which were negative in this case [4]. Although bacterial pleurisy and pyothorax can also cause bloody pleural effusion, pleural fluid culture test was negative and pleural fluid glucose level was not decreased (120 mg/dL) in this case, which was not compatible with bacterial pleurisy or pyothorax. In addition, there was no report of bloody pleural effusion due to pneumonia-associated pleural effusion. In the case of bloody pleural effusions, malignancy and tuberculosis are more frequent [5], and these tests are prioritized in clinical practice. Other diseases presenting with bloody pleural effusions are less frequent and may delay testing and diagnosis. On the



other hand, measurement of thyroid hormones is quite straightforward. If the bloody pleural effusion is due to hypothyroidism, it can be quickly corrected with thyroid hormone replacement. We believe that many clinicians should be aware of this fact.

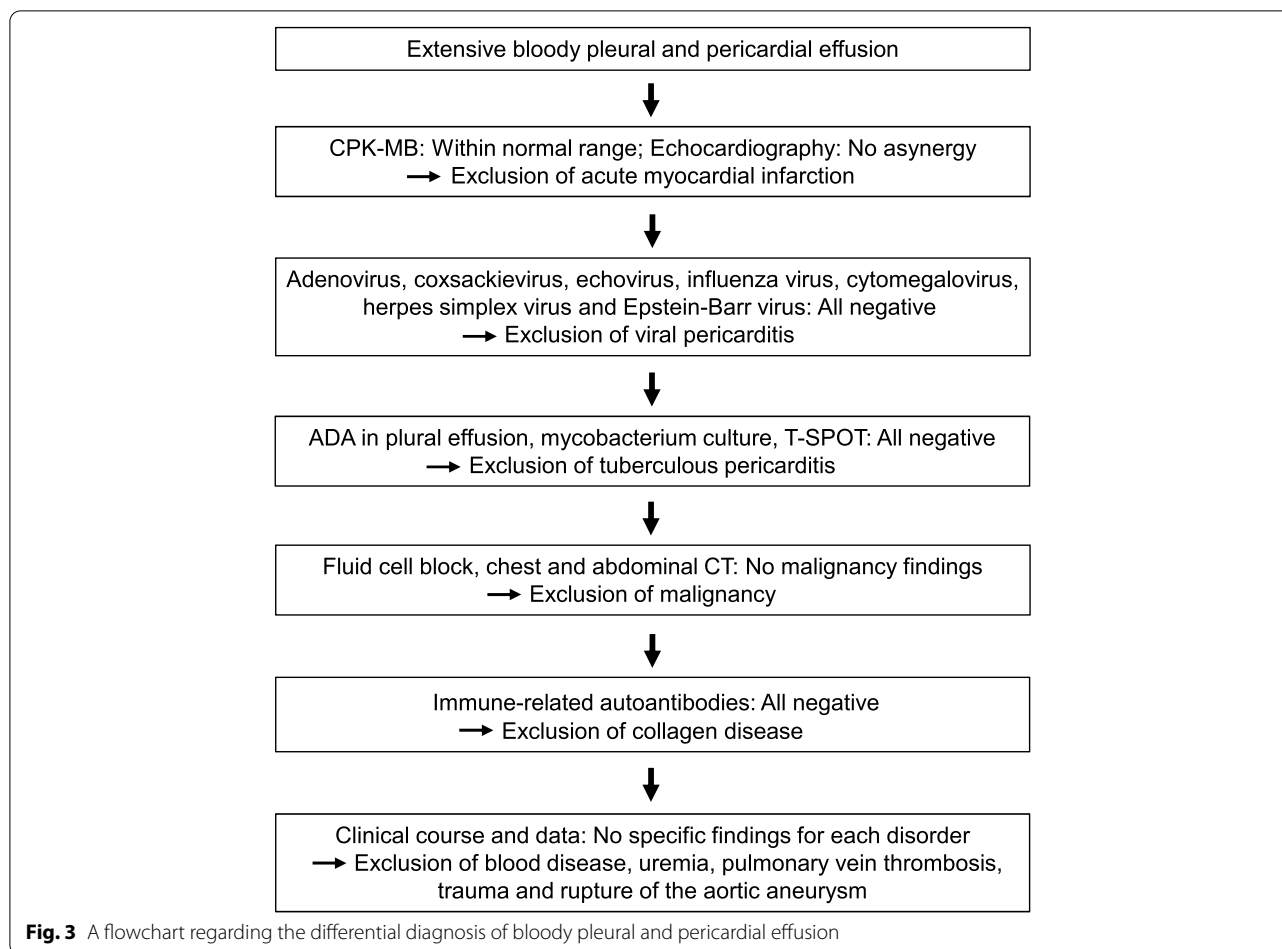
Hypothyroidism causes increased capillary permeability and impaired lymphatic drainage [6]. There have been case reports of bloody pericardial effusions due to systemic lupus erythematosus (SLE) [7]. Pericardial effusions due to SLE are also usually clear and yellow, but prolonged inflammation and infiltration of the pericardium with large numbers of

polymorphonuclear leukocytes and monocytes may result in a bloody pericardial effusion. As numerous inflammatory cells were also detected in this subject's pericardial and pleural fluid cell block, this subject may have presented with a bloody pericardial and pleural effusion by the same mechanism. Therefore, we concluded that bloody pleural effusion and bloody pericardial fluid were brought about in a subject with untreated known hypothyroidism after total thyroidectomy, triggered by pneumonia.

Fluid retention in hypothyroidism is characterized by a predominance of fluid retention in the upper body, such as pleural effusion and pericardial fluid. It was reported that about 30% of subjects with hypothyroidism had pericardial fluid and that most of them are reduced by thyroid hormone replacement therapy [8]. In this subject, however, a total of pericardial drainage was as large as 950 mL which was much larger than that in the previous reports. In addition, it was reported that cardiac tamponade due to hypothyroid was recovered within a few days by pericardial drainage and thyroid hormone replacement therapy [9]. Therefore, it is important to differentiate pericardial effusion due to hypothyroidism as early as possible in cases of unexplained pericardial effusion. We think that starting levothyroxine sodium soon after admission could help to prevent the recurrence of pericardial fluid in this subject. In addition, discontinuation of thyroid hormone replacement therapy in patients with documented hypothyroidism should be avoided as it can lead to serious complications such as pleural and/or pericardial effusions.

Severe hypothyroidism causes hypothermia and bradycardia. It is known that in severe conditions with a marked inflammatory response as observed in this case, an adaptive response to reduced thyroid hormone demand can reduce catabolism to protect the body [10]. In hypothyroidism, bradycardia may not be present even in cases where bradycardia should be present such as in cardiac tamponade [11]. It is assumed that a similar mechanism is responsible for the reduced tachycardic response in the present case. In most cases of serious diseases, there are other important signs besides vital signs, but in the case of hypothyroidism, vital signs may not be serious at first glance as observed in this case, and thus we must be careful about this point.

Although bloody fluid retention due to hypothyroidism is very rare and its pathogenesis is not known, we experienced a case of hypothyroidism with bloody pleural effusion and bloody pericardial effusion both of which were improved by pericardial drainage and thyroid hormone replacement therapy after excluding the



possibility of other diseases. Taken together, we must bear in mind that bloody pleural effusion and bloody pericardial effusion that is not seen when hypothyroidism is present alone can be brought on by hypothyroidism when complicated by other serious diseases such as infection.

Abbreviations

FT3: Free triiodothyronine; FT4: Free thyroxine; TSH: Thyroid-stimulating hormone; WBC: White blood cells; CRP: C-reactive protein; CT: Computer tomography; SpO₂: Saturation of percutaneous oxygen; AST: Aspartate transaminase; ALT: Alanine aminotransferase; γ-GTP: γ-glutamyl transpeptidase; BUN: Blood urea nitrogen; EF: Ejection fraction; ADA: Adenosine deaminase; CEA: Carcinoembryonic antigen; CA 19–9: Carbohydrate antigen 19–9; SLE: Systemic lupus erythematosus.

Acknowledgements

Not applicable.

Authors' contributions

Y.I., F.T., H.K. researched data and/or wrote the manuscript. Y.K., K.D., R.W., T.K., M.S., S.N., K.K., T.M. contributed to discussion. The author(s) read and approved the final manuscript.

Funding

The authors declare that there is no funding associated with this manuscript.

Availability of data and materials

Not applicable.

Declarations

Ethics approval and consent to participate

Not applicable.

Consent for publication

Written informed consent was obtained from the patient for publication of this Case report and any accompanying images. A copy of the written consent is available for review by the Editor of this journal.

Competing interests

We do not have any potential conflicts of interest relevant to this article.

Received: 9 January 2022 Accepted: 11 September 2022

Published online: 17 September 2022

References

1. Biondi B, Cooper DS. Thyroid hormone therapy for hypothyroidism. *Endocrine*. 2019;66(1):18–26.
2. Parving HH, Hansen JM, Nielsen SL, Rossing N, Munck O, Lassen NA. Mechanisms of edema formation in myxedema—increased protein extravasation and relatively slow lymphatic drainage. *N Engl J Med*. (1979) 301, 460–465. <https://doi.org/10.1056/NEJM197908303010902>.

3. Chahine J, Ala CK, Genty JL, Pantalone KM, Klein AL. Pericardial disease in patients with hypothyroidism. *Heart*. 2019;105(13):1027–33. <https://doi.org/10.1136/heartjnl-2018-314528>.
4. Villena V, Encuentra L, Lujan RG, Sustaeta JE, Martinez CJA. Clinical implications of appearance of pleural fluid at thoracentesis. *Chest*. 2004;125(1):156–9. <https://doi.org/10.1378/chest.125.1.156>.
5. Porcel JM, Vives M. Etiology and pleural fluid characteristics of large and massive effusions. *Chest*. 2003;124(3):978–83.
6. Ladenson PW. Recognition and management of cardiovascular disease related to thyroid dysfunction. *Am J Med*. 1990;88:638–41.
7. Castier MB, Albuquerque EM, Menezes ME, Klumb E, Albanesi Filho FM. Cardiac tamponade in systemic lupus erythematosus. Report of four cases. *Arq Bras Cardiol*. 2000;75:446–8.
8. Kerber RE, Sheeman B. Echocardiographic evaluation of pericardial effusion in myxedema. Incidence and biochemical and clinical correlations. *Circulation*. 1975;52:823–7. <https://doi.org/10.1161/01.CIR.52.5.823>.
9. Maddali VR, Myryala S, Bellamkonda YS, Nagula P. Cardiac tamponade due to primary hypothyroidism: acute management and approach to prevent recurrence—a case report. *Eur Heart J Case Rep*. 2020;4(3):1–5. <https://doi.org/10.1093/ehjcr/ytaa071>.
10. Gardner DF, et al. Effect of tri-iodothyronine replacement on the metabolic and pituitary responses to starvation. *N Engl J Med*. 1979;300(11):579–84.
11. Baldwin C, et al. Myxedema heart and Pseudotamponade. *J Endocr Soc*. 2021;5(1):bvaa125.

Publisher's Note

Springer Nature remains neutral with regard to jurisdictional claims in published maps and institutional affiliations.

Ready to submit your research? Choose BMC and benefit from:

- fast, convenient online submission
- thorough peer review by experienced researchers in your field
- rapid publication on acceptance
- support for research data, including large and complex data types
- gold Open Access which fosters wider collaboration and increased citations
- maximum visibility for your research: over 100M website views per year

At BMC, research is always in progress.

Learn more biomedcentral.com/submissions

