

Case Report

Supratentorial Intraparenchymal Haemorrhages during Spine Surgery

Gilberto Ka Kit Leung, M.D., Johnny Ping Hon Chan, M.D.

Division of Neurosurgery, Department of Surgery, Li Ka Shing Faculty of Medicine, The University of Hong Kong, Queen Mary Hospital, Hong Kong

Intracranial haemorrhages are rare but potentially life-threatening complications of spine surgery. Most reported cases involved subdural or cerebellar haemorrhages; supratentorial parenchymal bleeding is very uncommon. We report a 28-year-old woman who underwent resection of a thoracic Ewing's sarcoma, and developed fatal haemorrhages around her cerebral metastases during surgery. The clinical presentations, possible pathogenesis and potential preventive measures are discussed. Patients with disseminated metastases within the neural axis are at risks of intracranial complications during spine surgery. The presence of intracranial mass lesions should be considered as a relative contraindication to intradural spine surgery.

Key Words : Cerebrospinal fluid · Complications · Haemorrhage · Neoplasm · Spine.

INTRODUCTION

Intracranial haemorrhages are rare but potentially life-threatening complications of spine surgery^{1,3,6,8}. The underlying mechanism is likely due to cerebrospinal fluid (CSF) loss, causing intracranial hypotension and traction on the cerebral veins⁴. The majority of reported cases involved subdural⁷ or cerebellar haemorrhages⁵ that presented in the post-operative period. Supratentorial parenchymal bleeding, on the other hand, is very uncommon. We report a case of multiple intracerebral haemorrhages (ICH) that occurred during intradural spine surgery.

CASE REPORT

A 28-year-old woman presented with an acute onset of bilateral lower weakness. She had a history of Ewing's sarcoma involving the thoracic spine with metastases to the right lung, right kidney and brain (Fig. 1). Palliative systemic chemotherapy, radiotherapy to the right thorax, and whole brain irradiation were given seven months prior. She had no bleeding diathesis. On examination, she did not have any sign of raised intracranial pressure (ICP). Her lower limb motor power was grade 1/5 bilaterally. The sensory level was at T10 dermatome. There was acute urinary retention but intact anal tone. Computerized to-

mography (CT) of the brain showed multiple cerebral and cerebellar metastases with perifocal oedema (Fig. 2). There was no hydrocephalus. Magnetic resonance studies showed an intradural extramedullary lesion at T4/5 that was causing significant cord compression (Fig. 3).

Because of previous radiotherapy, surgery was the only treatment option for her. Laminectomy for tumour excision was

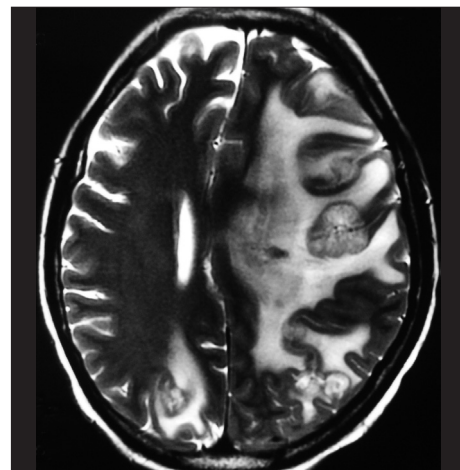


Fig. 1. T2-weighted magnetic resonance study shows multiple tumours in both cerebral hemispheres seven months prior.

• Received : August 13, 2012 • Revised : June 26, 2013 • Accepted : January 10, 2014

• Address for reprints : Gilberto Ka Kit Leung, M.D.

Division of Neurosurgery, Department of Surgery, Li Ka Shing Faculty of Medicine, The University of Hong Kong, Queen Mary Hospital, 102 Pokfulam Road, Hong Kong
Tel : +852-2255-3368, Fax : +852-2818-4350, E-mail : gilberto@hkucc.hku.hk

• This is an Open Access article distributed under the terms of the Creative Commons Attribution Non-Commercial License (<http://creativecommons.org/licenses/by-nc/3.0>) which permits unrestricted non-commercial use, distribution, and reproduction in any medium, provided the original work is properly cited.

therefore performed. Intra-operatively, spinal CSF was drained under normal pressure. Her haemodynamics were stable during surgery. The spinal cord was well decompressed after tumour removal. The procedure lasted three hours and 15 minutes. Immediately after surgery, the patient was found to have

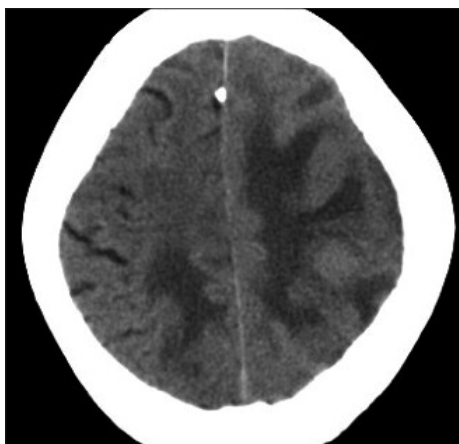


Fig. 2. Pre-operative computerized tomography shows peri-tumoural oedema.

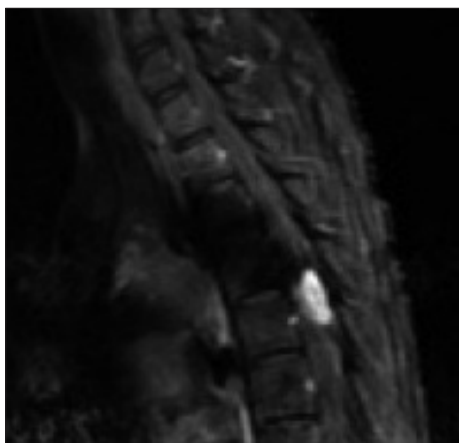

Fig. 3. Contrasted T1-weighted magnetic resonance study shows the spinal metastasis.

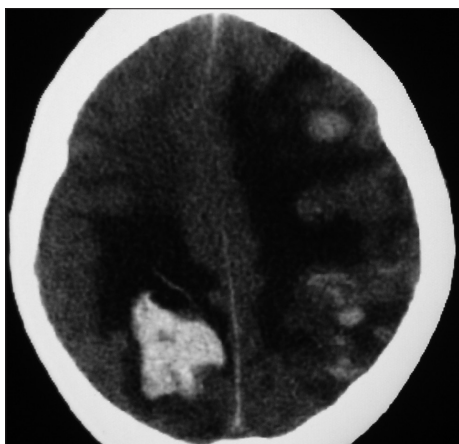


Fig. 4. Post-operative computerized tomography shows multiple haemorrhages around the cerebral metastases.

dilated and non-reactive pupils. CT brain scan showed significant brain swelling and multiple ICHs (Fig. 4). Her family declined further surgery in view of the poor prognosis. She died two days later despite medical therapy. Histological examination of the spinal lesion showed metastatic Ewing's sarcoma. No autopsy was performed.

DISCUSSION

The pathogenesis of intracranial haemorrhage following spine surgery is incompletely understood. It has been suggested that volume depletion of CSF due to intra-operative loss, occult fistulae or lumbar drainage may result in brain sagging and stretching of the bridging veins^{1,6}. The latter may then bleed and cause subdural haemorrhages², or undergo thrombosis and cause cerebral infarction. The cerebellum is the commonest site of parenchymal bleeding after spine surgery due to involvement of the superior cerebellar veins⁵. On the other hand, ICHs due to lumbar CSF loss is uncommon⁹. Thomas et al.⁸ reported a patient with supratentorial and infratentorial ICHs after spine surgery from which the patient made an uneventful recovery.

The majority of reported cases presented during the post-operative period^{3,6}. Our patient developed haemorrhages during surgery. Given the rapid course of events, venous thrombosis was unlikely to be responsible. It was possible that a sudden release of spinal CSF could have caused a surge in cerebral perfusion which then led to tumour bleeding. However, simultaneous haemorrhages from several tumours are unusual. Alternatively, in the presence of supratentorial mass lesions, spinal CSF loss may have resulted in brain herniation and haemorrhagic infarction, similar to what could happen after lumbar puncture. Without autopsy findings, we were unable to ascertain the exact mechanism.

External irradiation should be the most appropriate treatment for spinal metastasis, especially in patients with disseminated malignancy. The indication for laminectomy for our patient was weak. But, because of previous radiotherapy, surgery was the only treatment option for our patient, who was young and very keen on surgery for the relief of her acute neurological symptoms. The issue of whether the presence of intracerebral tumours should have contraindicated intradural spine surgery was debatable. Lesions with no mass effect were probably safe; those in our patient, in retrospect, were not. In retrospect, a ventriculostomy would have facilitated ICP control and prevented the creation of a significant craniospinal pressure gradient. Excessive CSF drainage through the spine should be avoided although a head-down prone position may potentially aggravate intracranial hypertension also in the event of haemorrhages. Fluctuations in systemic blood pressure and arterial carbon dioxide level during anaesthesia should be avoided with careful anaesthetic management. The use of peri-operative steroids, tranexamic acid or mannitol may help to reduce tumour swelling and the risks of bleeding. Surgery for the brain lesions prior

to spinal operation was a possible option although it was probably not appropriate for our patient with very terminal malignancy. The present case illustrates that spine surgery is potentially hazardous when performed in the presence of intracerebral mass lesions. It should not be considered as first-line treatment when other modalities such as radiotherapy is feasible. Should surgery be needed in extreme cases, patient counseling with regards to this rare but significant complication is essential.

CONCLUSION

Intradural spine surgery may be complicated by supratentorial ICH. In patients with disseminated metastatic diseases, preoperative imaging studies should be performed to exclude the presence of intracranial mass lesion. Brain lesions that are causing significant mass effect may be at risk of developing haemorrhages. These should be treated first if possible or considered as a relative contraindication to intradural spine surgery. Radiotherapy remains to be the most appropriate treatment for spinal metastasis, especially in patients with terminal malignancy.

References

1. Cornips EM, Staals J, Stavast A, Rijkers K, van Oostenbrugge RJ : Fatal cerebral and cerebellar hemorrhagic infarction after thoracoscopic microdiscectomy. Case report. *J Neurosurg Spine* 6 : 276-279, 2007
2. Dickerman RD, Morgan J : Acute intracranial subdural hematoma following a lumbar CSF leak caused by spine surgery. *Spine (Phila Pa 1976)* 31 : 1513-1514, 2006
3. Friedman JA, Ecker RD, Piepgras DG, Duke DA : Cerebellar hemorrhage after spinal surgery : report of two cases and literature review. *Neurosurgery* 50 : 1361-1363; discussion 1363-1364, 2002
4. Jung YY, Ju CI, Kim SW : Bilateral subdural hematoma due to an unnoticed dural tear during spine surgery. *J Korean Neurosurg Soc* 47 : 316-318, 2010
5. Karaeminogullari O, Atalay B, Sahin O, Ozalay M, Demirors H, Tuncay C, et al. : Remote cerebellar hemorrhage after a spinal surgery complicated by dural tear : case report and literature review. *Neurosurgery* 57 (1 suppl) : e215; discussion e215, 2005
6. Konya D, Ozgen S, Pamir MN : Cerebellar hemorrhage after spinal surgery : case report and review of the literature. *Eur Spine J* 15 : 95-99, 2006
7. Nowak R, Maliszewski M, Krawczyk L : Intracranial subdural hematoma and pneumocephalus after spinal instrumentation of myelodysplastic scoliosis. *J Pediatr Orthop B* 20 : 41-45, 2011
8. Thomas G, Jayaram H, Cudlip S, Powell M : Supratentorial and infratentorial intraparenchymal hemorrhage secondary to intracranial CSF hypotension following spinal surgery. *Spine (Phila Pa 1976)* 27 : e410-e412, 2002
9. Turkoglu E, Kazanci B, Karavelioglu E, Sanli M, Kazanci B, Sekerci Z : Intracerebral hematoma following lumboperitoneal shunt insertion : a rare case report. *Turk Neurosurg* 21 : 94-96, 2011