



Case report

Neurogenic pulmonary edema combined with febrile seizures in early childhood—A report of two cases



Keiji Tasaka*, Kousaku Matsubara, Masayuki Hori, Hiroyuki Nigami, Aya Iwata, Kenichi Isome, Yu Kawasaki, Sadayuki Nagai

Department of Pediatrics, Nishi-Kobe Medical Center, Kobe, Japan

ARTICLE INFO

Article history:

Received 29 September 2016

Received in revised form 21 October 2016

Accepted 21 October 2016

ABSTRACT

Neurogenic pulmonary edema (NPE) is a clinical entity that can occur following central nervous system disorders. However, NPE occurs quite rarely in early childhood, and there has only been one report about pediatric NPE associated with febrile seizures. Two cases are reported here. One case involved a 2-year-old girl who presented with febrile seizures, which rapidly progressed to severe NPE. Since the NPE occurred in the emergency department room, the patient was able to be resuscitated via immediate endotracheal intubation. The other case involved an 11-month-old boy who developed respiratory distress following a 50-min episode of febrile status epilepticus. Both patients required respiratory management in the intensive care unit. However their conditions were dramatically improved within several days and fully recovered without any sequelae.

© 2016 The Authors. Published by Elsevier Ltd. This is an open access article under the CC BY-NC-ND license (<http://creativecommons.org/licenses/by-nc-nd/4.0/>).

The fulminant development of the respiratory failure is noteworthy in the first patient. If such events had occurred outside the hospital, we might not have been able to resuscitate the patient. The second patient, to the best of our knowledge, is the youngest reported patient to have developed NPE caused by febrile or non-febrile seizures. We successfully managed severe NPE caused by febrile seizures in two infants. These are the second and third such cases ever reported. Although febrile seizures generally have a benign prognosis, clinicians should be aware that NPE can arise as a rare, but potentially fatal, complication of this common childhood disorder.

Introduction

Neurogenic pulmonary edema (NPE) is a clinical syndrome that is characterized by the acute onset of pulmonary edema, occurring in combination with central nervous system (CNS) disorders [1–3]. Even though a majority of patients with NPE exhibit rapid resolution, it has life-threatening potential [4,5]. Thus, the early recognition and appropriate management of NPE are both crucial for achieving good outcomes. In adults, a variety of CNS events, such as head trauma, status epilepticus, stroke, infection,

intracranial hemorrhage, and drug overdose, can cause this syndrome [1–3]. In contrast, NPE occurs less frequently in childhood, and there have been few reports about children that suffered NPE after non-febrile epileptic seizures [5–11]. There has only been one report about NPE caused by febrile seizures [3]. Febrile seizure is one of the most common childhood disorders encountered in emergency departments (ED) [12,13] and is considered to generally exhibit a benign clinical course [12]. However, if respiratory distress due to NPE occurs, febrile seizures might provoke serious adverse outcomes.

We report the cases of two pediatric patients with NPE caused by febrile seizures. These two cases showed that NPE should be recognized as an important, potentially fatal cause of acute respiratory failure following febrile seizures.

Case reports

Case 1

A previously healthy 2 1/2 year old girl presented to the ED after a 4-h history of fever. The patient had suffered a simple febrile seizure at 12 months of age. A physical examination showed pharyngeal redness, and the patient was diagnosed with viral pharyngitis. While waiting in the ED before receiving medication, the patient suffered a generalized convulsion. She was immediately brought to the treatment room. Her vital signs were as follows: body temperature: 40.0 °C, heart rate: 180 beats/min, and

* Corresponding author at: Department of Pediatrics, Nishi-Kobe Medical Center, 5-7-1 Kojidai, Nishi-ku, Kobe 651-2273, Japan.
E-mail address: tasaka_t1126@yahoo.co.jp (K. Tasaka).

percutaneous oxygen saturation (SpO₂): 92%. The patient received 0.4 mg/kg of intravenous diazepam twice, but no response was seen. Two doses of 5 mg/kg thiamylal were then intravenously administered, and the patient's seizures stopped (total duration: 20 min). At this time, she was apneic, her SpO₂ had fallen markedly to 61%, and she displayed bradycardia (60 beats/min). Failure to recover from low SpO₂ and bradycardia with bag-mask ventilation led to the intubation of the patient. Large amounts of a frothy, blood-tinged secretion were discharged from the endotracheal tube. Venous blood gas analysis performed just after intubation showed the following values: pH: 7.12, PCO₂: 63.4 mmHg, HCO₃⁻: 20.6 mmol/L, and base excess: -9.3 mmol/L. About 30 min after intubation, her SpO₂ had returned to over 90%. A plain chest X-ray film showed bilateral diffuse alveolar opacities, and a chest computed tomography (CT) scan demonstrated bilateral infiltrations on the dorsal side of each lung field (Fig. 1). Cranial CT did not show any intracranial hemorrhage or brain edema.

The patient was highly febrile at the time of her transfer to the intensive care unit. A respiratory sound examination detected bilateral coarse crackles over the entire lung field. A neurological examination demonstrated that the patient was comatose and was classified as E1V1M1 according to the Glasgow Coma Scale. The patient's extremities were flaccid and did not exhibit any spontaneous movements, and her pupils were small and bilaterally reactive to light stimuli. Under a tentative diagnosis of encephalopathy of unknown origin, she was managed under pressure-controlled mechanical ventilation and was treated with 30 mg/kg/dose of intravenous methylprednisolone, 10 mg/kg of acyclovir every 8 h, 30 mg/kg of cefotaxime every 8 h, and 10 mg/kg of glycerol, as well as a continuous infusion of midazolam. Laboratory examinations produced the following findings: white blood cell count (WBC): 6100/μL, hemoglobin: 12.1 g/dL, platelet count: 212 × 10³/μL, glucose: 223 mg/dL, lactate dehydrogenase: 255 IU/L, sodium: 134 mmol/L, and potassium: 3.3 mmol/L.

Eight hours later, the patient started to exhibit orientation towards her mother's speech. She was successfully extubated 18 h after the onset of the febrile seizures. Around 24 h after the onset of the febrile seizures, the patient fully recovered consciousness and was able to walk without support. She did not exhibit any further seizure activity after admission. A chest radiograph obtained on the fourth hospital day demonstrated that the infiltrates in the patient's lung fields had disappeared. On the tenth hospital day, she was discharged without any neurological or pulmonary sequelae. Coxsackievirus A4 was isolated from the serum sample obtained on admission, and the results of serological neutralization tests for coxsackievirus A4 increased from <1:8 on admission to 1:1024 4 weeks later, confirming that coxsackievirus A4 was the pathogen responsible for the patient's febrile illness.

Case 2

An 11-month-old boy had been in good health until 2 h before he was brought to the ED, when his family noticed that he had a fever. On the way to his primary physician, the patient suddenly lost consciousness and suffered a generalized tonic-clonic seizure. The patient was transferred to the ED. He had vomited several times.

On arrival, he was actively seizing (total duration: 50 min). The seizures were temporarily stopped via the intravenous administration of 0.3 mg/kg diazepam; however, they intermittently recurred. Thus, an additional diazepam dose of 0.3 mg/kg was administered, followed by a fosphenytoin loading dose of 22.5 mg/kg. Just after the complete cessation of the patient's convulsions, his vital signs were as follows: temperature: 41.0 °C, non-invasive blood pressure: 105/64 mmHg, heart rate:

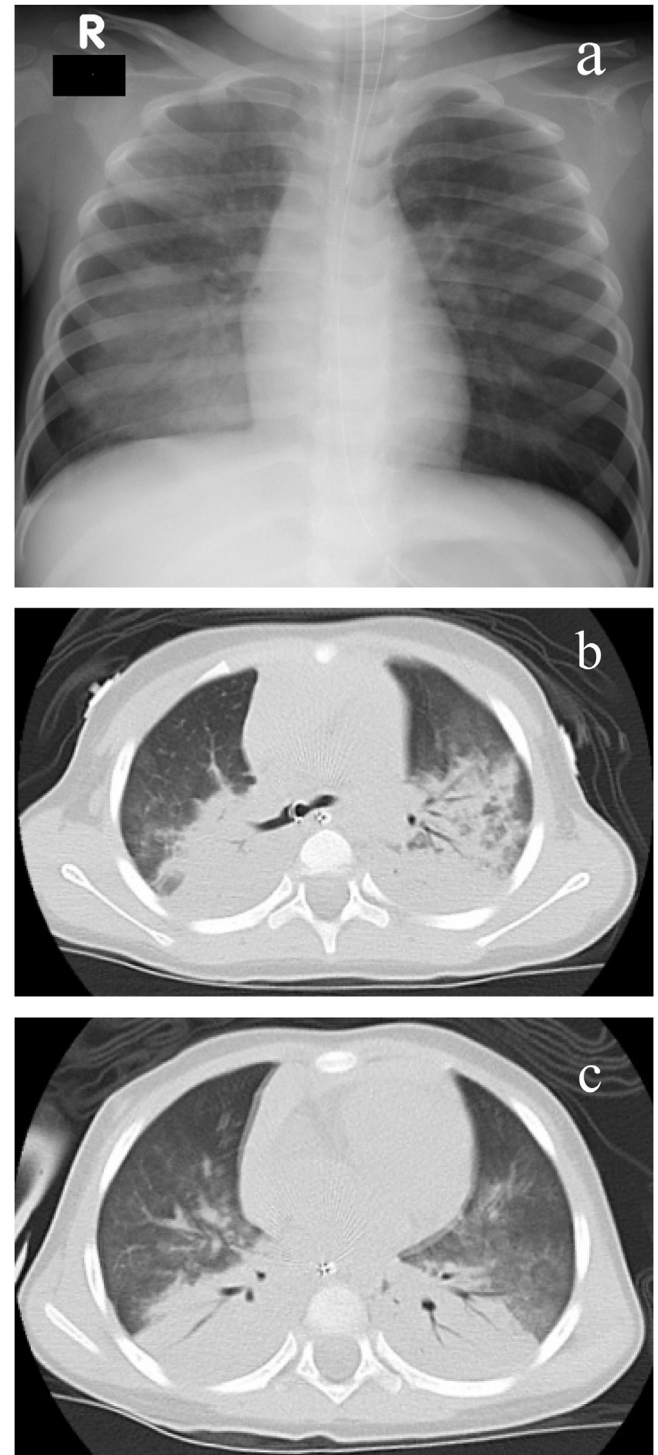


Fig. 1. Imaging findings of case 1.

A chest plain X-ray film (a) and computed tomography scans obtained at the level of the tracheal bifurcation (b) and the lower lung field (c) in case 1. The chest plain X-ray film showed bilateral diffuse alveolar opacities. Chest computed tomography showed diffuse bilateral infiltrates together with an air bronchogram on the dorsal sides of the lung fields.

140 beats/min, and respiratory rate: 50/min with wheezing and effort on breathing. As it was difficult to keep the patient's SpO₂ above 90%, he was given 15L/min oxygen via a reservoir mask. Venous blood gas analysis produced the following results: pH: 6.853, PCO₂: 127 mmHg, HCO₃⁻: 22.0 mmol/L, and base excess: -14.2 mmol/L. In addition, laboratory examinations obtained the

following findings: WBC: 8800/ μ L, hemoglobin: 12.5 g/dL, platelet count: 188×10^3 / μ L, glucose: 192 mg/dl, creatine kinase: 727 IU/L, aspartate aminotransferase: 65 IU/L, alanine aminotransferase: 25 IU/L, lactate dehydrogenase: 382 IU/L, sodium: 135 mmol/L, and potassium: 4.6 mmol/L.

Chest CT showed confluent alveolar consolidations, predominantly in the dorsal regions (Fig. 2). The patient's dyspnea gradually improved over the next 2 h, and a concomitant reduction in his oxygen demand was also observed. The patient was transferred to the intensive care unit, where he was treated with oxygen and 50 mg/kg of sulbactam/ampicillin every 8 h. Twelve hours later, he no longer required supplemental oxygen, and a chest radiograph showed that the patient's bilateral infiltrations had improved significantly. He fully recovered consciousness within 24 h of admission. On the third hospital day, the patient became afebrile and developed blanchable, erythematous macules and papules, primarily on his neck and trunk. He was clinically diagnosed with roseola infantum and was discharged in an excellent condition with no sequelae.

Discussion

We present two cases of infants with NPE caused by febrile seizures. Compared with adult patients, NPE is rarely diagnosed in childhood. Head trauma (including cases caused by abuse) and enterovirus 71 infection, are the disorders that are most commonly associated with pediatric NPE [3,4,14–16]. There have been only 7 reports about pediatric cases of NPE that occurred after non-febrile

epileptic seizures [5–11]. Furthermore, to the best of our knowledge, there has only been one report about pediatric NPE caused by febrile status epilepticus, which involved a 14-month-old child [3]. Thus, our cases are the second and third such cases. The 11-month old infant is the youngest patient to have developed NPE caused by a non-febrile [5–11] or febrile seizure [3] ever reported.

Febrile seizure is one of the most common disorders seen in early childhood [12,13], and it is generally considered to exhibit a benign clinical course [12]. However, both of our patients developed sudden-onset febrile seizures and suffered hypoxemic respiratory failure just after the cessation of their seizures. We successfully resuscitated both patients.

Fortunately, the first patient suffered respiratory failure in the ED and was successfully intubated. After intubation, large amounts of frothy, blood-tinged secretions, typical of pulmonary edema fluid, was suctioned from an endotracheal tube, and we needed to suction this material frequently. If such an event had occurred at home or had not been witnessed, the patient might have died before reaching hospital. Indeed, Terrence and colleagues [5] suggested that NPE is one of the pathophysiological mechanisms of unexpected, unexplained death in epileptic patients. The present cases showed that febrile seizures can cause life-threatening events. NPE might remain underdiagnosed, and hence, be an underreported cause of acute respiratory failure after febrile seizures.

In general, NPE is classified into two distinct clinical forms: an early form that develops within minutes to hours following a neurological injury and a delayed form that develops 12–24 h after a CNS insult [17]. Both of the presented patients were considered to have the early form of NPE, and the first patient should be referred to fulminant form which develops to severe respiratory failure within several minutes.

The mechanism for NPE likely involves increased pulmonary capillary permeability combined with a massive, centrally mediated, sympathetic discharge resulting in elevated pulmonary vascular resistance [1–3,6,7,17–19]. A sudden increase in intracranial pressure can induce overactivation of the sympathetic nervous system, which in turn leads to pulmonary and systemic vasoconstriction in the veins and arteries [1,2]. Transient but marked increases in pulmonary vascular pressure can cause hydrostatic injuries to the capillary endothelium [3]. Furthermore, such sympathetic surges can also directly injure the myocardium and cause changes in cardiopulmonary hemodynamics [3,20]. These hemodynamic mechanisms result in the extravasation of protein-rich fluid into the alveolar space and intra-alveolar hemorrhaging [2,3].

Most of the therapeutic measures used to treat NPE is supportive [1,7,8,19]. The primary management strategy for NPE should be based on controlling the triggering CNS insult [1,2]. When seizures persist, it is important to control them with anticonvulsants to prevent secondary brain functional disorders. In addition, supplemental oxygen should be provided to maintain cerebral oxygen delivery and avoid a worsening of the patient's pulmonary condition [1,2,19]. If a patient's oxygen saturation level remains <90% when they are on supplemental oxygen, positive-pressure ventilation is indicated [7]. Although patients with moderate symptoms can be treated using non-invasive ventilation, patients with severe NPE must be intubated early [1,2,19]. Above all, it is important to recognize the pathologies that can cause NPE at an early stage.

Conclusion

NPE combined with febrile seizures can occur in early childhood and can present in a fulminant form that develops

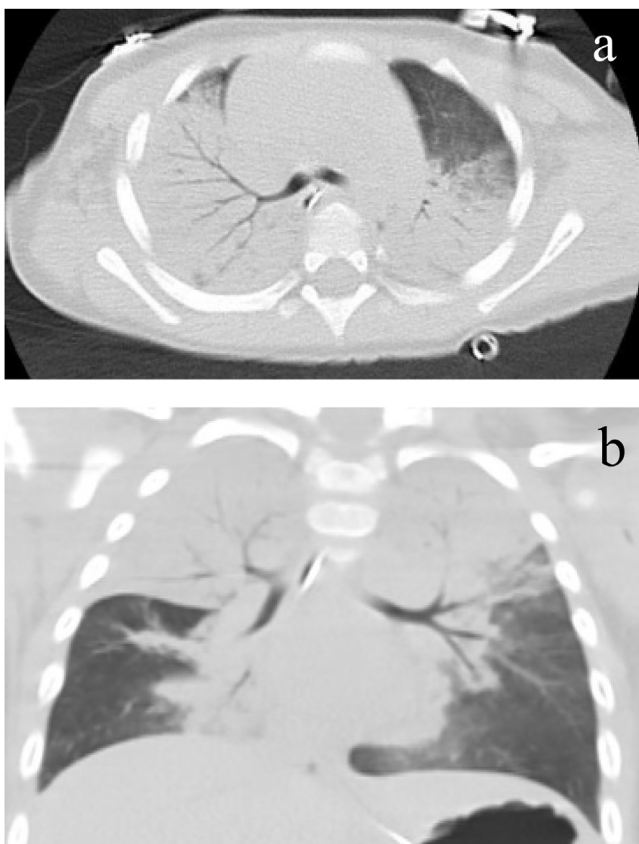


Fig. 2. CT findings of case 2. Horizontal (a) and coronal (b) sections obtained during chest computed tomography in case 2, showing confluent alveolar consolidations, predominantly in the dorsal regions.

within a few minutes. It can be life-threatening if it is not detected early and subjected to intensive care. Marked worsening of the patient's respiratory condition or the development of frothy airway fluid after a prolonged seizure is the crucial signs that are indicative of NPE so it is important to carefully follow-up patients who display these symptoms after seizures for NPE.

Conflict of interest statement

No conflict of interest to declare.

References

- [1] Fontes RB, Aguiar PH, Zanetti MV, Andrade F, Mandel M, Teixeira MJ. Acute neurogenic pulmonary edema: case reports and literature review. *J Neurosurg Anesthesiol* 2003;15:144–50.
- [2] Baumann A, Audibert G, McDonnell J, Mertes PM. Neurogenic pulmonary edema. *Acta Anaesthesiol Scand* 2007;51:447–55.
- [3] Nguyen TT, Hussain E, Grimason M, Goldstein J, Wainwright MS. Neurogenic pulmonary edema and acute respiratory distress syndrome in a healthy child with febrile status epilepticus. *J Child Neurol* 2013;28:1287–91.
- [4] Ooi MH, Wong SC, Lewthwaite P, Cardosa MJ, Solomon T. Clinical features, diagnosis, and management of enterovirus 71. *Lancet Neurol* 2010;9:1097–105.
- [5] Terrence CF, Rao GR, Perper JA. Neurogenic pulmonary edema in unexpected, unexplained death of epileptic patients. *Ann Neurol* 1981;9:458–64.
- [6] Mulroy JJ, Mickell JJ, Tong TK, Pellock JM. Postictal pulmonary edema in children. *Neurology* 1985;35:403–5.
- [7] Reuter-Rice K, Duthie S, Hamrick J. Neurogenic pulmonary edema associated with pediatric status epilepticus. *Pediatr Emerg Care* 2011;27:957–8.
- [8] Pender ES, Pollack Jr. CV. Neurogenic pulmonary edema: case reports and review. *J Emerg Med* 1992;10:45–51.
- [9] Wasowska-Królikowska K, Krogulska A, Modzelewska-Hołyńska M. Neurogenic pulmonary oedema in a 13-year-old boy in the course of symptomatic epilepsy—case report. *Med Sci Monit* 2000;6:1003–7.
- [10] Bonbrest HC. Pulmonary edema following an epileptic seizure. *Am Rev Respir Dis* 1965;91:97–100.
- [11] Meyer S, Lindinger A, Löffler G, Limbach HG, Shamdeen MG, Gottschling S, et al. Mechanisms of disease/hypothesis: neurogenic left ventricular dysfunction and neurogenic pulmonary oedema. *Wien Med Wochenschr* 2009;159:342–5.
- [12] Patel N, Ram D, Swiderska N, Mewasingh LD, Newton RW, Offringa M. Febrile seizures. *BMJ* 2015;351:h4240.
- [13] American Academy of Pediatrics. Provisional committee on quality improvement, subcommittee on febrile seizure. Clinical practice guideline—febrile seizures: guideline for the neurodiagnostic evaluation of the child with a simple febrile seizure. *Pediatrics* 2011;127:389–94.
- [14] Rubin DM, McMillan CO, Helfaer MA, Christian CW. Pulmonary edema associated with child abuse: case reports and review of the literature. *Pediatrics* 2001;108:769–75.
- [15] Milley JR, Nugent SK, Rogers MC. Neurogenic pulmonary edema in childhood. *J Pediatr* 1979;94:706–9.
- [16] Wang SM, Liu CC, Tseng HW, Wang JR, Huang CC, Chen YJ. Clinical spectrum of enterovirus 71 infection in children in southern Taiwan, with an emphasis on neurological complications. *Clin Infect Dis* 1999;29:184–90.
- [17] Busl KM, Bleck TP. Neurogenic pulmonary edema. *Crit Care Med* 2015;43:1710–5.
- [18] Colice GL, Matthay MA, Bass E, Matthay RA. Neurogenic pulmonary edema. *Am Rev Respir Dis* 1984;130:941–8.
- [19] Uejima T. General pediatric emergencies: acute pulmonary edema. *Anesthesiol Clin North Am* 2001;19:383–9.
- [20] Bahloul M, Chaari AN, Kallel H, Khabir A, Ayadi A, Charfeddine H. Neurogenic pulmonary edema due to traumatic brain injury: evidence of cardiac dysfunction. *Am J Crit Care* 2006;15:462–70.