

Diagnostic accuracy of pediatric atypical appendicitis

Three case reports

Zhi-hua Wang, MD^{a,*}, Jing Ye, BD^{a,b}, Yu-shui Wang, BD^a, Yan Liu, MD^a

Abstract

Rationale: Acute appendicitis is one of the most common causes of acute abdomen in children, yet it is difficult to diagnose in young children because its clinical manifestations may be atypical. Here, 3 atypical clinical cases associated with appendicitis in children are reported.

Patient concern: The 1st case corresponds to a 5-year-old male patient who presented with abdominal discomfort, intermittent fevers, and vomiting, have increased white blood cell (WBC) count and C-reactive protein (CRP). The second case is a 7-year-old male patient who began with intermittent fevers and lower quadrant abdominal pain, showing increased WBC count and CRP. The 3rd case corresponds to a 7-year-old female patient who presented with intermittent fevers, abdominal pain, and forebreast discomfort, demonstrating increased WBC count and CRP.

Diagnoses: Abdominal computed tomography (CT) scan presented data suggestive of enlarged appendix in diameter, and stercolith, corroborated through surgery.

Intervention: Two patients were treated by appendectomy, and 1 patient was treated conservatively with antibiotics.

Outcomes: Three patients were treated successfully. At 3-month follow-up, the patients had no complaints of discomfort with no relapse of appendicitis.

Lessons: Due to atypical symptoms of children, the diagnosis of appendicitis is often delayed, suggesting that the clinicians should be aware of this disease when encountering gastroenteritis patients with elevated WBC and CRP. Furthermore, abdominal CT scan should be taken into consideration when patients showed high level of WBC and CRP, whose appendix is not seen on ultrasound.

Abbreviations: CRP = C-reactive protein, CT = computed tomography, US = ultrasound, WBC = white blood cell.

Keywords: accuracy, appendicitis, atypical, children

1. Introduction

Acute appendicitis is one of the most common cause of acute abdomen in children, yet it can be difficult to differentiate from causes of acute abdomen. Morbidity in children is high, with an

overall frequency of appendix perforation of 12.5% to 30%.^[1] An accurate and early diagnosis of acute appendicitis is important to avoid both severe outcome and unnecessary surgery. However, to date, the diagnosis remains challenging because clinical signs, symptoms, and instrumental data can be nonspecific and unreliable especially in younger children.^[2] Here, we report 3 atypical cases to enhance awareness for the early diagnosis of acute appendicitis in children.

Editor: N/A.

Study designing and writing of the paper was done by ZW.

Case collection was done by JY, YW and YL.

Written informed consent was obtained from the patient's parents for publication of the case report and any accompanying images.

No financial assistance was received in support of the study.

The authors declared no potential conflicts of interest with respect to the research, authorship, and/or publication of this article.

^a Department of Pediatrics, Integrated Traditional Chinese and Western Medicine, Tianjin Nankai Hospital, ^b Department of Pediatrics, The Second Hospital Affiliated to Tianjin Medical University, Tianjin, China.

* Correspondence: Zhi-hua Wang, Department of Pediatrics, Integrated Traditional Chinese and Western Medicine, Tianjin Nankai Hospital, Tianjin, China. Nankai Sanwei Road, Tianjin 300100, China (e-mail: wzc927@126.com).

Copyright © 2019 the Author(s). Published by Wolters Kluwer Health, Inc. This is an open access article distributed under the terms of the Creative Commons Attribution-Non Commercial License 4.0 (CCBY-NC), where it is permissible to download, share, remix, transform, and buildup the work provided it is properly cited. The work cannot be used commercially without permission from the journal.

Medicine (2019) 98:13(e15006)

Received: 17 October 2018 / Received in final form: 14 February 2019 /

Accepted: 6 March 2019

<http://dx.doi.org/10.1097/MD.00000000000015006>

2. Case reports

2.1. Case 1

The case is a male patient of 5 years old, who presented abdominal, intermittent fevers, and vomiting. The mother reported non-bilious, non-bloody emesis before presentation. There was no diarrhea, melena, changes in bowel habits, rashes, or toxic ingestions reported. She denied sick contacts and recent travel history.

On initial physical examination, the patient presented periumbilical tenderness, and did not have any abnormal findings in the right lower quadrant abdomen. Vital signs were as follows: heart rate: 142 beats/min; respiratory rate: 24 breaths/min; blood pressure: 85/50 mm Hg; and body temperature: 38.3°C. He had dry mucous membranes but peripheral extremities were warm. All other initial examination findings were benign, including urinalysis and stool guaiac testing. Laboratory examination showed white blood cell (WBC) count $17.35 \times 10^9/L$ with a differential of 86.15% neutrophils, 10.1%

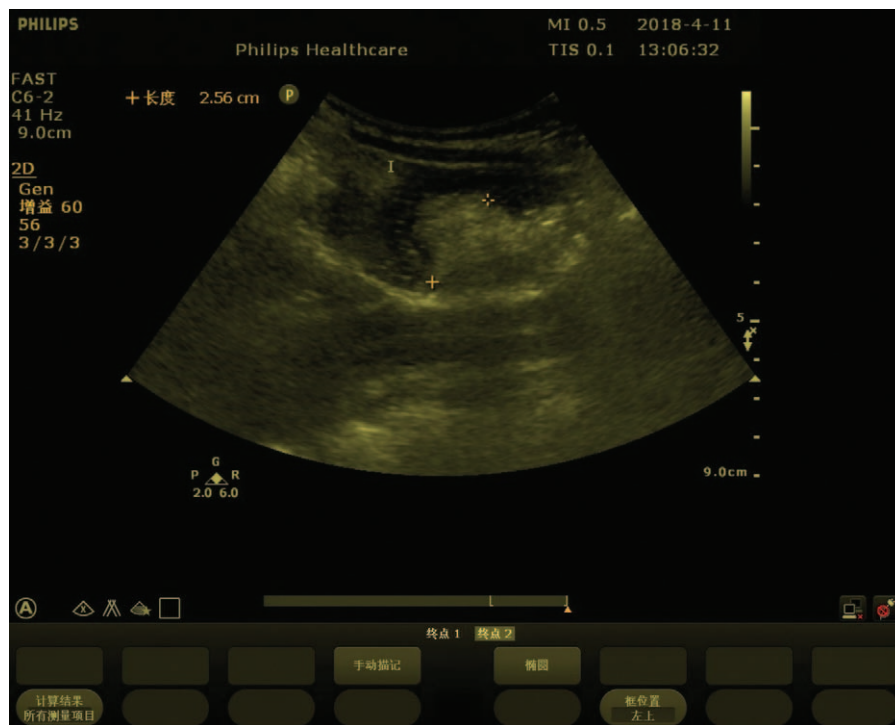


Figure 1. Abdominal ultrasound on the 12 h of admission, demonstrating a 2.56 cm thickness in mesentery of the right quadrant.

lymphocytes, and C-reactive protein (CRP) 71.6 mg/L (reference range <8 mg/L). Other routine test results, including blood glucose, renal function, liver enzymes, and electrolytes were within normal reference range. Abdominal ultrasound (US) was unremarkable. Based on these evidences, the patient was immediately given antibiotics and intravenous fluid. After 12 hours following treatment initiation, the patient's abdominal pain persisted overnight. In order to avoid radiation exposure of computed tomography (CT), the patient underwent another abdominal US. The US revealed a 2.56 cm thickness in mesentery of the right quadrant (Fig. 1), and a 0.94 cm deep right iliac fossa (Fig. 2). At the same time, abdominal X-ray was also performed, showing air-fluid level or gas deposition on the right lower quadrant (Fig. 3). Because the patient was suspicious of the acute abdomen, he was immediately transferred into another pediatric surgery department of hospital. He underwent abdominal CT scan at once, which showed increased appendix diameter and periappendiceal free fluid. In view of the diagnosis of acute appendicitis, the patient underwent appendectomy. The patient recovered well after surgery. The clinical data were shown in Table 1.

2.2. Case 2

The 2nd patient is a boy of 7 years old, who was referred to our emergency department because of intermittent fevers and lower quadrant abdominal pain. He was suffering from vomiting, without bilious and bloody emesis. The patient was treated with intravenous fluid at another the third level hospital; however, his symptoms were not be alleviated. There was no diarrhea, changes in bowel habits, rashes, or toxic ingestions reported. On physical examination revealed mild tenderness in the lower abdomen, but no rebound tenderness and muscular guarding. The patient did not have any abnormal findings in the right lower quadrant

abdomen. Vital signs at admission were as follows: heart rate: 112 beats/min; respiratory rate: 20 breaths/min; blood pressure: 95/65 mm Hg; and body temperature: 37.8°C. The peripheral extremities were warm. Stool testing was also unremarkable. Whereas urinalysis showed red blood cell count 2+, white blood count 1-2, and occult blood 2+ under high power microscope. Abdominal US showed unremarkable.

Laboratory testing revealed WBC, $17.9 \times 10^9/L$ with a differential of 73.2% neutrophils, 14.7% lymphocytes, and CRP 114.9 mg/L (reference range <8 mg/L). Other routine test results, including blood glucose level, renal function, liver enzymes, and electrolytes were within normal reference ranges. In view of the above, the patient underwent abdominal CT scan. The CT showed data suggestive of acute appendicitis, and appendicolith up to 2 cm (Fig. 4). Considering the diagnosis of acute appendicitis, an emergency surgery was performed. The appendix was enlarged, inflamed, and perforated. Appendectomy and abdominal drainage were performed. The patient recovered well in the postoperative period. The clinical data were shown in Table 1.

2.3. Case 3

Case 3 is a female of 7 years old. She was admitted in the hospital for presenting intermittent fevers, abdominal pain, and forebreast discomfort. There was no vomiting, diarrhea, melena, changes in bowel habits, rashes, or toxic ingestions reported. Parents denied sick contacts and recent travel history. History and family anamnesis were unremarkable.

Physical examination revealed mild periumbilical tenderness, but no rebound tenderness and muscular guarding. The patient did not have any abnormal findings in the right lower quadrant abdomen. Vital signs at admission were as follows: heart rate: 104 beats/min; respiratory rate: 22 breaths/min; blood pressure:

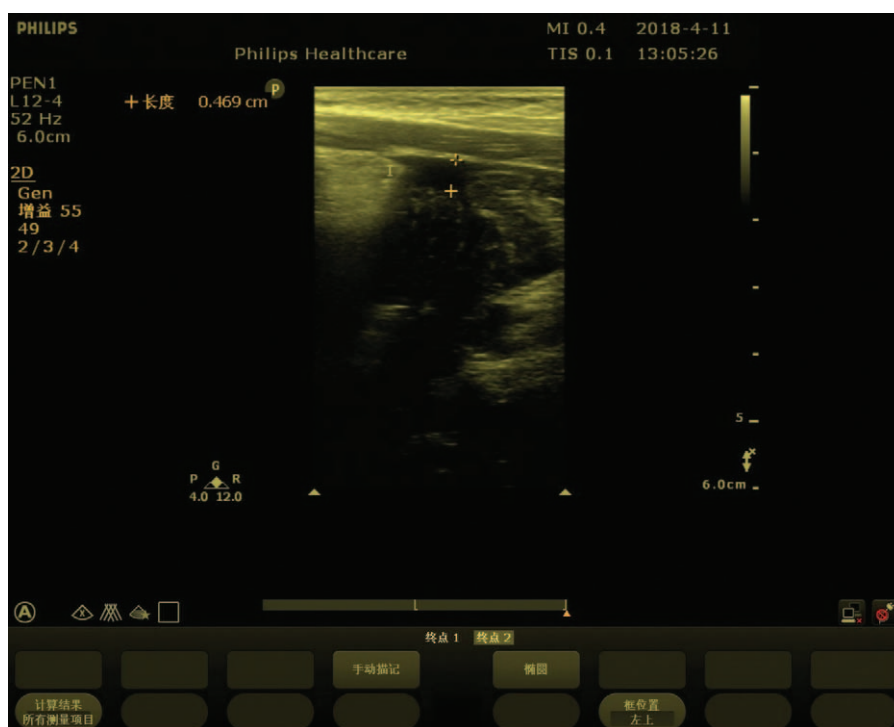

Figure 2. Abdominal ultrasound on the 12h of admission, demonstrating a 0.94 cm deep right iliac fossa.

95/65 mm Hg; and body temperature: 37.7°C. All other initial examination findings were benign. Laboratory testing revealed WBC, $22.63 \times 10^9/L$ with a differential of 86.5% neutrophils, 9.3% lymphocytes, and increased levels of CRP at 146.9 mg/L (reference range <8 mg/L). Other routine test results, including blood glucose, renal function, liver enzymes, electrolytes, lactate dehydrogenase, and troponin were within normal reference ranges. Urinalysis, stool testing, and cardiogram were also unremarkable. US of abdomen showed unremarkable. Abdominal CT scan was performed on account of physical examination and laboratory data, indicating enlarged appendix in diameter

without intraluminal stones (Fig. 5). Because the girl was diagnosed with appendicitis, an emergency surgery should be performed. However, the patient and her parents strongly refused to undergo operative treatment. The patient's symptoms gradually improved on the second day after she was given antibiotics. On the 7th day of hospitalization, the patient was discharged in an asymptomatic condition. She was followed up after discharge without any symptoms, and appendicitis has not recurred yet. The clinical data were shown in Table 1.

3. Discussion

Acute appendicitis in children is the most common condition requiring urgent abdominal surgery, and early diagnosis is critical in preventing perforation, abscess formation and postoperative complications.^[3] However, the diagnosis of this condition is challenging. Patients with gastroenteritis may have abdominal pain accompanied by nausea, vomiting, diarrhea, or fever. Moreover, children are less cooperative with physical examination. These make the diagnosis more difficult. Similarly, our patient's presentation was nonspecific symptoms, all the patients did not have any abnormal findings in the right lower quadrant abdomen, Furthermore, 2 patients suffered from perforated appendicitis. It further proved that appendicitis in children presented atypically and perforation can be a possible complication. Therefore, physicians must realize that the signs and symptoms of appendicitis change during the physiological course of the disease.

History and physical examination alone has a low sensitivity and specificity, so imaging may play a key role in the accurate and prompt diagnosis of suspected appendicitis. Ultrasonography has become the preferred imaging option in the assessment of children with abdominal pain.^[4] It is noninvasive, does not involve radiation, can be carried out repeatedly with minimal

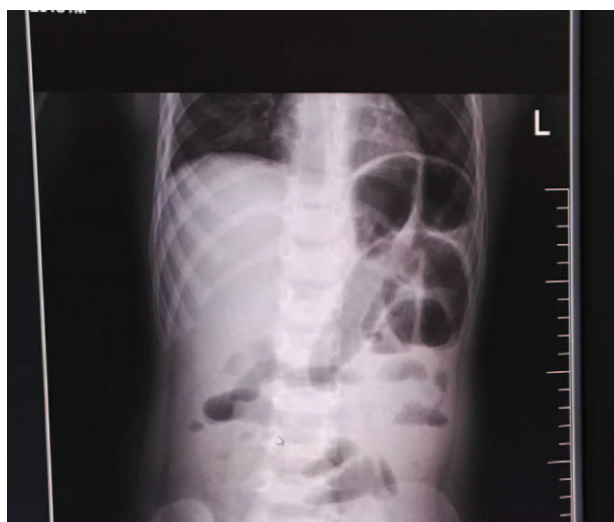

Figure 3. Abdominal X-ray showing air-fluid level or gas deposition on the right lower quadrant abdomen.

Table 1**The clinical characteristics of atypical appendicitis.**

Case	Age, yr	Gender	BMI, kg/m ²	Day of pain, d	Symptoms	Location of abdominal pain	WBC($\times 10^9/L$)	N (%)	L (%)	CRP, mg/L
1	5	Male	14.4	1	Abdominal discomfort, fever, vomiting	Perichilum	17.35	86.1	10.1	71.63
2	7	Male	17.6	3	Abdominal pain, fever, vomiting	Lower abdomen	17.9	73.2	14.7	114.89
3	7	Female	17.5	1	Fever, abdominal pain, forebreast discomfort	Perichilum	22.63	86.1	9.3	146.93

BMI=body mass index, CRP=C-reactive protein, L=lymphocytes, N=neutrophils, WBC=white blood cell.

harm to the patient. However, it has its limitations: accuracy depends on the technical skills of the radiologist, and body habitus of the patients can affect imaging results.^[5,6] In particular, it is difficult to decide how to interpret a study when the appendix cannot be visualized accurately.

A meta-analysis of diagnostic performance of CT mainly in adults or adolescents demonstrated superior sensitivity (91%) and specificity (90%) for appendicitis compared to US (78%, 83%, respectively).^[7] Therefore CT has been advocated for the routine assessment of abdominal pain because it demonstrates high sensitivity and high specificity in the diagnosis of appendicitis. However, CT scan is associated with high levels of radiation. Some studies report that 20% to 40% of CT scan performed in children for the investigation of abdominal pain revealed no intra-abdominal pathology owing to the risks of radiation exposure.^[8,9] Cases where the appendix cannot be visualized but clinical suspicion remains, present a diagnostic dilemma for the physician. In our study, the appendix was not seen on US in 3 cases, which may be related to body habitus. Two patients belonged to overweight according to body mass index.^[10] However, the performed CT indicated enlarged appendix and stercolith. Therefore CT examination should be performed in children with suspected appendicitis especially for children with overweight or obesity, otherwise it will be misdiagnosed.

In addition, diagnostic scoring systems have been developed in an attempt to improve the diagnostic accuracy of acute appendicitis. The most prominent of those scores is that developed by Alvarado.^[11] The modified Alvarado score is a more simplified and practical version of the original one and has been widely accepted after it was successfully tested in different studies.^[12] However, prospective studies have suggested that diagnostic scoring systems alone are inadequate as a diagnostic test for appendicitis. It has been reported that the increased levels of WBC and CRP were helpful in the diagnosis of acute appendicitis.^[13–15] Malia et al^[16] reported that in the cases where the appendix is not seen on the US, the strongest predictors of appendicitis include 1 or more of these findings: inflammatory changes, increase in WBC or CRP, and <3 days duration of abdominal pain. When 1 or more of these findings was present, then the suspicion for appendicitis should increase. However, when all elements are absent the likelihood of appendicitis is decreased. In our study, all patients had increased WBC and CRP, days of abdominal pain ≤ 3 days, which was in accord with the report.^[16] There are limitations in this case study. First, there are only 3 cases of appendicitis. Additionally, for patients who underwent appendectomy, surgical pathology reports were not obtained to confirm the appendicitis type.

In conclusions, due to atypical symptoms of children, the diagnosis of appendicitis is often delayed, suggesting that the

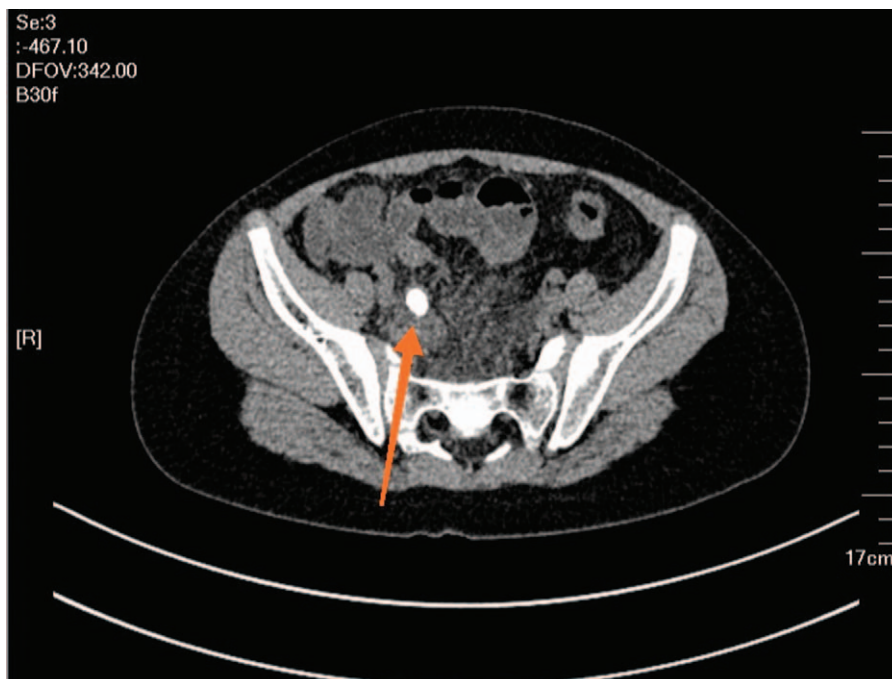


Figure 4. Abdominal computed tomography demonstrating appendicolith up to 2 cm.

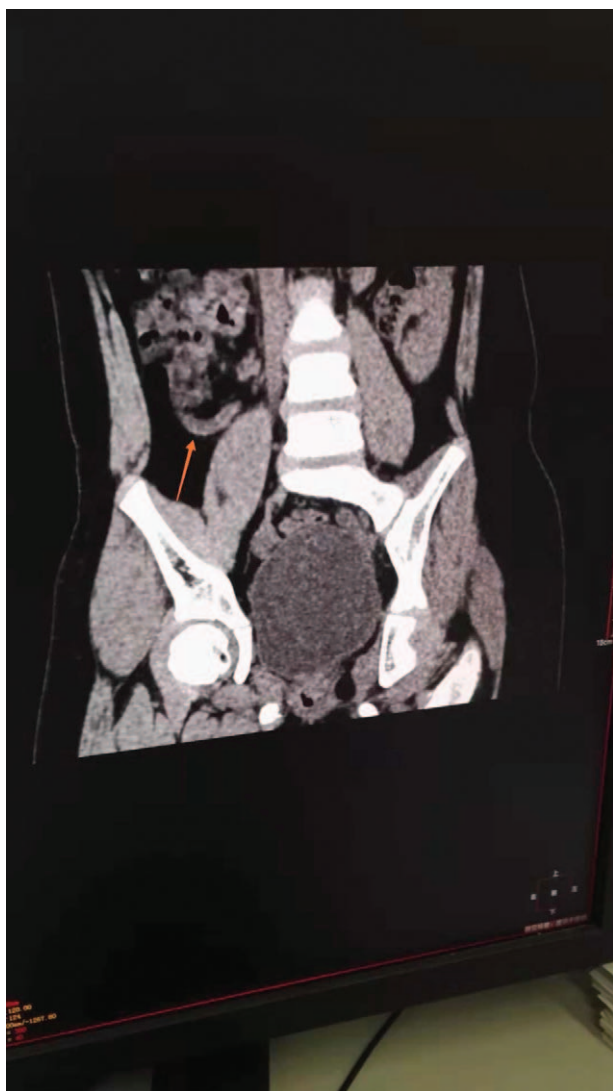


Figure 5. Abdominal computed tomography demonstrating enlarged appendix in diameter.

clinicians should be aware of this disease when encountering gastroenteritis patients with elevated WBC and CRP. Furthermore, abdominal CT scan should be taken into consideration when patients showed high level of WBC and CRP, whose appendix is not seen on US.

Author contributions

Conceptualization: Zhi-hua Wang.
Data curation: Yan Liu.
Investigation: Jing Ye.
Supervision: Yu-shui Wang
Validation: Jing Ye, and Yan Liu.
Writing – original draft: Zhi-hua Wang.
Writing – review and editing: Zhi-hua Wang.

References

- [1] Kulik DM, Uleryk EM, Maguire JL. Does this child have appendicitis? A systematic review of clinical prediction rules for children with acute abdominal pain. *J Clin Epidemiol* 2013;66:95–104.
- [2] Marzuillo P, Germani C, Krauss BS, et al. Appendicitis in children less than five years old: a challenge for the general practitioner. *World J Clin Pediatr* 2015;8:19–24.
- [3] Rothrock SG, Pagane J. Acute appendicitis in children: emergency department diagnosis and management. *Ann Emerg Med* 2000;36:39–51.
- [4] Doria AS, Moineddin R, Kellenberger CJ, et al. US or CT for diagnosis of appendicitis in children and adults? A meta-analysis. *Radiology* 2006;241:83–94.
- [5] Schuh S, Man C, Cheng A, et al. Predictors of non-diagnostic ultrasound scanning in children with suspected appendicitis. *J Pediatr* 2011;158:112–8.
- [6] Coursey CA, Nelson RC, Patel MB, et al. Making the diagnosis of acute appendicitis: do more preoperative CT scans mean fewer negative appendectomies? A 10-year study. *Radiology* 2010;254:460–8.
- [7] Van Randen A, Bipat S, Zwinderman AH, et al. Acute appendicitis: meta-analysis of diagnostic performance of CT and graded compression US related to prevalence of disease. *Radiology* 2008;249:97–106.
- [8] Modahl L, Digumarthy SR, Rhea JT, et al. Emergency department abdominal computed tomography for nontraumatic abdominal pain: optimizing utilization. *J Am Coll Radiol* 2006;3:860–6.
- [9] Miano DI, Silvis RM, Popp JM, et al. Abdominal CT does not improve outcome for children with suspected acute appendicitis. *West J Emerg Med* 2015;16:974–82.
- [10] Li H, Ji CY, Zong XN, et al. Body mass index growth curves for Chinese children and adolescents aged 0 to 18 years. *Chin J Pediatr* 2009;47:493–8.
- [11] Alvarado A. A practical score for the early diagnosis of acute appendicitis. *Ann Emerg Med* 1986;15:557–64.
- [12] Macklin CP, Radcliffe GS, Merei JM, et al. A prospective evaluation of the modified Alvarado score for acute appendicitis in children. *Ann R Coll Surg Engl* 1997;3:203–5.
- [13] Panagiotopoulou IG, Parashar D, Lin R, et al. The diagnostic value of white cell count C-reactive protein and bilirubin in acute appendicitis and its complications. *Ann R Coll Surg Engl* 2013;95:215–21.
- [14] Poudel R, Bhandari TR. Risk factors for complications in acute appendicitis among paediatric population. *JNMA J Nepal Med Assoc* 2017;56:145–8.
- [15] Msolli MA, Beltaief K, Bouida W, et al. Value of early change of serum C reactive protein combined to modified Alvarado score in the diagnosis of acute appendicitis. *BMC Emerg Med* 2018;18:15–20.
- [16] Malia L, Sturm JJ, Smith SR, et al. Diagnostic accuracy of laboratory and ultrasound findings in patients with a non-visualized appendix. *Am J Emerg Med* 2018; Aug 7. pii: S0735-6757(18)30650-8.