



BRAZILIAN JOURNAL
OF MEDICAL AND BIOLOGICAL RESEARCH

www.bjournal.com.br

ISSN 1414-431X
Volume 45 (12) 1102-1340 December 2012

**BIOMEDICAL SCIENCES
AND
CLINICAL INVESTIGATION**

Braz J Med Biol Res, December 2012, Volume 45(12) 1315-1319

doi: 10.1590/S0100-879X2012007500150

Oculo-facio-cardio-dental syndrome in three succeeding generations: genotypic data and phenotypic features

B. Lozić, J. Ljubković, D. Gabrić Pandurić, I. Saltvig, K. Kutsche, V. Krželj and T. Zemunik

The Brazilian Journal of Medical and Biological Research is partially financed by



Ministério da Ciência e Tecnologia



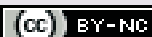Ministério da Educação



Institutional Sponsors



Explore High - Performance MS Orbitrap Technology In Proteomics & Metabolomics



All the contents of this journal, except where otherwise noted, is licensed under a [Creative Commons Attribution License](https://creativecommons.org/licenses/by-nc/4.0/)

Oculo-facio-cardio-dental syndrome in three succeeding generations: genotypic data and phenotypic features

B. Lozić¹, J. Ljubković², D. Gabrić Pandurić³, I. Saltvig⁴, K. Kutsche⁵,
V. Krželj¹ and T. Zemunik⁶

¹Department of Pediatrics, University Hospital Split, Split, Croatia

²Department of Pathology, Forensic Medicine and Cytology, University Hospital Split, Split, Croatia

³Department of Oral Surgery, School of Dental Medicine, University of Zagreb, Zagreb, Croatia

⁴Jessenius Faculty of Medicine of Comenius, University in Bratislava, Martin, Slovakia

⁵Institute of Human Genetics, University Medical Center Hamburg-Eppendorf, Hamburg, Germany

⁶Department of Medical Biology, School of Medicine, University of Split, Split, Croatia

Abstract

Oculo-facio-cardio-dental (OFCD) syndrome is a rare X-linked disorder mainly manifesting in females. Patients show ocular, facial, cardiac, and dental abnormalities. OFCD syndrome is caused by heterozygous mutations in the *BCOR* gene, located in Xp11.4, encoding the BCL6 co-repressor. We report a Croatian family with four female members (grandmother, mother and monozygotic female twins) diagnosed with OFCD syndrome who carry the novel *BCOR* mutation c.4438C>T (p.R1480*). They present high intrafamilial phenotypic variability with special regard to cardiac defect and cataract that showed more severe disease expression in successive generations. Clinical and radiographic examination of the mother of the twins revealed a talon cusp involving the permanent maxillary right central incisor. This is the first known report of a talon cusp in OFCD syndrome with a novel mutation in the *BCOR* gene.

Key words: OFCD syndrome; *BCOR* gene; Talon cusp; Intrafamilial phenotypic variability

Introduction

Oculo-facio-cardio-dental (OFCD) syndrome is characterized by ocular defects (congenital cataract, microphthalmia, secondary glaucoma), facial anomalies (long and narrow face, high nasal bridge, septate nasal cartilage, cleft palate), congenital cardiac defects [atrial septal defect (ASD), ventricular septal defect (VSD), floppy mitral valve], and dental irregularities (canine radiculomegaly, hypodontia, delayed permanent dentition) (1). It is an X-linked disorder manifesting mainly in females. Several incidences with mother-to-daughter transmission have been described, and females with OFCD syndrome show a completely skewed pattern of X-chromosome inactivation (2,3).

Genetic studies have led to the identification of heterozygous mutations in the *BCOR* gene, encoding the BCL6 co-repressor, in patients affected by OFCD (4). The mutation spectrum comprises nonsense, frameshift and splicing mutations, supporting the hypothesis that OFCD

syndrome is caused by heterozygous *BCOR* null alleles (1,4,5). Usually dentists are the first clinicians who notice characteristic manifestations of this disorder. The most consistent dental finding is radiculomegaly; the roots of the maxillary incisors and canines can continue to grow until they reach the cortical plate of the orbit or the lower border of the mandible, usually with widely open apices (6,7). Oligodontia, delayed eruption of the dentition, retained primary teeth, malocclusion, root dilacerations, macrodontia, fusion of teeth, hyperdontia, variable root length, and enamel defects are other dental findings that have been reported in OFCD syndrome (6,7).

Talon cusp or dens evaginatus is a very rare dental anomaly of unclear etiology and significance. W.H. Mitchell was the first who described this morphological anomaly in 1892 (8). It was named a talon cusp by Mellor and Ripa (9) due to its resemblance to an eagle's talon. The most

Correspondence: T. Zemunik, Department of Medical Biology, School of Medicine, University of Split, Šoltanska 2, 21000 Split, Croatia. Fax: +385-21-557-895. E-mail: tzemunik@mefst.hr

Received May 19, 2012. Accepted September 10, 2012. Available online September 21, 2012. Published December 17, 2012.

commonly affected teeth are maxillary incisors. It can occur as an isolated finding or be associated with other dental anomalies or some syndromes such as Mohr syndrome (oro-facial-digital II), Sturge-Weber syndrome (encephalotrigeminal angiomas), Rubinstein-Taybi syndrome, incontinentia pigmenti achromians, Ellis-van-Creveld syndrome, hypomelanosis of Ito, cleft lip and palate, and Alagille syndrome (10).

We report a family with 4 affected female patients in three generations, demonstrating vertical transmission of OFCD syndrome. The novel *BCOR* nonsense mutation c.4438C>T (p.R1480*) was identified in the monozygotic twins, their mother and maternal grandmother in the heterozygous state. We performed careful phenotypic analysis in all patients with special emphasis on discordant phenotypes in monozygotic female twins and describe a unique case of a maxillary talon cusp associated with OFCD syndrome.

Patients and Methods

Ethical approval

Clinical data and samples were obtained from the participating family members with informed consent, including consent to use photographs in this report. Genotyping protocols were approved by the University Medical Center Hamburg-Eppendorf Ethics Committee.

Case report

Monozygotic female twins (twin 1 and twin 2) were conceived after *in vitro* fertilization. Two embryos were transferred; one of them survived and divided to produce monozygotic twins. The twins were born at 32/33 weeks of gestation by cesarean section.

Birth weight of twin 1 was 1540 g (10-25th centile) and length was 42 cm (10-25th centile). During clinical examination, she was noted to have long philtrum, mildly broad nasal tip, asymmetric size of eyes, downward eyebrows, and congenital cataract of both eyes. Cataract surgery completely removed a cloudy lens of the eye because of inability of light penetration at the age of 4 months (Figure 1). She had additional anomalies: umbilical hernia, camptodactyly of 2nd and 3rd toes of the right foot, and echocardiography revealed ASD. Patients with ASD are usually asymptomatic in infancy and childhood. However, in

our patient, the defect was getting larger with appearance of moderate pulmonary hypertension followed by dyspnea and growth failure. Therefore, surgical closure of ASD at the age of 8 months was successfully performed to prevent development of Eisenmenger syndrome (Table 1).

Twin 2 was more severely affected than her twin sister at newborn age. Her birth weight was 1660 g (10-25th percentile) and length was 41 cm (10-25th percentile). She had dolichocephaly, long face, bilateral microphthalmia, bilateral cataract with completely cloudy lens, ptosis and downward eyebrows, long philtrum, mildly broad nasal tip, cleft dental ridge in midline, high palate, partial syndactyly of 2nd and 3rd toes on the left side, and broad hallux on both sides (Figure 1). Internal examinations showed congenital heart defect with ASD and VSD that were asymptomatic. Cardiologic assessment showed that cardiac defects tended to close spontaneously over time as the child grew. At the age of 7 months the cataracts were surgically removed and

Table 1. Clinical features of family members with OFCD syndrome.

Clinical findings	Twin 1 (1 year old)	Twin 2 (1 year old)	Mother (32 years old)	Grandmother (53 years old)
Ocular				
Congenital cataract	+ / CC	+ / CC	+ / IC	+ / IC
Microphthalmia	-	+	-	-
Ptosis	-	+	+	-
Coloboma of the iris	-	-	+	-
Nystagmus	-	-	+	-
Facial				
Broad nasal tip	+	+	-	+
Long philtrum	+	+	+	+
Long face	-	+	+	+
Downward eyebrows	+	+	-	-
Cleft dental ridge	-	+	-	-
High palate	-	+	+	+
Cardiac				
ASD/VSD	+	+	-	-
Skeletal				
Camptodactyly of toes 2-3	+	-	+	-
Syndactyly of toes 2-3	-	+	+	+
Broad halluces	-	+	+	-
Dental				
Delayed dentition	NA	NA	+	+
Oligodontia	NA	NA	+	+
Radiculomegaly	NA	NA	+	+
Talon cusp	NA	NA	+	-
Other				
Developmental delay	+	+	-	-
Umbilical hernia	+	-	-	-

OFCD = oculo-facial-cardio-dental syndrome; (+) = present; (-) = absent; CC = complete cataract; IC = incomplete cataract; NA = not applicable; ASD/VSD = atrial septal defect/ventricular septal defect.

intraocular lenses were implanted.

In both cases, visual impairment due to cataracts in early infancy was related to global developmental delay and they were referred to vision habilitation/rehabilitation services. Clinical evaluation of both twins at the age of 12 months revealed mild to moderate developmental delay and failure to thrive. They were unable to sit independently. Oral examination of the twin infants was unexceptional; both girls were edentulous (Table 1).

Examination of the 32-year-old mother of the monozygotic twins revealed normal height, weight and head circumference, with a high number of congenital anomalies including facial dysmorphism: long face, long philtrum, left ptosis, iris coloboma, and horizontal nystagmus (Figure 1). Thoracic kyphoscoliosis, syndactyly of 2nd and 3rd toes with camptodactyly of the second toe on the left side and broad hallux on both sides were also noted. She reported a normal psychomotor development and her intelligence

was above average. In early childhood, she was diagnosed with a heart murmur but with no heart defect. She was born with bilateral incomplete (incipient) cataract. After cataract surgery, performed at the age of 2 years, she developed subsequent glaucoma at the age of 12 years. She has been wearing glasses since her third year of life due to a high refractive error. Low vision is more pronounced in the left eye. She did not get pregnant for 5 years before the affected twins were born after *in vitro* fertilization.

Oral examination of the twins' mother showed several missing teeth and class II malocclusion with extremely deep overbite, highly arched palate, thickened maxillary frenulum with a 3-mm diastema between the upper central incisors, dens evaginatus or talon cusp of the maxillary right central incisor (Figure 2A), also recognized later on the orthopantomogram (OPG; Figure 2B). In addition, slight yellowish discoloration of the upper frontal teeth without enamel defects was found. OPG revealed radiculomegaly and root dilaceration of all four canines and lower right first premolar (Figure 2B). On the OPG, hypodontia of three second premolars and third molars was found on the right side. The lower right first premolar also showed an unusual appearance and morphology of the endodontic space. Review of her dental history indicated delayed eruption in both dentitions (Table 1).

Examination of the 53-year-old maternal grandmother of the monozygotic twins showed facial dysmorphism (long face, long philtrum, mildly broad nasal tip) and syndactyly of 2nd and 3rd toes on both sides. She was born with bilateral incomplete cataract that was operated in the second year of life. She developed subsequent glaucoma. Because of glaucoma she gradually lost vision in the right eye after her twenties and in the left eye after her thirties. Today she is blind due to congenital cataracts and secondary glaucoma, because during the operation in childhood no intraocular lenses were implanted. She had no cardiac disorders and she is not mentally disabled.

OPG of the twins' maternal grandmother revealed radiculomegaly and root dilacerations of the three canines. Review of her dental history indicated radiculomegaly of the extracted upper right canine due to complicated surgical removal of the tooth with the elongated root. Clinical examination showed high arched palate, numerous missing teeth and class II malocclusion with mild overbite on the remaining frontal teeth. Her dental history revealed delayed dental eruption and hypodontia of all four first premolars and of




Figure 1. Dysmorphic facial features typical of oculo-facio-cardio-dental (OFCD) syndrome in the 32-year-old mother and her 1-year-old monozygotic twins.

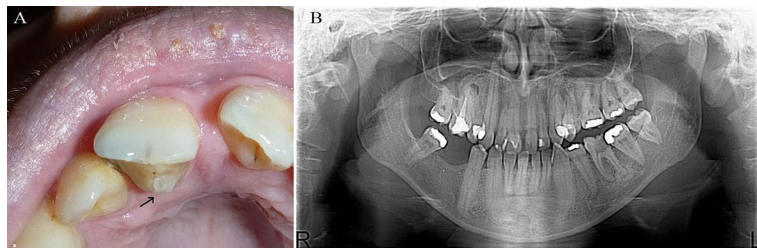


Figure 2. A, Intraoral photograph of the twins' mother showing talon cusp of the maxillary right central incisor. B, Orthopantomogram of the twins' mother.

the lower right lateral incisor (Table 1).

Genotypic data

In order to confirm monozygotic twins, postnatal DNA analysis of autosomal short tandem repeat (STR) loci was performed using the MiniFiler PCR Amplification Kit (Applied Biosystems, Germany) and showed that their STR profiles were identical.

The coding region of the *BCOR* gene (exons 2-15; GenBank accession No. NM_001123385) and flanking intronic sequences were PCR-amplified from genomic DNA of the twins' mother. Primer sequences are available on request. Amplicons were directly sequenced using the ABI BigDye Terminator Sequencing Kit (Applied Biosystems) and an automated capillary sequencer (ABI 3500; Applied Biosystems). Sequence electropherograms were analyzed using the Sequence Pilot software (JSI Medical Systems, Germany). Subsequently, *BCOR* exon 11 was amplified from genomic DNA of the 2 twins and their grandmother and directly sequenced.

We identified the heterozygous nonsense mutation c.4438C>T (p.R1480*) in exon 11 of *BCOR* in the mother of the twins. Sequencing of *BCOR* exon 11 in the DNA samples of the monozygotic twins and their grandmother revealed the same transition in the heterozygous state.

Discussion

We report here 4 females belonging to the same family with phenotypes typical of OFCD syndrome. Sequencing of the *BCOR* gene revealed a novel nonsense mutation (p.R1480*) in all of them and confirmed the clinical diagnosis. OFCD syndrome is inherited as an X-linked condition predominating in females, with high intrafamilial variability of the phenotypic outcome (2,11). This was also noticed in our study where all patients showed different phenotypic manifestations of the disease. Also, this is the first report of non-mosaic monozygotic twins with a *BCOR* gene mutation. A previous study reported identical twins with classical OFCD syndrome phenotype, but deletion of at least *BCOR* exons 4-15 was present in somatic mosaicism in both (6). The discordant congenital heart defect in the monozygotic twins described here evolved to a symptomatic type in early infancy in twin 1 and to a mild type in twin 2. Cardiac involvement in the present family ranged from asymptomatic to structural defects requiring surgery in infancy. The severity of cardiac defects showed increased expression in succeeding generations of the same family. At the same time, the severity of cataracts also showed pronounced expression in succeeding generations. It is anticipated that even mental development could follow this tendency. The high clinical variability in OFCD syndrome has been suggested to be due to X-chromosome inactivation skewing in

females with a *BCOR* mutation (3). Indeed, the influence of X-chromosome inactivation on the phenotypic outcome has been discussed before for two other X-linked dominant male-lethal disorders, such as the microphthalmia with linear skin defects syndrome and the oral-facial-digital type I syndrome (12). Thus, dosage compensation of the mammalian X-chromosome influences the phenotype of X-linked diseases manifesting primarily in females (12).

The most important clinical criteria leading to the diagnosis of OFCD syndrome are dental abnormalities, in particular extreme radiculomegaly of the canines and sometimes other teeth that we could demonstrate in our 2 adult patients. Radiculomegaly was found in almost all reported patients (6,7). Even in adult patients, the affected teeth showed vast extension of the root and open apices. Moreover, radiculomegaly was present in permanent incisors and premolars as we reported here. In both of our adult patients, we noticed dental anomalies such as oligodontia, delayed dental eruption, malocclusion, canine radiculomegaly, and root dilacerations that have also been described in the literature (6,7). An interesting dental finding was noticed in the twins' mother who showed dens evaginatus or talon cusp of the maxillary right central incisor, which is a rare dental anomaly in the normal population and has been reported in association with several other syndromes (8-10). Maxillary incisors are most frequently affected by talon cusp. We confirmed the presence of a talon cusp in the mother of the twins by clinical and X-ray diagnosis. To the best of our knowledge, this is the first report of a talon cusp in a patient with molecularly confirmed OFCD syndrome. Talon cusp has not been previously reported in OFCD syndrome even though dental findings are of particular interest in this disorder.

In summary, we undertook careful phenotypic analysis of 4 affected individuals in three successive generations of one family, all carrying a novel nonsense mutation in the *BCOR* gene. The most interesting finding was pronounced expression of cardiac defects and cataract in succeeding generations. Similar observations of increased clinical severity in successive generations have been reported by others (3). The second important observation was a talon cusp in a patient with genetically confirmed OFCD syndrome. This specific dental finding can be added to the dental abnormalities seen in females with this disorder. We suggest that talon cusp should be considered as a potential clinical predictor of OFCD syndrome, before X-ray diagnosis can be performed to uncover radiculomegaly as well as other dental anomalies.

Acknowledgments

We are grateful to the family for participating in this study.

References

1. Oberoi S, Winder AE, Johnston J, Vargervik K, Slavotinek AM. Case reports of oculofaciocardiodental syndrome with unusual dental findings. *Am J Med Genet A* 2005; 136: 275-277.
2. Wilkie AO, Taylor D, Scambler PJ, Baraitser M. Congenital cataract, microphthalmia and septal heart defect in two generations: a new syndrome? *Clin Dysmorphol* 1993; 2: 114-119.
3. Hedera P, Gorski JL. Oculo-facio-cardio-dental syndrome: skewed X chromosome inactivation in mother and daughter suggest X-linked dominant inheritance. *Am J Med Genet A* 2003; 123A: 261-266.
4. Horn D, Chyrek M, Kleier S, Luttgen S, Bolz H, Hinkel GK, et al. Novel mutations in BCOR in three patients with oculo-facio-cardio-dental syndrome, but none in Lenz microphthalmia syndrome. *Eur J Hum Genet* 2005; 13: 563-569.
5. Ng D, Thakker N, Corcoran CM, Donnai D, Perveen R, Schneider A, et al. Oculofaciocardiodental and Lenz microphthalmia syndromes result from distinct classes of mutations in BCOR. *Nat Genet* 2004; 36: 411-416.
6. Hilton E, Johnston J, Whalen S, Okamoto N, Hatsukawa Y, Nishio J, et al. BCOR analysis in patients with OFCD and Lenz microphthalmia syndromes, mental retardation with ocular anomalies, and cardiac laterality defects. *Eur J Hum Genet* 2009; 17: 1325-1335.
7. Schulze BR, Horn D, Kobelt A, Tariverdian G, Stellzig A. Rare dental abnormalities seen in oculo-facio-cardio-dental (OFCD) syndrome: three new cases and review of nine patients. *Am J Med Genet* 1999; 82: 429-435.
8. Mitchell WH. Letter to the editor. *Dental Cosmos* 1892; 34: 1036.
9. Mellor JK, Ripa LW. Talon cusp: a clinically significant anomaly. *Oral Surg Oral Med Oral Pathol* 1970; 29: 225-228.
10. Dinesh RB, Hegde S. A talon cusp on fused teeth associated with hypodontia: report of a unique case. *Eur J Dent* 2010; 4: 75-80.
11. McGovern E, Al-Mudaffer M, McMahon C, Brosnahan D, Fleming P, Reardon W. Oculo-facio-cardio-dental syndrome in a mother and daughter. *Int J Oral Maxillofac Surg* 2006; 35: 1060-1062.
12. Morleo M, Franco B. Dosage compensation of the mammalian X chromosome influences the phenotypic variability of X-linked dominant male-lethal disorders. *J Med Genet* 2008; 45: 401-408.