

Received: 2015.10.17
Accepted: 2016.01.26
Published: 2016.09.01

Anterograde Fixation Module for Posterior Acetabular Column Fracture: Computer-Assisted Determination of Optimal Entry Point, Angle, and Length for Screw Insertion

Authors' Contribution:
Study Design A
Data Collection B
Statistical Analysis C
Data Interpretation D
Manuscript Preparation E
Literature Search F
Funds Collection G

ABE 1,2 Yongqiang Xu
C 3 Chuangxin Lin
F 4 Lifeng Zhang
E 5 Miaoxiong Lin
D 1 Jianqiang Lai
C 1 Shenglu Cao
B 1 Gang Peng
F 1 Kai Feng
E 2 Ge Yan
E 3 Daozhang Cai
A 1 Gang Wang

1 Department of Orthopedics and Traumatology, Nanfang Hospital, Southern Medical University, Guangzhou, Guangdong, P.R. China
2 Department of Orthopedics, Hunan Provincial People's Hospital, Changsha, Hunan, P.R. China
3 Department of Orthopedics, The Third Affiliated Hospital of Southern Medical University, Guangzhou, Guangdong, P.R. China
4 Department of Traumatology, The Second Affiliated Hospital of Inner Mongolia Medical University, Hohhot, Inner Mongolia, P.R. China
5 Department of Clinical Laboratory Medicine, Hospital of Traditional Chinese Medicine of Zhongshan, Zhongshan, Guangdong, P.R. China

Corresponding Author: Gang Wang, e-mail: gang_w_wang@sina.com

Source of support: This study was supported by the Natural Science Foundation of Guangdong Province (no. 10151051501000085)

Background: The aim of this study was to provide valid data for a plate-screw fixation model for fractured posterior-anterior columns of the acetabulum.

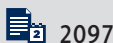Material/Methods: Nineteen cadaveric bony hemi-pelvis specimens were obtained and 50 healthy adults were enrolled. The modified Stoppa approach and computed tomography (CT) imaging were used to collect the measured parameter data of the module.

Results: The measured parameter data were as follows: *OP*, 0.96 ± 0.32 cm in females and 0.92 ± 0.16 cm in males ($P > 0.05$); *PI*, 0.98 ± 0.28 cm in females, and 0.75 ± 0.23 cm in males ($P > 0.05$); $\angle \theta$, $59.68^\circ \pm 6.28^\circ$ in females and $56.75^\circ \pm 3.22^\circ$ in males ($P > 0.05$); and $\angle \varphi$, $41.27^\circ \pm 2.76^\circ$ in females and $34.31^\circ \pm 2.78^\circ$ in males ($P < 0.05$). The corresponding CT image data were as follows: *PI*, 1.08 ± 0.22 cm in females and 0.85 ± 0.27 cm in males ($P > 0.05$); *OP*, 1.06 ± 0.29 cm in females and 1.12 ± 0.24 cm in males ($P > 0.05$); $\angle \theta$, $55.33^\circ \pm 4.00^\circ$ in females and $55.50^\circ \pm 3.43^\circ$ in males ($P > 0.05$); and $\angle \varphi$ was $39.21^\circ \pm 2.45^\circ$ in females and $35.58^\circ \pm 2.31^\circ$ in males ($P < 0.05$). No significant difference with respect to sex and side existed between specimens and healthy adults ($P > 0.05$).

Conclusions: The measured parameter data obtained in healthy adults and cadaveric specimens provided an anatomic basis for the designation of the guide module, and thus confirmed the accuracy and safety of screw placement in fractured columns of the acetabulum.

MeSH Keywords: **Computer Simulation • Fractures, Bone • Hip Fractures**

Full-text PDF: <http://www.medscimonit.com/abstract/index/idArt/896313>



2097



2



9



19



Background

Fracture of dual columns of the acetabulum is the most complicated type of acetabular fracture. Posterior-anterior column fixation is considered to be important for joint stability and early mobilization after surgery [1,2]. Screw penetration during surgery is considered unusual, but may lead to potential complications [3]. A proper plate-screw fixation model can avoid such complications [4].

Recently, screw placement assisted by digital technology has been used. Ochs et al. [5] investigated screw placement into the anterior column with CT analysis for 260 cadaveric bony hemi-pelvis specimens. Chen et al. [6] analyzed 164 cases of three-dimensional CT pelvic data and concluded that there is a sex difference in screw placement into fractured anterior columns. Few studies have focused on a fixation model involving fractured posterior-anterior columns of the acetabulum. Thus, we designed a plate-screw fixation model for fractured columns of the acetabulum (Figure 1; Patent No. CN203988321U). This model is divided into 3 parts: the reconstructive plate, which acts to fix the anterior column fracture; the square plate, which is used to support the fracture of the square area; and the third part is a lag screw for the posterior column, which is the key point of our design because the entry point of the lag screw determines the implant of the guide plate as well as the direction of the screw holes.

This study aimed to provide valid data for our design. We first used the Modified Stoppa approach for measuring the reference point, which can improve the entry point and angle of the lag screw, thus providing an anatomic basis for accurate placement of the screw. After cadaveric research, the comprehensive studies on the placement of the model and entry point of the lag screw of the acetabulum were measured by computed tomography (CT) images in healthy adults.

Material and Methods

Cadaveric research

The Ethics Board Review of South Medical University (Guangzhou, China) approved the study after a thorough investigation and verification. Nineteen recently embalmed adult bony hemi-pelvis specimens were obtained from the Anatomy Department of South Medical University. The specimens included 8 males and 11 females. Signed informed consent was obtained from all participants. All of the specimens had complete integrity and there were no deformities or fractures based on visual inspection and an X-ray study.




Figure 1. The plate-screw fixation model for both fractured columns of the acetabulum (Patent no. CN203988321U).

The surgical field of vision was marked by the modified Stoppa approach in the hemi-pelvis (Figure 2) [7]. The screw was inserted in a retrograde motion on the minimum of the ischial tuberosity (Figure 3) [8,9]. A screw, 3.5 mm in length, was inserted parallel to the posterior line of the ischiadic ramus. Screws were successfully placed in all 19 hemi-pelvises. The distance between the entry point and the vertical line of the arcus marginalis (OP), and distance between the apex-Q of the greater sciatic notch and the vertical line of the arcus marginalis (PI) were measured (Figure 4).

After projecting the line of the screw on an α -square, the angle of the screw placement direction and the α -square ($\angle\phi$) were measured. The angle of the screw placement direction and the arcus marginalis ($\angle\theta$) were measured (Figure 4). The distance between the entry point and the front line of the sacroiliac joint may exhibit a sex difference, thus the distance between the ischiadic spine and the posterior inferior iliac spine was also measured.

Module fixation of healthy adults

According to the data obtained from the cadaveric study, we selected 50 healthy adults (30 males and 20 females; age range, 25~69 years; mean age, 46.4 years) in this study. The method used in the specimens was applied to obtain the corresponding data. The data was collected by CT scan (16-slice multidetector scanner [slice thickness, 1.25 mm]; GE, [Fairfield, Connecticut], USA;). After data screening, the specimens that

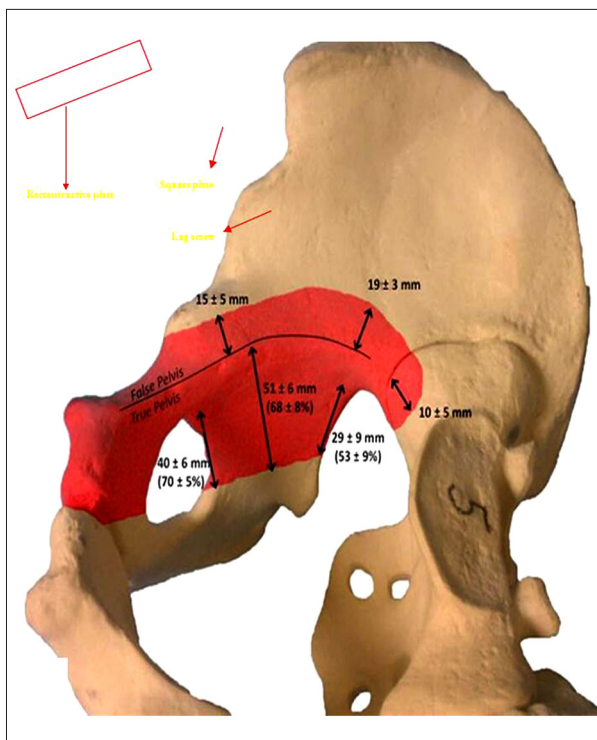


Figure 2. The surgical field of vision of the modified Stoppa approach was marked in the red area of the hemi-pelvis. The exposure of the iliac fossa: acetabular roof, 15 ± 5 mm outwards to the arc margin, 19 ± 3 mm posterior to the greater sciatic notch; the exposure of the square: front line, 40 ± 6 mm downwards to the arc margin, posterior line, 29 ± 9 mm downwards to the arc margin, midline, 51 ± 6 mm downwards to the arc margin; a 10 ± 5 mm area of the anterior part of sacroiliac joint can be exposed by the sacrum.

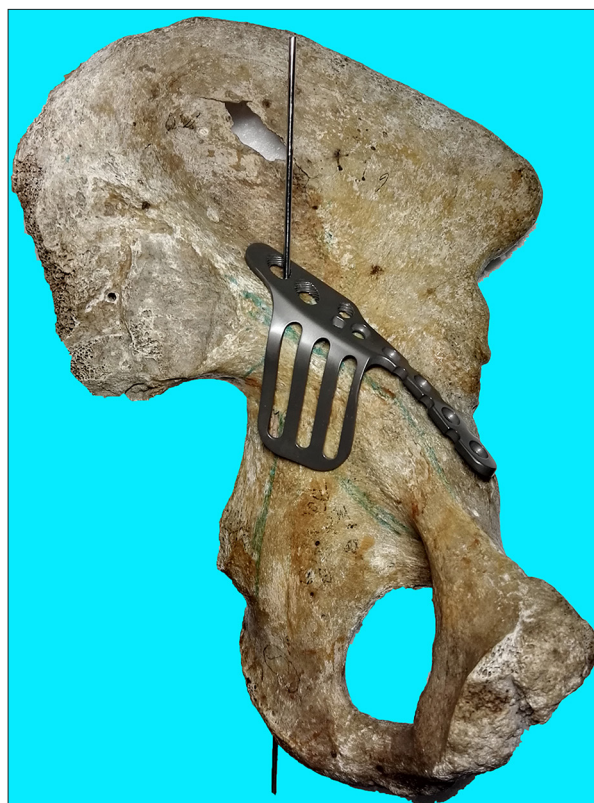


Figure 3. Screw placement of the hemi-pelvis specimens: a lag screw was inserted in a retrograde motion on the minimum of the ischial tuberosity and parallel to the posterior line of the ischiadic ramus.

included deformities, fractures, tumors, osteoporosis, or incomplete scanning were excluded. The data of the 50 specimens were stored in “.dicom” format and imported to Mimics 10.01 (Materialise, [Leuven], Belgium) for measurement. The threshold value was set with bone CT, and three-dimensional reconstruction was performed by region growth.

Designation of the guide module of the plate screw

The plate screw as 3 cm in length and 1.5 cm in width. The screw hole had a 2.5 mm radius, with a supplementary hole 1 cm from the screw hole. The spatial position was locked by the screw hole. The posterior hole was the screw hole (Figure 5).

The determination of entry point and the placement of guide module

The 3-dimensional reconstruction images of the hemi-pelvis specimens were rotated laterally and the square area was fully exposed. A line was drawn along the posterior border of the

ischial ramus and extended to cross the arcus marginalis at point I. Anterior to this point was the placement area of the guide module, which was 3 cm in length and 1.5 cm in width. A 6.5-mm screw was placed in the posterior column of the acetabulum from the iliac fossa to the tuberosity of the ischium [7]. The entry point of the posterior column was 15.27 mm from the anterior aspect of the sacroiliac joint and 13.62 mm from the arcus marginalis. Thus, the entry point of the posterior column was guaranteed in the placement area of the guide module. A 3-mm radius cylinder was virtually placed in the hemi-pelvis using Mimics-CAD. The cylinder was adjusted in the sagittal, coronal, and transverse sections. The 3-dimensional reconstruction images showed that the cylinder was not out of the sclerotin. Then, both ends of the cylinder were extended and crossed out of the iliac fossa and tuberosity of the ischium. The distance between the out-point, O, and the arcus marginalis, OP, as well as the length of the screw hole and posterior border of the guide module, PI, were measured (Figure 5). All the hemi-pelvis specimens were placed with screws virtually and the entry points were all guaranteed in the placement area of the guide module (Figure 6).

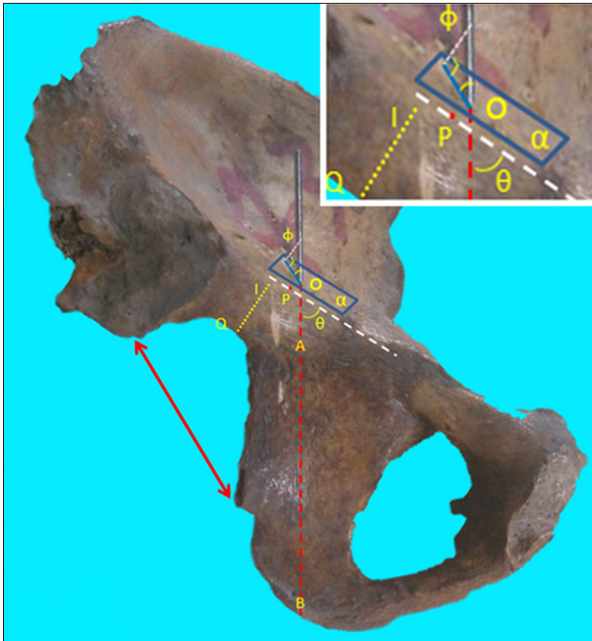


Figure 4. A reference line, AB, was composed in the square area of the acetabulum as the projection of the screw pathway. O – the direct motion entry point; P – the arcus marginalis; square α – considered as the entry point plate; $\angle\theta$ – the angle of the screw and arcus marginalis; $\angle\phi$ – the angle of the screw and the plate.




Figure 5. The screw thread of the hole prescribes a limit to the angle of placement from which the entry point of the screw, as well as the placement of the guide module, was determined.

Angle of the lag screw of the guide module

Because the placement area of the guide module, the fossa iliaca was parallel to the undersurface of the guide module; the relative position between the cylinder and the placement area was the direction of the locking screw. The relative position can be determined by $\angle\phi$ and $\angle\theta$. These 2 angles were measured using the RP Slice Module of Mimics (Figure 7).

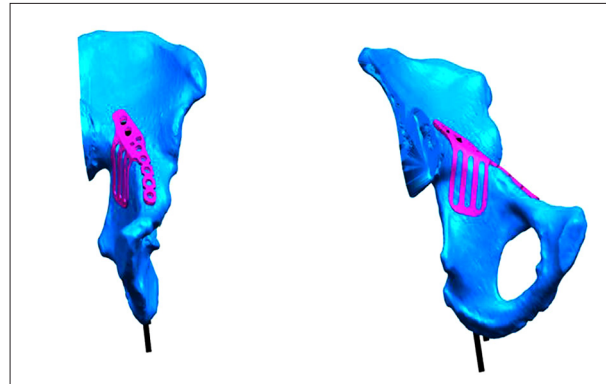


Figure 6. Virtual placement of the screws into the hemi-pelvic specimens.

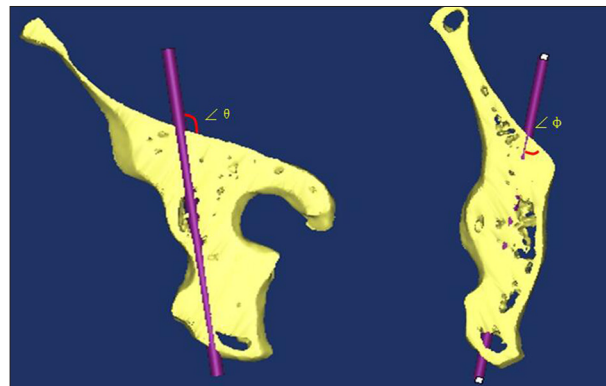


Figure 7. The RP Slice Module of Mimics.

Statistical analysis

The corresponding data were analyzed using SPSS (Statistical Program for Social Sciences, version 20.0; SPSS, Inc., Chicago, IL, USA). The values of the parameters are expressed as the mean \pm standard deviation. Between-group comparisons of the data were made by a t-test. P values <0.05 were regarded as statistically different.

Results

Cadaveric results

The data for cadaveric specimens are recorded in Table 1 and Figure 8. The distance between the out-point, O, and the arcus marginalis, OP, was 0.96 ± 0.32 cm in females and 0.92 ± 0.16 cm in males ($P>0.05$). The length of the screw hole and posterior border of the guide module, PI, was 0.98 ± 0.28 cm in females and 0.75 ± 0.23 cm in males ($P>0.05$). For the width of the entry point and the anterior border of the sacroiliac joint, the value was 2.43 ± 0.66 cm in females and 1.87 ± 0.26 cm in males ($P<0.05$). The distance between the ischiadic spine and posterior inferior iliac spine was 5.74 ± 0.46 cm in females and

Table 1. The data for cadaveric specimens.

Measured parameters	Female n=11	Male n=8	P
OP (cm)	0.96±0.32	0.92±0.16	0.786
The distance of the entry point and the anterior border of the sacroiliac joint (cm)	2.43±0.66	1.87±0.26	0.037*
PI (cm)	0.98±0.28	0.75±0.23	0.075
The distance of ischiadic spine and posterior inferior iliac spine (cm)	5.74±0.46	5.16±0.29	0.006*
∠θ (°)	59.68±6.28	56.75±3.22	0.245
∠φ (°)	41.27±2.76	34.31±2.78	<0.001*

* P<0.05.

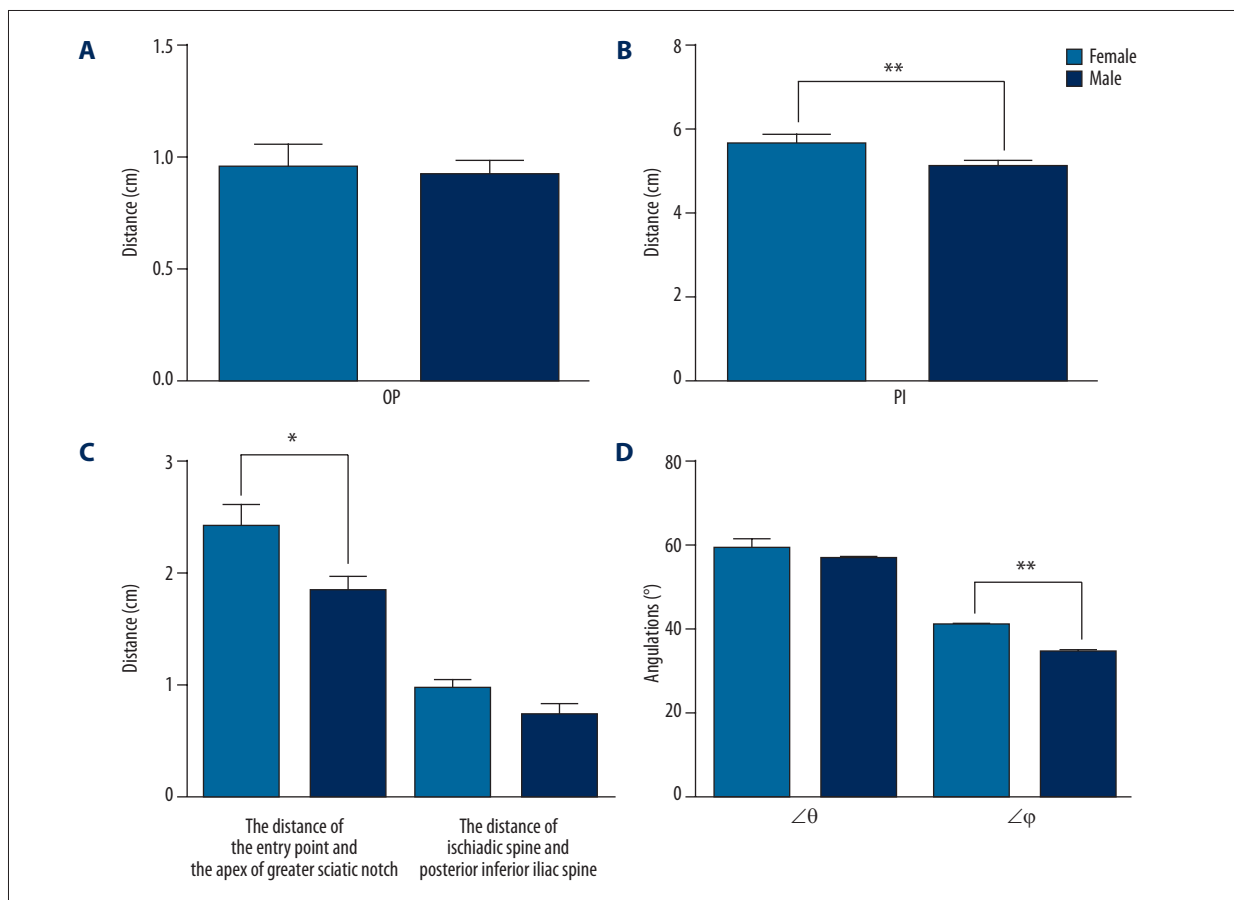


Figure 8. (A) There was no significant sex difference in OP; (B) The distance between the ischiadic spine and the posterior inferior iliac spine in females was greater than males. (C) The distance of the entry point and the apex of greater sciatic notch showed no significant sex difference, while that of the ischiadic spine and posterior inferior iliac spine was significantly different. (D) There was no significant sex difference in ∠θ, while ∠φ was significantly different.

5.16±0.29 cm in males (P<0.05). The angle of the screw and the arcus marginalis, ∠θ, was 59.68°±6.28° in females and 56.75°±3.22° in males (P>0.05). The angle of the screw and

square α, ∠φ, was 41.27°±2.76° in females and 34.31°±2.78° in males (P<0.05).

Table 2. Results of measured parameters of 50 healthy adults.

Measured parameters	Female n=20	Male n=30	P
OP (cm)	1.06±0.29	1.12±0.24	>0.05
The distance of the entry point and the anterior border of the sacroiliac joint (cm)	2.21±0.46	1.98±0.12	0.51
PI (cm)	1.08±0.22	0.85±0.27	>0.05
The distance of ischiadic spine and posterior inferior iliac spine (cm)	5.49±0.61	4.86±0.54	<0.001
∠θ (°)	55.33±4.00	55.50±3.43	>0.05
∠φ (°)	39.21±2.45	35.58±2.31	<0.05

* P<0.05.

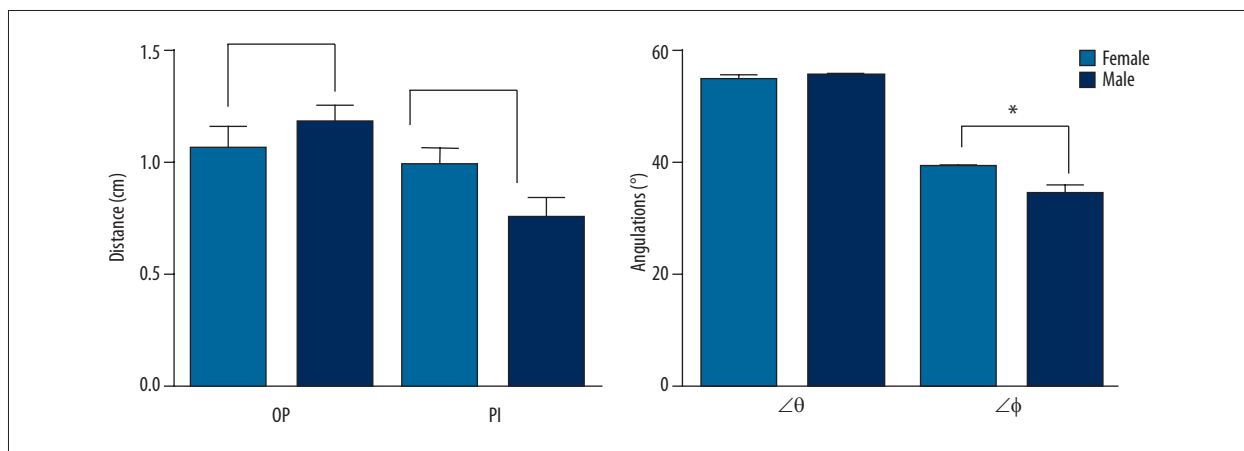


Figure 9. The results of measured parameters obtained in the specimens are consistent with the results in the healthy adults.

Module fixation results

The length of PI was 1.08±0.22 cm in females and 0.85±0.27 cm in males (mean, 0.98±0.13 cm; range, 0.67–1.56 cm; P>0.05), and the length of OP (the entry point and arcus marginalis) was 1.06±0.29 cm in females and 1.12±0.24 cm in males (mean, 1.09±0.26 cm; range, 0.70–1.59; P>0.05). The angle of the screw and the arcus marginalis (∠θ) was 55.33±4.00° in females and 55.50±3.43° in males (mean, 55.43±3.64°; range, 49.34°–66.88°; P>0.05). The angle of the screw and the plate (∠φ) was 39.21±2.45° in females and 35.58±2.31° in males (P<0.05). The width of the entry point and the anterior border of the sacroiliac joint was 2.21±0.46 cm in females and 1.98±0.12 cm in males (P=0.51). The distance between the ischiadic spine and posterior inferior iliac spine was 5.49±0.61 cm in females and 4.86±0.54 cm in males (P<0.001). The data for healthy adults are recorded in Table 2 and Figure 9. A comparison of the corresponding data was made between specimens and healthy adults, and there was no significant difference based on sex and side (P>0.05).

Discussion

Acetabular fractures, particularly those involving the anterior and posterior columns, remain technically challenging for orthopedic surgeons [10]. Dual column fixation is considered to be important for joint stability and early mobilization in surgery [11,12]. We designed a plate-screw fixation model for both fractured columns of the acetabulum. In this model, an excellent anatomic understanding of the hemi-pelvis can be very useful in determining the screw insertion into the hip joint. Thus, an anatomic study was conducted regarding screw fixation in the posterior column of the acetabulum because the placement of the screw determines fixation of the plate-screw model.

The angle of screw insertion in the posterior column was improved using a modified Stoppa approach, which can expose an area of 15–19 mm from the iliac fossa to the arcus marginalis [13]. This area, as well as the distal end of the square, was considered as the penetration plate [14]. To determine the insertion angle, the included angle of square, α, and screw, ∠φ, was measured and the angle of the screw and arcus marginalis,

$\angle\theta$, was measured for assistance. There was no significant sex difference in $\angle\theta$, while $\angle\phi$ was significantly different. During insertion, the deviation of the screw should be near 34° in males and 41° in females. The data maintained from the cadaveric specimens can support designation of the plate-screw.

To assist the design and clinical application of the guide module, the measured parameters were revised with reference to the data obtained from the cadaveric specimens. The reference section of the entry point, the anterior border of the sacroiliac joint, was changed to the intersection point of the arcus marginalis and the extension line of posterior border of the ischiadic ramus [15,16]. The reason for this revision indicates a significant sex difference by defining the anterior border of the sacroiliac joint as a reference section because the greater sciatic notch is wider in females than males [17]. Accordingly, the distance between the anterior border of the sacroiliac joint and the entry point is also wider in females. If the reference section is defined as the intersection point of the arcus marginalis and the extension line of the posterior border of the ischiadic ramus, there is no sex difference [18]. This was approved in CT reconstruction in our study and the distance was approximately 1 cm. The intersection point was closer to the fracture line and was determined by touching the greater sciatic notch in the anterior incision. Second, the absolute angle of the horizontal and sagittal planes was revised as the angle of the screw and the placement square, as well as the major axis of the placement square. This is a relative angle. In surgery, the horizontal and sagittal planes

were difficult to define because of the posture change of the patients [19]. Moreover, the CT data may have error when the different postures of patients were adjusted. Therefore, the relative angle may help with the design and manufacture of the guide module. As our research demonstrated promising results, we consider that the design may be valuable for safer fixation of bilateral acetabular fractures in peri-operative planning.

The major limitation in this study was that we only included a small number of cases based on the design in our study. We will continue to apply this method in larger numbers of healthy adults with dual acetabular fractures. The more comprehensive research on a larger number of cases will be beneficial to confirm the validity and efficiency of this design in clinical practice.

Conclusions

In this study, cadaveric specimens and healthy adults were selected to study the entry point and angle of the lag screw. The data of measured parameters obtained in this study, which are consistent, provided an anatomic basis for the designation of the guide module; therefore, accurate and safe placement of the lag screw into the posterior column of the acetabular fracture is possible.

Conflicts of interest

The authors have declared that no competing interests exist.

References:

- Culemann U, Marintschev I, Gras F, Pohlemann T: Infra-acetabular corridor – technical tip for an additional screw placement to increase the fixation strength of acetabular fractures. *J Trauma*, 2011; 70: 244–46
- Marintschev I, Gras F, Schwarz CE et al: Biomechanical comparison of different acetabular plate systems and constructs – the role of an infra-acetabular screw placement and use of locking plates. *Injury*, 2012; 43: 470–74
- Zhang K, Zhang S, Yang J et al: Proximal femoral nail vs. dynamic hip screw in treatment of intertrochanteric fractures: A meta-analysis. *Med Sci Monit*, 2014; 20: 1628–33
- Russell GV Jr, Nork SE, Chip Routt ML Jr: Perioperative complications associated with operative treatment of acetabular fractures. *J Trauma*, 2001; 51: 1098–103
- Ochs BG, Stuby FM, Ateschrang A et al: Retrograde lag screw placement in anterior acetabular column with regard to the anterior pelvic plane and midsagittal plane – virtual mapping of 260 three-dimensional hemipelvises for quantitative anatomic analysis. *Injury*, 2014; 45: 1590–98
- Chen KN, Wang G, Cao LG, Zhang MC: Differences of percutaneous retrograde screw fixation of anterior column acetabular fractures between male and female: A study of 164 virtual three-dimensional models. *Injury*, 2009; 40: 1067–72
- Bible JE, Choxi AA, Kadakia RJ et al: Quantification of bony pelvic exposure through the modified Stoppa approach. *J Orthop Trauma*, 2014; 28: 320–23
- Starr AJ, Reinert CM, Jones AL: Percutaneous fixation of the columns of the acetabulum: a new technique. *J Orthop Trauma*, 1998; 12: 51–58
- Vandenbussche E, Saffarini M, Taillieu F, Mutschler C: The asymmetric profile of the acetabulum. *Clin Orthop Relat Res*, 2008; 466: 417–23
- Liu X, Li G, Wang J, Zhang H: Minimally invasive unilateral vs. bilateral pedicle screw fixation and lumbar interbody fusion in treatment of multi-segment lumbar degenerative disorders. *Med Sci Monit*, 2015; 21: 3652–57
- Mardian S, Schaser KD, Hinz P et al: Fixation of acetabular fractures via the ilioinguinal versus pararectus approach: a direct comparison. *Bone Joint J*, 2015; 97-B: 1271–78
- Li X, Lv C, Yan T: Unilateral versus bilateral pedicle screw fixation for degenerative lumbar diseases: A meta-analysis of 10 randomized controlled trials. *Med Sci Monit*, 2015; 21: 782–90
- Harris AM, Althausen P, Kellam JF, Bosse MJ: Simultaneous anterior and posterior approaches for complex acetabular fractures. *J Orthop Trauma*, 2008; 22: 494–97
- Cong Y, Bao N, Zhao J, Mao G: Comparing accuracy of cervical pedicle screw placement between a guidance system and manual manipulation: A cadaver study. *Med Sci Monit*, 2015; 21: 2672–77
- Mu WD, Wang XQ, Jia TH et al: Quantitative anatomic basis of antegrade lag screw placement in posterior column of acetabulum. *Arch Orthop Trauma Surg*, 2009; 129: 1531–37
- Shahulhameed A, Roberts CS, Pomeroy CL et al: Mapping the columns of the acetabulum – implications for percutaneous fixation. *Injury*, 2010; 41: 339–42
- Dienstknacht T, Muller M, Sellei R et al: Percutaneous screw placement in acetabular posterior column surgery: Gender differences in implant positioning. *Injury*, 2014; 45: 715–20
- Gras F, Gottschling H, Schroder M et al: Sex-specific differences of the infraacetabular corridor: A biomorphometric CT-based analysis on a database of 523 pelvises. *Clin Orthop Relat Res*, 2015; 473: 361–69
- Dienstknacht T, Muller M, Sellei R et al: Screw placement in percutaneous acetabular surgery: gender differences of anatomical landmarks in a cadaveric study. *Int Orthop*, 2013; 37: 673–79