



ELSEVIER

Contents lists available at ScienceDirect

JSES International

journal homepage: www.jseinternational.org

Limitation of the external glenohumeral joint rotation is associated with subacromial impingement syndrome, especially pain

Daisuke Ishii, MD^a, Tomonori Kenmoku, MD, PhD^{a,*}, Ryo Tazawa, MD^a, Mitsufumi Nakawaki, MD^a, Naoshige Nagura, MD^a, Kyoko Muneshige, MD^a, Kazuo Saito, OT^b, Masashi Takaso, MD, PhD^a

^a Department of Orthopedic Surgery, Kitasato University School of Medicine, Sagami-hara, Japan

^b Department of Health Science, Tokyo Kasei University, Sayama, Japan

ARTICLE INFO

Keywords:

Shoulder impingement syndrome
Rotator cuff
Cine-magnetic resonance imaging
Shoulder pain
Rotator cuff dysfunction

Level of evidence: Level III; Cross-sectional design; Epidemiology study

Background: Subacromial impingement syndrome is a common disorder associated with functional impairment and disability of the shoulder. Internal/external glenohumeral rotation is important for shoulder function. However, because it is difficult to measure the glenohumeral joint rotation angle physically, the relationship between this angle and the clinical symptoms of subacromial impingement syndrome is still largely unknown. Using advanced cine-magnetic resonance imaging techniques, we designed a study to improve our understanding of the nature of this relationship.

Methods: We evaluated 100 shoulders with subacromial impingement syndrome. Patients underwent cine-magnetic resonance imaging during axial rotation with the arm adducted. During imaging, patients rotated their shoulder from maximum internal rotation to maximum external rotation over 10 seconds and then to maximum internal rotation over 10 seconds. The rotation angles were then evaluated using a series of axial images. The Constant–Murley (Constant) and UCLA scores for each patient were determined, and the correlation between the scores and rotational angles was assessed. Patients were divided into 3 groups according to the Constant pain score, and the rotational angles of each group were compared. Rotational angles were also compared between shoulders with and without night pain.

Results: The external rotation angle showed a significant but low correlation with the Constant and UCLA scores ($\rho = 0.24$ and 0.24 , respectively), whereas the internal rotation angle did not. In comparing the pain groups of Constant score and UCLA score, the external rotation angle significantly decreased as pain increased ($P < .01$), demonstrating a negative correlation ($\rho = -0.47$, -0.41 , respectively). Additionally, the shoulders of patients with night pain showed significantly more restriction of external rotation angles than the shoulders of those without night pain ($P = .01$).

Conclusions: Limitation of the glenohumeral joint's external rotation is correlated with pain, for which we explore possible explanations. The results suggest that night pain can be effectively reduced using therapeutic interventions that target external rotational dysfunction.

© 2021 The Author(s). Published by Elsevier Inc. on behalf of American Shoulder and Elbow Surgeons.

This is an open access article under the CC BY-NC-ND license (<http://creativecommons.org/licenses/by-nc-nd/4.0/>).

Subacromial impingement syndrome (SIS) is a common disorder associated with functional impairment and disability of the shoulder.^{16,28,30,36} It has been reported that the presence of SIS predisposed shoulders to mechanical compression in the subacromial space by causing excessive superior translation of the

humeral head during elevation.^{3,28,30} This caused a narrowing of acromiohumeral distance to be purported as the cause of SIS-related pain. However, a recent review showed no relationship between subacromial humeral distance and SIS-related pain.³⁴ Recent meta-analysis and review also suggested that SIS-related pain is not induced by impingement, but is associated with musculotendinous dysfunctions, such as the infraspinatus and subscapularis.^{13,28,30,34,36} However, the precise nature of their association with SIS has not been explored.

Internal/external glenohumeral rotation is important for shoulder function since it is involved in most shoulder movements such as abduction or forward flexion.^{1,24} Previous reports have indicated that internal/external glenohumeral rotation are

The experimental protocol was approved by the Institutional Review Board for Observation and Epidemiological Study, Kitasato University Medical Ethics Organization (reference number: KME0 B11-87).

* Corresponding author: Tomonori Kenmoku, MD, PhD, Department of Orthopaedic Surgery, School of Medicine, Kitasato University, 1-15-1 Kitasato, Minami-ku, Sagami-hara, Kanagawa 252-0570, Japan.

E-mail address: pseudolefty811@yahoo.co.jp (T. Kenmoku).

<https://doi.org/10.1016/j.jseint.2021.01.015>

2666-6383/© 2021 The Author(s). Published by Elsevier Inc. on behalf of American Shoulder and Elbow Surgeons. This is an open access article under the CC BY-NC-ND license (<http://creativecommons.org/licenses/by-nc-nd/4.0/>).

restricted during elevation in shoulders with SIS.^{12,25,35} However, the rotational angle of the shoulder that can be measured physically is the thoracohumeral angle, which includes the motion of not only the glenohumeral joint but also the thoracoscapular, acromioclavicular, and sternoclavicular joints.⁴¹ Thus, because it is difficult to measure the glenohumeral joint rotation angle physically, the relationship between glenohumeral rotational function and clinical symptoms of SIS is still largely unknown.

Recent advances in magnetic resonance imaging (MRI) systems now enable the acquisition of 1 to 2 images per second for cine-MRI, allowing dynamic joint motion analysis. Cine-MRI allows live assessment of individuals and has been used for various applications, such as evaluation of cardiac function.^{2,15} Shoulders with SIS have been shown to have significant limitations in glenohumeral joint rotation, determined using cine-MRI, when compared with asymptomatic shoulders.¹⁸ However, the clinical implications of glenohumeral rotational limitations remain unclear.

We believe that elucidating these clinical implications may help in treating SIS by targeted therapy. This could be accomplished through analyzing the relationship between the clinical score and glenohumeral rotation angle. The purpose of this study was to investigate the relationship between the limitation of glenohumeral joint rotation and the clinical symptoms of patients with SIS. We hypothesized that the limitation of glenohumeral rotation is positively associated with clinical symptoms, especially pain.

Materials and methods

Participants

The experimental protocol was conducted in accordance with the guidelines of our institutional review board, which approved the protocol for this study. All participants provided written informed consent. The informed consent for participants below the age of 20 years was provided by their parents.

This was a cross-sectional study. Between January 2012 and December 2015, a total of 155 patients (169 shoulders) with a mean age of 53 years (range, 15–81 years), with suspected SIS, and without global loss of passive range of motion ($\leq 100^\circ$ of forward flexion, $\leq 10^\circ$ of external rotation with the arm adducted, and internal rotation of $<$ the L5 level),³⁹ underwent cine-MRI at one of our 2 institutions. Before testing, we excluded patients who experienced pain either at rest or in both active and passive internal and external rotation with the arm in an adducted position to eliminate the influence of pain on restriction of active rotational motion ($n = 17$). We excluded patients with collagen diseases ($n = 4$). A single surgeon confirmed that all patients were positive for at least 3 of the following tests: the painful arc sign,¹⁹ the Neer impingement test,³⁰ the Hawkins–Kennedy impingement test,¹⁴ Jobe's test,¹⁶ or the horizontal impingement test.⁴⁴ The maneuver for the horizontal impingement test began with the examiner placing the patient's arm in 90 degrees of shoulder abduction with the elbow flexed to 90 degrees and then rotating the arm internally. The test was considered positive if the patient experienced pain upon passive internal rotation. Thirty-four patients (29 shoulders) who were diagnosed with partial or full-thickness rotator cuff tears using MRI (T2-weighted coronal and sagittal images) were also excluded. None of the patients showed the presence of increased signal intensity or capsule edema around the axillary recess using fat-suppressed T2-weighted MRI, which strongly suggests capsulitis related to glenohumeral joint motion (sensitivity, 85.3–88.2%; specificity, 88.2%).^{10,33} In addition, the same shoulder surgeon confirmed that all patients had no symptoms to warrant suspicion of frozen shoulder³⁹ at least 1 month after MRI. Thus, 95 patients

Table 1
Patient demographic data.

	Shoulders (n = 100)
Age (y)	51 (range, 16–81)
Sex	F, 33; M, 62
Side	D, 61; ND, 39
Clinical ROM	
Flexion ($^\circ$)	158 \pm 22
Abduction ($^\circ$)	136 \pm 39
ER ($^\circ$)	68 \pm 18
IR*	T10 (B–T5)
Physical tests	
Painful arc test	Positive, 77; negative, 23
Neer impingement test	Positive, 50; negative, 50
Hawkins–Kennedy test	Positive, 91; negative, 9
Jobe's test	Positive, 79; negative, 21
Horizontal impingement test	Positive, 87; negative, 13
Clinical score	
Constant score (points)	65 \pm 13
UCLA score (points)	18 \pm 3

F, female; M, male; D, dominant; ND, nondominant; ER, external rotation; IR, internal rotation; ROM, range of motion; T, thoracic vertebra; B, buttock; UCLA, University of California in Los Angeles.

* IR was determined using the vertebra reachable by the thumb.

(100 shoulders), 62 men and 33 women with a mean age of 51 years (range, 16–81 years), were included in this study (Table 1, Fig. 1).

Clinical assessment

One orthopedic surgeon measured the active range of motions for flexion, abduction, and internal and external rotation of the adducted shoulders with the patients seated. According to Cave and Roberts' concept of defining a zero position of the glenohumeral joint with a goniometer,⁵ flexion and abduction were measured in the sagittal and coronal planes with the elbow extended and the wrist in a neutral position. External rotation (ER) was measured with the arm at the side and 90-degree elbow flexion. Internal rotation (IR) was measured as the best reached height of the patient's thumb on their back along their vertebra according to the Constant–Murley score.⁷

All patients were also evaluated using the Constant–Murley score⁷ and the University of California at Los Angeles Shoulder Rating Scale (UCLA score).⁸ Both scores were determined using a questionnaire that the patient responded to based on the guidance of an orthopedic surgeon. Every patient assessed their pain in both clinical scores, after one orthopedic surgeon had suggested a reference category based on the numeric rating scale of pain (mild, 1–3; moderate, 4–7; and severe, >8).¹¹ Similarly, in the UCLA score, patients chose their own pain category from the items (group 1, occasional and slight; group 2, present during heavy or particular activities only, salicylates used occasionally; group 3, none or little at rest' present during light activities, salicylates used frequently; group 4, present always but bearable' strong medication occasionally; group 5, present always and unbearable, strong medication frequently).

Night pain

Night pain associated with shoulder disorders can be due to several pathologies and is frequently characterized by aching pain that is relieved upon sitting upright.^{23,31,38} This can also cause individuals to awaken from pain induced by rolling over or adopting the lateral decubitus position.^{40,43} Consistent with the definition previously reported,^{23,38} we divided patients into 2 groups, those who had night pain and those who did not. We excluded

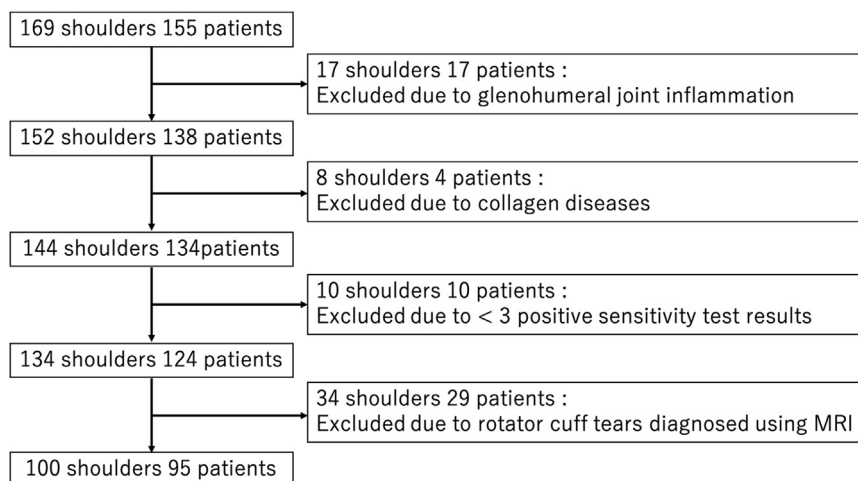


Figure 1 A flowchart showing the progressive inclusion and exclusion of subjects in this study. MRI, magnetic resonance imaging.

movement-related pain, such as that experienced when rolling over, and compression pain on the affected side when in the lateral position.

MRI acquisition

Imaging was performed with a 1.5 T MRI system using a 4-channel shoulder array coil (Signa; GE Healthcare, Amersham, England) or with a 1.5 T MRI system using one of the manufacturer's shoulder coils (shoulder 16, MAGNETOM Aera; Siemens Healthineers, Erlangen, Germany). Cine-MRI of the shoulder was performed using two-dimensional fast imaging employing steady-state acquisition (FIESTA) technique (GE Healthcare; imaging parameters: repetition time (TR)/time to echo (TE) = 4.6 ms/2.1 ms; flip angle, 20°; receiver bandwidth, ± 62.5 kHz; matrix, 256 × 224; number of excitations, 1.0; field of view, 28 × 28 cm; slice thickness, 6.0 mm) or true fast imaging with steady-state precession (True FISP) (Siemens Healthcare; imaging parameters: TR/TE = 4.91 ms/2.46 ms; flip angle, 20°; bandwidth, 349 Hz/pixel; matrix, 256 × 256; number of excitations, 1.0; field of view, 28 × 28 cm; slice thickness, 6.0 mm). Sequential images were recorded at a rate of one per second during activity. Image acquisition was performed using axial slices that included the center of the humeral head determined with a best-fit circle.

The participants performed internal and ER of the shoulder with the arm adducted in the supine position. Soft plate cushions were placed under the arm to maintain its long axis parallel to the trunk. The acquisition began with the arm fully rotated internally (with the dorsum of the hand on the greater trochanter). The radiologist counted the time using a stopwatch as the participants rotated the arm to maximum ER over 10 s and then reversed to maximum IR in the subsequent 10 s. Before MRI acquisition, all participants practiced the motion several times according to the instructions of a physician or therapist. We recorded the motion of at least 2 sets of activities for each participant.

MRI evaluation

We assessed the MRI-acquisitioned internal and external rotations of the glenohumeral joint and their correlation with the clinical scores. In addition, patients were classified using their responses to the questions of the Constant–Murley score. We then divided the patients into 3 groups according to the Constant–Murley score's pain subgroups. We also divided the

patients into 5 groups based on the UCLA score's pain subgroups. Additionally, we compared the rotational angles between patients with and without night pain.

The rotation angle was defined as the angle formed by the glenoid axis and the humeral head axis, as described in a previous report.¹⁸ The glenoid axis was defined as the line perpendicular to the glenoid fossa at its midpoint. The humeral head axis was defined as the line connecting the midpoint of the articular surface of the humeral head and the center of the best-fit circle applied to the humeral head. When the 2 axes were parallel, the joint was considered in a neutral position. (Fig. 2) All participants' recorded activities were measured, and the largest value for each participant was used for further assessment.

Statistical analysis

Statistical analysis was performed using commercial software (JMP Pro, version 14.3; SAS Institute Inc., Cary, NC). Results are presented as mean ± standard deviation. Correlations between rotational angles and clinical scores were determined using Spearman's rank correlation coefficient. The Kruskal–Wallis test was used to compare rotational angles among the pain groups, followed by the Dwass–Steel–Critchlow–Fligner as a post hoc test. Correlations between rotational angles and clinical pain subgroups of both clinical scores were determined using Spearman's rank correlation coefficient. A statistical difference between participants with and without night pain was determined using the nonparametric Mann–Whitney U test. For all statistical analyses, significance was defined as $P < .05$. The classification scheme for the correlation is defined as follows: $0 < |\rho| \leq .2$, negligible; $0.2 < |\rho| \leq .4$, low; $0.4 < |\rho| \leq .7$, moderate; $0.7 \leq |\rho|$, high.

Results

Participants' demographics

Cine-MRI was able to obtain scans of the coordinated movements of the rotator cuff with vivid clarity in all examined shoulders (Video). The mean internal and external rotational angles determined by cine-MRI were $38^\circ \pm 21^\circ$ and $14^\circ \pm 26^\circ$, respectively. The means of the Constant–Murley score (Constant score) and UCLA score were 65 ± 13 points and 18 ± 3 points, respectively. The number of patients whose shoulder pain was classified as mild, moderate, and severe was 29, 41, and 30, respectively. In addition,

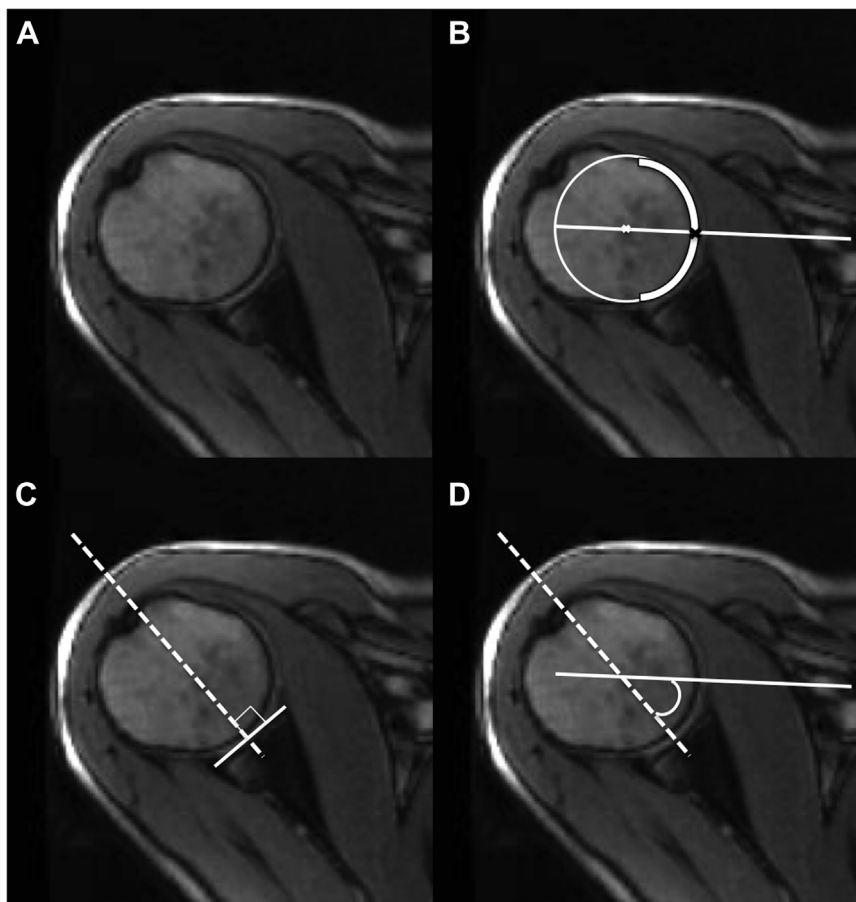


Figure 2 Determination of rotational angle on images captured using cine-magnetic resonance imaging. (A) Showed a raw figure. (B) The axis of the humeral head was defined as the line connecting the center of the humeral head and the midpoint of the humeral head surface. (C) centerline of the glenoid was defined as the line perpendicular to the surface of the glenoid fossa at its midpoint. (D) The angle of rotation was defined as the angle between the two lines, with the zero point at the intersection of the axis of the humeral head and the centerline of the glenoid.

the number of each item groups in UCLA score was 3, 31, 36, 26, and 4, respectively (Table II). In addition, the numbers of shoulders with and without night pain were 46 and 54, respectively. (Table III)

Correlation of clinical scores and rotational angles

The ER angle as determined using cine-MRI was significantly positively correlated with the Constant score (Fig. 3, A; $\rho = 0.24$, $P = .019$) as well as the UCLA score (Fig. 3, B; $\rho = 0.24$, $P = .015$), although the ρ values defined these correlations as low.

There were significant differences among the 3 pain groups in the ER angle ($P < .001$) but not in the IR angle ($P = .79$). (Table II, Fig. 4, A and B) Post hoc testing showed that the ER angle was significantly smaller in the severe pain group than in the mild and moderate pain groups (severe vs. mild, $P < .001$; severe vs. moderate, $P = .004$). In the comparison among 5 pain groups, ER angle was significantly smaller in the group 4 group than in groups 2 and 3 (group 2 vs group 4, $P < .001$; group 2 vs group 3, $P = .001$). In the analysis of the correlation between rotational angle and pain groups, the ER angle was also significantly correlated with the 3 pain groups ($\rho = -0.47$, $P < .001$) but the IR angle was not ($P = .46$). (Table II, Fig. 4, C and D) In the pain groups of UCLA score, The ER angle was significantly correlated with the 3 pain groups ($\rho = -0.41$, $P < .001$) but the IR angle was not ($P = .47$). Therefore, the correlation between both pain groups and ER angle was moderate as defined by the ρ value, although the number of groups 1

and 5 were small in the pain groups of UCLA score (group 1, $n = 3$; group 5, $n = 4$).

Glenohumeral rotational angles according to night pain

In the demographic data, there were no significant differences found in sex and affected side between shoulders with and without night pain. However, patients with night pain were significantly older than those without pain (Table III). Shoulders with night pain had smaller ER angles, determined using cine-MRI, than those without ($P = .018$); however, there was no significant difference in the IR angles ($P = .089$) (Table III, Fig. 5).

Discussion

This study revealed that glenohumeral ER with the arm adducted was significantly restricted in the shoulders with SIS and proportional to the decrease in clinical scores. Shoulders in the severe pain group showed significantly smaller ER angles than those in the mild and moderate pain groups. In addition, SIS patients with night pain had smaller ER angles of the shoulder joint compared to the ER angles of those without night pain, as determined by cine-MRI-based analysis; there was no significant difference in the demographic data except in age, to account for this finding. Our results suggest that limitation of ER in shoulders in the

Table II
Demographic data of pain groups.

Constant score	Mild (n = 29)	Moderate (n = 41)	Severe (n = 30)	P value
Age (y)	47 (range, 16-77)	52 (range, 16-81)	52 (range, 16-76)	.37
Sex	F, 8; M, 21	F, 16; M, 25	F, 9; M, 21	.56
Side	D, 18; ND, 11	D, 26; ND, 15	D, 17; ND, 13	.84
Clinical ROM				
Flexion (°)	163 ± 16	160 ± 20	150 ± 27	.16
Abduction (°)	150 ± 27	136 ± 43	122 ± 39	.048[†]
ER (°)	71 ± 14	70 ± 17	63 ± 21	.26
IR* [‡]	T10 (L3-T5)	T10 (B-T5)	T10 (B-T5)	.51
ROM determined by cine-MRI				
IR (°)	36 ± 27	38 ± 19	40 ± 19	.79
ER (°)	29 ± 18	17 ± 24	-4 ± 26	<.001[‡]

UCLA score	Group 1 (n = 3)	Group 2 (n = 31)	Group 3 (n = 36)	Group 4 (n = 26)	Group 5 (n = 4)	P value
Age (y)	50 (range, 37-63)	45 (range, 17-77)	55 (range, 19-81)	52 (range, 16-76)	52 (range, 18-64)	.37
Sex	F, 0; M, 3	F, 9; M, 22	F, 15; M, 21	F, 7; M, 19	F, 2; M, 2	.31
Side	D, 2; ND, 1	D, 21; ND, 10	D, 21; ND, 15	D, 14; ND, 12	D, 3; ND, 1	.80
Clinical ROM						
Flexion (°)	170 ± 9	164 ± 16	159 ± 21	153 ± 26	128 ± 28	.07
Abduction (°)	133 ± 31	153 ± 29	135 ± 42	123 ± 41	95 ± 13	.023[§]
ER (°)	80 ± 5	72 ± 14	68 ± 18	62 ± 22	70 ± 12	.45
IR* [‡]	T11 (L3-T7)	T9 (L3-T5)	T11 (B-T5)	T9 (B-T5)	T10 (L2-T7)	.39
ROM determined by cine-MRI						
IR (°)	36 ± 27	38 ± 19	40 ± 19	40 ± 19	40 ± 19	.79
ER (°)	11 ± 17	27 ± 20	20 ± 23	-7 ± 25	6 ± 37	<.001

F, female; M, male; D, dominant; ND, nondominant; MRI, magnetic resonance imaging; ROM, range of motion; ER, external rotation; IR, internal rotation; T, thoracic vertebra; L, lumbar vertebra; B, buttock.

Bold values showed significant difference.

* IR was determined using the vertebra reachable by the thumb.

† There was significant difference between mild and severe groups (P = .018).

‡ Severe group was significantly restricted compared with mild and moderate groups (P < .001, P = .004, respectively).

§ There was significant difference between item 5 and item 2 group (P = .044).

|| Group 4 was significantly restricted ER angle compared with groups 2 and 3 (P < .001, P = .001, respectively).

Table III
Demographic data of shoulders with or without night pain.

	With night pain (n = 46)	Without night pain (n = 54)	P value
Age (y)	55 (range, 18-81)	46 (range, 16-7)	.018
Sex	F, 14; M, 32	F, 19; M, 35	.61
Side	D, 27; ND, 19	D, 34; ND, 20	.66
Clinical ROM			
Flexion (°)	152 ± 24	163 ± 18	.008
Abduction (°)	125 ± 41	145 ± 35	.017
ER (°)	62 ± 19	74 ± 15	.001
IR* [‡]	T10 (B-T5)	T10 (L4-T5)	.84
ROM determined by cine-MRI			
IR (°)	35 ± 20	40 ± 22	.089
ER (°)	8 ± 27	20 ± 25	.018

F, female; M, male; D, dominant; ND, nondominant; ROM, range of motion; MRI, magnetic resonance imaging; ER, external rotation; IR, internal rotation; T, thoracic vertebra; B, buttock; L, lumbar vertebra.

Bold values showed significant difference.

* IR was determined using the vertebra reachable by the thumb.

adducted position, especially glenohumeral ER, can be a therapeutic target for SIS-related pain.

This study indicates that ER limitation, but not IR limitation, was strongly associated with poor functional scores, especially pain scores. Numerous authors reported that the limitation of glenohumeral ER is related to symptoms of SIS,^{12,25,27} and our findings were consistent with previous reports. The humeral head is rotated externally during elevation,^{9,12,21,25,26} and the supraspinatus and infraspinatus tendon are rubbed against the subacromial bursa while passing beneath the acromion, especially during abduction. Hallström et al¹² reported that ER during elevation decreased in shoulders with SIS. During the early phase of scaption, the ER angle is significantly smaller in shoulders with symptomatic rotator cuff tears than in normal shoulders and shoulders with asymptomatic rotator cuff tears.²¹ In this study, the abduction angle was also

significantly decreased as the pain was severe (Table II). Therefore, decreased ER may aggravate symptoms by causing the greater tuberosity to rub against the subacromial bursa during elevation, especially with abduction.

However, the ability to rotate externally may be less impaired in shoulders with IR limitation. For the arm elevation, IR of the glenohumeral joint is related with flexion rather than abduction.^{9,26} SIS-related pain occurred during abduction, such as painful arc sign.¹⁹ In this study, there was no significant difference in flexion angle among pain groups in both clinical scores. Therefore, IR dysfunction may be less associated with SIS-related pain than ER dysfunction. Since we did not analyze rotational differences during elevation, further research is needed.

Night pain has been associated with increased subacromial pressure,^{17,22,31} and this may account for the night pain observed in

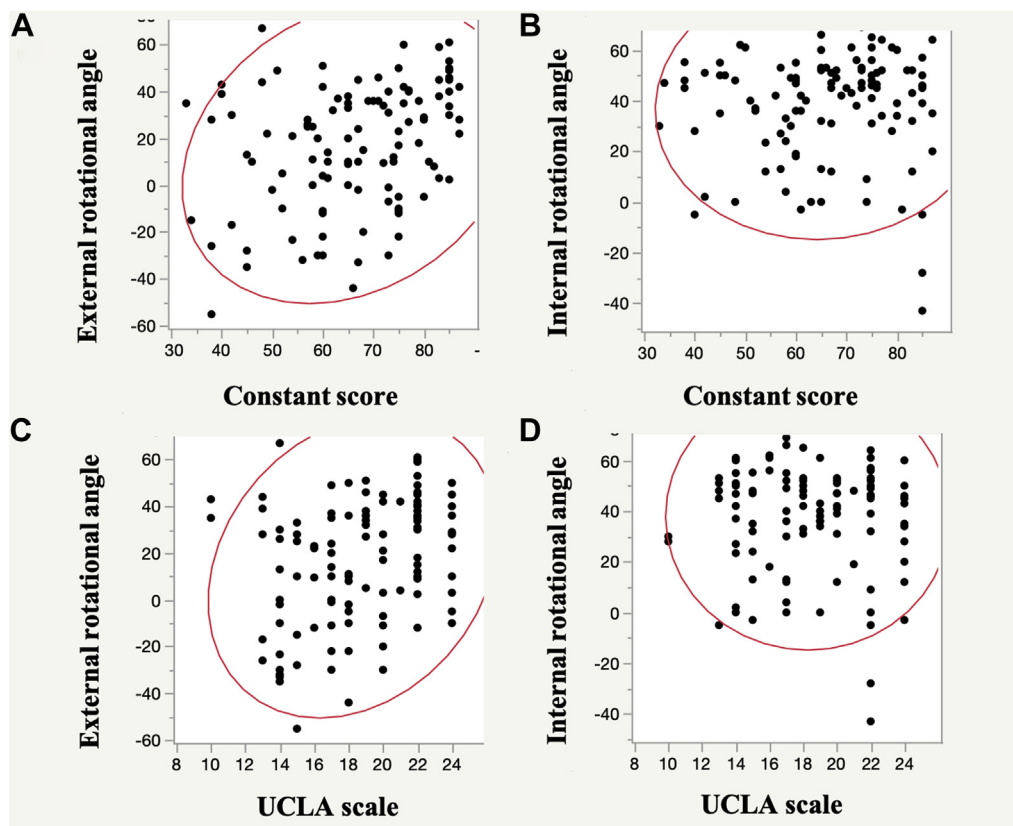


Figure 3 Correlation of clinical scores and rotational angles. (A) Correlation between the external rotation angle and the Constant–Murley score ($\rho = 0.24$, $P = .019$). (B) Correlation between the internal rotation angle and the Constant–Murley score. ($\rho = 0.12$, $P = .22$). (C) Correlation between the external rotation angle and the UCLA scale ($\rho = 0.24$, $P = .015$). (D) Correlation between the internal rotation angle and the UCLA scale ($\rho = 0.03$, $P = .79$).

this study. The subscapularis and infraspinatus muscles contribute towards keeping proper position of the humeral head to the glenoid.^{4,6,32,36,37} Werner et al⁴² reported that subacromial pressure increases IR and decreases ER. Furthermore, the amount of subacromial pressure is strongly negatively correlated with the force generated by the infraspinatus in the neutral position.⁴² These reports suggest that restriction of the glenohumeral joint's ER is associated with increased subacromial pressure in the supine position. As night pain improves rapidly once the upper body is raised to a sitting or inclined position due to an increase in subacromial space volume,^{22,31} it can be inferred from our findings that night pain may be effectively reduced using therapeutic interventions that target the external rotational dysfunction of the glenohumeral joint. Further research is needed to confirm this conjecture.

Limitations

This is a cross-sectional study. A longitudinal study that examines changes in rotational angles before and after treatment may be needed to appropriately assess the relationships between symptoms and the rotational angle. Second, we did not assess muscle activity in this study. Electromyography (EMG) may be needed; however, it is difficult to perform EMG and MRI simultaneously. Third, the diagnostic criteria for SIS in this study may be less strict as compared with the criteria in a previous report.²⁹ The horizontal impingement test suggests SIS-related pain because this maneuver requires the greater tuberosity of the humeral head

is passed below the subacromial space without rubbing against the subacromial bursa. This maneuver is similar to the Hawkins–Kennedy test with 90 degrees abduction; however, the sensitivity for the horizontal impingement test has not been reported. In this study, 87 of 100 shoulders demonstrated positive responses to the horizontal impingement test. This suggests that our criteria to diagnose patients with SIS were also sufficient. Fourth, SIS-related pain has also been associated with scapular dyskinesia,²⁰ and we did not assess scapular motion that related with SIS, such as posterior tilt during elevation. We believe this to be one of the limitations of this study. In an ideal cross-sectional study, we would have included EMG to assess muscle activity and assessed scapular motion, as well as. However, we believe that this study has established a relationship between the glenohumeral joint rotation and SIS-related pain.

Conclusion

We examined the relationship between clinical symptoms of shoulders with SIS and glenohumeral rotation using cine-MRI. Unlike IR, the ER angle of shoulders with SIS was significantly positively correlated with the Constant–Murley and UCLA scales. The ER angle of the severe pain group, in particular, was significantly smaller than that of the mild and moderate pain groups. In addition, patients with night pain had significantly restricted ER angles of the glenohumeral joint compared with the angles of those without night pain, as determined by cine-MRI-based analyses. In

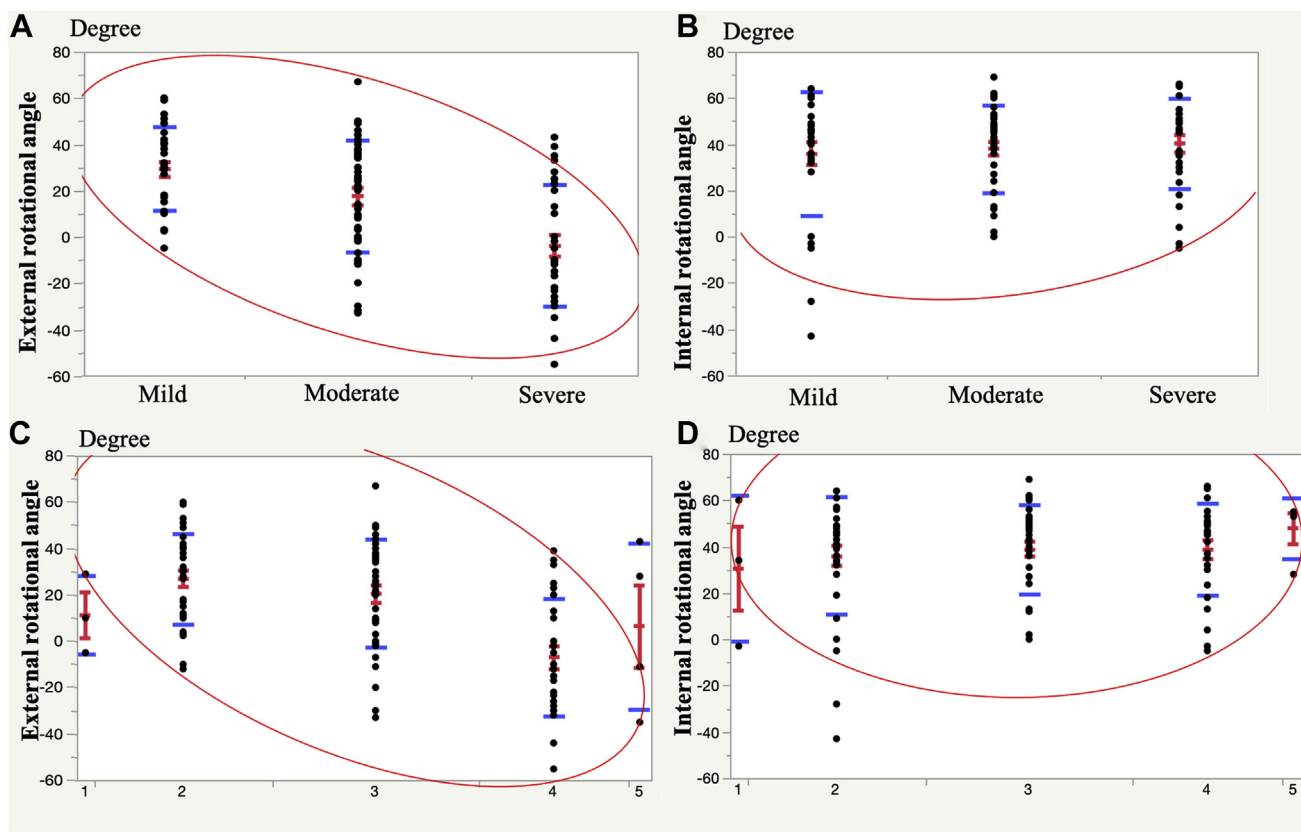


Figure 4 Comparison of rotational angle among the pain groups. (A) There were significant differences in the external rotation angle among the 3 pain groups of Constant–Murley score ($P < .001$; 95% confidence interval [CI]; mild, 21–38; moderate, 10–25; severe, -13–4). Post hoc testing revealed that the external rotation angle was significantly smaller in the severe pain group than in the mild and moderate pain groups (severe vs. mild: $P < .001$; mean difference [MD], -20; CI, -51 – -19; severe vs. moderate: $P = .004$; MD, -15; CI, -40 – -6). Correlation between the external rotation angle and the pain groups ($\rho = -0.47, P < .001$). (B) There were no significant differences in internal rotation angles ($P = .61$; 95% CI; mild, 26–42; moderate, 31–44; severe, 31–48). Correlation between the internal rotation angle and the pain groups ($\rho = 0.05, P = .59$). (C) There were significant differences in the external rotation angle among the 5 pain groups of UCLA score ($P < .001$; 95% CI; group 1, -31–54; group 2, 20–34; group 3, 13–28; group 4, -17–3; group 5, -50–63). Post hoc testing revealed that the external rotation angle was significantly smaller in the group 4 than in the groups 2 and 3 (group 4 vs. group 2: $P < .001$; MD, -20; CI, -54 – -16; group 4 vs. group 3: $P = .001$; MD, -18; CI, -49 – -10). Correlation between the external rotation angle and the pain groups ($\rho = -0.41, P < .001$). (D) There were no significant differences in internal rotation angles ($P = .79$; 95% CI; 1, -48–109; 2, 27–45; 3, 32–45; 4, 30–47; 5, 27–69). Correlation between the internal rotation angle and the pain groups ($\rho = 0.07, P = .47$). Blue bar, standard error; red bar, average and standard deviation; red ellipse, 0.90 confidence ellipse.

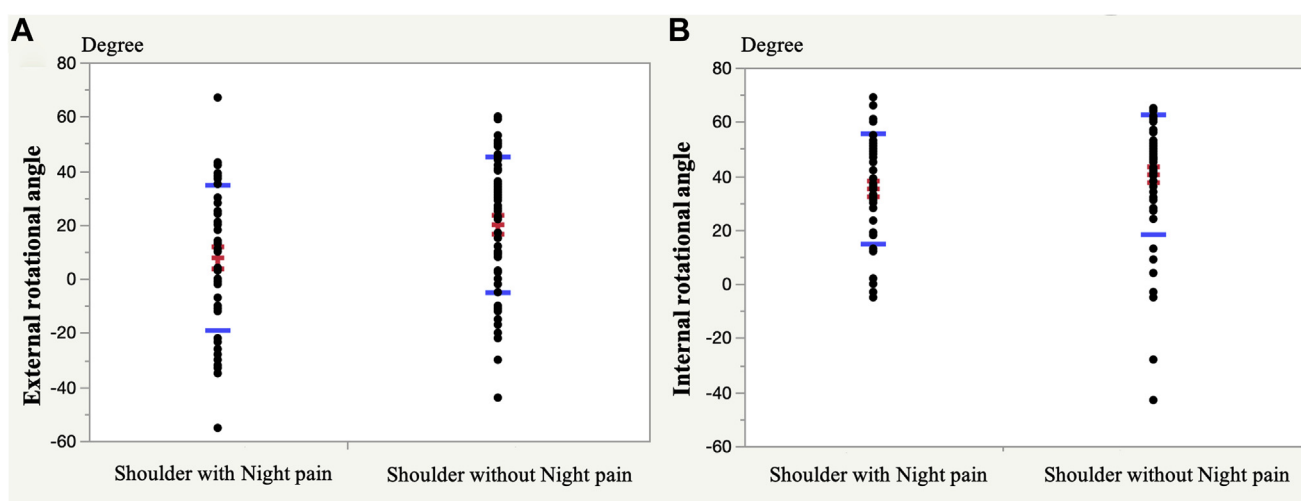


Figure 5 Comparison of the rotational angle between shoulders with and without night pain. (A) Shoulders with night pain had smaller external rotation angles than shoulders without night pain ($P = .018$; 95% confidence interval [CI]; shoulder with night pain, 0–15; shoulder without night pain, 14–27). (B) No significant difference was seen in internal rotation angles ($P = .089$; 95% CI; shoulder with night pain, 29–41; shoulder without night pain, 34–46). Blue bar, standard error; red bar, average and standard deviation.

the context of the larger body of research, our results indicate that the external rotational limitation of the glenohumeral joint is associated with pain induced by rotator cuff dysfunction. Furthermore, our findings suggest that night pain can be effectively reduced using therapeutic interventions that target the external rotational dysfunction of the glenohumeral joint.

Acknowledgments

The authors thank Yusuke Inoue (Division of Radiology, Kitasato University School of Medicine), Hideki Ikuma (Division of Radiology, Kitasato University East Hospital), Shogo Nishiyama, and Harumi Watanabe (Division of Radiology, Fuchinobe General Hospital) for administrative and technical support with the cine-MRI. They would also like to thank Editage (www.editage.com) for English language editing.

Disclaimers:

Funding: This study was partly supported by research grants from the Japan Society for the Promotion of Science (JSPS) Grant-in-Aid for Scientific Research (KAKENHI; Grant No. 25861340).

Conflicts of interest: The authors, their immediate families, and any research foundations with which they are affiliated have not received any financial payments or other benefits from any commercial entity related to the subject of this article.

Supplementary data

Supplementary data to this article can be found online at <https://doi.org/10.1016/j.jseint.2021.01.015>.

References

- Anglin C, Wyss UP, Pichora DR. Glenohumeral contact forces. *Proc Inst Mech Eng H* 2000;214:637–44.
- Barkhausen J, Ruehm SG, Goyen M, Buck T, Laub G, Debatin JF. MR evaluation of ventricular function: true fast imaging with steady-state precession versus fast low-angle shot cine MR imaging: feasibility study. *Radiology* 2001;219:264–9.
- Bigliani LU, Levine WN. Subacromial impingement syndrome. *J Bone Joint Surg Am* 1997;79:1854–68.
- Bitter NL, Clisby EF, Jones MA, Magarey ME, Jaberzadeh S, Sandow MJ. Relative contributions of infraspinatus and deltoid during external rotation in healthy shoulders. *J Shoulder Elbow Surg* 2007;16:563–8. <https://doi.org/10.1016/j.jse.2006.11.007>.
- Cave EF, Roberts SM. A method for measuring and recording joint function. *J Bone Joint Surg Am* 1936;18:455–65.
- Clisby EF, Bitter NL, Sandow MJ, Jones MA, Magarey ME, Jaberzadeh S. Relative contributions of the infraspinatus and deltoid during external rotation in patients with symptomatic subacromial impingement. *J Shoulder Elbow Surg* 2008;17:875–925. <https://doi.org/10.1016/j.jse.2007.05.019>.
- Constant CR, Murley AH. A clinical method of functional assessment of the shoulder. *Clin Orthop Relat Res* 1987;214:160–4.
- Ellman H, Hunker G, Bayer M. Repair of the rotator cuff. End-result study of factors influencing reconstruction. *J Bone Joint Surg Am* 1986;68:1136–44.
- Giphart JE, Brunkhorst JP, Horn NH, Shelburne KB, Torry MR, Millett PJ. Effect of plane of arm elevation on glenohumeral kinematics: A normative biplane fluoroscopy study. *J Bone Joint Surg Am* 2013;95:238–45. <https://doi.org/10.2106/JBJS.J.01875>.
- Gondim Teixeira PA, Balaj C, Chanson A, Lecocq S, Louis M, Blum A. Adhesive capsulitis of the shoulder: value of inferior glenohumeral ligament signal changes on T2-weighted fat-saturated images. *AJR Am J Roentgenol* 2012;198:W589–96. <https://doi.org/10.2214/ajr.11.7453>.
- Haefeli M, Elfering A. Pain assessment. *Eur Spine J* 2006;15:17–24. <https://doi.org/10.1007/s00586-005-1044-x>.
- Hallström E, Kärrholm J. Shoulder kinematics in 25 patients with impingement and 12 controls. *Clin Orthop Relat Res* 2006;448:22–7. <https://doi.org/10.1097/01.blo.0000224019.65540.d5>.
- Hanratty CE, McVeigh JG, Kerr DP, Basford JR, Finch MB, Pendleton A, et al. The Effectiveness of Physiotherapy Exercises in Subacromial Impingement Syndrome: A Systematic Review and Meta-Analysis. *Semin Arthritis Rheum* 2012;42:297–316. <https://doi.org/10.1016/j.semarthrit.2012.03.015>.
- Hawkins RJ, Kennedy JC. Impingement syndrome in athletes. *Am J Sports Med* 1980;8:151–8.
- Heitner J, Bhumireddy GP, Crowley AL, Weinsaft J, Haq SA, Klem I, et al. Clinical application of cine-MRI in the visual assessment of mitral regurgitation compared to echocardiography and cardiac catheterization. *PLoS One* 2012;7:e40491. <https://doi.org/10.1371/journal.pone.0040491>.
- Jobe FW, Moynes DR. Delineation of diagnostic criteria and a rehabilitation program for rotator cuff injuries. *Am J Sport Med* 1982;10:336–9.
- Kempf B, Kongsted A. Association between the side of unilateral shoulder pain and preferred sleeping position: A cross-sectional study of 83 Danish patients. *J Manipulative Physiol Ther* 2012;35:407–12. <https://doi.org/10.1016/j.jmpt.2012.04.015>.
- Kenmoku T, Matsuki K, Ochiai N, Sonoda M, Ishida T, Sasaki S, et al. Comparison of glenohumeral joint rotation between asymptomatic subjects and patients with subacromial impingement syndrome using cine-magnetic resonance imaging: a cross-sectional study. *BMC Musculoskelet Disord* 2019;20:475. <https://doi.org/10.1186/s12891-019-2818-3>.
- Kessel L, Watson M. The painful arc syndrome. Clinical classification as a guide to management. *J Bone Joint Surg Br* 1977;59:166–72.
- Kibler WB, Sciascia A, Wilkes T. Scapular Dyskinesia and Its Relation to Shoulder Injury Abstract. *J Am Acad Orthop Surg* 2012;30:364–72. <https://doi.org/10.5435/00124635-200303000-00008>.
- Kijima T, Matsuki K, Ochiai N, Yamaguchi T, Sasaki YY, Hashimoto E, et al. In vivo 3-dimensional analysis of scapular and glenohumeral kinematics: Comparison of symptomatic or asymptomatic shoulders with rotator cuff tears and healthy shoulders. *J Shoulder Elbow Surg* 2015;24:1817–26. <https://doi.org/10.1016/j.jse.2015.06.003>.
- Konishiike T, Hashizume H, Nishida K, Inoue H, Nagoshi M. Shoulder pain in long-term haemodialysis patients. A clinical study of 166 patients. *J Bone Joint Surg Br* 1996;78:601–5.
- Krishnan SG, Hawkins RJ, Bokor DJ. Clinical evaluation of shoulder problems. In: Rockwood CA, Matsen FA, Wirth MA, Lippitt SB, editors. *The Shoulder*. 3rd ed. Philadelphia: Saunders; 2004. p. 145–85.
- Kuechle DK, Newman SR, Itoi E, Niebur GL, Morrey BF, An KN. The relevance of the moment arm of shoulder muscles with respect to axial rotation of the glenohumeral joint in four positions. *Clin Biomech (Bristol, Avon)* 2000;15:322–9.
- Ludewig PM, Cook TM. Alterations in shoulder kinematics and associated muscle activity in people with symptoms of shoulder impingement. *Phys Ther* 2000;80:276–91.
- Ludewig PM, Phadke V, Braman JP, Hassett DR, Cieminski CJ, LaPrade RF. Motion of the shoulder complex during multiplanar humeral elevation. *J Bone Joint Surg Am* 2009;91:378–89. <https://doi.org/10.2106/JBJS.G.01483>.
- Matsen FA, Arntz CT. Subacromial impingement. In: Rockwood CA, Matsen FA, editors. *The Shoulder*. 3rd ed. Philadelphia: WB.Saunders; 1990. p. 623–36.
- Michener LA, McClure PW, Karduna AR. Anatomical and biomechanical mechanisms of subacromial impingement syndrome. *Clin Biomech* 2003;18:369–79. [https://doi.org/10.1016/S0268-0033\(03\)00047-0](https://doi.org/10.1016/S0268-0033(03)00047-0).
- Michener LA, Walsworth MK, Doukas WC, Murphy KP. Reliability and Diagnostic Accuracy of 5 Physical Examination Tests and Combination of Tests for Subacromial Impingement. *Arch Phys Med Rehabil* 2009;90:1898–903. <https://doi.org/10.1016/j.apmr.2009.05.015>.
- Neer CS 2nd. Anterior acromioplasty for the chronic impingement syndrome in the shoulder: A preliminary report. *J Bone Joint Surg Am* 1972;54:41–50.
- Okutsu I, Ninomiya S, Takatori Y, Hamaoka I, Schonholtz GJ. Coracoacromial ligament release for shoulder impingement syndrome using the Universal Subcutaneous Endoscope system. *Arthroscopy* 1992;8:2–9.
- Otis JC, Jiang CC, Wickiewicz TL, Peterson MG, Warren RF, Santner TJ. Changes in the moment arms of the rotator cuff and deltoid muscles with abduction and rotation. *J Bone Joint Surg Am* 1994;76:667–76.
- Park S, Lee DH, Yoon SH, Lee HY, Kwack KS. Evaluation of adhesive capsulitis of the shoulder with fat-suppressed T2-weighted MRI: Association between clinical features and MRI findings. *Am J Roentgenol* 2016;207:135–41. <https://doi.org/10.2214/AJR.15.15200>.
- Park SW, Chen YT, Thompson L, Kjoenoe A, Juul-Kristensen B, Cavalheri V, et al. No relationship between the acromiohumeral distance and pain in adults with subacromial pain syndrome: a systematic review and meta-analysis. *Sci Rep* 2020;10:1–14. <https://doi.org/10.1038/s41598-020-76704-z>.
- Poppen NK, Walker PS. Normal and abnormal motion of the shoulder. *J Bone Joint Surg Am* 1976;58:195–201.
- Sharkey NA, Marder RA. The rotator cuff opposes superior translation of the humeral head. *Am J Sports Med* 1995;23:270–5.
- Sharkey NA, Marder RA, Hanson PB. The entire rotator cuff contributes to elevation of the arm. *J Orthop Res* 1994;12:699–708.

38. Terabayashi N, Watanabe T, Matsumoto K, Takigami I, Ito Y, Fukuta M, et al. Increased blood flow in the anterior humeral circumflex artery correlates with night pain in patients with rotator cuff tear. *J Orthop Sci* 2014;19:744-9. <https://doi.org/10.1007/s00776-014-0604-5>.
39. Ueda Y, Sugaya H, Takahashi N, Matsuki K, Kawai N, Tokai M, et al. Rotator cuff lesions in patients with stiff shoulders: a prospective analysis of 379 shoulders. *J Bone Joint Surg Am* 2015;97:1233-7. <https://doi.org/10.2106/JBJS.N.00910>.
40. van der Windt DA, Koes BW, de Jong BA, Bouter LM. Shoulder disorders in general practice: incidence, patient characteristics, and management. *Ann Rheum Dis* 1995;54:959-64.
41. Veeger HEJ, van der Helm FCT. Shoulder function: the perfect compromise between mobility and stability. *J Biomech* 2007;40:2119-29. <https://doi.org/10.1016/j.jbiomech.2006.10.016>.
42. Werner CML, Blumenthal S, Curt A, Gerber C. Subacromial pressures in vivo and effects of selective experimental suprascapular nerve block. *J Shoulder Elbow Surg* 2006;15:319-23. <https://doi.org/10.1016/j.jse.2005.08.017>.
43. Zenian J. Sleep position and shoulder pain. *Med Hypotheses* 2010;74:639-43. <https://doi.org/10.1016/j.mehy.2009.11.013>.
44. Shoulder examination tests; Shoulderdoc. co. uk. <https://www.shoulderdoc.co.uk/section/497#staticlink>.