



First report of phaeohyphomycosis caused by *Phialophora americana* in a domestic cat from Argentina

Pablo Borrás¹, Fernando Messina² , Rubén Abrantes³, Ricardo Iachini⁴, Leonardo Minatel⁵ and Gabriela Santiso²

Journal of Feline Medicine and Surgery Open Reports
1–7

© The Author(s) 2022

Article reuse guidelines:

sagepub.com/journals-permissions

DOI: 10.1177/20551169221077611

journals.sagepub.com/home/jfmsopenreports

This paper was handled and processed by the American Editorial Office (AAFP) for publication in *JFMS Open Reports*



Abstract

Case summary A 10-year-old male neutered domestic shorthair cat from Quilmes (Province of Buenos Aires, Argentina) presented at the Infectious Diseases and Parasitology Unit with a hyperpigmented nodule of 5 cm diameter on the nasal plane with a small ulceration of more than 1 year's evolution. A scaly and hyperpigmented alopecic lesion of 3 cm in diameter was found on the lower edge of the tail. The patient was under immunosuppressive therapy with corticosteroids for lymphoplasmacytic duodenitis. Samples of the lesion present on the nasal plane were taken under a surgical procedure. In the wet mount preparations, pigmented irregular hyphae were observed. They developed dark colonies when cultured on Sabouraud medium. On micromorphology, structures compatible with *Phialophora* species were identified. PCR and sequencing of *ITS* (*ITS1-5.8S-ITS2*) confirmed *Phialophora americana* as the etiologic agent. A therapeutic scheme that included a combination of itraconazole oral solution (1.5 mg/kg PO q12h) with terbinafine (30 mg/kg PO q24h) was indicated for a period of 10 months. The patient died of complications resulting from its underlying disease.

Relevance and novel information As far as the authors are aware, this is the first study to report *P americana* as an etiologic agent of phaeohyphomycosis in cats. In this case study, the species was identified using molecular tests.

Keywords: *Phialophora americana*; phaeohyphomycosis; rare opportunistic mycoses; molecular identification

Accepted: 16 January 2022

Introduction

Phaeohyphomycosis encompasses a heterogeneous group of mycoses that can affect humans, plants and animals. The different fungi that produce this opportunistic infection have the peculiarity of presenting melanin in their cell walls (dematiaceous fungi).

The most frequently found species in cats are *Exophiala*, *Fonsecaea*, *Macrophomina*, *Microspora*, *Moniliella*, *Phialophora*, *Phoma*, *Scolecobasidium* and *Stemphylium*.¹ In domestic cats, these conditions are reported in association with basic immunosuppression or when these animals receive long-term immunosuppressive therapy with agents such as glucocorticoids and ciclosporin.^{1,2} This group of fungi enter the skin by traumatic inoculation from the environment, generating conditions of inflammatory origin and chronic evolution. The lesions are nodular, often hyperpigmented and they tend to ulcerate. Occasionally, and depending on

the animal's immunity, they can affect other tissues or organs. Antifungal therapy must be administered for

¹Infectious Diseases and Parasitology Unit, Panda Veterinary Clinic, Buenos Aires, Argentina

²Mycology Unit, Francisco Javier Muñoz Infectious Diseases Hospital, Buenos Aires, Argentina

³Superficial Mycoses and Mycelial Fungi Service, Mycology Department, INEI ANLIS 'Dr Carlos G Malbrán', Buenos Aires, Argentina

⁴Biochemical and Microbiological Lab, Instituto de Zoonosis 'Luis Pasteur', Buenos Aires, Argentina

⁵Veterinary Pathology, Faculty of Veterinary Sciences, University of Buenos Aires, Buenos Aires, Argentina

Corresponding author:

Pablo Borrás DVM, MSc, Infectious Diseases and Parasitology Unit, Panda Veterinary Clinic, Ruiz Huidobro 4771, Buenos Aires C1430CKF, Argentina

Email: pablojesusborras@gmail.com



Creative Commons Non Commercial CC BY-NC: This article is distributed under the terms of the Creative Commons

Attribution-NonCommercial 4.0 License (<https://creativecommons.org/licenses/by-nc/4.0/>) which permits non-commercial use, reproduction and distribution of the work without further permission provided the original work is attributed as specified on the SAGE and Open Access pages (<https://us.sagepub.com/en-us/nam/open-access-at-sage>).

several months and even combined with surgical procedures.¹⁻³ Some patients may have recurrences once the treatment has been completed.⁴

The purpose of this case report is to describe, for the first time, *Phialophora americana* as a causal agent of phaeohyphomycosis in a cat from Argentina.

Case description

A 10-year-old male neutered domestic shorthair cat from Quilmes (Province of Buenos Aires, Argentina) presented at the Infectious Diseases and Parasitology Unit (Panda Veterinary Clinic) with a hyperpigmented nodule of 5 cm diameter on the nasal plane with a small ulceration of more than 1 year's evolution. A scaly and hyperpigmented alopecic lesion of 3 cm in diameter was found on the lower edge of the tail (Figure 1). The patient had been previously diagnosed with inconclusive subcutaneous mycosis, for which it had been treated with itraconazole (10 mg/kg PO q24h) for a period of 1 year.

The patient had also been diagnosed 6 years before with lymphoplasmacytic duodenitis detected by histopathology of the duodenal mucosa obtained by endoscopy, and was therefore undergoing immunosuppressive therapy. Prednisolone had been prescribed as immunosuppressive therapy at doses that varied between 1 and 2 mg/kg PO q12h, depending on the clinical response of the patient. Both feline immunodeficiency virus and feline leukemia virus had been ruled out by PCR and rapid immunochromatography test (SPEED DUO FeLV-FIV) on several occasions.

Among the supplementary methods at the time of consultation, complete blood count revealed normochromic normocytic anemia and neutrophilia with a left shift. Blood chemistry was within the normal parameters. No skull radiography was performed, and abdominal ultrasound showed enteritis and mild hepatomegaly.

It was decided that treatment with itraconazole would be suspended for 15 days. In addition, samples of the lesion on the nasal plane were taken under a surgical procedure as a diagnostic and therapeutic tool. Some of the samples were submitted in 10% formalin for histopathologic examination and others were prepared by adding physiologic solution for mycologic examination. The samples for microbiologic examination were sent to the Mycology Unit of the Hospital de Infecciosas Francisco Javier Muñiz.

Histology tests revealed a severe chronic focal pyogranulomatous dermatitis consisting of neutrophils, macrophages and granulation tissue, with a few giant cells. There was a moderate number of lymphocytic and plasma cells. The pyogranulomas contained a small number of pleomorphic yeasts and many pigmented, septate and torulose hyphae with irregular walls, both free and within macrophages and giant cells. Both yeasts and irregular hyphae had brown walls with hematoxylin and eosin, which were highlighted with periodic acid-Schiff stain and negative staining. The yeasts were between 5 and 25 µm in diameter. The lesion was well defined but not encapsulated and had a fistulous tract in the middle (Figure 2).

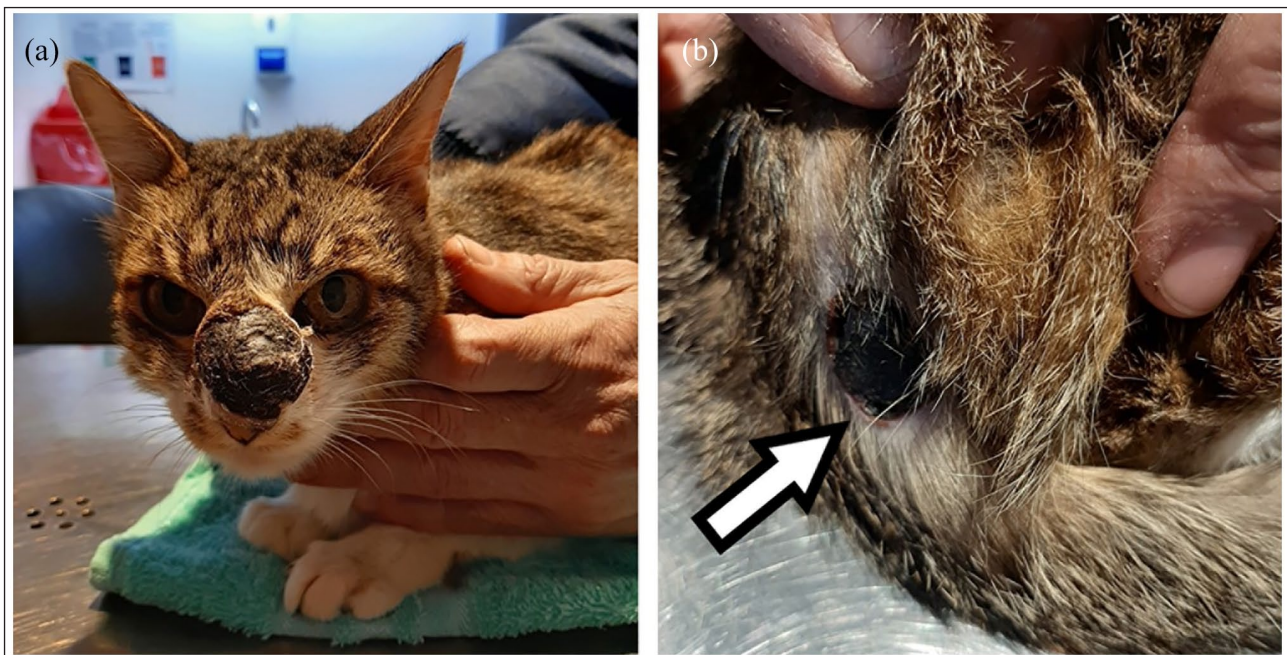


Figure 1 (a) Hyperpigmented nodule of 5 cm in diameter on the nasal plane of the patient. (b) Scaly and hyperpigmented alopecic lesion of 3 cm in diameter on the lower edge of the tail (arrow)

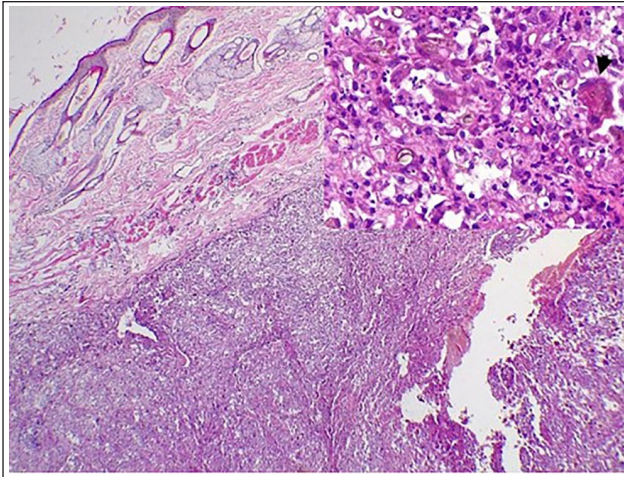


Figure 2 Focal pyogranulomatous dermatitis with subcutaneous tissue involvement and part of a fistulous pathway (hematoxylin and eosin). Insert: pleomorphic yeast with pigmented walls between the inflammatory cells. Note the phagocytic multinucleated giant cells with negative staining microorganisms (arrowhead)

Pigmented hyphae were found in the microscopic examinations of wet mount preparations from samples of the nasal lesion (Figure 3) and in the Giemsa stain from the same samples (Figure 4).

The samples were cultured on Sabouraud agar, brain heart infusion agar and glycerinated agar, and incubated at 28°C and 37°C. Between the second and third weeks, the development of flat velvety dark-brown colonies was observed. After the dissociation of these colonies, pigmented hyphae and phialides with collarettes were found. These morphologic characteristics allowed us to obtain a preliminary identification of the fungus as *Phialophora* species. For definitive identification, the strain was sent to INEI ANLIS 'Dr Carlos G Malbrán', where culture characteristics and microscopic morphology were studied in potato dextrose agar (Figure 5), and a partial portion of rDNA of *ITS* was sequenced (*ITS1-5.8S-ITS2*). An NCBI BLAST search using the *ITS* sequence (DMic 206208 [622 base pairs]) identified it as *P americana*, with a similarity of 99.4%, a coverage of 100% and an E value of 0.0 with strain CDC-5 (accession U31837.1). *ITS* sequences of the DMic 206208 isolate were aligned with sequences belonging to *Phialophora* species deposited in GenBank and used to construct the phylogenetic tree (Figure 6). Although there are no established breakpoints available in veterinary medicine for these organisms, antifungal susceptibility testing was performed (Table 1).⁵

A therapeutic scheme that included a combination of itraconazole oral solution (1.5 mg/kg PO q12h)⁶ associated with terbinafine (30 mg/kg PO q24h) was prescribed

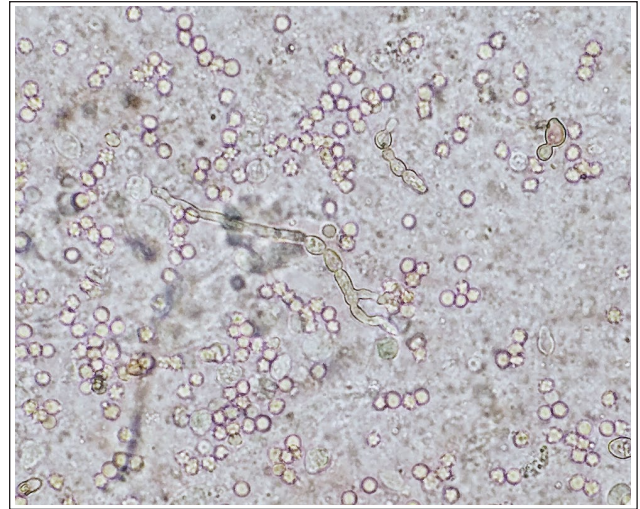


Figure 3 Wet mount preparation examinations: pigmented hyphae were observed

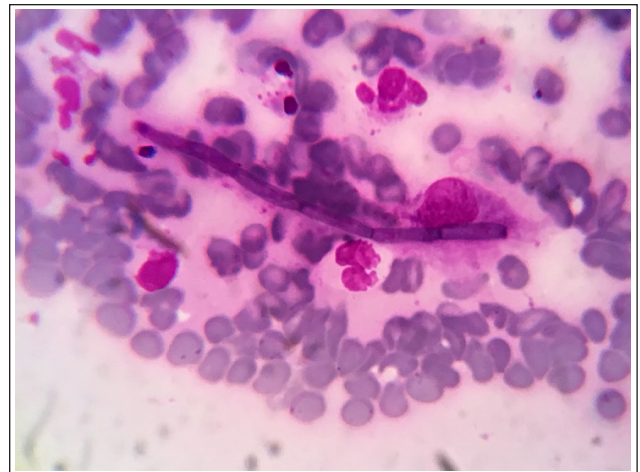


Figure 4 Septate hyphae detected by Giemsa staining

for a period of 10 months. The use of posaconazole was ruled out due to the cost of the drug for prolonged therapy. The patient showed a period of improvement in the first 5 months. Owing to the cat's underlying disease and the immunosuppressive treatment, 6 months after the initiation of treatment, relapse was observed in the lesions on the nasal plane and at the base of the tail, alternating with brief periods of clinical improvement. A second surgery with the aim of debulking the main nasal lesion could not be performed due to the general clinical condition of the cat. Finally, the cat experienced complications as a result of its underlying disease that included anorexia, abdominal pain, vomiting and diarrhea, and was unresponsive to conventional treatments for 2 weeks. The owners decided to euthanize the cat at this point.

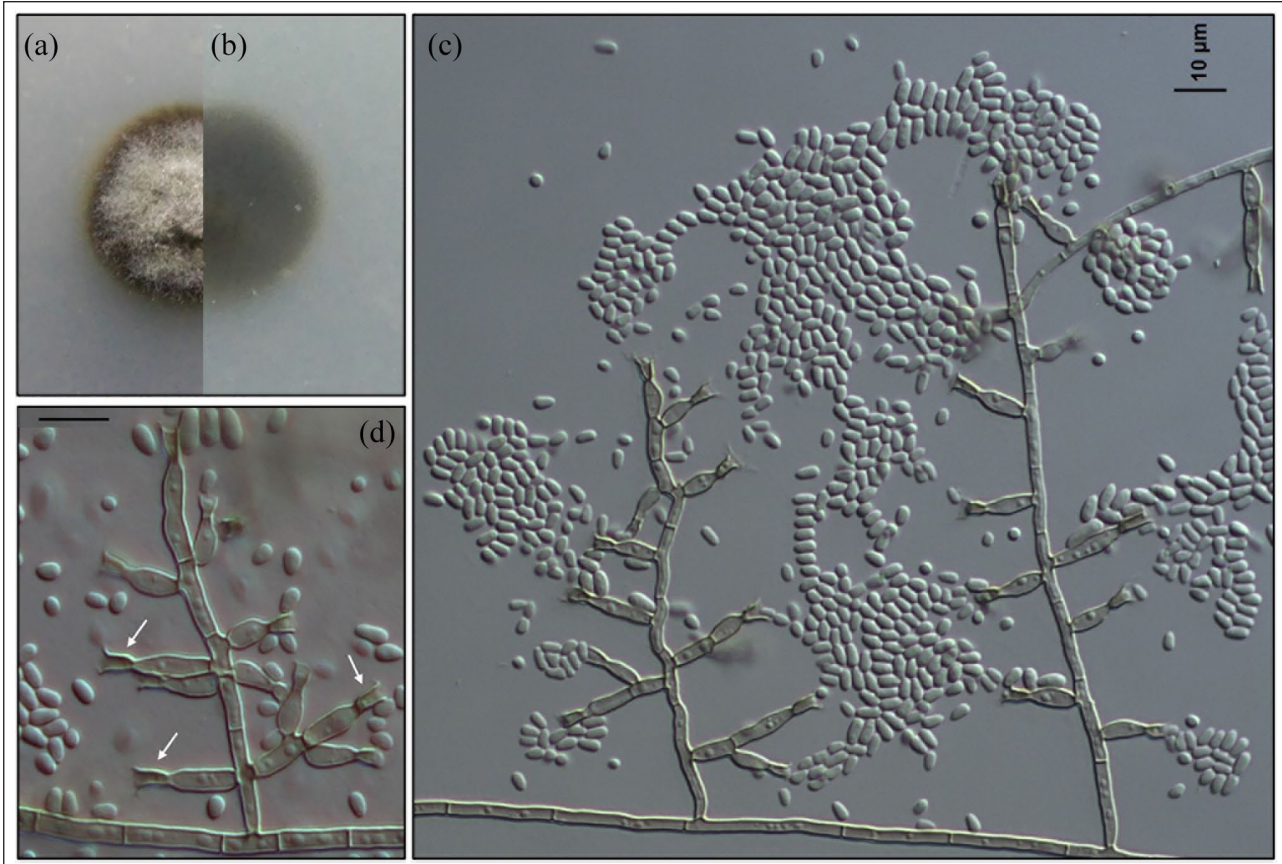


Figure 5 *Phialophora americana* DMic 206208. Colony on potato dextrose agar [(a) surface; (b) reverse] after 7 days at 25°C. Conidiogenous (c) cells and (d) conidia. Arrows indicate conspicuous collarettes at the top of conidiogenous cells. Bars = 10 µm

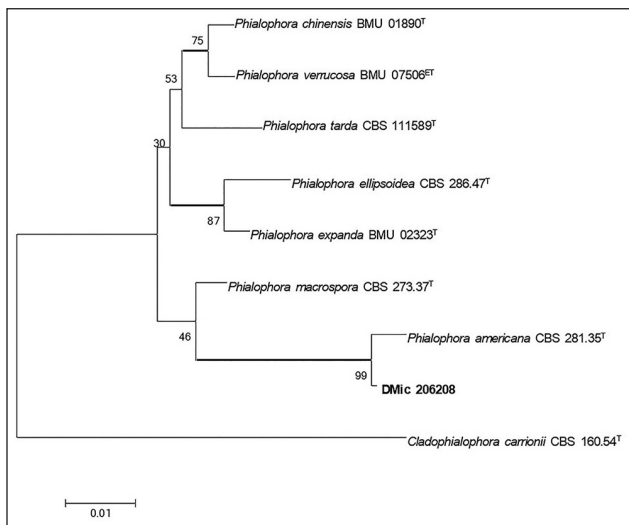


Figure 6 Phylogenetic tree inferred from maximum-likelihood analysis of partial *ITS* sequences (552 base pairs). DMic 206208 strain located in the clade *Phialophora americana*. The tree was generated from 1000 replicates, and the Kimura two-parameter model was selected as the best-fit model of nucleotide substitution. The bar length represents 0.01 substitution per site. Bootstrap percentages are shown at the respective node. ^T = type strain

Table 1 Antifungal susceptibility data for the *Phialophora americana* isolate cultured from the cat

Drug	Inhibitory concentration (µg/ml)
Amphotericin B	0.5
Itraconazole	0.125
Isavuconazole	2
Voriconazole	0.25
Posaconazole	0.06
Anidulafungin	0.03
Caspofungin	0.25
Micafungin	0.032
Terbinafine	0.015

Discussion

To the authors' knowledge, this is the first report of phaeohyphomycosis produced by *P americana* in an immunocompromised cat.

Clinical signs of phaeohyphomycosis in cats are associated with granulomatous skin lesions that are generally pigmented, which can be confused with melanoma.⁷⁻⁹ Although it is not frequent, there may be systemic dissemination with compromise of the central nervous

system.¹ The patient in question had lesions similar to those described previously in the literature, with manifestations in different parts of the body, either due to local spread or continuous exposure to the fungal agent.

Phaeohyphomycosis in dogs and cats is associated with an immunosuppressive component, whether from an underlying cause or due to treatment. Prolonged use of corticosteroids produces an inhibition of the T helper 1 (Th1) response, which is essential in controlling the clinical signs of fungal etiology.² In the present case, treatment with prednisolone at immunosuppressive doses had been prescribed for years as a therapy for lymphoplasmacytic duodenitis. This favored the evolution of the disease and probably generated a poor and intermittent response to antifungal agents.

Thanks to the application of molecular methods, *P americana* was identified as the causative agent in this clinical case. There are isolated reports of *Phialophora verrucosa* as a causal agent of phaeohyphomycosis in cats.^{7,10} Although *P americana* has been described as the etiologic agent of this condition in humans,¹¹ to date, there are no records in cats.

Seven phylogenetic species of *Phialophora* have been identified on a molecular basis: *P verrucosa*, *P americana*, *Phialophora chinensis*, *Phialophora ellipsoidea*, *Phialophora expanda*, *Phialophora macrospora* and *Phialophora dela*. Together, these species make up the 'Phialophora verrucosa species complex'.^{12,13} They are morphologically similar but with some variations in growth rate and subtle differences in the shape of the phialides and their collarettes.¹² However, *P americana* tends to have deeper collarettes than the other species in the complex.¹⁴

In a study of the biodiversity of clinical and environmental strains using molecular tools,¹² of 118 strains previously identified morphologically as *P verrucosa*, only six belonged to that species and about 50 strains were identified as *P americana*.¹²

Morphological differences between the *Phialophora* species are not easy to distinguish; therefore, in medical healthcare centers where identification is by phenotypic methods, the isolates that come from clinical cases are usually attributed to *P verrucosa*.¹⁵

Unlike *Cladophialophora carrionii* and *Fonsecaea* species, which exclusively produce chromoblastomycosis, *P verrucosa* (and other species of *Phialophora*) produces a wide range of clinical conditions in humans, such as subcutaneous and disseminated phaeohyphomycosis, eumycetoma, keratitis and endophthalmitis.¹⁵

Different therapeutic alternatives have been used in humans and animals with these mycoses, such as itraconazole, voriconazole, posaconazole and even intravenous treatments with amphotericin B or echinocandins.^{1,2,4} Currently, isavuconazole appears to have a favorable sensitivity profile, at least in vitro.¹⁶ Itraconazole or posaconazole are reported as a first option in the medical

treatment of phaeohyphomycosis in combination with other antifungal drugs.^{1,2,17} In this case, posaconazole could not be used because the owners were unable to afford the cost of a long-term treatment.

Although isolation of the agent makes it possible to determine the antifungal sensitivity in vitro, the discrepancy between the in vitro results and the in vivo effectiveness in phaeohyphomycosis has been described previously.^{15,18,19} Its use as a tool in therapeutic protocols is limited for fungi producing phaeohyphomycosis. On the one hand, it is a valid option to perform it, at least to select the antifungal treatment and evaluate the response in vivo. On the other hand, antifungals have a reduced effect on phaeohyphomycosis since the hyphae have high amounts of melanin, which contributes to fungal virulence.²⁰ The treatment of choice in phaeohyphomycosis includes surgical excision of the local lesions and the use of antifungal agents.^{2,3} Reducing immunosuppressive treatment where possible is also important in treating these types of cases. In the present case, antifungal treatment and partial surgery of the nasal lesion were opted for because complete excision was a difficult procedure to perform in the compromised anatomic area and the owners declined invasive surgery. In cases where an aggressive surgical excision cannot be performed, debulking is an essential option in association with the use of systemic antifungals.^{3,21} In the present case, a second surgery with the aim of debulking the main nasal lesion could not be performed in the middle of the therapy, which complicated the response to antifungal treatment. The use of a combination of itraconazole and terbinafine has recently been reported for the treatment of a cat with phaeohyphomycosis caused by *Cladophialophora* species.³ Although the clinical response was highly variable, good results were obtained for as long as it could be applied appropriately. The use of itraconazole in oral solution was useful because it allowed administration of a lower dose due to the high bioavailability that this formulation presents in cats.⁶ Therefore, the combination of antifungal drugs would be a valid option in patients in which a surgical procedure cannot be performed.

In human cases of phaeohyphomycosis due to dematiaceous fungi with chromoblastomycosis and extensive lesions or poor response to itraconazole, combined treatment with 5-fluorocytosine or terbinafine is usually prescribed.²² Another possible therapeutic option for phaeohyphomycosis in cats would be the use of intralésional amphotericin B, as reported in the literature for the treatment of other skin and subcutaneous mycoses,²³ such as sporotrichosis,^{24,25} especially in refractory cases, in combination with azoles.^{24,25} Strategies with other azoles, other than itraconazole or posaconazole, have also been used.²⁶ The use of voriconazole in cats has been proposed as a first-line treatment.² However, the

clinical recurrence when stopping treatment, as well as the cost of the medication, does not favor its use as the drug of choice.⁴

Conclusions

Phaeohyphomycosis in cats is a rare opportunistic mycosis that should be considered in patients with single or multiple hyperpigmented skin lesions that do not respond to conventional treatments. The application of effective antifungal protocols is challenging on account of the few reported clinical cases, the long duration of treatment, the variable clinical response, the presence of comorbidities and the degree of involvement shown by pet owners.

Acknowledgements The authors would like to thank Mariano Anaya (Surgery Unit, Panda Veterinary Clinic) and Alejandra Fiorentino (Oncología e inmunología Veterinaria Alejandra Fiorentino).

Conflict of interest The authors declared no potential conflicts of interest with respect to the research, authorship, and/or publication of this article.

Funding The authors received no financial support for the research, authorship, and/or publication of this article.

Ethical approval The work described in this manuscript involved the use of non-experimental (owned or unowned) animals. Established internationally recognized high standards ('best practice') of veterinary clinical care for the individual patient were always followed and/or this work involved the use of cadavers. Ethical approval from a committee was therefore not specifically required for publication in *JFMS Open Reports*. Although not required, where ethical approval was still obtained, it is stated in the manuscript.

Informed consent Informed consent (verbal or written) was obtained from the owner or legal custodian of all animal(s) described in this work (experimental or non-experimental animals, including cadavers) for all procedure(s) undertaken (prospective or retrospective studies). For any animals or people individually identifiable within this publication, informed consent (either verbal or written) for their use in the publication was obtained from the people involved.

ORCID iD Fernando Messina  <https://orcid.org/0000-0003-3062-7851>

References

- Lloret A, Hartmann K, Pennisi MG, et al. **Rare opportunistic mycoses in cats: phaeohyphomycosis and hyalohyphomycosis: ABCD guidelines on prevention and management.** *J Feline Med Surg* 2013; 15: 628–630.
- Dedeaux A, Grooters A, Wakamatsu-Utsuki N, et al. **Opportunistic fungal infections in small animals.** *J Am Anim Hosp Assoc* 2018; 54: 327–337.
- Brooks IJ, Walton SA, Shmalberg J, et al. **Novel treatment using topical malachite green for nasal phaeohyphomycosis caused by a new *Cladophialophora* species in a cat.** *JFMS Open Rep* 2018; 4. DOI: 10.1177/2055116918771767.
- Evans N, Gunew M, Marshall R, et al. **Focal pulmonary granuloma caused by *Cladophialophora bantiana* in a domestic short haired cat.** *Med Mycol* 2011; 49: 194–197.
- Clinical and Laboratory Standards Institute. Reference method for broth dilution antifungal susceptibility testing of filamentous fungi. 3rd ed. Wayne, PA: Clinical and Laboratory Standards Institute, 2017.
- Sykes J and Papich M. **Antifungal drugs.** In: Sykes J (ed). *Canine and feline infectious diseases.* St Louis, MO: Elsevier, 2013, pp 87–96.
- Beccati M, Vercelli A, Peano A, et al. **Phaeohyphomycosis by *Phialophora verrucosa*: first European case in a cat.** *Vet Rec* 2005; 57: 93–94.
- Fondati A, Gallo MG, Romano E, et al. **A case of feline phaeohyphomycosis due to *Fonsecaea pedrosoi*.** *Vet Dermatol* 2001; 12: 297–301.
- Krockenberger MB, Martin P, Halliday C, et al. **Localised *Microsphaeropsis arundinis* infection of the subcutis of a cat.** *J Feline Med Surg* 2010; 12: 231–236.
- Dion WM, Pukay BP and Bundza A. **Feline cutaneous phaeohyphomycosis caused by *Phialophora verrucosa*.** *Can Vet J* 1982; 23: 48–49.
- Huang C, Zhang Y, Song Y, et al. **Phaeohyphomycosis caused by *Phialophora americana* with CARD9 mutation and 20-year literature review in China.** *Mycoses* 2019; 62: 908–919.
- Li Y, Xiao J, de Hoog GS, et al. **Biodiversity and human-pathogenicity of *Phialophora verrucosa* and relatives in *Chaetothyriales*.** *Persoonia* 2017; 38. DOI: 10.3767/003158517X692779
- Song Y, Menezes da Silva N, Vicente VA, et al. **Comparative genomics of opportunistic *Phialophora* species involved in divergent disease types.** *Mycoses* 2021; 64: 555–568.
- De Hoog S, Weenink XO and van den Ende BG. **Taxonomy of the *Phialophora verrucosa* complex with the description of two new species.** *Stud Mycol* 1999; 43: 107–122.
- Ahmed SA, Bonifaz A, González GM, et al. **Chromoblastomycosis caused by *Phialophora* – proven cases from Mexico.** *J Fungi* 2021; 7: 95. DOI: 10.3390/jof7020095.
- Lewis RE, Wurster S, Beyda ND, et al. **Comparative in vitro pharmacodynamic analysis of isavuconazole, voriconazole, and posaconazole against clinical isolates of aspergillosis, mucormycosis, fusariosis, and phaeohyphomycosis.** *Diagn Microbiol Infect Dis* 2019; 95: 114861. DOI: 10.1016/j.diagmicrobio.2019.06.013.
- Daly JA, Hubka V, Kubátová A, et al. **Feline disseminated cutaneous phaeohyphomycosis due to *Exophiala spinifera*.** *Med Mycol Case Rep* 2019; 27: 32–35.
- Vitale RG, De Hoog GS and Verweij PE. **In vitro activity of amphotericin B, itraconazole, terbinafine and 5-fluorocytosine against *Exophiala spinifera* and evaluation of post-anti-fungal effects.** *Med Mycol* 2003; 41: 301–307.
- Overy DP, Martin C, Muckle A, et al. **Cutaneous phaeohyphomycosis caused by *Exophiala attenuata* in a domestic cat.** *Mycopathologia* 2015; 180: 281–287.

- 20 Revankar SG, Sutton DA and Rinaldi MG. **Primary central nervous system phaeohyphomycosis: a review of 101 cases.** *Clin Infect Dis* 2004; 38: 206–216.
- 21 Bentley RT, Faissler D and Sutherland-Smith J. **Successful management of an intracranial phaeohyphomycotic fungal granuloma in a dog.** *J Am Vet Med Assoc* 2011; 239: 480–485.
- 22 Chowdhary A, Meis JF, Guarro J, et al. **ESCMID and ECMM joint clinical guidelines for the diagnosis and management of systemic phaeohyphomycosis: diseases caused by black fungi.** *Clin Microbiol Infect* 2014; 20 Suppl 3: 47–75.
- 23 Malik R, Krockenberger MB and O'Brian CR. **Intralesional amphotericin B – worth a try, maybe for lots of things, but we need more data.** *J Feline Med Surg* 2009; 11: 621–623.
- 24 Gremiao ID, Schubach TM, Pereira SA, et al. **Intralesional amphotericin B in a cat with refractory localised sporotrichosis.** *J Feline Med Surg* 2009; 11: 720–723.
- 25 Gremiao I, Schubach T, Pereiras S, et al. **Treatment of refractory feline sporotrichosis with a combination of intralesional amphotericin B and oral itraconazole.** *Aust Vet J* 2011; 89: 346–351.
- 26 Santos DWCL, de Azevedo CMPES, Vicente VA, et al. **The global burden of chromoblastomycosis.** *PLoS Negl Trop Dis* 2021; 15: e0009611. DOI: 10.1371/journal.pntd.0009611.