

Estimation of silver nucleolar organizer regions in oral lichen planus, oral lichenoid reactions and oral lichenoid dysplasia

J Chandrakala, M Vidya, S Hemavathy¹, Sahana Srinath, T Suresh, T Satish Yadav

Department of Oral Pathology, Government Dental College and Research Institute, ¹Department of Oral Pathology, Sri Rajiv Gandhi College of Dental Sciences and Hospital, Bengaluru, Karnataka, India

Abstract

Aims and Objective: (1) To study the clinical and histological features of oral lichen planus, oral lichenoid reaction (OLR) and oral lichenoid dysplasia (OLD). (2) To estimate and compare the silver nucleolar organizer regions in OLR and OLD.

Materials and Methods: A total of 40 biopsies were studied; sections were divided as study group, which consists of OLP, OLR and OLD each of 10 cases and 10 biopsies of normal oral mucosa as control group. Sections were stained by silver staining technique and total number of silver stained nucleolar organizer regions (AgNORs) were counted in nucleoli of 100 cells in each section under x100 objective (oil immersion).

Results: Our study revealed that the difference between the (AgNOR) count of OLP (2.272 ± 0.09) and OLR (2.27 ± 0.073) is not statistically significant ($P = 0.81$). The mean AgNOR count of OLD (2.388 ± 0.043) compared to that of OLP (2.272 ± 0.09) and OLR (2.27 ± 0.073) showed an increase and it is statistically highly significant ($P = 0.002$ and $P = 0.003$, respectively).

Conclusion: AgNOR count is an objective test, which has stronger biological basis for diagnosing epithelial dysplasia. It is easy to perform, inexpensive and is performed on biopsied specimen. However, this technique cannot differentiate OLP and OLR, as there is no much difference in the proliferative activity of cells in these two lesions. It is reasonable to suggest that all biopsy tissues from lichenoid lesions where dysplastic features are observed in routine histopathological sections should be additionally stained by silver technique to ascertain dysplastic status of the lesion.

Clinical Significance: This is an improved diagnostic parameter, which will help pathologists to formulate more definitive final histopathological diagnosis and will in turn facilitate the formulation of patient treatment and follow-up care by clinicians.

Keywords: Lichen planus, oral lichen planus, oral lichenoid dysplasia, oral lichenoid reaction

Address for correspondence: Dr. J Chandrakala, Department of Oral Pathology, Government Dental College and Research Institute, Bengaluru - 560 002, Karnataka, India.

E-mail: kalamds@gmail.com

Received: 20.03.2017, **Accepted:** 21.09.2017

Access this article online

Quick Response Code:



Website:

www.jomfp.in

DOI:

10.4103/jomfp.JOMFP_69_14

This is an open access article distributed under the terms of the Creative Commons Attribution-NonCommercial-ShareAlike 3.0 License, which allows others to remix, tweak, and build upon the work non-commercially, as long as the author is credited and the new creations are licensed under the identical terms.

For reprints contact: reprints@medknow.com

How to cite this article: Chandrakala J, Vidya M, Hemavathy S, Srinath S, Suresh T, Yadav TS. Estimation of silver nucleolar organizer regions in oral lichen planus, oral lichenoid reactions and oral lichenoid dysplasia. J Oral Maxillofac Pathol 2017;21:454.

INTRODUCTION

Oral lichen planus, oral lichenoid reaction (OLR) and oral lichenoid dysplasia (OLD) are three different entities with close resemblance in clinical and histological appearance but differ in etiology, pathogenesis and biological behavior.

Many lesions may be remarkably similar to oral lichen planus clinically and yet have significant histologic differences. However, lesional distribution, concurrent skin involvement, similar but unique light microscopic findings help in discriminating oral lichen planus from other oral lichenoid lesions.^[1]

The clinical criteria include the bilateral presence of symmetrical lesions and white reticular lesions. The lesions may be atrophic, erosive, bullous or manifest in the form of plaque, appearing along with reticular lesions in a given area of the oral cavity. The histological criteria include the existence of a band of lymphocytic inflammatory infiltrate in the subepithelial connective tissue, hydropic degeneration of the basal layer and the absence of epithelial dysplasia. If both criteria are met, it is considered a typical lichen planus^[2-4] [Figure 1].

The occurrence of lesions having clinical and histopathological features of lichen planus, but apparently induced by drugs, has been recognized for some time. A significant number of them may be associated with metal restorations. The oral lesions that mimic the classical type of lichen planus have been described as OLR. There is as yet no specific test for OLR, although resolution on withdrawal and recurrence on reexposure to the drug is probably diagnostic.^[5] The histopathological confirmation of a lichenoid reaction is difficult if not possible. The subepithelial infiltrate however is not band like in appearance as in LP but instead extends more deeply into

the underlying connective tissue. It has been suggested that the presence of a mixed subepithelial infiltrate, in contrast to the strict lymphohistocytic infiltrate that defines OLP, and a deeper more diffuse distribution within the lamina propria and superficial submucosa is as marker of a drug related lichenoid oral lesions^[5] [Figure 2].

Epithelial maturational disturbance with cellular aberrations that range from mild atypia to frank dysplasia, which is recognized in a lichenoid lesion, has been categorized as a separate entity by Krutchkoff and Eisenberg in 1985 and termed it as OLD.^[6] In any oral lichenoid lesions whether reactive or dysplastic, the presence of localized mononuclear cell infiltration within the superficial lamina propria merely indicates cellular immune recognition of antigenically altered epithelium. Such alterations occur in response to many different insults that indicate physical trauma, the action of chemicals, drugs, food and microorganisms.^[7]

The crucial determinant that allows separation of OLD from OLP is the additive presence in the former of dysplastic features within the overlying epithelium. Such features are often subtle and include increased nuclear size, usually manifested by increased nuclear–cytoplasmic ratio, nuclear pleomorphism, nuclear hyperchromasia, disturbed or disorderly maturation, lack of cellular cohesion, often manifested by marked intercellular edema, increased or abnormal mitosis and blunt club shaped or “tear– drop–” shaped rete pegs [Figure 3]. The presence of any two or more of these features in an otherwise lichenoid lesion mandates separate consideration and is sufficient to rule out a diagnosis of an unembellished LP regardless of the form or character or coincident lichenoid features.^[6] Review of many cases and much histologic material has led to the conclusion that OLD is fundamentally a precancerous process with lichenoid features.^[4]

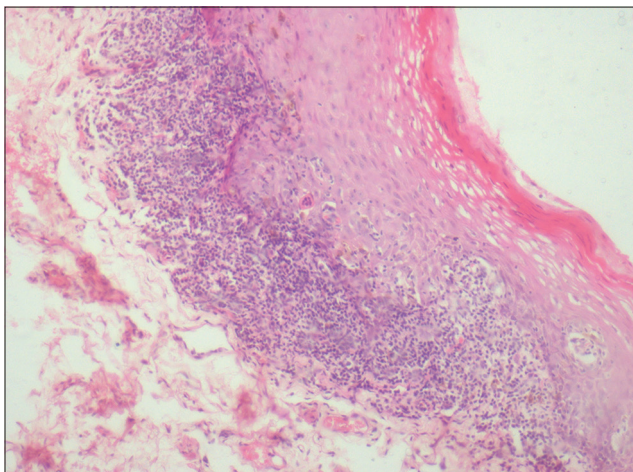


Figure 1: Photomicrograph of oral lichen planus (H&E, ×10)

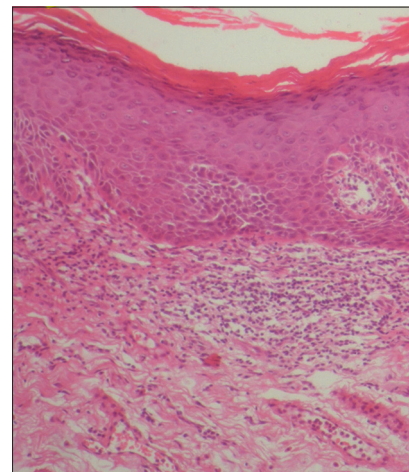


Figure 2: Photomicrograph of oral lichenoid reaction (H&E, ×10)

MATERIALS AND METHODS

Total of 40 biopsies were studied; biopsies were obtained from the patients visiting various departments of Yenepoya Dental College Mangalore. Tissue sections were prepared from fresh biopsies obtained and also from the formalin-fixed and paraffin-embedded wax blocks from archives of the Department of Oral Pathology, Yenepoya Dental College and Hospital.

The sections were divided as follows:

1. Study group: OLP – 10 cases, OLR – 10 cases and OLD – 10 cases
2. Control group: 10 biopsies were obtained from gingiva of uninfected impacted third molar extraction.

Two sets of sections each of 4-micron thickness were prepared; one set of the sections was stained by Harry's hematoxylin and eosin, which is used for routine diagnosis. Another set of sections were stained by the silver staining techniques for nucleolar organizer regions as given by Plonton D *et al.* 1986^[8] with slight modification of the incubation temperature (from the usual 20°C–40°C). The sections were dewaxed in xylene for about 3–5 min and then rehydrated through decreasing grades of ethanol (all dilutions of ethanol were made in deionized water) followed by thorough washing in running deionized water for 8–10 min.

The sections were then stained with freshly prepared silver colloidal solution (1 part by volume of 2% gelatin in 1% formic acid and two parts by volume of 50% aqueous silver nitrate solution) in a closed Coplin jar for 35 min at room temperature, while ensuring that a dark environment was maintained throughout the reaction time. The silver colloidal solution was washed with double distilled ionized water. The sections were then treated with 5% sodium thiosulfate for 5 min and washed in double distilled deionized water, dehydrated through increasing grades of alcohol, cleared in xylene and mounted. In all sections, (AgNORs) were distinctly visible as black “dots” or “blebs” of varying sizes in the brown-stained nucleus on a pale-yellow background of the cells [Figures 4-6]. In each of the section, 100 individual cells were examined from the representative areas of the epithelium. The methodological and systemic quantification of AgNORs was carried out using oil immersion objective ($\times 100$). In each section, 100 cells were examined from representative areas of epithelium. The total number of AgNORs were counted as per the standardized procedure recommended by Smith and Crocker *et al.*^[9]

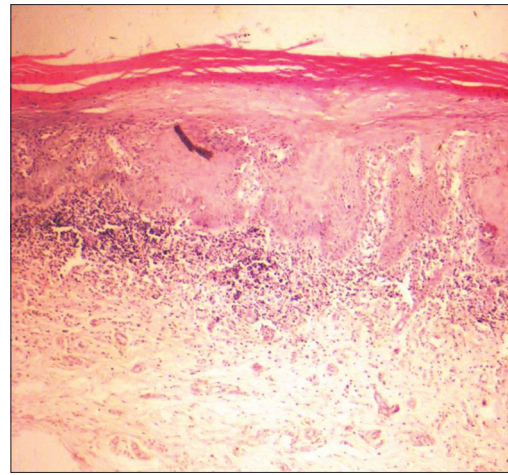


Figure 3: Photomicrograph of oral lichenoid dysplasia (H&E, $\times 10$)

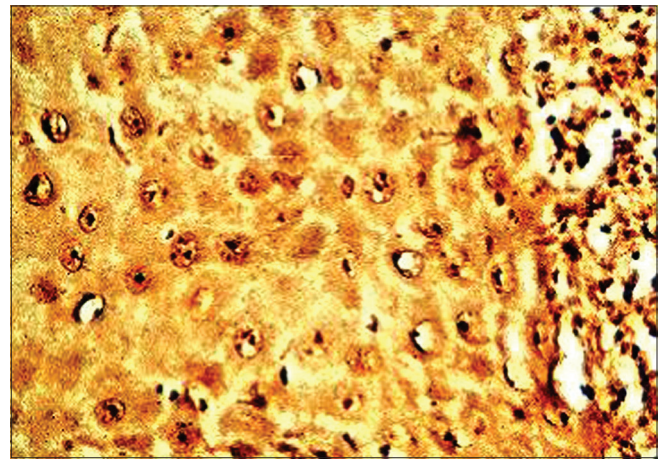


Figure 4 : Photomicrograph showing argyrophilic nucleolar organizer regions in oral lichen planus (silver stain, $\times 100$)

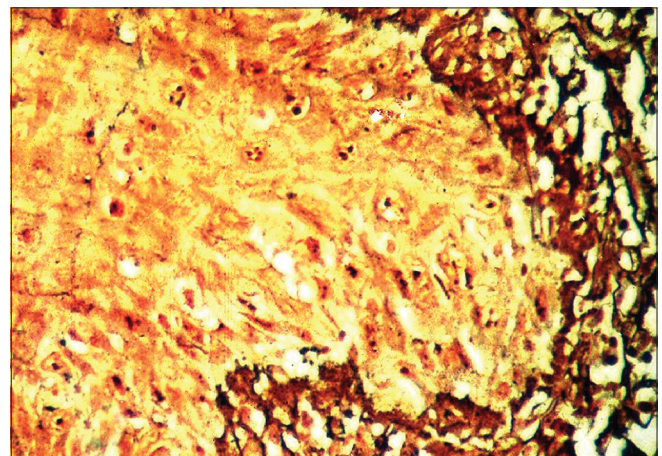


Figure 5: Photomicrograph showing argyrophilic nucleolar organizer regions in oral lichenoid reaction

The results thus obtained by the above method were subjected to statistical analysis for obtaining significant value (P value) using students t -test.

RESULTS

The sample comprised each 10 cases of OLP, OLR and OLD as study group and 10 normal mucosal biopsies constituted the control group.

In a total of 10 OLP patients, 7 were males and 3 were females with a ratio of 2.3:1. The age ranged from 18 to 56 years for males with a mean of 30.4 years and 35–56 years for females with a mean of 38.3 years [Table 1].

The total AgNOR count in OLP patients ranged from 2.18 to 2.41 with a mean count of 2.272 ± 0.09 (standard deviation [SD]). In the control group, AgNOR count ranged from 2.11 to 2.25 with a mean of 2.20 ± 0.0485 (SD). When these two groups were compared, the results were statistically highly significant ($P = 0.022$) [Tables 2 and 3].

In a total of 10 OLR patients, the age ranged from 25 to 52 years for males with a mean of 45.2 years and 40–50 years for females with a mean of 36.3 years and the male: female ratio of 1:1. [Table 1]. The total AgNOR count in OLR ranged from 2.23 to 2.37 with a mean count of 2.27 ± 0.073 (SD). When mean AgNOR count of OLR was compared with control group the results were statistically significant ($P = 0.012$) and when compared to OLP it was nonsignificant ($P = 0.081$) [Tables 2 and 3].

In a total of 10 OLD patients, 7 were males and 3 were females with a ratio of 2.3:1. The age ranged from 20 to 49 years for males with a mean of 35.7 years and

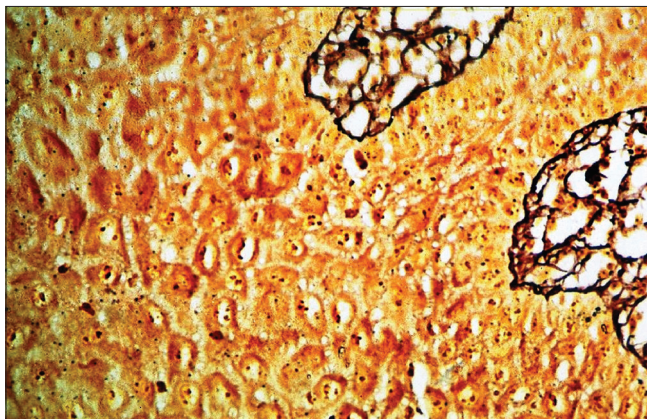


Figure 6: Photomicrograph showing argyrophilic nucleolar organizer regions in oral lichenoid dysplasia

30–37 years for females with a mean of 33.6 years [Table 1]. The total AgNOR count in OLD patients ranged from 2.33 to 2.45 with a mean count of 2.388 ± 0.043 (SD). When the mean AgNOR count of OLD is compared with the control group, the results showed very high significant value ($P = 0.001$), and when compared to OLP ($P = 0.002$) and OLR ($P = 0.003$), the results showed statistically highly significant [Table 2 and 3].

DISCUSSION

Since the time of Kaposi^[10] and Wickham^[11] in the late 1800s, lichen planus has been recognized as a chronic mucocutaneous inflammatory condition. Although the cause of lichen planus remains unknown, a cell-mediated immune response is suspected.

Clinically, lichenoid lesions presumed to be oral lichen planus were found by studying the biopsy specimens to represent other condition, which include atypical lichenoid stomatitis and dysplasia.

Review of many cases and much histologic material has led to the conclusion that OLD is fundamentally a precancerous process with lichenoid features. It is related to oral lichen planus and other benign lichenoid conditions only in so far as superficial resemblance is concerned. It looks like oral lichen planus both clinically and histologically. The finding that OLD and OLR are frequently confused with oral lichen planus serves as a reasonable explanation for further study.

The early stages in the development of dysplasia can be detected by various advanced diagnostic methods. Cell proliferation markers such as labeling index, 5-bromo-2'-deoxyuridine, flow cytometry, image cytometry, PCNA and Ki-67 are widely used to evaluate the malignant potential of the lesions. Silver stainable AgNORs is one such method used as a proliferative marker.

The NORs are loops of DNA found in the nucleolus, which are thought to encode for ribosomal RNA. The nonhistone nucleoproteins associated with NORs can be identified by silver staining (AgNORs).^[8] The quantitative and qualitative analysis of AgNORs had been carried out in different lesions and significant changes have been

Table 1: Age and sex distribution of OLP, OLR & OLD

Lesion	Number of cases	Male	Female	Age range (years)		Average age (years)	
				Male	Female	Male	Female
Oral lichen planus	10	7	3	18-56	35-56	30.4	38.3
Oral lichenoid reaction	10	5	5	25-52	40-50	45.2	36.3
Oral lichenoid dysplasia	10	7	3	20-49	30-37	35.7	33.6

Table 2: Mean range, mean count and standard deviation of AgNORs count in OLP, OLR OLD & control group. SD (standard deviation)

Lesion	Number of cases	Mean range of AgNORs	Mean count of AgNORs	SD
Oral lichen planus	10	2.18-2.41	2.272	0.09
Oral lichenoid reaction	10	2.23-2.37	2.270	0.073
Oral lichenoid dysplasia	10	2.33-2.45	2.388	0.043
Control group	10	2.11-2.25	2.20	0.0485

AgNORs: Argyrophilic nucleolar organizer regions, SD: Standard deviation

Table 3: Student “t” test and “p” value of OLP, OLR, OLD & control group

Sample	t-test	P
Oral lichen planus versus control group	2.271	0.022 (significant)
Oral lichenoid reaction versus control group	2.259	0.012 (significant)
Oral lichenoid dysplasia versus control group	9.126	0.001 (very highly significant)
Oral lichen planus versus oral lichenoid reaction	0.059	0.81 (nonsignificant)
Oral lichenoid reaction versus oral lichenoid dysplasia	4.370	0.003 (highly significant)
Oral lichenoid dysplasia versus oral lichen planus	4.113	0.002 (highly significant)

observed in benign and malignant lesions.^[12-14] The increase in the total number of AgNORs in dysplasia and carcinoma has already been established in several studies.^[13,15]

The present study was carried out in 10 cases of OLP comprising of both male and female patients with an age range of 18–56 years for males and 35–56 years for females with a male: female ratio of 2.3:1. In 10 cases of OLR, an age ranged 25–52 years for males and 40–50 years for females with a male: female ratio of 1:1. In 10 cases of OLD, an age ranged 20–49 years for males and 30–37 years for females with a male:female ratio of 2.3:1 and 10 sections of normal gingiva as control.

The quantitative estimation of AgNORs was carried out in the above cases. AgNOR counts for normal mucosa varied in different studies. Rajendra and Nair^[16] reported a range of 1.198–3.21 with a mean count of 2.50 ± 0.52 (SD), whereas Cabrini *et al.*^[14] reported as 2.95 ± 1.42 (SD). Ray *et al.*^[17] documented the mean AgNOR count in the basal and parabasal layer, lower spinous layer and upper spinous layer as 2.26 ± 0.52 , 2.36 ± 0.6 and 1.93 ± 0.06 , respectively. In the present study, the total AgNOR count of control group ranged from 2.11–2.25 with a mean count of 2.2 ± 0.0485 (SD). The interpretation of AgNOR count in highly structured cell populations with a rapid turnover in health, such as normal oral epithelium, may be a more complex process compared to tissues with stable cell populations.

The mean AgNOR count of oral lichen planus, OLR and OLD is 2.272 ± 0.09 , 2.270 ± 0.073 and 2.388 ± 0.043 , respectively [Figures 1-6]. The substantial increase in the mean AgNORs has been observed in above-mentioned lichenoid lesions, when compared to that of control group and is statistically significant.

When AgNOR count of OLP and OLR was compared with control group, the results showed high significance ($P = 0.022$) and ($P = 0.12$). This indicated significant increase in the proliferative activity of epithelial cells in oral lichen planus and OLR, compared to control group. Under normal conditions, epithelial morphology is in part determined by the balance between cell proliferation and programmed cell death.^[18] The external and internal insults, such as inflammation, mechanical trauma and exposure to toxic agents, can in different ways affect the epithelial homeostasis.^[19] Varying degree of increased proliferation, apoptosis and expression of major histocompatibility complex class-II antigen, human leukocyte antigen-D related and decreased epithelial thickness have been observed in OLP as reported by various authors.^[20-22] Inflammatory mediators released from the cellular infiltrate may activate basal keratinocytes to become activated and hyperproliferate.^[23] Our study revealed that AgNOR count of OLP (2.272 ± 0.09) and OLR (2.27 ± 0.073), that are nearly similar and are not statistically significant ($P = 0.81$), may indicate that there is no much difference in the proliferative or mitotic activity of oral lichen planus and OLR.

The mean AgNOR count of OLD (2.388 ± 0.043) compared to that of oral lichen planus (2.272 ± 0.09) and OLR (2.27 ± 0.073) shows increase in AgNOR count and statistically highly significant ($P = 0.002$ and $P = 0.003$, respectively).

It was found that OLD statistically has very high significant value ($P = 0.001$) when compared to control group. The increase in number of AgNORs could be related to the proliferative activity of the dysplastic cells in OLD. Warnakulasuriya and Jhonson observed that the degree of dispersion or disaggregation of AgNORs largely accounted for the increased count of AgNORs found in some dysplastic and in neoplastic tissues.^[13] Dispersion of AgNORs over the nucleoplasm thus appears to be a hallmark of malignancy as described by several previous workers.^[15,24,25] AgNORs count will rise with increase in cell ploidy,^[26] with increased transcriptional activity and in states of active cell proliferation.^[24] The progression of an oral keratinocyte from metaplasia to dysplasia and eventually to neoplasia is a multistep process involving

complex factors additional to increase in cell proliferation and aneuploidy-pathological processes for which AgNORs may be acting as a marker.^[24]

AgNOR count alone cannot be used to distinguish an individual dysplastic lesion or an individual carcinoma from a benign keratosis.^[24]

We need specific or definite criteria to separate oral lichen planus, OLR and OLD histologically. In the present study, the AgNOR technique was tried to find out whether this could be helpful in this direction. The results showed that OLD can be differentiated from other lichenoid lesions, but in case of oral lichen planus and OLR, the technique could not differentiate them, may be due similar rate of proliferative activity and also it could be due to small sample size. Further, more sensitive techniques such as image analysis can be explored in this direction so that oral lichen planus, OLR and OLD are distinguished easily.

CONCLUSION

AgNOR count is an objective test, which has stronger biological basis for diagnosing epithelial dysplasia. It is easy to perform, inexpensive and is performed on biopsied specimen. However, this technique cannot differentiate OLP and OLR, as there is no much difference in the proliferative activity of cells in these two lesions. It is reasonable to suggest that all biopsy tissues from lichenoid lesions where dysplastic features are observed in routine histopathological sections should be additionally stained by silver technique to ascertain dysplastic status of the lesion.

Clinical significance

Thus, the increase in number of AgNORs could be related to the proliferative activity of the cells in OLD. The evolution of normal to dysplasia to carcinoma is a slow process. The early stages in the development of dysplasia can be detected by various advanced diagnostic methods; AgNORs is one such method, which is used as a proliferative marker. This is an improved diagnostic parameter, which will help pathologists to formulate more definitive final histopathological diagnosis and will in turn facilitate the formulation of patient treatment and follow-up care by clinicians.

Acknowledgment

I acknowledge Dr. Maji Jose for her guidance and I thank Mr. Jayraj and Mrs. Jayalaxmi lab technicians for their support.

Financial support and sponsorship

Nil.

Conflicts of interest

There are no conflicts of interest.

REFERENCES

- Eisenberg E, Krutchkoff DJ. Lichenoid lesions of oral mucosa. Diagnostic criteria and their importance in the alleged relationship to oral cancer. *Oral Surg Oral Med Oral Pathol* 1992;73:699-704.
- Fernández-González F, Vázquez-Álvarez R, Reboiras-López D, Gándara-Vila P, García-García A, Gándara-Rey J. Histopathological findings in oral lichen planus and their correlation with the clinical manifestations. *Oral Medicine and Pathology Oral Cir Bucal* 2011;16:e641-6.
- Red EE. White and ulcerated oral lesions-some considerations for the diagnostic approach. *J Dermatol Surg* 1987;13:21.
- Krutchkoff DJ, Cutler L, Laskowski S. Oral lichen planus: The evidence regarding potential malignant transformation. *J Oral Pathol* 1978;7:1-7.
- Savage NW. Oral lichenoid drug eruptions. *Oral Dis* 1997;3:55-7.
- Krutchkoff DJ, Eisenberg E. Lichenoid dysplasia: A distinct histopathologic entity. *Oral Surg Oral Med Oral Pathol* 1985;60:308-15.
- Kalpan B, Barnes L. Oral lichen planus and squamous cell carcinoma. *Arch Otolaryngol* 1985;111:543-7.
- Ploton D, Menager M, Jeannesson P, Himber G, Pigeon F, Adnet JJ. Improvement in the staining and in the visualization of the argyrophilic proteins of the nucleolar organizer region at the optical level. *The Histochemical Journal* 1986;18:5-14.
- Smith R, Crocker J. Evaluation of nucleolar organizer region-associated proteins in breast malignancy. *Histopathology* 1988;12:113-25.
- Kaposi M. Lichen ruber pemphigoides. *Arch Dermatol Syph (Berl)* 1892;24:34-6.
- Wickham LF. Sur un signs pathognomonique de lichen du Wilson (lichen plan) stries et pontuations grisâtres. *Ann Dermatol Syph* 1895;6:517-20.
- Egan MJ, Crocker J. Nucleolar organizing regions in pathology. *Br J Cancer* 1992;65:1-7.
- Warnakulasuriya KA, Johnson NW. Nucleolar organiser region (NOR) distribution as a diagnostic marker in oral keratosis, dysplasia and squamous cell carcinoma. *J Oral Pathol Med* 1993;22:77-81.
- Cabrini RL, Schwint AE, Mendez A, Femopase F, Lanfranchi H, Itoiz ME, *et al.* Morphometric study of nucleolar organizer regions in human oral normal mucosa, papilloma and squamous cell carcinoma. *J Oral Pathol Med* 1992;21:275-9.
- Sano K, Takahashi H, Fujita S, Inokuchi T, Pe MB, Okabe H, *et al.* Prognostic implication of silver-binding nucleolar organizer regions (AgNORs) in oral squamous cell carcinoma. *J Oral Pathol Med* 1991;20:53-6.
- Rajendra R, Nair SM. Silver binding nucleolar organizer regions proteins as a possible prognostic indicator in oral submucous fibrosis. *Oral Surg Oral Med Oral Pathol* 1992;74:481-6.
- Ray JG, Chattopadhyay A, Caplan DJ. Usefulness of AgNOR counts in diagnosing epithelial dysplasia. *J Oral Pathol Med* 2003;32:71-6.
- Gandarillas A. Epidermal differentiation, apoptosis, and senescence: Common pathways? *Exp Gerontol* 2000;35:53-62.
- Squier CA, Kremer MJ. Biology of oral mucosa and esophagus. *J Natl Cancer Inst Monogr* 2001;(29):7-15.
- Hirota M, Ito T, Okudela K, Kawabe R, Yazawa T, Hayashi H, *et al.* Cell proliferation activity and the expression of cell cycle regulatory proteins in oral lichen planus. *J Oral Pathol Med* 2002;31:204-12.
- Neppelberg E, Johannessen AC, Jonsson R. Apoptosis in oral lichen planus. *Eur J Oral Sci* 2001;109:361-4.
- Tanda N, Mori S, Saito K, Ikawa K, Sakamoto S. Expression of apoptotic signaling proteins in leukoplakia and oral lichen planus: Quantitative and topographical studies. *J Oral Pathol Med* 2000;29:385-93.
- Freedberg IM, Tomic-Canic M, Komine M, Blumenberg M. Keratins and the keratinocyte activation cycle. *J Invest Dermatol* 2001;116:633-40.

24. Crocker J, Hall PA, McCarthy JC, Stansfeld AC. A comparative study of nucleolar organizer regions (AgNORs) Ki-67 staining and DNA flow cytometry in non Hodgkin's lymphoma. *J Pathol* 1998;154:3717.
25. Zhang CZ, Young WG, Li H, Rolinson S, Waters MJ. Growth hormone regulates nucleolar organizer regions during odontogenesis in the rat. *J Oral Pathol Med* 1992;21:395-400.
26. Wachtler F, Hopman AH, Wiegant J, Schwarzacher HG. On the position of nucleolar organizer regions (NORs) in interphase nuclei. Studies with a new, non-autoradiographic *in situ* hybridization method. *Exp Cell Res* 1986;167:227-40.