



Cytogenetic analysis of genetic damage in young individuals exposed to chronic mechanical irritation in the lateral border of the tongue due to sharp teeth – a novel study

Thuckanickenpalayam Ragunathan Yoithaprabhunath,
Nalliappan Ganapathy, Seeni Renugadevi, Jalaludheen Misbha Rafath,
Vishnuvarthan Aparna, Janardhanam Dineshshankar

Oral and Maxillofacial Pathology
Department, Vivekanandha Dental
College for Women, Tamilnadu, India

Abstract

Background. Chronic inflammation is estimated to contribute to approximately 25% of human cancers. Inflammation can be induced by chronic mechanical irritation which can lead to oral pre-cancer and oral cancer. Though many studies have been conducted to identify the genetic damage in oral cancer or dysplastic stages, no study has been conducted so far on early detection of genetic damage in healthy individuals presenting with sharp teeth in contact with the lateral border of the tongue.

Objective. The study is aimed at analyzing the genetic damage (micronuclei) in healthy individuals with sharp teeth in contact with the lateral border of the tongue causing chronic mechanical irritation.

Methods. The study group included 75 clinically healthy individuals with sharp teeth in contact with the lateral border of the tongue and 25 clinically healthy individuals with normal teeth in contact with the lateral border of the tongue as a control group. Brush samples of epithelial cells were collected, then spread over clean glass slide and fixed in 100% alcohol, stained with rapid PAP and analyzed under the light microscope. The exfoliated cells were examined to detect micronuclei.

Results. Micronuclei frequency was found to be increased in the study group where sharp teeth were in contact with the lateral border of the tongue of healthy individuals without deleterious habits such as usage of tobacco in smoking/smokeless form, areca nut chewing or alcohol consumption.

Conclusions. Cytogenetic analysis is a simple and scantily invasive technique allowing clinicians the early detection of DNA damage in patients with sharp teeth and subsequently preventing carcinogenesis by proper treatment and follow-up.

Keywords: micronuclei, sharp teeth, inflammation

Introduction

Cancer is the end product of an untamed proliferation of cells resulting from the accretion of sequential genetic alterations (mutations) in a precursor cell. One of the major Public health problems faced by Indian subcontinent is Oral cancer and it ranks among the top three types of cancer in the country [1]. GLOBOCAN 2018, the International Agency for Research on Cancer (IARC)

released its latest global cancer data. According to the India fact sheet of that summit, cancer of the lip and oral cavity showed a huge increase of 114.2% with 56,000 cases in 2012 which had increased to 119,992 in 2018 [2]. Carcinogenesis is multifactorial in humans. There is no single cause for oral cancer. It results from a variety of factors that operate over time and is dependent on each person's unique response to these factors. Tobacco and

DOI: 10.15386/mpr-1567

Manuscript received: : 07.01.2020
Received in revised form: 11.03.2020
Accepted: 23.04.2020

Address for correspondence:
yoitha.dentist@gmail.com

This work is licensed under a Creative Commons Attribution-NonCommercial-NoDerivatives 4.0 International License

alcohol are often considered as the major risk factor for oral cancer. There are also individuals unexposed to those factors that could develop malignant lesions. According to the literature, lateral border of the tongue is the most commonly involved site especially in non-smokers (90%) [3]. Chronic mechanical irritation (CMI) due to sharp/broken teeth may not be able to produce genetic mutation but may prompt epigenetic changes that ultimately promotes genetic damage and inhibits DNA repair [4]. Patients with oral cancer often present late to the physician making treatment difficult, expensive and sometimes unsuccessful. Delay in presentation may be considered to be a health risk-taking behavior. There are always clues right before our eyes that help us to prevent something from happening than to treat the damage. One such clue for the development of oral cancer is identifying and analyzing the genetic damage. Unstable chromosome aberrations can be studied in the epithelial cells by the detection of micronuclei in exfoliated interphase cells. Since 1937, Micronuclei (MN) have been used as an indicator of genotoxic exposure due to their association with chromosomal aberrations. They can be detected in exfoliated cells micronucleus assay which involves microscopic analysis of epithelial smears to determine the prevalence of micronucleation, an indicator of structural or numerical chromosome aberrations. The assay is reliable and technically easy to perform, noninvasive and sensitive with limited cost [5-7]. The rationale of the study is to emphasize the severity of CMI due to sharp teeth which also will enable health professionals and the public health workers to plan methods of the appropriate approach in handling this condition and the necessity of early precautionary treatment in individuals identified with a risk factor.

Methods

Individuals with the presence of sharp teeth either on unilateral (either right or left side) or bilateral (both right and left side) posterior region (in premolars and molars) causing mechanical irritation and trauma in the lateral borders of the tongue were included as a study group. The study population comprised of both male and female, with the age group of 30-40 years. Individuals who have potentially malignant disorders, those who are on treatment for potentially malignant disorders, potentially malignant disorders that have progressed to malignancy, individuals recently exposed to diagnostic radiation or radiation therapy, individuals who have systemic disease/disorders and individuals with the usage of smoking tobacco / smokeless tobacco, areca nut and alcohol consumption habits were excluded from the study. Healthy individuals within 30-40 years of age who did not have sharp teeth on the posterior region were considered as a control group.

The study group was subdivided into 4 groups:

- **Control group**
- Group I:** 25 subjects without sharp teeth
- **Study groups**
- Group II:** 25 subjects having sharp teeth on both

the left and right-side posterior region causing chronic mechanical irritation on both lateral borders of the tongue.

Group III: 25 subjects having sharp teeth in the right side posterior region causing chronic mechanical irritation in the right lateral border of the tongue.

Group IV: 25 subjects having sharp teeth in the left side posterior region causing chronic mechanical irritation in the left lateral border of the tongue.

Institutional Ethical Committee (IEC): the study details were presented to the IEC and a clearance certificate was obtained (IEC no - VDCW/IEC/152/2019).

Sample collection and evaluation of the slides

Study participants were asked to rinse their mouth with water before sampling. A cyto-brush was used to obtain cell samples from both right and left lateral borders of the tongue. It was then transferred into centrifuge tubes with Phosphate Buffered Saline (PBS) at pH 7.2 and centrifuged for 10 minutes at 1500 rotations per minute (rpm). Supernatant was replaced with 5 ml of fresh PBS solution, centrifuged for 10 minutes at 1500 rpm and repeated twice. This supernatant was discarded and the pellet smeared onto clean microscopic slides, air dried for 10 minutes and fixed in ethanol and acetic acid in the ratio of 3:1 for 10 minutes. Slides were then stained using RAPID PAP for bright field microscopic analysis and evaluated using classification for nuclear abnormalities by Tolbert et al. [8], to determine the MN frequencies. The cells were counted under 40x magnification. A total of 100 cells per subject were counted. Cells with indefinite borders, overlapping cells were excluded from counting. The MN present in each cell was then determined. The samples were analyzed and a photomicrograph was taken using a Leica DMD 108 micro-imaging system (Figure 1). The results were tabulated and subjected to statistical analysis.

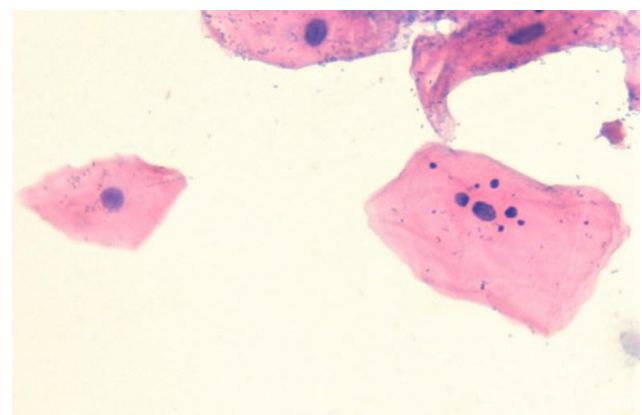


Figure 1. Image shows exfoliated cell with micronuclei. (magnification – 40X).

Cells with MN: these cells are characterized by the presence of a main nucleus and one or more smaller structures called MN. The MN are rounded or oval in shape, with a

diameter between 1/3 and 1/16 that of the main nucleus. MN exhibited the same staining intensity and texture as the main nucleus. Most cells with MN have only one micronucleus, though some may contain two or more.

Statistical analysis

Software used was Statistical package for social science SPSS version 16 (IBM CORP, Chicago, IL, USA). The level of significance ($p < 0.05$) was employed in all statistical comparisons. Quantitative data were recorded as mean \pm standard deviation. Data were subjected to student t-test and ANNOVA test.

Results

Comparison algorithm

1. Intergroup comparison of MN frequency among group I vs group II
2. Intergroup comparison of MN frequency among right side of group I vs group III
3. Intergroup comparison of MN frequency among left side of group I vs group IV
4. Intragroup comparison of MN frequency between right side of group III and left side of group III
5. Intragroup comparison of MN frequency between left side of group IV and right side of group IV

1. Intergroup comparison of MN frequency among group I vs group II

Micronuclei frequency between (sum of right side

and left side) group I (Mean 66.560) and group II (187.360) population and was found to be highly significant (Table I). The sharp teeth associated group evidenced an increased amount of micronuclei formation comparing to that of the non-associated population.

2. Intergroup comparison of MN frequency among right side of group I vs group III

Sharp teeth in contact with the right-side lateral border of the tongue of group III (Mean 105.002) showed significantly increased MN frequency when compared with the right side of group I (Mean 29.9600) (Table II).

3. Intergroup comparison of MN frequency among left side of group I vs group IV

Sharp teeth in contact with the left-side lateral border of the tongue of group IV (Mean 91.0000) showed significantly increased MN frequency when compared with the left side of group I (Mean 36.6000) (Table III).

4. Intragroup comparison of MN frequency between right side of group III and left side of group III

Intra group comparison among group III depicted an increased micronuclei frequency in the right side lateral border of the tongue (Mean 105.002) rather than the left side (Mean 45.5600) and was found to be highly significant (Table IV). The side where sharp teeth were in contact with the lateral border of the tongue (right side) showed an increased amount of micronuclei formation compared to that of the non-associated side.

Table I. Comparison of micronuclei count among group I and group II.

	N	Micronuclei count - control		t	p	95% Confidence interval of the difference	
		Mean	SD			Lower	Upper
Group I	25	66.560	27.3024	-12.301	.000 ($p < 0.05$)	-140.5452	-101.0548
Group II	25	187.360	40.8114			-140.6198	-100.9802

Table II. Comparison of micronuclei count among group I and group III.

Right side	N	Micronuclei count - control		t	p	95% Confidence interval of the difference	
		Mean	SD			Lower	Upper
Group I	25	29.9600	12.53821	-16.766	.000 ($p < 0.05$)	-84.03893	-66.04107
Group III	25	105.002	18.53600			-84.07124	-66.00876

Table III. Comparison of micronuclei count among group I and group IV.

Left side	N	Micronuclei count - control		t	p	95% Confidence interval of the difference	
		Mean	SD			Lower	Upper
Group I	25	36.6000	20.77458	-8.636	.000 ($p < 0.05$)	-67.06487	-41.73513
Group IV	25	91.0000	23.67136			-67.07039	-41.72961

Table IV. Intragroup comparison of micronuclei frequency in group III.

Group II	N	Micronuclei count - control		t	p	95% Confidence interval of the difference	
		Mean	SD			Lower	Upper
Left side	25	45.5600	18.68172	-11.293	.000	-70.02282	-48.85718
Right Side	25	105.002	18.53600			-70.02283	-48.85717

Table V. Intragroup comparison of micronuclei frequency in group IV.

Group III	N	Micronuclei count - control		t	p	95% Confidence interval of the difference	
		Mean	SD			Lower	Upper
Left side	25	91.0000	23.67136	9.938	.000	41.79879	63.00121
Right side	25	38.6000	11.60460			41.69508	63.10492

5. Intragroup comparison of MN frequency between the left side of group IV and the right side of group IV

The intra group comparison between group IV depicts an increased micronuclei frequency in the left side lateral border of the tongue (Mean 91.0000) in comparison with the right side (Mean 38.6000) and was found to be highly significant (Table V). The side where sharp teeth was in contact with the lateral border of the tongue (left side) showed an increased micronuclei frequency compared to that of the non-associated side.

Discussion

MNs originate from extra-nuclear bodies of acentric chromosome fragments or whole chromosomes that lag behind at anaphase during the nuclear division. It is microscopically visible as the round to oval cytoplasmic chromatin mass in the extra nuclear vicinity. The loss of chromatin in the main nucleus due to a mutagenic exposition, contributes to the formation of micronuclei [5,6]. Micronuclei frequencies are observed in exfoliated buccal cells in normal mucosa, pre-cancerous lesion and squamous cell carcinoma. Thus it has been concluded that a gradual increase in the micronuclei count from normal mucosa to precancerous to carcinoma thereby suggesting a link of this biomarker with neoplastic progression. The initiation and progression of cancer has now been largely attributed to the role played by inflammatory cells such as cytokines and growth factors like chemokines [7,9,10]. The lateral border of the tongue was found to be the most common site of tumor occurrence in both smokers and nonsmokers. The incidence of tumor occurrence in the lateral border of the tongue was twice as common in nonsmokers when compared to smokers [3].

The tongue is the most common site for sustained traumatic ulcers (Decubitus ulcer) and traumatic ulcerative granuloma (Eosinophilic ulcer of the tongue). Traumatic ulcers heal within 7 to 10 days but some persist for weeks to months due to constant irritation [9]. Previous studies state the hypothesis that CMI could act at least as a co-factor in oral carcinogenesis and it is underrated as a potential risk factor; its relevance in oral carcinogenesis might be of even more importance. Proper treatment of the mechanical injuring factors of oral mucosa (dental, prosthetic and functional) could be an imperative measure

to reduce the risk in individuals with other oral cancer risk factors [11,12].

In the present study, a cytological smear from the lateral border of the tongue in contact with the sharp teeth revealed an increased incidence of genetic damage. Especially in a study population with bilateral sharp teeth, there is a notable increase of MN count in the lateral border of the tongue when compared with the control population.

An experimental study in hamsters has shown that chronic trauma in addition to carcinogen application could promote tumor initiation. In this study, mechanical irritation by scratching with a pulp cleaner has been shown to significantly increase the incidence of a chemical carcinogen-induced tongue carcinoma. Therefore, it is prudent to closely monitor patients with known risk factors for signs and symptoms of irritation from teeth (Sharp/broken teeth) [13].

In the present study, when intra group comparison was made, there was a significant increase of MN count among the lateral border of the tongue which was in contact with sharp teeth when compared with the other side. The MN count was found to be increased within the study group where sharp teeth was in contact with the lateral border of the tongue. There is no significant difference in the incidence of MN among the genders and the results from our study states a strong relationship between CMI due to the presence of sharp teeth and MN formation in relation to the lateral border of the tongue even in the absence of any habits such as the usage of tobacco in smoking/smokeless form, areca nut chewing or alcohol consumption. This correlates with the existing literature that, any chronic mechanical irritation will result in inflammation which paves a way to genetic instability such as MN formation.

Inflammation is a perilous component of tumor progression. Past studies state that many cancers arise from sites of infection, chronic irritation and inflammation. It also states that for promoting proliferation, survival and migration of tumor cell, tumor microenvironment, which is largely orchestrated by inflammatory cells, is essential. In 1863, Virchow hypothesized that the origin of cancer was at sites of chronic inflammation. In part based on his hypothesis that some classes of irritants, together with the tissue injury and ensuing inflammation they cause, enhance cell proliferation.

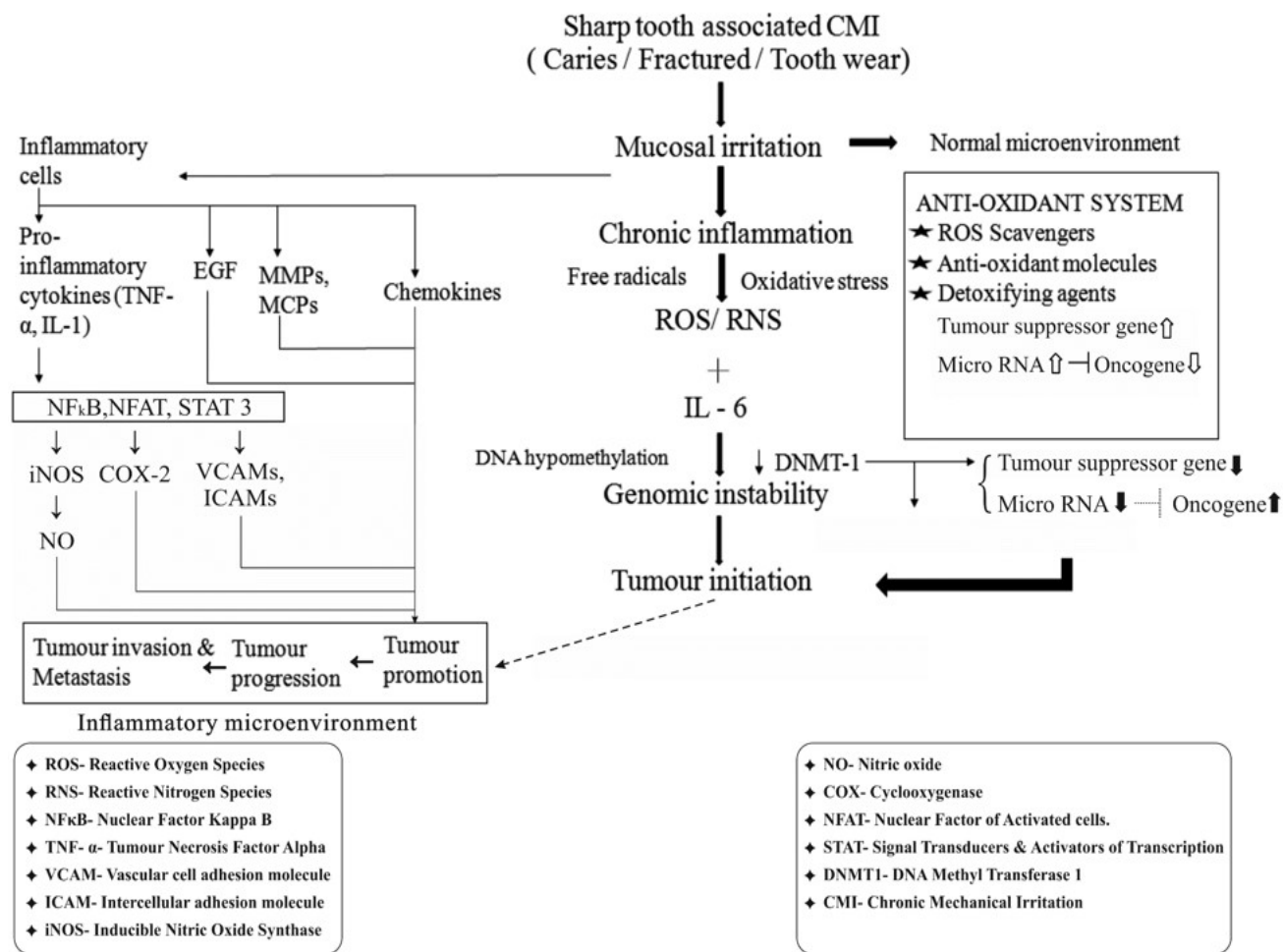


Figure 2. Epigenetic alterations under inflammatory microenvironment.

Under an inflammatory microenvironment, exposure to Reactive Oxygen Species/Reactive Nitrogen Species (ROS/RNS) or pro-inflammatory cytokines such as interleukin 6 (IL-6) transcriptionally affects the DNA methyltransferase 1 (DNMT1) protein, resulting in enhanced DNA methylation of tumor suppressor genes and microRNAs. ROS/RNS also induce global DNA hypomethylation, resulting in genomic instability. Multistage carcinogenesis consists of three steps: tumor initiation, promotion, and progression. The genomic instability or damage will result in tumor initiation (Figure 2) [14].

Casartelli et al. (2000) observed micronuclei frequencies in exfoliated buccal cells in normal mucosa, precancerous lesion and squamous cell carcinoma. Thus, they have arrived at a conclusion stating that a gradual increase in micronuclei count from normal mucosa to precancerous to carcinoma thereby suggesting a link of this biomarker with neoplastic progression. The initiation and progression of cancer has now been largely attributed to the role played

by inflammatory cells such as cytokines and growth factors like chemokines [10].

In the present study, the results have revealed a significant increase in the frequency of micronuclei on the lateral border of the tongue due to CMI, where the sharp teeth are in contact. Hence sharp tooth induced chronic inflammation could be a vital co-factor, where the initiation of carcinogenesis can be induced along with the exposure to other carcinogenic factors.

Conclusion

Sharp teeth induced CMI is a risk rarely addressed in oral carcinogenesis. It induces chronic inflammation, thus causing genetic instability which can be promoted as genetic damage or mutation when the factor is left untreated or if there is an involvement of other factors. Our study strengthens the hypothesis that CMI could act as a sole/associated factor in the initiation and promotion of multistep carcinogenesis. To the authors' knowledge,

this is the first study analyzing the association of sharp teeth with micronuclei frequency and a possible molecular pathway regarding sharp teeth induced carcinogenesis. Since increased frequency of such a biomarker was found even in healthy individuals with sharp teeth in contact with the lateral border of the tongue, clinically, the ability to identify high-risk subgroups is imperative, as such individuals might benefit from early detection and prevention programs.

Acknowledgement

We would like to thank the prestigious Indian Council of Medical Research for selecting this study (Reference ID 2019-02773) under the Short Term Studentship (ICMR-STs) category and encouraging it with a scholarship.

References

1. Sharma S, Satyanarayana L, Asthana S, Shivalingesh KK, Goutham BS, Ramachandra S. Oral cancer statistics in India on the basis of first report of 29 population-based cancer registries. *J Oral Maxillofac Pathol.* 2018;22:18-26.
2. Bray F, Ferlay J, Soerjomataram I, Siegel RL, Torre LA, Jemal A. Global cancer statistics 2018: GLOBOCAN estimates of incidence and mortality worldwide for 36 cancers in 185 countries. *CA Cancer J Clin.* 2018;68:394-424.
3. Selvamani M, Yamunadevi A, Basandi PS, Madhushankari GS. Prevalence of oral squamous cell carcinoma of tongue in and around Davangere, Karnataka, India: a retrospective study over 13 years. *J Pharm Bioallied Sci.* 2015;7(Suppl 2):S491-S494.
4. Lazos JP, Piemonte ED, Lanfranchi HE, Brunotto MN. Characterization of chronic mechanical irritation in oral cancer. *Int J Dent.* 2017;2017:6784526. doi: 10.1155/2017/6784526.
5. Fenech M. Cytokinesis-block micronucleus cytome assay. *Nat Protoc.* 2007;2:1084-1104.
6. Bolognesi C, Fenech M. Micronucleus assay in human cells: lymphocytes and buccal cells. *Methods Mol Biol.* 2013;1044:191-207.
7. Gupta A, Bhovi TV, Jaju PP, Gupta A, Gupta M, Shrivastava K. Micronuclei frequency as an early diagnostic tool for detection of Oral Cancer: A comparative study. *Int J Oral Health Dent.* 2016;2:77-83.
8. Tolbert PE, Shy CM, Allen JW. Micronuclei and other nuclear anomalies in buccal smears: methods development. *Mutat Res.* 1992;271:69-77.
9. Kohli M, Ahuja P, Mehendiratta M, Sharma M, Dutta J. Micronucleus assay: an early diagnostic tool to assess genotoxic changes in patients with tobacco use, oral leukoplakia and oral submucous fibrosis. *J Clin Diagn Res.* 2017;11:ZC28-ZC32.
10. Casartelli G, Bonatti S, De Ferrari M, Scala M, Mereu P, Margarino G, et al. Micronucleus frequencies in exfoliated buccal cells in normal mucosa, precancerous lesions and squamous cell carcinoma. *Anal Quant Cytol Histol.* 2000;22:486-492.
11. Piemonte E, Lazos J, Belardinelli P, Secchi D, Brunotto M, Lanfranchi-Tizeira H. Oral cancer associated with chronic mechanical irritation of the oral mucosa. *Med Oral Patol Oral Cir Bucal.* 2018;23:e151-e160.
12. Rajmohan M, Naidu RM, Thamaraiselvi D, M D. In vivo autofluorescence spectroscopic study and evaluation of DNA damage by comet assay in smokers. *J Clin Diagn Res.* 2015;9:ZC16-ZC19.
13. Kumar M, Nanavati R, Modi TG, Dobariya C. Oral cancer: etiology and risk factors: a review. *J Can Res Ther.* 2016;12:458-463.
14. Murata M. Inflammation and cancer. *Environ Health Prev Med.* 2018;23:50. doi: 10.1186/s12199-018-0740-1.