

IMAGES AND VIDEOS

Changes in the venous pulse waveform in pericardial effusion revealed by Doppler echocardiography of the superior vena cava

Benoy N Shah MD(Res) MRCP FESC and Dhruvo J Rakhit PhD FRCP FACC

Department of Cardiology, University Hospital Southampton, Southampton, UK

Correspondence
should be addressed
to B N Shah
Email
benoy.shah@uhs.nhs.uk

Summary

Echocardiography is valuable for urgent assessment of the haemodynamic significance of pericardial effusions and thus assisting in the clinical diagnosis of cardiac tamponade. Classical echocardiographic findings (e.g. respiratory variation in trans-valvular velocities) are not always present and, when seen, may be attributable to other conditions (e.g. obesity or obstructive airways disease) (1). Therefore, it is important to be familiar with other abnormalities that may be observed, such as that in the superior vena cava (SVC). SVC imaging is best performed from the right supraclavicular window, with the transducer placed vertically in the fossa between the sternal and clavicular heads of the sternomastoid muscle

and with the patient lying supine and the transducer marker pointing superiorly (2). Figure 1 (and Videos 1 and 2), taken in a 46-year-old male who presented with dizziness and had a large global pericardial effusion on 2D echocardiography, illustrate the changes seen in the SVC flow profile (which reflect the changes seen in the jugular venous pulse (JVP) waveform upon physical examination) before and after pericardiocentesis. SVC Doppler interrogation may be particularly valuable for determining the dominant haemodynamic condition in patients with both pericardial effusion and suspected pericardial constriction. In cardiac tamponade, compression occurs throughout the cardiac cycle and thus ventricular filling is impaired

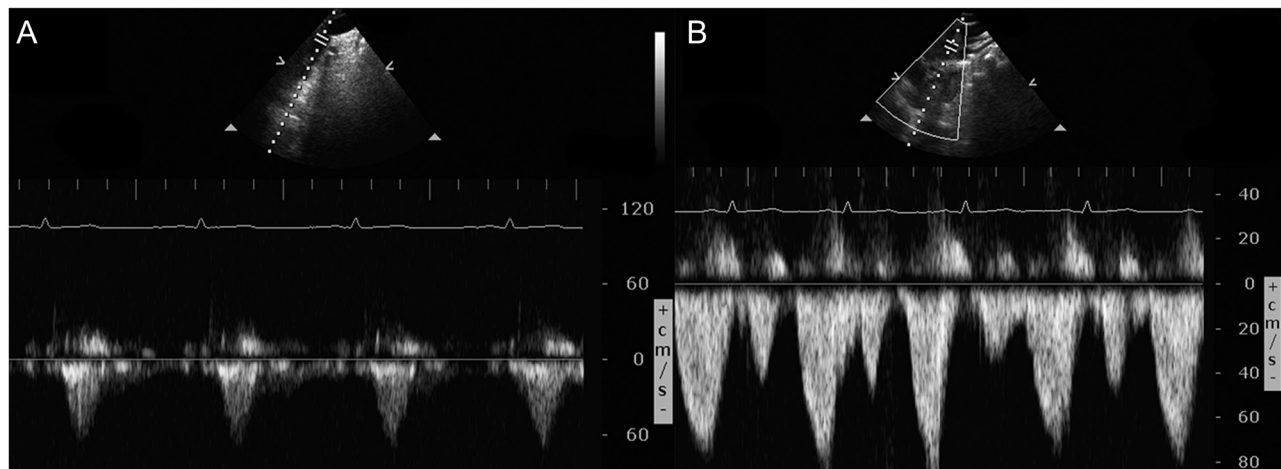


Figure 1

Pulsed Doppler echocardiography of the superior vena cava in our patient admitted with dizziness and with a large global effusion on echocardiography. Initially, flow was noted in systole but not in diastole (panel A). Following successful drainage of over 600 mL of fluid, with swift haemodynamic and clinical improvement, there was restoration of flow in both systole and diastole in the SVC (panel B).

throughout diastole, resulting in minimal or no flow into the right atrium from the SVC during diastole (i.e. absence of the diastolic wave (absent Y descent in the JVP)) (3). However, in pericardial constriction, early ventricular filling is preserved and is rapid but ends abruptly as soon as maximum intrapericardial pressure is reached, resulting in both systolic and diastolic (D) waves though the D wave has a steep deceleration slope (Fig. 2), mirroring the rapid Y descent observed in the JVP (4).

Video 1

Color Doppler imaging of the superior vena cava before pericardiocentesis, revealing monophasic flow during systole only. View Video 1 at <http://movie-usa.glencoesoftware.com/video/10.1530/ERP-17-0025/video-1>.

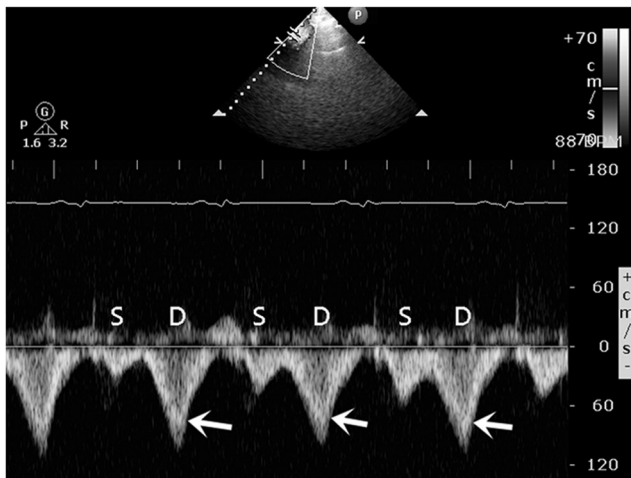


Figure 2
SVC Doppler tracing from a patient with pericardial constriction. Note the initial steep deceleration slope (arrows) of the diastolic (D) waves, which reflect the rapid Y descent seen in the jugular venous pulse on physical examination.

Video 2

Color Doppler imaging of the SVC after pericardiocentesis, revealing restoration of normal flow -in systole and diastole – within the SVC. View Video 2 at <http://movie-usa.glencoesoftware.com/video/10.1530/ERP-17-0025/video-2>.

Declaration of interest

The authors declare that there is no conflict of interest that could be perceived as prejudicing the impartiality of this article.

Funding

This work did not receive any specific grant from any funding agency in the public, commercial or not-for-profit sector.

Patient consent

Written permission has been obtained from the patient.

Author contribution statement

B N S conceived the idea for the article, wrote the first draft and created the figures. D J R provided critical feedback and edited the manuscript. B N S is the corresponding author and guarantor.

References

- Boonyaratavej S, Oh JK, Tajik AJ, Appleton CP & Seward JB 1998 Comparison of mitral inflow and superior vena cava Doppler velocities in chronic obstructive pulmonary disease and constrictive pericarditis. *Journal of the American College of Cardiology* **32** 2043–2048. (doi:10.1016/S0735-1097(98)00472-0)
- Khouzam RN, Minderman D & D'Cruz IA 2005 Echocardiography of the superior vena cava. *Clinical Cardiology* **28** 362–366. (doi:10.1002/clc.4960280804)
- Zhang S, Kerins DM & Byrd BF 3rd 1994 Doppler echocardiography in cardiac tamponade and constrictive pericarditis. *Echocardiography* **11** 507–521. (doi:10.1111/j.1540-8175.1994.tb01092.x)
- Oh JK, Hatle LK, Seward JB, Danielson GK, Schaff HV, Reeder GS & Tajik AJ 1994 Diagnostic role of Doppler echocardiography in constrictive pericarditis. *Journal of the American College of Cardiology* **23** 154–162. (doi:10.1016/0735-1097(94)90514-2)

Received in final form 22 September 2017

Accepted 25 September 2017