

## Clinical Viewpoint

# Why Your Patient May Need an ACL Reconstruction Plus Lateral Extra-Articular Tenodesis Procedure

Amit Momaya, MD, Chandler Harris, Matt Hargreaves

Keywords: ACL, Lateral extra-articular tenodesis (LET), knee

<https://doi.org/10.26603/001c.94015>

---

## International Journal of Sports Physical Therapy

Vol. 19, Issue 3, 2024

---

Anterior cruciate ligament (ACL) tears are one of the most common knee injuries experienced by active individuals engaging in cutting sports. Despite improved surgical techniques and rehabilitation, the return to sport rate and re-tear rates remain unsatisfactory. Lateral extra-articular tenodesis (LET) is a procedure that has been growing in interest when performed in conjunction with ACL reconstruction. The benefits of adding an LET procedure to an ACL surgery may include greater rotational stability, decreased re-tear rates, and improved return to play.

Level of evidence: V

## INTRODUCTION

Approximately 250,000 anterior cruciate ligament (ACL) tears occur annually in the United States, with most tears arising from non-contact mechanisms.<sup>1,2</sup> Anterior cruciate ligament reconstruction (ACLR) is considered a cost-effective treatment for such injuries in competitive athletes and the standard of care for those who wish to return to sport.<sup>3</sup> Worldwide, ACLR appears to be growing for both adult and pediatric populations.<sup>4-7</sup> Despite advancements in ACLR techniques, re-tear rates and return-to-play rates remain unsatisfactory in certain populations.<sup>8-10</sup> The overall return to previous level of play is reported to be just below 65% for athletes.<sup>3</sup> A recent study on female soccer athletes who underwent ACLR reported that 28% of all female soccer players and 34% of those players who returned to soccer experienced a second ACL tear. In another study on female soccer athletes, less than half returned to preinjury level of sport.<sup>9</sup>

Increased attention has been placed on residual post-operative rotary instability, which may correlate with increased failure rates, especially in young, highly active individuals.<sup>11,12</sup> ACLRs have evolved significantly from one of the first ACL repair operations pioneered by Sir Arthur Mayo-Robson in 1895, and many techniques now exist.<sup>13</sup> While most techniques focus on intra-articular graft reconstruction, high graft failure rates and persistent pivot shift have been seen in high-demand individuals.<sup>12,14</sup> Persistent pivot shift and rotatory laxity have been shown to correlate with graft failure, lower clinical outcome scores, and increased reoperation rates.<sup>15</sup> Such adverse outcomes are particularly pronounced in young patients participating in sports requiring regular pivoting, such as soccer, basketball, and football.<sup>16,17</sup>

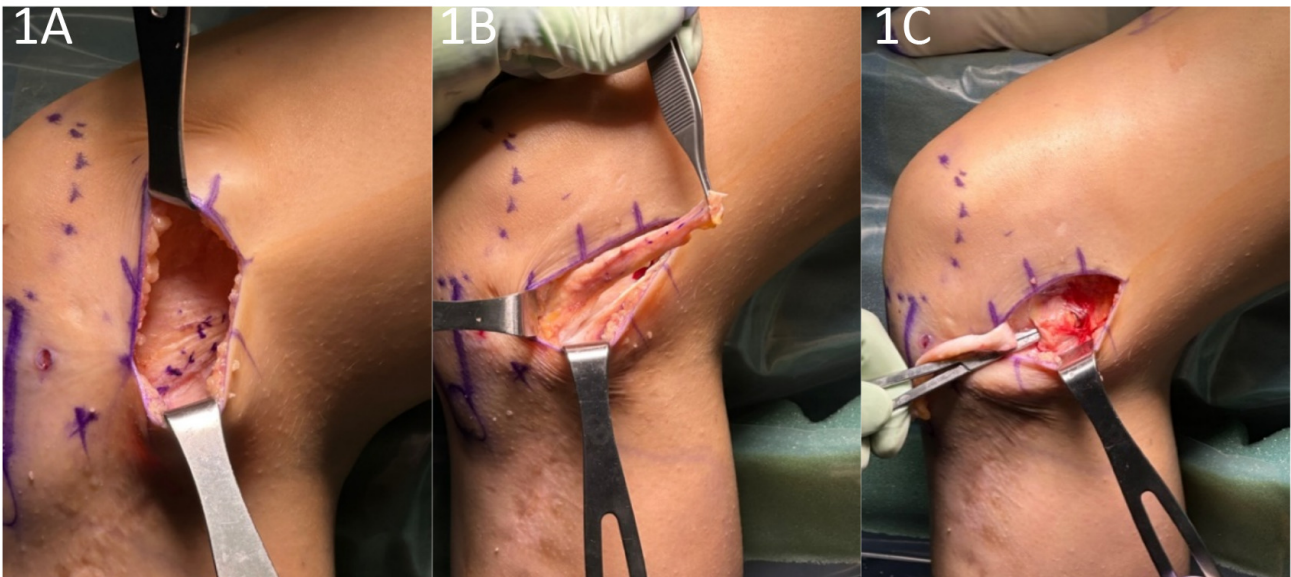
Recent investigations into the persistence of anterolateral rotatory laxity in these patients have led to an increased focus on the role of the anterolateral complex in

modulating knee stability.<sup>18</sup> Specifically, lateral extra-articular tenodesis (LET) has grown in popularity in the setting of ACLR. This procedure was initially utilized in ACL-deficient knees before the advent of intra-articular reconstruction techniques.<sup>19</sup> One method by which to perform an LET is known as the Modified Lemaire Technique. This procedure entails a transfer of approximately an 8x1 cm graft of the iliotibial band (ITB) while leaving it anchored distally to Gerdy's tubercle. The graft is released proximally from the vastus lateralis, passed under the lateral collateral ligament (LCL), and fixed to the femur just proximal and posterior to the lateral epicondyle ([Figures 1-4](#)).<sup>20</sup>

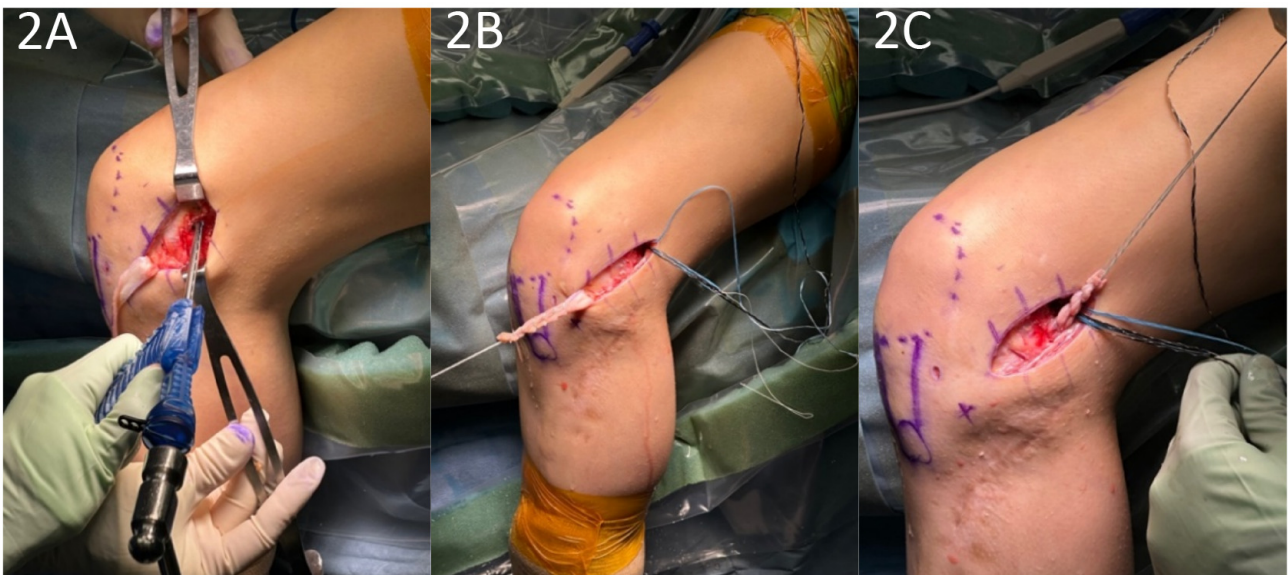
## BIOMECHANICS OF LET

The biomechanical aims of performing a LET in conjunction with an ACLR are the restoration of normal knee kinematics, correcting a high-grade pivot shift, and correcting increased internal tibial rotation. There has been significant investigation into the biomechanical effects of the LET, with cadaveric studies generally supporting its use in conjunction with ACLR.<sup>21-23</sup> Studies have shown reduced anterolateral residual laxity, ACL graft force, and anterior tibial translation (ATT).<sup>24,25</sup> Further biomechanical studies have also investigated the utility of the LET + ACLR with a concurrent medial meniscectomy,<sup>26</sup> showing reductions in ATT and internal rotation. These biomechanical studies suggest that a combined ACLR and LET may provide a protective effect on ACL graft and meniscus repair by increasing knee stability.

Despite such benefits, concerns have been raised regarding over-constraint and increased loading of the lateral compartment of the knee, although clinically, short to midterm studies have not shown increased osteoarthritis of the lateral compartment.<sup>27-29</sup> Furthermore, there have been mixed results regarding the effect of LET on in-vivo mechanics.<sup>30,31</sup> Nonetheless, a recent systematic review



**Figure 1. A. The iliotibial band is identified and marked. B 1x8 cm strip of IT band is harvested. C. The LCL is identified and a pathway underneath it is exposed.**



**Figure 2. A. The knotless anchor is inserted on the femur. B. The IT band is prepped with suture. C. The IT band is passed under the LCL.**

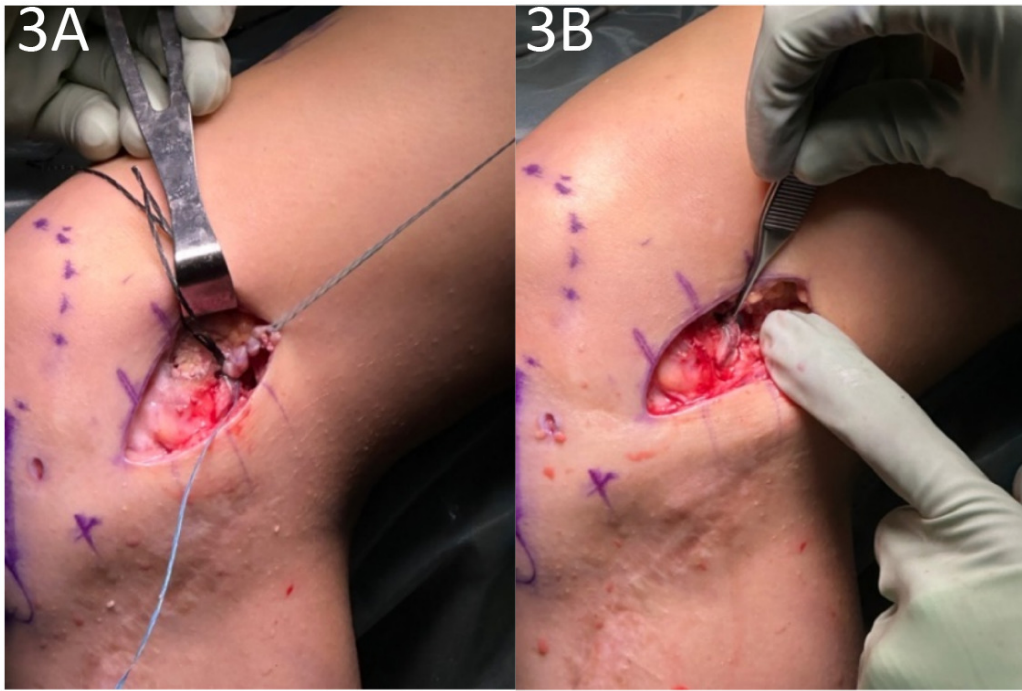
concluded that the LET procedure can resist internal rotation and improve residual knee rotatory laxity when performed in conjunction with ACLR.<sup>21</sup>

#### CLINICAL OUTCOMES

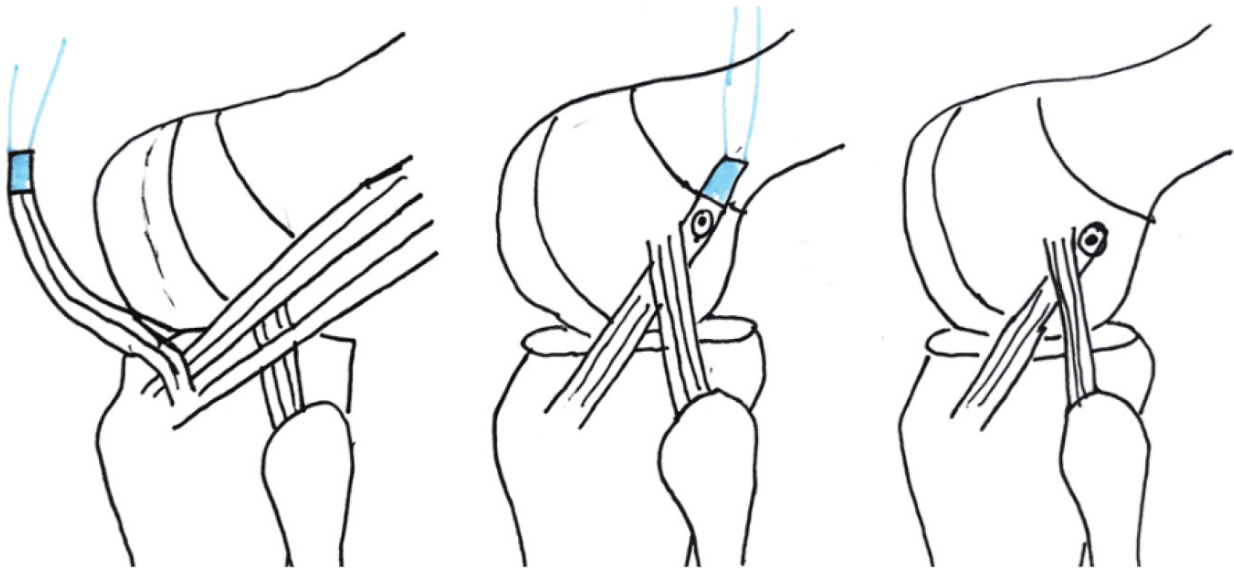
While the biomechanical results establish a foundation for the benefits of LET, recent clinical studies have provided further support for the use of LET. In the largest randomized clinical trial of LETs performed to date, 618 patients with a mean age of 18.9 years (range: 14-25) were randomized into ACLR vs. ACLR+LET groups. The addition of a LET to a hamstring autograft ACLR led to a statistically and

clinically significant decrease in graft rupture rates from 11% to 4% and clinical failure rates (persistent asymmetric rotatory laxity and graft rupture) from 40% to 25%.<sup>32</sup> The number to treat with LET to prevent one graft rupture was 14.

In another study, 49 consecutive patients aged 11 to 16 years old (mean 14.2 years) with a 98% participation rate in high-risk competitive sports demonstrated a graft re-rupture rate of 0% with a mean follow-up of 3.4 years and a return to sports rate of 100% following a quadriceps autograft ACLR with LET.<sup>33</sup> Furthermore, another study of 66 pediatric patients between 12-16 years old showed patients who received a LET in addition to an ACLR had better



**Figure 3. A. The graft is tensioned and fixed to the femur proximal and posterior to the lateral epicondyle. B. The picture shows the final construct.**



**Figure 4. Illustration detailing the harvest of the IT band followed by passage deep to LCL.**

KT-1000 arthrometer readings, better rotational stability measurements using kinematic rapid assessment (triaxial accelerometer), and lower graft rupture and cumulative failure rates than patients who underwent ACLR alone.<sup>34</sup> In the revision setting, LET has been shown to improve International Knee Documentation Committee scores, restore rotational stability, and reduce failure rates compared with isolated ACLR.<sup>35</sup>

When considering operation morbidity, adding the LET does not appear to be a significant factor, as there were

no clinically significant differences in motion or adverse events in a large-scale randomized trial.<sup>36</sup>

#### INDICATIONS

Significant risk factors for ACL re-tear include but are not limited to gender, age, sport, anatomic variation, hyper-extension, and athletic level, all of which should be considered when deciding on the utility of a LET. The senior author of this paper (AMM) typically adds an LET for “high-

**Table 1. The indications for adding an LET to ACLR are generally those that increase the risk of graft failure**

<b>Relative Indications for LET</b>
Female Population
Soccer Athletes
Elite Athletes (national or international level)
Inherent ligamentous laxity
Increased posterior tibial slope
High grade pivot shift
Revision ACL surgery
Meniscal root tears and subtotal meniscectomies
Chronic ACL tear

risk” patients during ACLR. Common indications include female sex, soccer athletes, elite athletes, inherent ligamentous laxity, increased posterior tibial slope, high-grade pivot shift, revision ACL surgery, meniscal root tears/subtotal meniscectomies, and chronic ACL tears (Table 1).

In the revision setting, LET+ACLR has shown good return to sport rates in high-level basketball and soccer players.<sup>37</sup> A study of 78 athletes in the Netherlands found a significant difference in RTS rates for revision ACL with LET (52%) compared to ACLR without LET (31%).<sup>38</sup> Similar benefits have been seen for athletes competing at an elite (national or international) level. In a study of 455 elite athletes (83% male, mean age 22.5 years), 117 underwent ACLR + LET, and 338 underwent ACLR only. The cohort with ACLR only had a 9.5% retear rate, whereas the ACLR + LET group had a 3.4% retear rate. This reduction equated to ACLR + LET reducing graft failure by a factor of 2.8.<sup>39</sup>

**REHABILITATION**

One concern often raised regarding the addition of the LET is the effect on rehabilitation timelines. In the senior au-

thor’s practice, the LET does not change the rehabilitation protocol compared to a stand-alone ACLR. Furthermore, there is not increased rate of adverse events. The study by Heard et al. demonstrated that the ACLR + LET group had increased hardware irritation and increased pain at 3 months only. With regard to hardware irritation, many of the patients in that trial underwent LET fixation with a metal staple, which can be proud and irritating. Current techniques allow us to fix the LET with low-profile, knotless anchors.<sup>36</sup>

**CONCLUSION**

LET, when performed in conjunction with ACLR, has the potential to improve rotational stability, re-tear rates, and return to play for athletes. The procedure results in minimal morbidity and should be selectively used for higher risk patients. Further randomized studies are underway to better understand the indications for LET in patients with ACL injuries.

© The Author(s)



This is an open-access article distributed under the terms of the Creative Commons Attribution 4.0 International License (CCBY-NC-4.0). View this license’s legal deed at <https://creativecommons.org/licenses/by-nc/4.0> and legal code at <https://creativecommons.org/licenses/by-nc/4.0/legalcode> for more information.

## REFERENCES

1. Kaeding CC, Léger-St-Jean B, Magnussen RA. Epidemiology and Diagnosis of Anterior Cruciate Ligament Injuries. *Clin Sports Med.* 2017;36(1):1-8. [doi:10.1016/j.csm.2016.08.001](https://doi.org/10.1016/j.csm.2016.08.001)
2. Musahl V, Karlsson J. Anterior Cruciate Ligament Tear. *N Engl J Med.* 2019;380(24):2341-2348. [doi:10.1056/nejmcp1805931](https://doi.org/10.1056/nejmcp1805931)
3. Stewart BA, Momaya AM, Silverstein MD, Lintner D. The Cost-Effectiveness of Anterior Cruciate Ligament Reconstruction in Competitive Athletes. *Am J Sports Med.* 2017;45(1):23-33. [doi:10.1177/0363546516664719](https://doi.org/10.1177/0363546516664719)
4. Sherman SL, Calcei J, Ray T, et al. ACL Study Group presents the global trends in ACL reconstruction: biennial survey of the ACL Study Group. *J ISAKOS.* 2021;6(6):322-328. [doi:10.1136/jisakos-2020-000567](https://doi.org/10.1136/jisakos-2020-000567)
5. Herzog MM, Marshall SW, Lund JL, Pate V, Mack CD, Spang JT. Trends in Incidence of ACL Reconstruction and Concomitant Procedures Among Commercially Insured Individuals in the United States, 2002-2014. *Sports Health.* 2018;10(6):523-531. [doi:10.1177/1941738118803616](https://doi.org/10.1177/1941738118803616)
6. Janssen KW, Orchard JW, Driscoll TR, van Mechelen W. High incidence and costs for anterior cruciate ligament reconstructions performed in Australia from 2003–2004 to 2007–2008: time for an anterior cruciate ligament register by Scandinavian model? *Scand J Med Sci Sports.* 2011;22(4):495-501. [doi:10.1111/j.1600-0838.2010.01253.x](https://doi.org/10.1111/j.1600-0838.2010.01253.x)
7. Zbrojkiewicz D, Vertullo C, Grayson JE. Increasing rates of anterior cruciate ligament reconstruction in young Australians, 2000–2015. *Med J Aust.* 2018;208(8):354-358. [doi:10.5694/mja17.00974](https://doi.org/10.5694/mja17.00974)
8. Allen MM, Pareek A, Krych AJ, et al. Are Female Soccer Players at an Increased Risk of Second Anterior Cruciate Ligament Injury Compared With Their Athletic Peers? *Am J Sports Med.* 2016;44(10):2492-2498. [doi:10.1177/0363546516648439](https://doi.org/10.1177/0363546516648439)
9. Britt E, Ouillette R, Edmonds E, et al. The Challenges of Treating Female Soccer Players With ACL Injuries: Hamstring Versus Bone–Patellar Tendon–Bone Autograft. *Orthop J Sports Med.* 2020;8(11):232596712096488. [doi:10.1177/2325967120964884](https://doi.org/10.1177/2325967120964884)
10. Ellman MB, Sherman SL, Forsythe B, LaPrade RF, Cole BJ, Bach BRJ. Return to play following anterior cruciate ligament reconstruction. *J Am Acad Orthop Surg.* 2015;23(5):283-296. [doi:10.5435/jaaos-d-13-00183](https://doi.org/10.5435/jaaos-d-13-00183)
11. Noyes FR, Huser LE, West J, Jurgensmeier D, Walsh J, Levy MS. Two Different Knee Rotational Instabilities Occur With Anterior Cruciate Ligament and Anterolateral Ligament Injuries: A Robotic Study on Anterior Cruciate Ligament and Extra-articular Reconstructions in Restoring Rotational Stability. *Arthroscopy.* 2018;34(9):2683-2695. [doi:10.1016/j.arthro.2018.04.023](https://doi.org/10.1016/j.arthro.2018.04.023)
12. Jesani S, Getgood A. Modified Lemaire Lateral Extra-Articular Tenodesis Augmentation of Anterior Cruciate Ligament Reconstruction. *JBJS Essent Surg Tech.* 2019;9(4):e41. [doi:10.2106/jbjs.st.19.00017](https://doi.org/10.2106/jbjs.st.19.00017)
13. Gee MSM, Peterson CDR, Zhou ML, Bottoni CR. Anterior Cruciate Ligament Repair: Historical Perspective, Indications, Techniques, and Outcomes. *J Am Acad Orthop Surg.* 2020;28(23):963-971. [doi:10.5435/jaaos-d-20-00077](https://doi.org/10.5435/jaaos-d-20-00077)
14. Prodromos CC, Joyce BT, Shi K, Keller BL. A meta-analysis of stability after anterior cruciate ligament reconstruction as a function of hamstring versus patellar tendon graft and fixation type. *Arthroscopy.* 2005;21(10):1202.e1-1202.e9. [doi:10.1016/j.arthro.2005.08.036](https://doi.org/10.1016/j.arthro.2005.08.036)
15. Ayeni OR, Chahal M, Tran MN, Sprague S. Pivot shift as an outcome measure for ACL reconstruction: a systematic review. *Knee Surg Sports Traumatol Arthrosc.* 2012;20(4):767-777. [doi:10.1007/s00167-011-1860-y](https://doi.org/10.1007/s00167-011-1860-y)
16. Webster KE, Feller JA. Exploring the High Reinjury Rate in Younger Patients Undergoing Anterior Cruciate Ligament Reconstruction. *Am J Sports Med.* 2016;44(11):2827-2832. [doi:10.1177/0363546516651845](https://doi.org/10.1177/0363546516651845)
17. Webster KE, Feller JA, Leigh WB, Richmond AK. Younger patients are at increased risk for graft rupture and contralateral injury after anterior cruciate ligament reconstruction. *Am J Sports Med.* 2014;42(3):641-647. [doi:10.1177/0363546513517540](https://doi.org/10.1177/0363546513517540)
18. Musahl V, Herbst E, Burnham JM, Fu FH. The Anterolateral Complex and Anterolateral Ligament of the Knee. *J Am Acad Orthop Surg.* 2018;26(8):261-267. [doi:10.5435/jaaos-d-16-00758](https://doi.org/10.5435/jaaos-d-16-00758)

19. Kennedy JC, Stewart R, Walker DM. Anterolateral rotatory instability of the knee joint. An early analysis of the Ellison procedure. *J Bone Joint Surg Am.* 1978;60(8):1031-1039.
20. Cerciello S, Batailler C, Darwich N, Neyret P. Extra-Articular Tenodesis in Combination with Anterior Cruciate Ligament Reconstruction: An Overview. *Clin Sports Med.* 2018;37(1):87-100. doi:10.1016/j.csm.2017.07.006
21. van der Wal WA, Meijer DT, Hoogeslag RAG, LaPrade RF. The Iliotibial Band is the Main Secondary Stabilizer for Anterolateral Rotatory Instability and both a Lemaire Tenodesis and Anterolateral Ligament Reconstruction Can Restore Native Knee Kinematics in the Anterior Cruciate Ligament Reconstructed Knee: A Systematic Review of Biomechanical Cadaveric Studies. *Arthroscopy.* 2024;40(2):632-647.e1. doi:10.1016/j.arthro.2023.05.005
22. Delaloye JR, Hartog C, Blatter S, et al. Anterolateral Ligament Reconstruction and Modified Lemaire Lateral Extra-Articular Tenodesis Similarly Improve Knee Stability After Anterior Cruciate Ligament Reconstruction: A Biomechanical Study. *Arthroscopy.* 2020;36(7):1942-1950. doi:10.1016/j.arthro.2020.03.027
23. Mayr R, Sigloch M, Coppola C, Hoermann R, Itchev A, Schmoelz W. Modified Lemaire tenodesis reduces anterior cruciate ligament graft forces during internal tibial torque loading. *J Exp Orthop.* 2022;9(1):45. doi:10.1186/s40634-022-00484-w
24. Inderhaug E, Stephen JM, Williams A, Amis AA. Anterolateral Tenodesis or Anterolateral Ligament Complex Reconstruction: Effect of Flexion Angle at Graft Fixation When Combined With ACL Reconstruction. *Am J Sports Med.* 2017;45(13):3089-3097. doi:10.1177/0363546517724422
25. Marom N, Ouanezar H, Jahandar H, et al. Lateral Extra-articular Tenodesis Reduces Anterior Cruciate Ligament Graft Force and Anterior Tibial Translation in Response to Applied Pivoting and Anterior Drawer Loads. *Am J Sports Med.* 2020;48(13):3183-3193. doi:10.1177/0363546520959322
26. Özbek EA, Runer A, Dadoo S, et al. The Effect of Lateral Extra-articular Tenodesis in an ACL-Reconstructed Knee With Partial Medial Meniscectomy: A Biomechanical Study. *Am J Sports Med.* 2023;51(13):3473-3479. doi:10.1177/03635465231198856
27. Geeslin AG, Moatshe G, Chahla J, et al. Anterolateral Knee Extra-articular Stabilizers: A Robotic Study Comparing Anterolateral Ligament Reconstruction and Modified Lemaire Lateral Extra-articular Tenodesis. *Am J Sports Med.* 2017;46(3):607-616. doi:10.1177/0363546517745268
28. Marom N, Jahandar H, Fraychineaud TJ, et al. Lateral Extra-articular Tenodesis Alters Lateral Compartment Contact Mechanics under Simulated Pivoting Maneuvers: An In Vitro Study. *Am J Sports Med.* 2021;49(11):2898-2907. doi:10.1177/03635465211028255
29. Pearce SL, Bryniarski AR, Brown JR, et al. Biomechanical Analysis of Tibial Motion and ACL Graft Forces After ACLR With and Without LET at Varying Tibial Slopes. *Am J Sports Med.* 2023;51(10):2583-2588. doi:10.1177/03635465231184389
30. Chiba D, Gale T, Nishida K, et al. Lateral Extra-articular Tenodesis Contributes Little to Change In Vivo Kinematics After Anterior Cruciate Ligament Reconstruction: A Randomized Controlled Trial. *Am J Sports Med.* 2021;49(7):1803-1812. doi:10.1177/03635465211003298
31. Sheean AJ, Lian J, Tisherman R, et al. Augmentation of Anatomic Anterior Cruciate Ligament Reconstruction With Lateral Extra-articular Tenodesis Does Not Significantly Affect Rotatory Knee Laxity: A Time Zero, In Vivo Kinematic Analysis. *Am J Sports Med.* 2020;48(14):3495-3502. doi:10.1177/0363546520966624
32. Getgood AMJ, Bryant DM, Litchfield R, et al. Lateral Extra-articular Tenodesis Reduces Failure of Hamstring Tendon Autograft Anterior Cruciate Ligament Reconstruction: 2-Year Outcomes From the STABILITY Study Randomized Clinical Trial. *Am J Sports Med.* 2020;48(2):285-297. doi:10.1177/0363546519896333
33. Green DW, Hidalgo Perea S, Brusalis CM, Chipman DE, Asaro LA, Cordasco FA. A Modified Lemaire Lateral Extra-articular Tenodesis in High-Risk Adolescents Undergoing Anterior Cruciate Ligament Reconstruction With Quadriceps Tendon Autograft: 2-Year Clinical Outcomes. *Am J Sports Med.* 2023;51(6):1441-1446. doi:10.1177/03635465231160681
34. Perelli S, Costa GG, Terron VM, et al. Combined Anterior Cruciate Ligament Reconstruction and Modified Lemaire Lateral Extra-articular Tenodesis Better Restores Knee Stability and Reduces Failure Rates Than Isolated Anterior Cruciate Ligament Reconstruction in Skeletally Immature Patients. *Am J Sports Med.* 2022;50(14):3778-3785. doi:10.1177/03635465221128926

35. Boksh K, Sheikh N, Chong HH, Ghosh A, Aujla R. The Role of Anterolateral Ligament Reconstruction or Lateral Extra-articular Tenodesis for Revision Anterior Cruciate Ligament Reconstruction: A Systematic Review and Meta-analysis of Comparative Clinical Studies. *Am J Sports Med.* 2023;52(1):269-285. [doi:10.1177/03635465231157377](https://doi.org/10.1177/03635465231157377)
36. Heard M, Marmura H, Bryant D, et al. No increase in adverse events with lateral extra-articular tenodesis augmentation of anterior cruciate ligament reconstruction – Results from the stability randomized trial. *J ISAKOS.* 2023;8(4):246-254. [doi:10.1016/j.jisako.2022.12.001](https://doi.org/10.1016/j.jisako.2022.12.001)
37. Borim FM, Jubert NJ, Vinaixa MMR, et al. Good rates of return-to-sport in athletes after revision anterior cruciate ligament reconstruction using autologous patellar tendon and lateral extra-articular tenodesis: a 2-year follow-up prospective study. *Eur J Orthop Surg Traumatol.* 2023;33(7):3125-3133. [doi:10.1007/s00590-023-03544-8](https://doi.org/10.1007/s00590-023-03544-8)
38. Keizer MNJ, Brouwer RW, de Graaff F, Hoogeslag RAG. Higher return to pre-injury type of sports after revision anterior ligament reconstruction with lateral extra-articular tenodesis compared to without lateral extra-articular tenodesis. *Knee Surg Sports Traumatol Arthrosc.* 2022;31(5):1699-1703. [doi:10.1007/s00167-022-07018-y](https://doi.org/10.1007/s00167-022-07018-y)
39. Borque KA, Jones M, Laughlin MS, et al. Effect of Lateral Extra-articular Tenodesis on the Rate of Revision Anterior Cruciate Ligament Reconstruction in Elite Athletes. *Am J Sports Med.* 2022;50(13):3487-3492. [doi:10.1177/03635465221128828](https://doi.org/10.1177/03635465221128828)