

Case Report

First reported treatment of aggressive hemangioma with intraoperative radiation therapy and kyphoplasty (Kypho-IORT)



B. Pinar Sedeño^{a,d,e,*}, N. Rodríguez Ibarria^{a,d}, H. Mhaidli Hamdani^b, T. Fernández Varela^b, I. San Miguel Arregui^{a,d}, D. Macías Verde^c, P.C. Lara Jiménez^{a,d,e}

^aRadiation Oncology Department, Hospital Universitario de Gran Canaria “Dr. Negrín”, Barranco de La Ballena s/n, CP 35020 Las Palmas de Gran Canaria, Spain

^bSpine Unit, Hospital Universitario de Gran Canaria “Dr. Negrín”, Barranco de La Ballena s/n, CP 35020 Las Palmas de Gran Canaria, Spain

^cMedical Physics Department, Hospital Universitario de Gran Canaria “Dr. Negrín”, Barranco de La Ballena s/n, CP 35020 Las Palmas de Gran Canaria, Spain

^dInstituto Canario de Investigación del Cáncer (ICIC), Plaza de Sixto Machado nº 3, CP 38009 Santa Cruz de Tenerife, Spain

^eClinical Sciences Department, Universidad de Las Palmas de Gran Canaria, C/ Dr. Pasteur s/n, CP 35016 Las Palmas de Gran Canaria, Spain

ARTICLE INFO

Article history:

Received 20 October 2016

Accepted 21 December 2016

Available online 26 January 2017

Keywords:

Aggressive vertebral hemangioma

Kyphoplasty

Intraoperative radiation therapy (IORT)

ABSTRACT

Aggressive hemangiomas invade the spinal canal and/or paravertebral space and may cause cord compression and neurological symptoms. Radiation therapy was recognized as an effective strategy for the treatment of aggressive hemangiomas. Here, it is reported the first case of aggressive vertebral hemangioma treated by a combination of intraoperative radiation therapy and kyphoplasty (Kypho-IORT).

© 2017 The Authors. Published by Elsevier Ireland Ltd on behalf of European Society for Radiotherapy and Oncology. This is an open access article under the CC BY-NC-ND license (<http://creativecommons.org/licenses/by-nc-nd/4.0/>).

Introduction

Vertebral hemangiomas (VH) are benign lesions arising from vascular tissue in the vertebral body bone. Enneking classification has been used for the classification of benign and malignant tumors of the musculoskeletal system for over 25 years. In Enneking classification, benign tumors are indicated with arabic numbers according to the nature of tumor and its histopathological grade. Benign tumors are classified as 1 inactive (latent), 2 active and 3 aggressive [1]. Based on the patients' lesions and symptoms, type 3 aggressive VH are those that present neurological deficit with epidural and/or soft tissue extension.

Treatment for VHs should be based entirely on patients' symptoms, because VH lesions may be benign in nature and rarely progress rapidly [2]. In type 3, aggressive VH, reported treatments include radiotherapy, kyphoplasty, direct alcohol injection, embolization of the feeding arteries, surgery, or a combination of these modalities [3]. Surgery is indicated in cases with rapid progressive and/or severe myelopathy. Correspondingly, a laminectomy could be combined with intraoperative vertebroplasty or alcohol injection, which may shrink the hemangiomas and lead to intrale-

sional thrombosis [4]. Spondylectomy is only indicated for ventrally located lesions with bony compression [5].

Although radiation therapy is the most common treatment for lesions that cause pain, its use as a sole therapy for patients with progressive neurological deficits is controversial. Most authors have favored surgical decompression, with radiotherapy often used as an adjuvant [6], although neurologic improvement may be possible with radiotherapy and steroid treatment alone, with a clinical and radiological improvement that may take several months to occur [7].

Also stereotactic body radiotherapy, in single-session or multi-session, has been proposed for the treatment of benign spinal tumors as a more accurate way of delivering radiation therapy with acceptable local control. The main advantages are better sparing of the spinal cord and the possibility of increasing the dose to the tumor target volume [8,9].

The risk of vertebral collapse after radiation therapy often requires the combination with percutaneous kyphoplasty and vertebroplasty leading to a better stabilization of the spine. Intraoperative radiotherapy (IORT) effectively combines the characteristics of surgery and radiotherapy, providing a more beneficial method for local tumor control. The development of micro X-ray emitters has led to the creation of a lightweight mobile unit suitable for micro-invasive puncture IORT. Instability is another factor of spine lesions. The INTRABEAM® system delivers 50 kV X-rays with a

* Corresponding author at: Radiation Oncology Department, Hospital Universitario de Gran Canaria “Dr. Negrín”, Barranco de la Ballena s/n, CP 35020 Las Palmas de Gran Canaria, Spain. Fax: +34 928449127.

E-mail address: beapinsede@hotmail.com (B. Pinar Sedeño).

sharp decline in radiation dose beyond the radiation range, which provides a higher dose to the tumor [10].

Material and methods

A 56-year-old caucasian male with no relevant past or family history presented with a two-years history of walking instability and dysthermia in his anterior face of the thigh though without thoracic pain associated. In the last month before diagnosis, the patient referred to experiencing a loss of walking ability due to a severe reduction in deep positional sensitivity. At the moment of the physical examination, the patient did not present secondary pain with thoracic spine palpation, the motility was almost preserved (4+/5 global in lower limbs) and there was a slight sensitivity reduction in lower limbs as well as a patellar hyperreflexia.

Computed tomography described a “polka dot” appearance with high contrast uptaking, commonly associated with vertebral hemangioma. MR study revealed a T5 vertebral hemangioma as a T2 and STIR hyperintense, T1 hypointense, enhancing and expansile bony lesion, with an anterior epidural mass, near the posterior wall, with 50% spinal canal invasion, associated with a right paravertebral soft tissue mass.

Results

After an unsuccessful embolization attempt, the patient was operated on the 3rd of April 2014. The kyphoplasty itself was performed according to the standard procedure with some modifications. Using a trans-pedicular access, specially designed metallic sleeves (5 mm diameter, 6 cm length) were inserted to guide the

electron drift tube (3.2 mm diameter) of the miniature X-ray generator (INTRABEAM, Carl Zeiss Surgical, Oberkochen, Germany) (Fig. 1). After verification of the position of the guiding sleeves using biplanar X-ray, the INTRABEAM system was inserted with a novel sheet (diameter 4.2 mm) designed for this approach protecting the drift tube, into the vertebral body. Special care was taken to avoid sheer and bending stress on the drift tube and the sheet. A radiation dose of 8 Gy in 10 mm distance was delivered (Fig. 2). IORT took approximately two minutes. After IORT the INTRABEAM® device was removed, the cement was injected through both pedicles. A balloon was not needed during this procedure because there was no height loss in the affected vertebra.

There were no immediate complications after procedure. The day after the procedure, all neurological symptoms disappeared, and the patient had recovered his walking ability completely, without pain association. There was no visible radiation induced skin reaction.

CT and MRI post-operative studies described no morphological or cement-associated complications. After a follow-up of 30 months, the patient remained asymptomatic without treatment related complications. Follow-up image studies show a normal morphology of treated vertebra with a reduction in the epidural anterior mass (Fig. 3).

Discussion

Hemangiomas are benign slow growing vascular tumors composed of newly formed capillary, cavernous or venous blood vessels. Among skeletal locations, vertebrae are the second commonest site and thoracic spine is affected most frequently. Symptomatic hemangiomas of the vertebral bodies associated with

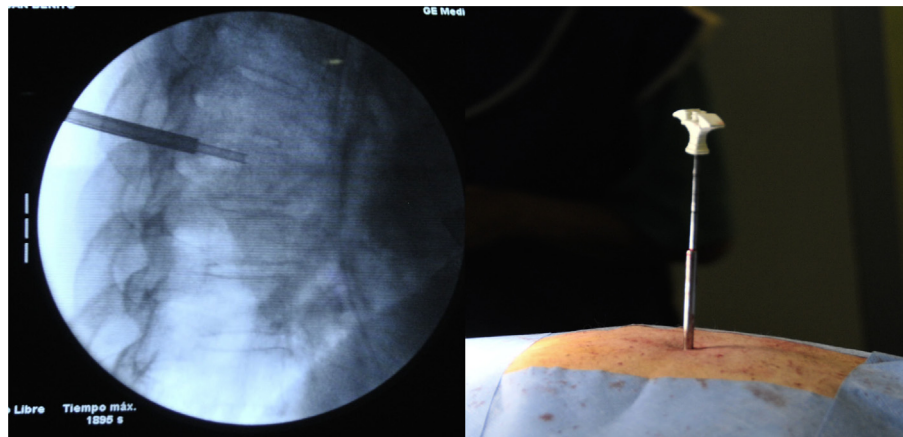


Fig. 1. Using a trans-pedicular access, ad-hoc designed metallic sleeves were positioned into the vertebral body.

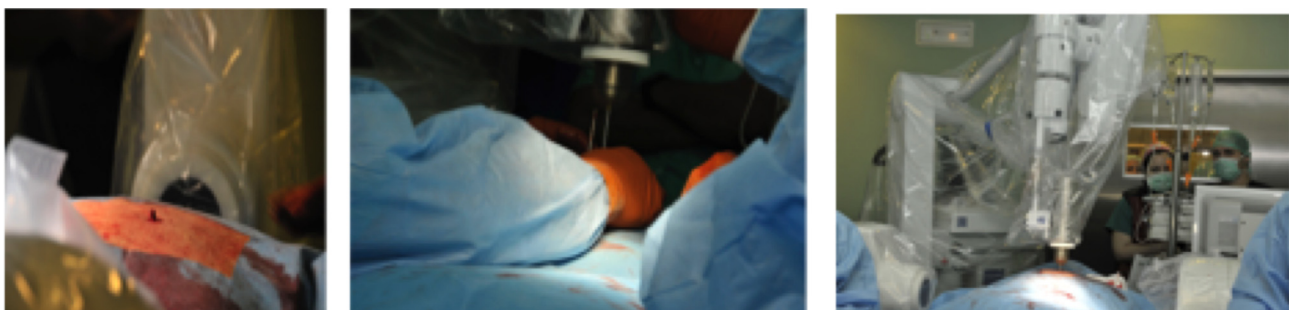


Fig. 2. A specific needle applicator including the drift tube of the INTRABEAM®, was guided through the metallic sleeves into the vertebral body and a single dose of 8 Gy to 10 mm was delivered.

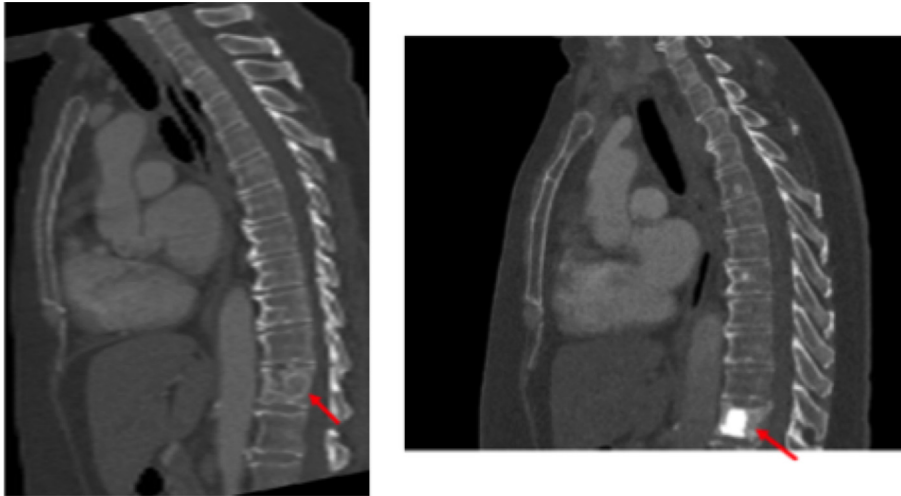


Fig. 3. CT scans pre and post-kyphoplasty.

neurologic manifestations are usually located in the mid thoracic region, where diameter of the spinal canal is also small. Cord compression is more likely to occur with lesions that extend into the pedicles and laminae of thoracic vertebra where cord occupies most of the volume of the spinal canal [11]. In the present case, the thoracic 5th vertebral body was affected. Neurologic complications dominated the clinical picture with compression of the spinal cord.

Historically, surgery was the treatment of choice in symptomatic vertebral hemangiomas. The aim was spinal cord decompression and sometimes only partial removal of the tumor. The operation of laminectomy to relieve cord compression may be hazardous in vertebral hemangiomas. Due to high vascularisation of haemangiomas, copious bleeding may complicate surgery, and can even be life-threatening [12]. Arterial embolization has been reported to reduce intraoperative bleeding and to reverse neurological deficits in some cases. In cases with progressive neurological deficits, arterial embolization is mainly performed preoperatively, to reduce intraoperative bleeding [6].

Since the effectiveness of radiation therapy in the treatment of VHs had been first described by the 1930's, many series have been reported with symptomatic improvements ranging from 60 to almost 90% of the patients [13]. When considering the degree of complication and the possible risk of severe complications of the different therapeutic modalities used in VHs, radiotherapy seems to be the easiest and most efficacious treatment modality. Radiation therapy has been delivered most commonly using fractionated schedules [14]. There is a dose–effect relationship for the treatment of symptomatic vertebral hemangiomas and it has been recommended a total dose of 40 Gy of external beam radiation therapy over 4 weeks [2,11]. With the development of intensity-modulated radiation therapy, it may be possible to safely deliver higher doses of radiation while avoiding complications [13].

The spine is the most common site of bone metastases. Incidence of spinal metastasis is approximately 30% in patients with cancer at their time of death. About 5% of cancer patients are estimated to develop neurological deficits as a result of spinal metastases. Effective treatment is required to control both spinal metastases and its associated neurological symptoms. Kyphoplasty is a common treatment method used to stabilize the vertebral body, thus avoiding pathological fractures and controlling pain [15,16]. Kyphoplasty has no direct anticancer effect and external beam radiotherapy is usually added to avoid early recurrences [17].

Decompressive surgery has been combined with intraoperative radiotherapy (IORT) with electrons for the treatment of spinal metastasis since 1992, with excellent results, in terms of neurological recovery and local control. Using an electron cone with spinal cord lead shielding, doses delivered ranged from 15 to 25 Gy [18,19].

However, the interest in IORT has increased considerably with the development of novel miniature X-ray generators, with a new needle applicator, designed combining a stainless steel tube to protect the radiation source and a plastic tip that minimizes the absorption of the radiation. The intraoperative treatment during kyphoplasty allows the combination of surgical stabilization for pain relief and radiotherapy for tumor cell sterilization, increasing life expectancy with one minimally invasive treatment, with excellent reported results [20–24].

Vascular injury has long been known to be the most common effect when exposing normal tissues to radiation. Single dose radiation therapy provides remarkably high rates of control, even for tumors resistant to fractionated radiotherapy due to a gradual loss of tumor endothelial cells after irradiation. Overall tumor control depends on acute acid sphingomyelinase-mediated endothelial cell injury [25]. Recently, ceramide-induced endothelial apoptosis rather than DNA DSB-induced clonogenic cell death has been considered to underlie the effects of hypofractionated stereotactic body radiotherapy [26]. In this way, vascular tumors could be specifically sensitive to single dose IORT.

With this biological and clinical background, it seems to be appropriate to combine a vertebroplasty or kyphoplasty with a single dose of IORT with an INTRABEAM device through the same pedicular access, leading to a vertebral stabilization and an effective vascular injury during only one surgical procedure.

In large series reported, radiation therapy has proved to be easy, safe, and effective for pain relief treatment for symptomatic vertebral hemangioma. Total doses of at least 40 Gy give the best symptomatic response [11,13,14,27]. The application of radiotherapy in hemangiomas is to eliminate the abnormal veins and capillaries to reduce the size of the lesion and a known long term effect of radiotherapy is impairment of circulation by causing vascular endothelial damage [11,25].

Radiation is effective at controlling pathological vascular tissue but does not have a radiographically demonstrable effect on the surrounding bony tissue. In this way, radiation alone may be less effective for patients who have neurological compression due to focal bone hypertrophy. Vertebroplasty or kyphoplasty with

methyl methacrylate cement has been described as an option in the treatment of vertebral hemangiomas since the late 1980s with improvements in hemostatic embolization, but also in the load-bearing capacity of the anterior column, with good clinical results [13]. In this way, kyphoplasty's trans-pedicular access represents an excellent access also for intraoperative radiation therapy. Kypho-IORT with INTRABEAM is a novel method of single-fraction radiotherapy performed during a stabilizing procedure using an X-ray source, that allows a combination of minimally invasive surgery and radiotherapy in one visit, with a minimal increase of surgery time of approximately 15 min and minimal effort with regard to radiation protection [24]. This modality combining approach is an attractive alternative, leading patients to be treated completely in just one day, during the surgical stabilization procedure, avoiding more aggressive surgical options as a laminectomy.

Conclusion

The intraoperative treatment during kyphoplasty allows the combination of surgical stabilization for neurological symptoms and radiotherapy for rapid post-irradiation vascular endothelial damage, increasing clinical efficacy with one minimally invasive treatment. Kypho-IORT seems to be a feasible procedure in the treatment of aggressive vertebral hemangiomas in terms of safety and efficacy, resulting in patient neurological symptoms' control and patient comfort. Further studies are necessary to evaluate the long-term effectiveness of this treatment.

References

- [1] Ciftdemir M, Kaya M, Selcuk E, Yalniz E. Tumors of the spine. *World J Orthoped* 2016;7(2):109–16. <http://dx.doi.org/10.5312/wjov.v7.i2.109>.
- [2] Jiang L, Liu XG, Yuan HS, et al. Diagnosis and treatment of vertebral hemangiomas with neurologic deficit: a report of 29 cases and literature review. *Spine J* 2014;14(6):944–54. <http://dx.doi.org/10.1016/j.spinee.2013.07.450>.
- [3] Cloran FJ, Pukenas BA, Loevner LA, Aquino C, Schuster J, Mohan S. Aggressive spinal haemangiomas: imaging correlates to clinical presentation with analysis of treatment algorithm and clinical outcomes. *Br J Radiol* 2015;1055(88):20140771. <http://dx.doi.org/10.1259/bjr.20140771>.
- [4] Goldstein CL, Varga PP, Gokaslan ZL, Boriani S, Luzzati A, Rhines L, et al. Spinal hemangiomas: results of surgical management for local recurrence and mortality in a multicenter study. *Spine (Phila Pa 1976)* 2015;40(9):656–64. <http://dx.doi.org/10.1097/BRS.0000000000000840>.
- [5] Nair AP, Kumar R, Srivastav AK, et al. Outcome of dorsolumbar vertebral hemangiomas presenting with neuraxial compression. *Indian J Orthop* 2012;46(5):536–41. <http://dx.doi.org/10.4103/0019-5413.101033>.
- [6] Ogawa R, Hikata T, Mikami S, Fujita N, Iwanami A, Watanabe K, et al. Total en bloc spondylectomy for locally aggressive vertebral hemangioma causing neurological deficits. *Case Rep Orthop* 2015;2015:724364. <http://dx.doi.org/10.1155/2015/724364>.
- [7] Sewell MD, Dbeis R, Bliss P, Watkinson T, Hutton M. Radiotherapy for acute, high-grade spinal cord compression caused by vertebral hemangioma. *Spine J* 2016;16(3):e195–6. <http://dx.doi.org/10.1016/j.spinee.2015.10.018>.
- [8] Sahgal A, Chou D, Ames C, Ma L, Lamborn K, Huang K, et al. Image-guided robotic stereotactic body radiotherapy for benign spinal tumors: the University of California San Francisco preliminary experience. *Technol Cancer Res Treat* 2007;6(6):595–604. PMID: 17994789.
- [9] Castelli J, Thariat J, Benezery K, Courdi A, Chanalet S, Paquis P, et al. Spinal and paraspinal tumors treated by CyberKnife: feasibility and efficacy. *Cancer Radiother* 2010;14(1):5–10. <http://dx.doi.org/10.1016/j.canrad.2009.09.005>.
- [10] Chen K, Huang L, Cai Z, Shi J, You K, Shen H. Micro-invasive surgery combined with intraoperative radiotherapy for the treatment of spinal metastasis. *Eur Spine J* 2016. <http://dx.doi.org/10.1007/s00586-016-4826-4> [Epub ahead of print]. PMID: 27807777.
- [11] Aich RK, Deb AR, Banerjee A, Karim R, Gupta P. Symptomatic vertebral hemangioma: treatment with radiotherapy. *J Cancer Res Ther* 2010;6(2):199–203. <http://dx.doi.org/10.4103/0973-1482.65248>.
- [12] Robinson Y, Sheta R, Salci K, Willander J. Blood loss in surgery for aggressive vertebral haemangioma with and without embolisation. *Asian Spine J* 2015;9(3):483–91. <http://dx.doi.org/10.4184/asi.2015.9.3.483>.
- [13] Vasudeva VS, Chi JH, Groff MW. Surgical treatment of aggressive vertebral hemangiomas. *Neurosurg Focus* 2016;41(2):E7. <http://dx.doi.org/10.3171/2016.5.FOCUS.16169>.
- [14] Miszczyk L, Tukiendorf A. Radiotherapy of painful vertebral hemangiomas: the single center retrospective analysis of 137 cases. *Int J Radiat Oncol Biol Phys* 2012;82(2):e173–80. <http://dx.doi.org/10.1016/j.ijrobp.2011.04.028>.
- [15] Hao J, Hu Z. Percutaneous cement vertebroplasty in the treatment of symptomatic vertebral hemangiomas. *Pain Physician* 2012;15(1):43–9. <http://dx.doi.org/10.1007/s00117-015-0013-6>.
- [16] Wilhelm K. Vertebroplasty—state of the art. *J Radiol* 2015;55(10):847–52. <http://dx.doi.org/10.1007/s00117-015-0013-6>.
- [17] Binning MJ, Gottfried ON, Klimo Jr P, Schmidt MH. Minimally invasive treatments for metastatic tumors of the spine. *Neurosurg Clin N Am* 2004;15(4):459–65.
- [18] Saito T, Kondo T, Hozumi T, Karasawa K, Seichi A, Nakamura K. Results of posterior surgery with intraoperative radiotherapy for spinal metastases. *Eur Spine J* 2006;15:216–22.
- [19] Kondo T, Hozumi T, Goto T, Seichi A, Nakamura K. Intraoperative radiotherapy combined with posterior decompression and stabilization for non-ambulant paralytic patients due to spinal metastasis. *Spine* 2008;33(17):1898–904. <http://dx.doi.org/10.1097/BRS.0b013e31817c0410>.
- [20] Wenz F, Schneider F, Neumaier C, Kraus-Tiefenbacher U, Reis T, Schmidt R, et al. Kypho-IORT—a novel approach of intraoperative radiotherapy during kyphoplasty for vertebral metastases. *Radiat Oncol* 2010;11(5):11. <http://dx.doi.org/10.1186/1748-717X-5-11>.
- [21] Schmidt R, Wenz F, Reis T, Janik K, Bludau F, Obertacke U. Kyphoplasty and intra-operative radiotherapy, combination of kyphoplasty and intra-operative radiation for spinal metastases: technical feasibility of a novel approach. *Int Orthop* 2012;36(6):1255–60. <http://dx.doi.org/10.1007/s00264-011-1470-9>.
- [22] Reis T, Schneider F, Welzel G, Schmidt R, Bludau F, Obertacke U, et al. Intraoperative radiotherapy during kyphoplasty for vertebral metastases (Kypho-IORT): first clinical results. *Tumori* 2012;98(4):434–40. <http://dx.doi.org/10.1700/1146.12636>.
- [23] Kayser R, Ender SA, Asse E, Wilhelm E, Adler F, Schmidt R, et al. Kyphoplasty in combination with intraoperative radiotherapy. Technical and regulatory characteristics of a concept for treatment of vertebral metastases. *Orthopade* 2013;42(9):765–71. <http://dx.doi.org/10.1007/s00132-013-2071-7>.
- [24] Schneider F, Greineck F, Clausen S, Mai S, Obertacke U, Reis T, et al. Development of a novel method for intraoperative radiotherapy during kyphoplasty for spinal metastases (Kypho-IORT). *Int J Radiat Oncol Biol Phys* 2011;81(4):1114–9. <http://dx.doi.org/10.1016/j.ijrobp.2010.07.1985>.
- [25] Almaghrabi MY, Supiot S, Paris F, Mahé MA, Rio E. Stereotactic body radiation therapy for abdominal oligometastases: a biological and clinical review. *Radiat Oncol* 2012;7:126. <http://dx.doi.org/10.1186/1748-717X-7-126>.
- [26] Corre I, Guillonnet M, Paris F. Membrane signaling induced by high doses of ionizing radiation in the endothelial compartment. Relevance in radiation toxicity. *Int J Mol Sci* 2013;14:22678–96. <http://dx.doi.org/10.3390/ijms141122678>.
- [27] Rades D, Bajrovic A, Alberti W, Rudat V. Is there a dose-effect relationship for the treatment of symptomatic vertebral hemangiomas? *Int J Radiat Oncol Biol Phys* 2003;55:178–81.