



REVIEW

Esophageal Dysfunction in Systemic Sclerosis: An Update

Bo Li · Junqing Yan · Jincheng Pu · Jianping Tang · Shuchang Xu · Xuan Wang

Received: August 3, 2021 / Accepted: September 27, 2021 / Published online: October 9, 2021
© The Author(s) 2021

ABSTRACT

Esophageal motility disorders are prevalent in 90% of patients with systemic sclerosis [scleroderma (SSc)], with an increased mortality rate in patients with severe esophageal involvement. Esophageal smooth muscle damage caused by ischemia, nerve damage, and inflammatory factors may be responsible for discomfort and various complications in these patients. The

clinical manifestations are diverse. Most hospitals still use traditional esophageal manometry and 24-h pH monitoring to diagnose esophageal function in patients with SSc. The aim of this review article is to provide an overview of SSc-related esophageal motility disorders and related research progress, including the pathogenesis and clinical features of these disorders and the progress made in endoscopic diagnosis. We also discuss the possible pathogenesis and potential therapeutic targets.

Keywords: Clinical features; Esophageal motility disorders/physiopathology; Esophageal motility disorders/therapy; Systemic scleroderma; Complications

B. Li · S. Xu (✉)
Department of Gastroenterology, Tongji Hospital,
Shanghai, China
e-mail: xschang@163.com

B. Li · J. Pu · J. Tang · X. Wang (✉)
Department of Rheumatology and Immunology,
Tongji Hospital, Shanghai, China
e-mail: xuan2018@tongji.edu.cn

B. Li
e-mail: 1553040libo@alumni.tongji.edu.cn

J. Pu
e-mail: 1910829@tongji.edu.cn

J. Tang
e-mail: tangjp6512@126.com

J. Yan
Department of Surgery, Tongji Hospital, Shanghai,
China
e-mail: yanjunqing@tongji.edu.cn

Key Summary Points

Esophageal complications in patients with systemic sclerosis (SSc) greatly affect the quality of life of the patient, and even affect the patient's lifespan.

The pathogenesis of these esophageal complications is not clear, but based on correlations between the patient's blood indicators, clinical manifestations and symptoms, it is speculated that the pathogenesis may involve the interaction of vascular factors, immune factors, and neurological factors.

There is no one specific clinical manifestation of esophageal dysfunction in patients with SSc. The relationship between the degree of esophageal reflux and esophageal peristalsis is unclear, but patients with absent esophageal peristalsis are younger and have more serious complications.

The treatment plan for the vascular factors, immune factors, and neurological factors involved in pathogenesis is still being developed. Regulating blood vessel walls to improve vasospasm, new immunosuppressants, and the use of drugs that stimulate esophageal motor nerves are expected to further improve the patient's condition.

INTRODUCTION

Systemic sclerosis (SSc) is a multisystem autoimmune disease characterized by vasculopathy and tissue fibrosis of the skin and various internal organs and has a global incidence of 3 cases per 100,000 population [1, 2]. SSc and gastrointestinal manifestations have been shown to be correlated [3], with > 90% of patients with SSc patients also having different degrees of gastrointestinal dysfunction, which is

regarded as the third leading cause of death in SSc patients [1, 4]. Esophageal micro-reflux, which manifests as dysphagia and reflux heartburn, is the most commonly occurring manifestation of gastrointestinal dysfunction involvement and exacerbates the existing interstitial pulmonary diseases to some extent [5]. Moreover, Barrett's esophagus, esophageal stenosis, and esophageal cancer caused by the development of esophageal motility disorders may also further affect the prognosis of patients with SSc [5, 6].

The 9-year cumulative survival rate of patients with severe esophageal involvement is only 38% [7]. Gastrointestinal involvement as the direct cause of death accounts for nearly 5% of total deaths [8]. However, the pathogenesis and timing of esophageal motility disorders in patients with SSc are still unknown, and the symptoms lack specificity, resulting in difficulty of early detection. Even if the diagnosis is confirmed, there is no appropriate treatment.

We have performed a search of the Pubmed and Google Scholar databases for articles published from January 2000 to 19 July 2021 using the following search items: ("Scleroderma, systemic/complications" AND "esophageal motility disorders") OR ("scleroderma, systemic/therapy" AND/OR "esophageal motility disorders"). Following initial identification of articles, we then further screened the abstracts of these articles. In this article, we review the pathogenesis, clinical manifestations, diagnosis, treatment, and possible therapeutic targets of esophageal motility disorders caused by SSc. This article is based on previously conducted studies and does not contain any new studies with human participants or animals performed by any of the authors.

PATHOGENESIS

The pathogenesis of esophageal motility disorders in patients with SSc is still uncertain. We speculated that the pathogenesis was related to vascular injury, fibrosis, and inflammatory factors, which are more likely to work together or occur in sequence. Many functional tests support the presence of vascular damage, fibrosis,

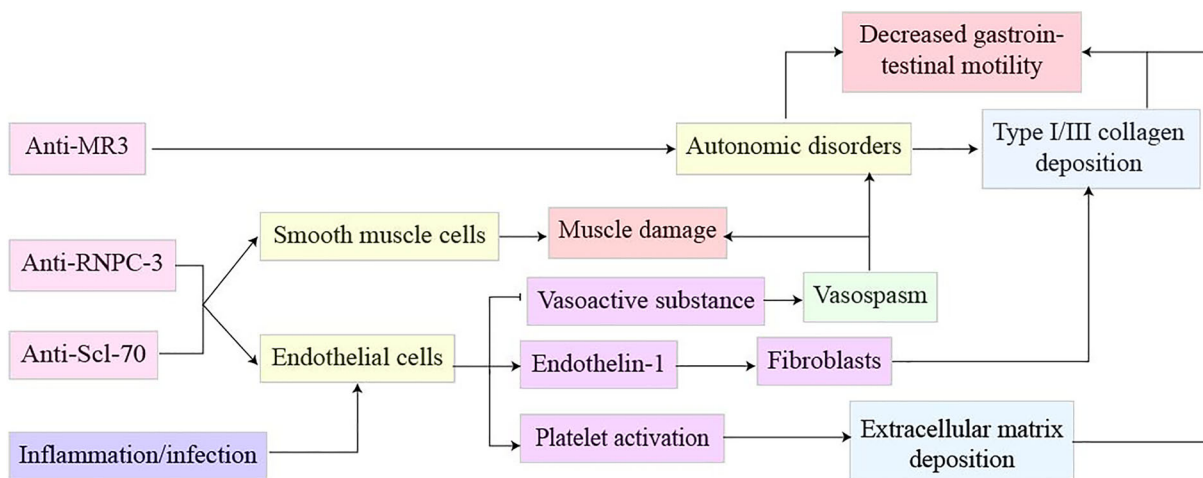


Fig. 1 Possible mechanism of esophageal lesions in patients with systemic sclerosis

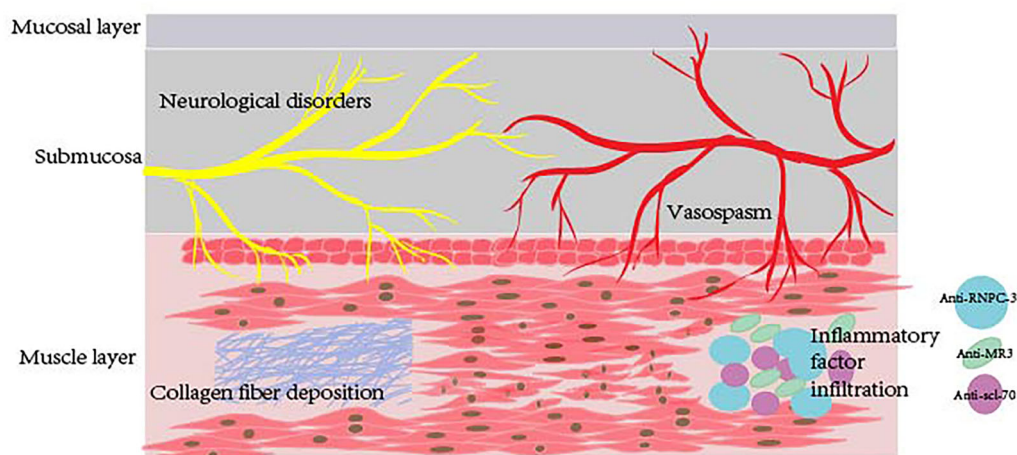


Fig. 2 Simulation diagram of the structure of esophageal lesions in patients with systemic sclerosis

and inflammatory disease, although these three factors may not represent a comprehensive picture and may lead to undiagnosed pathogenesis. In the past, some studies reporting the related pathological observations showed the atrophy of esophageal muscles, without evidence of vascular damage, fibrosis and inflammatory infiltration [9–13]. However, the exact mechanism of esophageal muscle atrophy is not known. Therefore, it can be suggested that there may be alternative mechanisms involved in esophageal muscle atrophy during the progression of the disease. In Figs. 1 and 2 are schematic diagrams of the possible pathogenesis of

the disease and structures involved based on recent results and data. The following mechanisms have been proposed:

- (1) Tissue ischemia and hypoxia caused by vascular injury may lead to the irreversible injury of esophageal muscles and nerves. Raynaud’s phenomenon caused by vasospasms is significantly correlated with the occurrence of esophageal motility disorders [14]. It is speculated that smooth muscle esophageal motor disorders are caused by decreased muscle blood supply and neurodegenerative changes due to the related vasospasms. Associated

pathological studies suggest that intermittent occlusion and spasms similar to Raynaud's phenomenon can occur in the capillaries of vital organs in the body [13]. Vascular endothelial damage caused by repeated ischemic perfusion eventually leads to increased endothelin and platelet activation [13]. Endothelin induces the expression of fibroblasts on smooth muscle, while platelet-derived growth factor (PDGF) and transforming growth factor- β (TGF- β) cause excessive synthesis and deposition of extracellular matrix [13]. Based on these above findings, we suggest that the above mechanism causes nerve damage and collagen deposition, and reduces the blood supply, eventually leading esophageal dyskinesia.

- (2) Fibroblast-related collagen deposition may lead to severe fibrosis of the esophageal tissue, thereby affecting esophageal function. Patients with SSc have increased skin collagen deposition and fibrous tissue [12, 15]. Previous studies have shown that skin thickness in patients with SSc is correlated with the occurrence of esophageal disorders, indicating that increased collagen deposition and fibrous tissue may also occur in the esophageal tissue [1]. Related research has put forward that deposition of type I/III collagen leads to decreased esophageal peristalsis and thickening of the submucosa of the upper gastrointestinal tract [2, 6, 12]. The presence of cell proliferation-related molecules and cyclin-related factors analyses of pathological molecular characteristics indicates the existence of cell proliferation [16].
- (3) The existence of inflammatory factors is generally correlated with the occurrence of esophageal complications. As an immune-related disease, SSc is associated with a large range of autoantibodies, many of which remain undefined. Some studies have shown that there is a relevant association between anti-centromere antibodies [anti-ACA(-)] and anti-topoisomerase I [anti-Scl-70(+)] antibodies in the serum and esophageal disorders [17]. However,

the relevance of these two antibodies to esophageal motility disorders is still controversial. Total esophageal and lower esophageal involvement are widespread in patients with anti-Scl-70(+) antibodies [6]. The above studies have shown that there is likely a correlation between esophageal motility disorders and inflammatory factors in patients. In addition, basic research has found that anti-RNPC-3 (U11/U12) antibodies can be a marker for moderate and severe gastrointestinal lesions as patients with positive antibodies are more likely to develop esophageal motility disorders and reflux [18]. M3 muscarinic acetylcholine receptor (M3R) antibodies, which may restrict excitatory transmission and cause motor dysfunction, have also been shown to be present in patients with SSc [19]. Patients who are positive for anti-citrullinated peptide autoantibody have an increased risk for esophageal complications [20]. Studies on related pathological molecular characteristics have found that esophageal pathology can be divided into two groups. The inflammatory group exhibits the presence of interferon-induced proteins and inflammasomes, suggesting that quite a few patients' esophageal lesions are directly related to inflammation [16].

CLINICAL MANIFESTATIONS

Esophageal motility disorders in patients with SSc present with a variety of clinical symptoms but without specificity. In fact, asymptomatic patients account for 18–50% of SSc patients with esophageal motility disorders [14]. Symptomatic patients show mostly related clinical manifestations that are related to esophageal peristalsis and esophageal acid reflux, such as acid reflux, belching, dyspepsia, heartburn, and pain behind the sternum; the severity of these symptoms is usually not related to the course of disease [21, 22]. Most authors believe that esophageal dysmotility is associated with diffuse SSc [5, 21, 23], the clinical symptoms of which

are not specific and the pathological mechanism not clear. The main manifestations are dysphagia, acid reflux, heartburn, and post-sternal pain, but there may be additional gastrointestinal symptoms, such as indigestion, weight loss, nausea, vomiting, cough, and hoarseness [22, 24].

In a clinical study, Tang et al. found that most patients with heartburn symptoms had no skin involvement and that the esophagus had only early regurgitation, whereas patients with dysphagia had more severe skin involvement and the esophagus showed no contractility [25]. The absence of contractility and acid reflux can be correlated with the severity of esophageal lesions. Mild heartburn (acid reflux) is the more common symptom in the early stages, and severe dysphagia (peristalsis) occurs in the later stages. The physiological development is speculated as follows: esophageal motility disorders first occur with esophageal reflux, which in turn leads to esophageal peristalsis damage [26]. For traditional gastroesophageal reflux disease, esophageal acid reflux is due to anatomical abnormalities or physiological defects related to the peristalsis of the border between the stomach and esophagus [27]. In addition, some cohort studies have shown that esophageal symptoms have nothing to do with the course of the disease, with patients in related studies having only esophageal motility disorders without lower sphincter relaxation and acid reflux [17]. The causal relationship between the occurrence of esophageal symptoms, esophageal motility disorder, lower esophageal sphincter relaxation, and esophageal acid reflux is not clear, and more research in this area is needed.

Long-term esophageal motility disorders in patients with SSc may lead to related complications, such as gastroesophageal reflux, esophagitis, esophageal erosion, esophageal stricture, Barrett's esophagus, esophageal ulcers and, in rare cases, to esophageal diverticulum, adenocarcinoma, and esophageal leukoplakia [4, 21, 22, 28, 29]. It has been suggested that microaspiration caused by reflux of esophageal dyskinesia can also cause pulmonary fibrosis [30, 31]. The diameter of the diseased esophagus is significantly related to the degree of pulmonary fibrosis, and esophageal dilatation

causes atelectasis and aggravates pulmonary fibrosis [14, 15, 17]. However, other authors suggest that pulmonary fibrosis leads to increased lung ventilation and downward movement of the diaphragm and that the use of bronchodilators causes the esophagus to dilate [2, 32]. It is not clear whether there is a causal relationship between lung disease and esophageal motility disorders in patients with SSc or whether simultaneous involvement of these organ systems is a manifestation of advanced disease. However, it is undeniable that early intervention for esophageal disease affects the severity of lung involvement [20].

CLINICAL EXAMINATION AND DIAGNOSIS

The diagnosis of esophageal involvement in patients with SSc requires the clinician to consider a comprehensive range of possibilities and base the diagnosis on such symptoms as esophageal reflux and peristalsis after excluding other diseases. Related SSc clinical guidelines are based on reduced peristalsis of the lower esophagus (grade 1: mild), gastroesophageal reflux disease (grade 2: moderate), reflux esophagitis with dysphagia (grade 3: severe), and esophageal stenosis-related dysphagia (grade 4: very severe) to evaluate the degree of severity of the patient's esophagus involvement [33]. A classical radiology examination shows that the lumen of the esophagus becomes extended, while radiopaque sphere scintillation imaging shows a delay in emptying. However, the specificity and sensitivity of these diagnostic modalities are unsatisfactory [34]. For the initial diagnosis of patients, experts recommend barium imaging, which shows esophageal dilatation and air in the esophagus [2]. However, the sensitivity of this diagnostic modality is lower than that of the esophageal pressure measurement, and early lesions are difficult to detect. Gastrointestinal endoscopy can detect complications, such as esophagitis and Barrett's esophagus, at an early stage [35]. Most patients' upper gastrointestinal endoscopic findings show esophagitis [36] without clear specific manifestations [4, 17, 23, 37]. Early biopsy of

the lower end of the esophagus commonly shows squamous cell gap widening, and late biopsy shows pathological manifestations related to its complications [38]. Endoscopic ultrasonography manifests with hyperechoic lamina propria and muscularis mucosa, suggesting the occurrence of fibrosis [2]. Although the current guidelines have not clarified the timing at which patients should undergo gastrointestinal endoscopy and other related examinations [33], we recommend that all patients with SSc undergo relevant gastrointestinal examinations and assessments early after diagnosis in order to intervene in esophageal complications earlier.

Traditional Manometric Monitoring and Characteristics

Esophageal manometry and 24-h pH monitoring are commonly used in assessing esophageal peristalsis [24]. The typical manifestations of esophageal dyskinesia caused by SSc in esophageal manometry are the absence of contractility or weak peristalsis in the lower third of the esophagus and relaxation of the esophagogastric junction (EGJ) [38–40]. About 60–80% of patients with SSc have abnormal reflux, and 50–90% have abnormal pressure [23]. The amplitude of slow waves in the gastrointestinal tract disappears, and the lower esophageal sphincter (LES) is short and atelectic [23]. Relevant studies have statistically shown that the mean resting pressure of esophageal dyskinesia caused by SSc is decreased to about 9–15 mmHg and that the average esophagogastric junction length is only 1.58 cm (normal width: about 1–3 cm; normal pressure: 10–30 mmHg) [23, 24, 39]. At the same time, the baseline impedance (BI) of SSc patients is lower than that of patients with ordinary reflux patients and healthy individuals [20]. Therefore, BI can be used as an indirect marker to assess esophageal abnormalities. The BI of patients with gastroesophageal reflux decreases only in the distal esophagus, but in SSc patients, it is decreased in the proximal and distal esophagus [40]. The correlation between abnormal esophageal pressure and skin involvement, esophageal symptoms, and severity of pulmonary fibrosis is still

open to discussion [15]. Accumulated evidence suggests that changes in esophageal motility are common in patients with SSc but that these changes may not be related to skin stretch involvement, the presence of interstitial lung disease, or the patient's gastrointestinal complaints [41].

The contraction strength of the esophagus in the healthy population increases from the proximal part to the distal part. In contrast, the contraction range of each part of the esophagus in patients with achalasia is similar, but with reduced pressure [13]. Compared to patients with achalasia, the contraction amplitude of the esophagus in patients with SSc gradually decreases from the proximal part to the distal part [39]. In addition, the total pressure in SSc patients is less than that of achalasia patients [39]. The pressure at the EGJ in patients with achalasia is usually > 15 mmHg, and only about 2% of patients with SSc have achalasia at the same time [42]. Also, the endoscopic functional luminal imaging probe (EndoFLIP) is complementary to high-resolution pressure measurement (HRM) and barium imaging for diagnosis [38]. Twenty-four-hour multichannel impedance and pH monitoring (MII-pH) and wireless esophageal pH monitoring are novel techniques for improving detection [35]. However, there is as yet no completely reliable diagnostic tool, and the application of new detection technologies for such patients is also lacking in supportive data.

High-Resolution Esophageal Pressure Measurement and Characteristics

In recent years, high-resolution pressure measurement has been used as a more sensitive examination method for detecting esophageal function and the early detection of abnormal esophageal motility reserve [43]. The pressure measurement points are more densely distributed in the esophagus, and the pressure measurement results are more accurate. Among asymptomatic patients with SSc, > 85% of patients have abnormal HRM results [17]. According to the latest Chicago classification criteria, most HRM results in patients with

systemic esophageal motility disorders can be categorized as absent contractility (AC) or ineffective esophageal motility (IEM) [4, 44]. AC is a serious obstacle to exercise activities. A few studies have found that contraction in the middle part of the esophagus is more pronounced than in the distal esophagus [6], which suggests that esophageal reflux may not have a clear causal relationship with the occurrence of esophageal peristalsis.

Patients with AC are generally younger and have more severe skin lesions, worse lung function, and other complications that make them even more prone to asymptomatic pericardial effusion [4]. The severity of reflux in patients is significantly related to the degree of esophageal dyskinesia, indicating that AC or IEM will aggravate gastroesophageal reflux, making it more difficult to control the symptoms and more likely that the patient has complications, as well as indicating a worse prognosis. At the same time, some researchers have suggested that multiple rapid swallows (MRS) should be included in the evaluation of patients' peristaltic storage [20]. The abnormal MRS in patients with SSc prove that patients with early SSc have already experienced decreased esophageal peristaltic function reserve [20, 45]. For patients with SSc, the use of HRM at an early stage is a sensitive method that allows the detection of early esophageal lesions, which enables the physician to treat these lesions earlier and more actively.

EXISTING TREATMENT METHODS AND POTENTIAL THERAPEUTIC TARGETS

The focus of current treatment strategies is to control gastroesophageal reflux and improve peristalsis. There is no definitive treatment strategy aimed at controlling disease progression and improving prognosis.

General Treatment

The general life management strategies for this kind of patient is similar to those for people

with gastroesophageal reflux and includes avoiding alcoholic drinks, smoking, and non-steroidal anti-inflammatory drugs (NSAIDs) [2]. The patient is recommended to avoid a supine position after eating and to sleep with a raised pillow. The use of antihypertensive drugs might have a potential effect on this disease. For example, nifedipine can decrease LES pressure, and diltiazem can increase esophageal sphincter pressure and improve Raynaud's phenomenon [2, 46]. Severe malnutrition and low body weight are closely related to early death, and the occurrence of esophageal complications will also affect the nutritional status of patients [47]. Therefore, nutritional intervention for these patients is an important part of any treatment. At present, there is no clear gold standard for nutritional screening of such patients. The nutritional status of patients can be assessed based on the Adapted Malnutrition Universal Screening Test (MUST) score, body mass index, skin wrinkle thickness, and hemoglobin, folic acid, and carotene levels [48]. Once malnutrition has been diagnosed, the patient must be sent for dietary help and/or support from an occupational therapist [48, 49]. Oral, enteral, and parenteral nutrition alone or combined nutritional support should be provided, and when the nutritional status continues to decline after oral or enteral nutrition support, parenteral nutrition support should be given [48].

Medication

Acid-suppressing drugs and prokinetic agents are currently the main treatment. Acid inhibitors include proton pump inhibitors (PPIs) and histamine 2-receptor antagonists (H2RAs) [50]. PPIs, the main class of drugs prescribed for this condition, can be increased to twice the daily full-dose PPI until symptoms are controlled [2]. Current evidence shows that omeprazole can significantly reduce the content of hydroxyproline (an index of collagen deposition) in the esophageal mucosa [51]. However, the efficacy of PPIs for long-term disease development has not been determined. Clinical studies on lansoprazole have shown that it can only relieve symptoms but not restrict the progression of

disease, and there is still no evidence indicating that PPIs can improve esophageal movement [5, 50]. However, long-term acid suppression therapy will be complicated by esophageal candidiasis and intestinal flora disorders. From this point of view, the management of intestinal flora is necessary. At the same time, management of intestinal flora may affect esophageal motility and immune regulation in these patients and relieve the clinical symptoms [52].

H2RAs alter the pressure of LES and control nocturnal esophageal acid reflux when combined with PPIs [50]. Studies indicate that H2RAs reduce the occurrence of reflux esophagitis by alkalinizing gastric juice. However, there is no credible effect on esophageal peristalsis, and the symptoms of dysphagia and esophageal stenosis in patients cannot improve with H2RAs [53].

Potassium-competitive acid blocker (P-CAB), a new H^+/K^+ -ATPase inhibitor, has been shown to have a longstanding and rapid effect in patients with gastroesophageal reflux disease [54]. The authors of a recent study believe that vonoprazan positively improves esophageal erosion but has a limited effect on dysphagia [55].

In the early stage, prokinetic agents, such as mosapride, cisapride, metoclopramide [56], domperidone, erythromycin [57], and trimebutine [33], increase human LES pressure by stimulating cholinergic nerves [2, 58]. However, these agents do not improve food transit in patients at later disease stages. These results indicate that such patients may not have severe myopathy in the early stage and that the muscles respond well to acetylcholine stimulation [58]. Likewise, such drugs cannot stop disease progression. Guidelines recommend the early application of gastric motility drugs to improve symptoms [33]. The combination of PPIs and prokinetic drugs should be considered for improving the symptoms of patients [59].

Esophageal nerve injury affects the response of gastric motility drugs. Buspirone, pyridostigmine, and carbachol have shown short-term effects in improving esophageal movement [60]. Therefore, in terms of the mechanism of esophageal nerve injury in patients, the early

application of related drugs to maintain the sensitivity of muscle nerve response may prolong the action time of gastrodynamic drugs. Cisapil can stimulate the 5-hydroxytryptamine 4 (5-HT₄) receptor and promote esophageal motility [20]. Clinical studies have shown that buspirone, a 5-HT_{1A} receptor agonist, reduces the sensitivity of the 5-HT receptor to increase the resting pressure, especially the pressure of the lower sphincter, and stimulate peristalsis, which can significantly improve the symptoms of esophageal motility [61]. Intravenous immunoglobulin, prucalopride, and baclofen also affect esophageal motility to a certain extent [56]. Some exercises are also promising for improving digestive tract symptoms. Inhalation training can increase the contraction ability of muscles related to the antireflux barrier, but it can only be used as an auxiliary method [62].

Surgery

The main surgical procedures, including fundoplication and gastric bypass, are not recommended as a first-line treatment for these patients [50]. The choice of timing for surgery and the surgical procedure of choice for such patients are not clearly defined [1]. There is symptom improvement after gastric fundus folding, but 30–70% of patients have dysphagia after long-term observation [63]. Some researchers have proposed that gastric bypass surgery is the safer option, with more significant symptom improvement [64]. The use of PPIs and steroid drugs are reduced or completely eliminated within a short time after such surgeries, and the degree of esophagitis also significantly subsides after both kinds of surgeries [64]. The anterior robotic Dor fundoplication, reported by Alonso Andrade, which is associated with a decreased risk of dysphagia, is an effective option for patients [63]. Therefore, the improvement of symptoms should be balanced against the risk of surgical complications when surgeons choose surgical procedures.

Table 1 Potential therapeutic agents, mechanisms, and evidence

Medications	Mechanisms of actions	Supporting evidence
Statins	Reduce cholesterol and protect blood vessel walls Increase circulating endothelial cells Reduce inflammatory cytokine levels	Improve Raynaud's phenomenon [68, 69]
Clonidine	Activate α_2 adrenal receptors	Observations that the esophagus moves faster and the lower sphincter contracts [13]
Treprostinil	Prostaglandins locally dilate blood vessels and increase blood flow to organs	Topical use improves skin perfusion in patients [70]
Fasudil	Inhibit the RhoA/Rho ^a kinase pathway	Animal level prevents skin and lung fibrosis from occurring [71, 72]
Nilotinib/ Imatinib	Inhibit tyrosine kinase affects PDGF ^b and c-Abl ^c and prevents pathological fibrosis	Reduction of dermal thickness and collagen deposition [74–76]
Torvatinib	Inhibit janus kinase prevents the up-regulation of pro-inflammatory and pro-fibrotic markers	Being studied in patients with skin and joint involvement [80]
Tocrituzumab	Anti-IL-6 ^d receptor antibody	Ability to affect fibroblasts early [81–83]
Belimumab/ Rituximab	Specific inhibitor of B lymphocyte stimulating factor	Improvement of fibrosis and microcirculation [84–86]
Abaproxil	Prevent T lymphocyte activation	Improvement of the skin thickness of patients [87]

^a The RhoA/Rho kinase pathway is an important pathway in many cell functions and is related to oxidative stress and vascular damage

^b PDGF (platelet-derived growth factor) promotes the chemotaxis of fibroblasts in tissue repair and is associated with pathological fibrosis

^c c-Abl (cellular Abelson) is a non-receptor tyrosine kinase

^d IL-6 (interleukin 6) is an interleukin that acts as both a pro-inflammatory and anti-inflammatory cytokine

Traditional Chinese Medicine Treatment

It has been reported that patients treated with transcutaneous electrical nerve stimulation achieve a high physiological score (36-Item Short Form Survey) and that gastrointestinal symptoms are significantly improved, including upper gastrointestinal symptoms. This treatment also balances the sympathovagal activity in patients with SSc [65].

Potential Therapeutic Targets

The potential therapeutic drugs are summarized in Table 1 and described in the following subsections.

Targeting vascular injury Statins have been used in patients with SSc because statins can significantly regulate the blood-vessel wall [66] and they reduce the levels of inflammatory cytokines and increase circulating endothelial precursors in a dose-dependent manner [66–68]. Statins have been shown to improve Raynaud's phenomenon in some clinical trials, leading us to speculate that they could improve

esophageal vascular damage [68, 69]. α 2-Adrenergic receptors and the RhoA/Rho kinase pathway are potential therapeutic targets. In clinical trials, clonidine, as an α 2 agonist, improves esophageal peristalsis and the ability of the lower sphincter to contract [2, 13]. Prostaglandin-related drugs that can increase blood flow, such as treprostinil, have been shown to significantly improve the blood flow of the local skin after ion introduction into the skin [70]. Fasudil can inhibit the RhoA/Rho kinase pathway, improve angiogenesis defects, increase circulating endothelial cells, dilate blood vessels, and contribute to the repair of esophageal vessels and the protection of endothelial cells [13]. Although fasudil showed negative results in the treatment of Raynaud's symptoms, it still prevented the occurrence of skin and lung fibrosis *in vivo*. Therefore, it is necessary to understand the role of this drug in the esophagus to further clarify its use based on the disease stage [71, 72].

Target fibrosis process TGF- β and PDGF are related to pathological fibrosis [73]. Tyrosine kinase inhibitors (TKIs), including nilotinib and imatinib, can affect PDGF and promote fibrosis c-Abl (Abelson kinase) [74–76]. *In vitro* experiments have confirmed that these drugs can reduce the thickness of the dermis and the accumulation of collagen [74, 77]. Whether they affect the esophageal smooth muscle in patients with SSc with esophageal dyskinesia should be investigated. Regarding internal fibrosis deposition, Janus kinase (JAK) inhibitors (e.g., torvatinib) that target the pro-fibrosis and pro-inflammatory pathways in macrophages have been proven to prevent the upregulation of some pro-inflammatory markers and pro-fibrotic markers at the molecular level [78]. Applications can reduce the occurrence of fibrosis and change the related symptoms [79]. At present, there are only a few related studies and these are limited to the external body and the skin and joint level [80].

Targeting the inflammatory damage Many inflammatory cells and inflammatory factors are involved in the pathogenesis of autoimmune diseases. Interleukin 6 is a key cytokine in the development of vascular disease. The anti-

interleukin-6 receptor antibody tocilizumab, an inflammatory receptor antibody drug, has entered phase III clinical trials [81]. Its ability to affect fibroblasts in the development of early systemic sclerosis has been confirmed [81–83]. In addition, for B cells and T cells that play an important role in the immune process, researchers have also carried out related studies. Belimumab and rituximab have also been used in patients with SSc, and these drugs have been found to improve the patient's microcirculation and affect fibrosis genes and pathways [84–86]. However, there are very few relevant clinical trials providing clear evidence. Abaproxil improves skin thickness by blocking the activation of T lymphocytes and is also expected to become one of the drugs that affect local symptoms of the digestive tract [87].

FUTURE AND PROSPECTS

Esophageal motility disorders in patients with SSc is a type of esophageal neuromuscular degeneration that has not yet been fully defined. In recent years, researchers have been exploring its specific pathogenesis, clinical features, and treatment methods.

At present, the pathogenesis focuses on three pathways: vascular injury, inflammation, and collagen deposition. The role of inflammatory factors in esophageal lesions is still controversial, and the discovery of key inflammatory factors can help us establish a feasible esophageal injury model. Meanwhile, focusing on whether there are common mechanisms in the pathogenesis of SSc can lead to the identification of the pivotal links that affect disease progression. Related molecular studies classify patients into inflammation and non-inflammation groups, suggesting that there might be different dominant pathogenesis mechanisms in patients. Classifying patients better could help in choosing favorable drugs. Finding the directly related factors of the symptoms can better guide the treatment of patients based on the symptoms. The current guidelines have not yet given clear recommendations on the timing of examinations for such patients. However, because there are no specific clinical

characteristics and the early diagnosis and treatment of such patients are closely related to the prognosis, we advocate that high-resolution esophageal manometry be performed when patients are diagnosed. Although the guidelines strongly recommend the use of PPIs and prokinetic drugs, these drugs will not prevent the progression of patients' esophageal disease, and we urgently need to address the key links in the mechanism. Preventing early blood vessel damage, nerve damage, and inflammation infiltration may lead to a better treatment or even prevent or delay disease development.

Finally, SSc itself has ethnic specificity [88]. Most of the current studies are based on the characteristics of cases in Western European and North American populations. Research on Asian populations is lacking. Therefore, we need to develop a better understanding of esophageal involvement in Asian populations with SSc.

ACKNOWLEDGEMENTS

Funding. The authors are grateful to all members of the Department of Rheumatology and Immunology and the Department of Gastroenterology, Tongji Hospital, Tongji University School of Medicine, for fruitful discussions and contributions. This research and the journal's Rapid Service Fee was supported by the National Natural Science Foundation of China (Grant/Award Number: 81974067, 81801601, 81671598).

Authorship. All named authors meet the International Committee of Medical Journal Editors (ICMJE) criteria for authorship for this article, take responsibility for the integrity of the work as a whole, and have given their approval for this version to be published.

Author Contributions. All authors contributed to the study conception and design. The first draft of the manuscript was written by Bo Li and all authors commented on previous versions of the manuscript. All authors read and approved the final manuscript.

Disclosures. Bo Li, Junqing Yan, Jincheng Pu, Jianping Tang, Shuchang Xu and Xuan Wang have nothing to disclose.

Compliance with Ethics Guideline. This article is based on previously conducted studies and does not contain any new studies with human participants or animals performed by any of the authors.

Open Access. This article is licensed under a Creative Commons Attribution-NonCommercial 4.0 International License, which permits any non-commercial use, sharing, adaptation, distribution and reproduction in any medium or format, as long as you give appropriate credit to the original author(s) and the source, provide a link to the Creative Commons licence, and indicate if changes were made. The images or other third party material in this article are included in the article's Creative Commons licence, unless indicated otherwise in a credit line to the material. If material is not included in the article's Creative Commons licence and your intended use is not permitted by statutory regulation or exceeds the permitted use, you will need to obtain permission directly from the copyright holder. To view a copy of this licence, visit <http://creativecommons.org/licenses/by-nc/4.0/>.

REFERENCES

1. Emmanuel AJ. Current management of the gastrointestinal complications of systemic sclerosis. *Nat Rev Gastroenterol Hepatol.* 2016;13(8):461–72.
2. Ebert EC. Esophageal disease in progressive systemic sclerosis. *Curr Treat Options Gastroenterol.* 2008;11(1):64–9.
3. Alastal Y, Hammad TA, Renno A et al. Gastrointestinal manifestations associated with systemic sclerosis: results from the nationwide inpatient sample. *Ann Gastroenterol.* 2017;30(5):498.
4. Aggarwal N, Lopez R, Gabbard S, Wadhwa N, Devaki P, Thota PN. Spectrum of esophageal dysmotility in systemic sclerosis on high-resolution esophageal manometry as defined by Chicago classification. *Dis Esophagus.* 2017;30(12):1–6.

5. Vischio J, Saeed F, Karimeddini M, et al. Progression of esophageal dysmotility in systemic sclerosis. *J Rheumatol*. 2012;39(5):986–91.
6. Roman S, Hot A, Fabien N, et al. Esophageal dysmotility associated with systemic sclerosis: a high-resolution manometry study. *Dis Esophagus*. 2011;24(5):299–304.
7. Steen VD, Medsger TA. Severe organ involvement in systemic sclerosis with diffuse scleroderma. *Arthritis Rheum*. 2000;43(11):2437–44.
8. Sampaio-Barros PD, Bortoluzzo AB, Marangoni RG, et al. Survival, causes of death, and prognostic factors in systemic sclerosis: analysis of 947 Brazilian patients. *J Rheumatol*. 2012;39(10):1971–8.
9. Roberts CG, Hummers LK, Ravich WJ, Wigley FM, Hutchins GM. A case-control study of the pathology of oesophageal disease in systemic sclerosis (scleroderma). *Gut*. 2006;55(12):1697–703.
10. Miller LS, Liu JB, Klenn PJ, et al. Endoluminal ultrasonography of the distal esophagus in systemic sclerosis. *Gastroenterology*. 1993;105(1):31–9.
11. D'Angelo WA, Fries JF, Masi AT, Shulman LE. Pathologic observations in systemic sclerosis (scleroderma). A study of fifty-eight autopsy cases and fifty-eight matched controls. *Am J Med*. 1969;46(3):428–40.
12. Varga J, Abraham D. Systemic sclerosis: a prototypic multisystem fibrotic disorder. *J Clin Invest*. 2007;117(3):557–67.
13. Wigley FM. Vascular disease in scleroderma. *Clin Rev Allergy Immunol*. 2009;36(2):150–75.
14. Kimmel JN, Carlson DA, Hinchcliff M, et al. The association between systemic sclerosis disease manifestations and esophageal high-resolution manometry parameters. *Neurogastroenterol Motil*. 2016;28(8):1157–65.
15. Kuribayashi S. Relationship between esophageal motility abnormalities and skin or lung involvements in patients with systemic sclerosis. *JGH Open*. 2019;54(11):950–62.
16. Taroni JN, Martyanov V, Huang CC, et al. Molecular characterization of systemic sclerosis esophageal pathology identifies inflammatory and proliferative signatures. *Arthritis Res Ther*. 2015;17(1):194.
17. Vettori S, Tolone S, Capocotta D, et al. Esophageal high-resolution impedance manometry alterations in asymptomatic patients with systemic sclerosis: prevalence, associations with disease features, and prognostic value. *Clin Rheumatol*. 2018;37(5):1239–47.
18. McMahan ZH, Domsic RT, Zhu L, Medsger TA, Casciola-Rosen L, Shah AA. Anti-RNPC-3 (U11/U12) antibodies in systemic sclerosis in patients with moderate-to-severe gastrointestinal dysmotility. *Neurogastroenterol Motil*. 2019;71(9):1164–70.
19. Gyger G, Baron M. Gastrointestinal manifestations of scleroderma: recent progress in evaluation, pathogenesis, and management. *Curr Rheumatol Rep*. 2012;14(1):22–9.
20. Tétréault M-P, Kahrilas P. GI manifestations with a focus on the esophagus: recent progress in understanding pathogenesis. *Curr Rheumatol Rep*. 2019;21(8):42.
21. Lahcene M, Oumnia N, Matougui N, Boudjella M, Touchene B. Esophageal involvement in scleroderma: clinical, endoscopic, and manometric features. *ISRN Rheumatol*. 2011;2011(4):325826.
22. Adarsh MB. Esophageal manometry, esophagogastroduodenoscopy, and duodenal mucosal histopathology in systemic sclerosis. *Rev Assoc Med Bras (1992)*. 2019;3(3):206–9.
23. Arif T, Masood Q, Singh J, Hassan I. Assessment of esophageal involvement in systemic sclerosis and morphea (localized scleroderma) by clinical, endoscopic, manometric and pH metric features: a prospective comparative hospital based study. *BMC Gastroenterol*. 2015;15:24.
24. López NPY, Lugo-Zamudio G, Barbosa-Cobos RE, Wong-Lam A, Torres-López E. Frequency of motor alterations detected through manometry in patients with esophageal symptoms and scleroderma. *Rev Gastroenterol Mex*. 2017;82(2):193.
25. Tang DM, Pathikonda M, Harrison M, Fisher RS, Friedenberg FK, Parkman HP. Symptoms and esophageal motility based on phenotypic findings of scleroderma. 2013;26(2):197–203.
26. Cozzi F, Zucchetta P, Durigon N, et al. Esophageal dysmotility in scleroderma patients with different disease forms and ANA patterns: a scintigraphic study in 100 cases. *Reumatismo*. 2003;55(2):86–92. <https://doi.org/10.4081/reumatismo.2003.86>.
27. Gyawali CP, Kahrilas PJ, Savarino E, et al. Modern diagnosis of GERD: the Lyon Consensus. 2018;67(7):1351–62.
28. Matthew W, Emma W, Dorothy L, Sandra L, Michael C. White esophageal lesions in a patient with scleroderma: epidermoid metaplasia. *Gastroenterol Rep*. 2019;2:2.
29. Chatterjee A, Chaudhury S. A rare case of interaorticobronchial diverticulum of esophagus in a case of scleroderma. *Lung India*. 2013;30(3):222.

30. Bütikofer S, Jordan S, Sauter M, et al. Abnormal esophageal motility during a solid test meal in systemic sclerosis—detection even in very early disease and association with disease progression. *Neurogastroenterol Motil.* 2019;31(1):e13480.
31. Charles SA, Nicole B, Luc L. Lung atelectasis secondary to massive esophageal dilation in a patient with scleroderma. *Can Respir J.* 2010;17(4):96–8.
32. Daisuke T, Arami S, Sheppard TJ, et al. Computed tomography of the esophagus in scleroderma and lung disease. *Tohoku J Exp Med.* 2015;237(4):345–52.
33. Asano Y, Jinnin M, Kawaguchi Y, et al. Diagnostic criteria, severity classification and guidelines of systemic sclerosis. *J Dermatol.* 2018;45(6):633–91.
34. Rutka K, Garkowski A, Karaszewska K, Łebkowska U. Imaging in diagnosis of systemic sclerosis. *J Clin Med.* 2021;10(2):248.
35. Clarke JO, Pandolfino JE. Upper gastrointestinal tract: manifestations of systemic sclerosis. In: Varga J, Denton C, Wigley F, Allanore Y, Kuwana M. (eds) *Scleroderma*. Cham: Springer; 2017, pp. 427–41. https://doi.org/10.1007/978-3-319-31407-5_30.
36. Arif T, Adil M, Sodhi JS. Upper gastrointestinal endoscopy in systemic sclerosis: A cross sectional study. *J Pak Assoc Dermatol.* 2019;29(4):374–83.
37. Denaxas K, Ladas SD, Karamanolis GP. Evaluation and management of esophageal manifestations in systemic sclerosis. *Ann Gastroenterol.* 2018;31(2):165.
38. Chwiesko A, Kowal-Bielecka O, Sierakowski S. Perspectives on the interlinked nature of systemic sclerosis and reflux disease. *Expert Rev Gastroenterol Hepatol.* 2019;13(3):213–27.
39. Mainie I, Tutuian R, Patel A, Castell DO. Regional esophageal dysfunction in scleroderma and achalasia using multichannel intraluminal impedance and manometry. *Dig Dis Sci.* 2008;53(1):210–6.
40. Adarsh MB, Sharma SK, Prasad KK, Dhir V, Singh S, Sinha SK. Esophageal manometry, esophagogastroduodenoscopy, and duodenal mucosal histopathology in systemic sclerosis. *JGH Open.* 2019;3(3):206–9.
41. Markus J, Pinto RMC, Matoso AGB, Ranza R. Esophageal manometry in systemic sclerosis: findings and association with clinical manifestations. *Rev Assoc Med Bras (1992).* 2020;66(1):48–54.
42. Poormoghim H, Dodangheh S, Yaseri H, Jalali A, Andalib E. Disorder by high resolution manometry in systemic sclerosis: association with clinical features. *SM Rheumatol.* 2019;3(1):1005.
43. Schutyser W, Cruyt L, Vulsteke JB, Lenaerts JL, De Langhe E. The role of high-resolution manometry in the assessment of upper gastrointestinal involvement in systemic sclerosis: a systematic review. *Clin Rheumatol.* 2020;39(1):149–57.
44. Rohof WOA, Bredenoord AJ. Chicago classification of esophageal motility disorders: lessons learned. *Curr Gastroenterol Rep.* 2017;19(8):37.
45. Motegi SI, Jordan S, Sauter M, et al. Abnormal esophageal motility during a solid test meal in systemic sclerosis—detection even in very early disease and association with disease progression. *J Gastroenterol.* 2019;31(1):e13480
46. Jean F, Aubert A, Bloch F, et al. Effects of diltiazem versus nifedipine on lower esophageal sphincter pressure in patients with progressive systemic sclerosis. *Arthritis Rheum.* 1986;29(8):1054–5.
47. Assassi S, Del Junco D, Sutter K, et al. Clinical and genetic factors predictive of mortality in early systemic sclerosis. *Arthritis Rheum.* 2009;61(10):1403–11.
48. Harrison E, Herrick AL, McLaughlin JT, Lal S. Malnutrition in systemic sclerosis. *Rheumatology (Oxford).* 2012;51(10):1747–56.
49. Recasens MA, Puig C, Ortiz-Santamaria V. Nutrition in systemic sclerosis. *Reumatol Clin.* 2012;8(3):135–40.
50. Nagaraja V, McMahan ZH, Getzug T, Khanna D. Management of gastrointestinal involvement in scleroderma. *Curr Treat Options Rheumatol.* 2015;1(1):82–105.
51. Hendel L. Hydroxyproline in the oesophageal mucosa of patients with progressive systemic sclerosis during omeprazole-induced healing of reflux oesophagitis. *Aliment Pharmacol Ther.* 1991;5(5):471–80.
52. McMahan ZH, Volkmann ER. An update on the pharmacotherapeutic options and treatment strategies for systemic sclerosis. *Expert Opin Pharmacother.* 2020;21(16):2041–56.
53. Horikoshi T, Sekiguchi T, Kusano M, Matsuzaki T. Effects of famotidine on upper gastrointestinal motility in patients with progressive systemic sclerosis. *Gastroenterol Jpn.* 1991;26(2):145–50.
54. Han S, Choi HY, Kim YH, et al. Randomised clinical trial: safety, tolerability, pharmacokinetics, and pharmacodynamics of single and multiple oral doses of tegoprazan (CJ-12420), a novel potassium-

- competitive acid blocker, in healthy male subjects. *J Aliment Pharmacol Ther.* 2019;50(7):751–9.
55. Tabuchi M, Minami H, Akazawa Y, et al. Use of vonoprazan for management of systemic sclerosis-related gastroesophageal reflux disease. *Biomed Rep.* 2021;14(2):1–1.
56. Tandaipan JL, Castellví IJ. Systemic sclerosis and gastrointestinal involvement. *Rev Colombiana Reumatol (English Edition).* 2020;27:44–54.
57. Miller JB, Gandhi N, Clarke J, McMahan Z. Gastrointestinal involvement in systemic sclerosis: an update. *J Clin Rheumatol.* 2018;24(6):328.
58. Wang SJ, La JL, Chen DY, Chen YH, Hsieh TY, Lin WY. Effects of cisapride on oesophageal transit of solids in patients with progressive systemic sclerosis. *Clin Rheumatol.* 2002;21(1):43–5.
59. Foocharoen C, Chunlertrith K, Mairiang P, et al. Effectiveness of add-on therapy with domperidone vs alginate acid in proton pump inhibitor partial response gastro-oesophageal reflux disease in systemic sclerosis: randomized placebo-controlled trial. *Rheumatology (Oxford).* 2017;56(2):214–22.
60. Ghani S, Serraj I, Salihoun M, Acharki M, Kabbaj N. Esophageal motility disorders in systemic sclerosis. *PAMJ Clin Med.* 2020;2:108. <https://doi.org/10.11604/pamj-cm.2020.2.108.21950>.
61. Karamanolis GP, Panopoulos S, Denaxas K, et al. The 5-HT1A receptor agonist buspirone improves esophageal motor function and symptoms in systemic sclerosis: a 4-week, open-label trial. *Arthritis Res Ther.* 2016;18(1):195.
62. Nobre e Souza MÂ, Bezerra PC, Nobre RA, da Fonseca Holanda ES, dos Santos AA. Increased inspiratory esophagogastric junction pressure in systemic sclerosis: an add-on to antireflux barrier. *World J Gastroenterol.* 2015;21(7):2067–72.
63. Andrade A, Folstein MK, Davis BR. Case report of robotic dor fundoplication for scleroderma esophagus with aperistalsis on manometry. *Int J Surg Case Rep.* 2017;37:69–71.
64. Yan J, Strong AT, Sharma G, et al. Surgical management of gastroesophageal reflux disease in patients with systemic sclerosis. *Surg Endosc.* 2018;32(9):3855–60.
65. Sallam H, McNearney TA, Doshi D, Chen JD. Transcutaneous electrical nerve stimulation (TENS) improves upper GI symptoms and balances the sympathovagal activity in scleroderma patients. *Dig Dis Sci.* 2007;52(5):1329.
66. Abou-Raya A, Abou-Raya S, Helmii M. Statins as immunomodulators in systemic sclerosis. *Ann NY Acad Sci.* 2007;1110:670–80.
67. Gonçalves RSG, Dantas AT, Pereira MC, et al. Statins inhibit cytokines in a dose-dependent response in patients with systemic sclerosis. *Inflammation.* 2019;42(2):407–11.
68. Tingey T, Shu J, Smuczek J, Pope J. Meta-analysis of healing and prevention of digital ulcers in systemic sclerosis. *Arthritis Care Res (Hoboken).* 2013;65(9):1460–71.
69. Sadik HY, Moore TL, Vail A, et al. Lack of effect of 8 weeks atorvastatin on microvascular endothelial function in patients with systemic sclerosis. *Rheumatology (Oxford).* 2010;49(5):990–6.
70. Guigui A, Mazet R, Blaise S, et al. Treprostinil hydrogel iontophoresis in systemic sclerosis-related digital skin ulcers: a safety study. *J Clin Pharmacol.* 2020;60(6):758–67.
71. Fava A, Wung PK, Wigley FM, et al. Efficacy of Rho kinase inhibitor fasudil in secondary Raynaud's phenomenon. *Arthritis Care Res (Hoboken).* 2012;64(6):925–9.
72. Bei Y, Hua-Huy T, Nicco C, et al. RhoA/Rho-kinase activation promotes lung fibrosis in an animal model of systemic sclerosis. *Exp Lung Res.* 2016;42(1):44–55.
73. Gordon JK, Martyanov V, Magro C, et al. Nilotinib (Tasigna™) in the treatment of early diffuse systemic sclerosis: an open-label, pilot clinical trial. *Arthritis Res Ther.* 2015;17(1):213.
74. Zerr P, Distler A, Palumbo-Zerr K, et al. Combined inhibition of c-Abl and PDGF receptors for prevention and treatment of murine sclerodermatous chronic graft-versus-host disease. *Am J Pathol.* 2012;181(5):1672–80.
75. Akhmetshina A, Dees C, Pilecky M, et al. Dual inhibition of c-Abl and PDGF receptor signaling by dasatinib and nilotinib for the treatment of dermal fibrosis. *FASEB J.* 2008;22(7):2214–22.
76. Beyer C, Distler JH, Distler O. Are tyrosine kinase inhibitors promising for the treatment of systemic sclerosis and other fibrotic diseases? *Swiss Med Wkly.* 2010;140:w13050.
77. Distler JH, Distler O. Intracellular tyrosine kinases as novel targets for anti-fibrotic therapy in systemic sclerosis. *Rheumatology (Oxford).* 2008;47(Suppl 5):v10–1.
78. You H, Xu D, Hou Y, et al. Tofacitinib as a possible treatment for skin thickening in diffuse cutaneous

- systemic sclerosis. *Rheumatology (Oxford)*. 2021;60(5):2472–7.
79. Deverapalli SC, Rosmarin D. The use of JAK inhibitors in the treatment of progressive systemic sclerosis. *J Eur Acad Dermatol Venereol*. 2018;32(8):e328.
80. Komai T, Shoda H, Hanata N, Fujio K. Tofacitinib rapidly ameliorated polyarthropathy in a patient with systemic sclerosis. *Scand J Rheumatol*. 2018;47(6):505–6.
81. Khanna D, Lin CJF, Furst DE, et al. Tocilizumab in systemic sclerosis: a randomised, double-blind, placebo-controlled, phase 3 trial. *Lancet Respir Med*. 2020;8(10):963–74.
82. Denton CP, Ong VH, Xu S, et al. Therapeutic interleukin-6 blockade reverses transforming growth factor-beta pathway activation in dermal fibroblasts: insights from the fascinate clinical trial in systemic sclerosis. *Ann Rheum Dis*. 2018;77(9):1362–71.
83. Zacay G, Levy Y. Outcomes of patients with systemic sclerosis treated with tocilizumab: case series and review of the literature. *Best Pract Res Clin Rheumatol*. 2018;32(4):563–71.
84. Gordon JK, Martyanov V, Franks JM, et al. Belimumab for the treatment of early diffuse systemic sclerosis: results of a randomized, double-blind, placebo-controlled, pilot trial. *Arthritis Rheumatol*. 2018;70(2):308–16.
85. Vilela VS, da Silva BRA, da Costa CH, Lopes AJ, Levy RA, Rufino R. Effects of treatment with rituximab on microcirculation in patients with long-term systemic sclerosis. *BMC Res Notes*. 2018;11(1):874.
86. O'Reilly S, van Laar J. B(effector)reaking bad in systemic sclerosis: role of a novel B cell subset. *Clin Exp Immunol*. 2020;201(3):231–2.
87. Misra DP, Ahmed S, Agarwal V. Is biological therapy in systemic sclerosis the answer? *Rheumatol Int*. 2020;40(5):679–94.
88. Lee JS, Kim H, Moon JR, et al. Esophageal involvement and determinants of perception of esophageal symptoms among south koreans with systemic sclerosis. *J Neurogastroenterol Motil*. 2020;26(4):477–85.