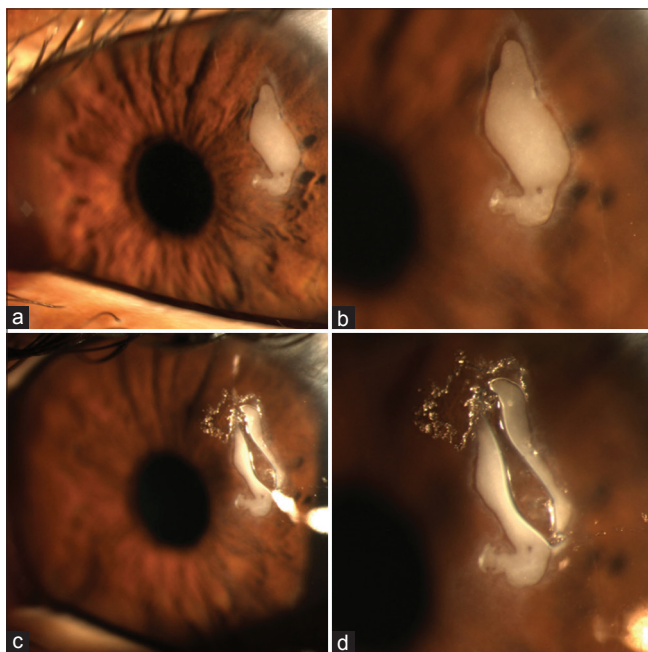


### Epithelial ingrowth following LASIK managed with Nd:YAG laser

A 34-year old presented with a history of foreign body sensation and reduced vision (from irregular astigmatism) after eye rubbing in his left eye following myopic LASIK 10 years ago. Fig. 1a and b shows active epithelial ingrowth at the flap margin.<sup>[1-4]</sup> Fig. 1c and d demonstrates ideal appearance of the epithelial ingrowth following Nd:YAG laser (1 MJ) aimed at creating a discontinuity between the flap edge ingrowth and the inner island to prevent progression. After 3 months, the ingrowth disappeared and patient was emmetropic with no irregular astigmatism. These images can be used as a guide when performing YAG lasers in such cases.

#### Declaration of patient consent

The authors certify that they have obtained all appropriate patient consent forms. In the form the patient(s) has/have given his/her/their consent for his/her/their images and other clinical information to be reported in the journal. The patients understand that their names and initials will not be published



**Figure 1:** (a) Size and extent of epithelial ingrowth at the LASIK flap margin. (b) The magnified view of the epithelial ingrowth and the LASIK flap margin. (c) Epithelial ingrowth following Nd:YAG laser application to create a discontinuity between the LASIK flap edge epithelial ingrowth and the inner island to prevent progression. (d) The magnified view of the Nd:YAG laser-induced discontinuity

and due efforts will be made to conceal their identity, but anonymity cannot be guaranteed.

#### Financial support and sponsorship

Nil.

#### Conflicts of interest

There are no conflicts of interest.

**Mayank A Nanavaty**

Sussex Eye Hospital,  
Brighton, United Kingdom

Correspondence to: Dr. Mayank A Nanavaty,

Sussex Eye Hospital,  
Brighton and Sussex University Hospitals NHS Trust,  
Eastern Road, Brighton - BN2 5BF, United Kingdom.  
E-mail: mayank.nanavaty@nhs.net

#### References

1. Ayala MJ, Alió JL, Mulet ME, De La Hoz F. Treatment of laser *in situ* keratomileusis interface epithelial ingrowth with neodymium: Yttrium-aluminum-garnet laser. *Am J Ophthalmol* 2008;145:630-4.
2. Lindfield D, Ansari G, Poole T. Nd:YAG laser treatment for epithelial ingrowth after laser refractive surgery. *Ophthalmic Surg Lasers Imaging* 2012;43:247-9.
3. Kim JM, Goel M, Pathak A. Epithelial ingrowth - Nd:YAG laser approach. *Clin Exp Ophthalmol* 2014;42:389-90.
4. Ting DSJ, Srinivasan S, Danjoux JP. Epithelial ingrowth following laser *in situ* keratomileusis (LASIK): Prevalence, risk factors, management and visual outcomes. *BMJ Open Ophthalmol* 2018;3:e000133.

This is an open access journal, and articles are distributed under the terms of the Creative Commons Attribution-NonCommercial-ShareAlike 4.0 License, which allows others to remix, tweak, and build upon the work non-commercially, as long as appropriate credit is given and the new creations are licensed under the identical terms.

#### Access this article online

##### Quick Response Code:



##### Website:

www.ijo.in

##### DOI:

10.4103/ijo.IJO\_1825\_18

**Cite this article as:** Nanavaty MA. Epithelial ingrowth following LASIK managed with Nd:YAG laser. *Indian J Ophthalmol* 2019;67:1474.