

Anti-Glutamate $\epsilon 2$ Receptor Antibody-Positive and Anti-N-Methyl-D-Aspartate Receptor Antibody-Negative Lobar Encephalitis Presenting as Global Aphasia and Swallowing Apraxia

Yuki Hayata^a Kensuke Hamada^a Yasuhisa Sakurai^a Izumi Sugimoto^a
Toru Mannen^a Yukitoshi Takahashi^b

^aDepartment of Neurology, Mitsui Memorial Hospital, Tokyo, and ^bNational Epilepsy Center, Shizuoka Institute of Epilepsy and Neurological Disorders, Shizuoka, Japan

Key Words

Anti-glutamate receptor antibodies · Aphasia · Lobar encephalitis · N-methyl-D-aspartate receptor encephalitis · Swallowing apraxia

Abstract

Background: Little is known about the difference between anti-N-methyl-D-aspartate receptor (NMDAR) antibody-positive encephalitis and anti-glutamate receptor (GluR) antibody-positive encephalitis. **Objectives:** To characterize anti-GluR antibody-positive encephalitis. **Methods:** We report a 33-year-old man with nonparaneoplastic anti-GluR $\epsilon 2$, $\zeta 1$ and $\delta 2$ antibody-positive and anti-NMDAR antibody-negative encephalitis, using neuropsychological tests and imaging studies including magnetic resonance imaging and single photon emission computed tomography (SPECT) with a ^{99m}Tc-ethylcysteinate dimer. **Results:** The patient exhibited global aphasia and swallowing apraxia (inability to transfer food to the pharyngeal cavity without sialorrhea). He was treated with 3 courses of corticosteroid pulse therapy and had recovered markedly 3 weeks after onset. Magnetic resonance diffusion-weighted images revealed hyperintensity in the bilateral frontal and left parietal cortices. Seven months later, a small area of hyperintensity in the left supramarginal gyrus remained. SPECT revealed hypoperfusion in extensive regions of the bilateral frontal lobes and left supramarginal gyrus. Thirteen months later, blood flow reduction was restricted to diffuse

Yasuhisa Sakurai, MD, PhD
Department of Neurology
Mitsui Memorial Hospital
1, Kanda-Izumi-cho, Chiyoda-ku, Tokyo 101-8643 (Japan)
E-Mail ysakurai-ky@umin.ac.jp

Hayata et al.: Anti-Glutamate $\epsilon 2$ Receptor Antibody-Positive and Anti-N-Methyl-D-Aspartate Receptor Antibody-Negative Lobar Encephalitis Presenting as Global Aphasia and Swallowing Apraxia

areas in the frontal lobes. **Conclusions:** Frontal lobar encephalitis without medial temporal involvement, marked cognitive impairment with a relatively preserved level of consciousness, and a favorable response to corticosteroid therapy, with nearly reversible cortical damage, may characterize anti-GluR antibody-positive encephalitis.

© 2014 S. Karger AG, Basel

Introduction

Autoimmune encephalitis associated with antibodies against N-methyl-D-aspartate-type glutamate receptors (anti-NMDAR encephalitis) was first reported by Dalmau et al. [1] in 2007. Clinical features are acute limbic encephalitis with personality and behavioral change, catatonia, memory loss, seizures, dyskinesia, and autonomic dysfunction [2–5]. The disease most often involves young women and accompanies ovarian teratoma. However, 40% of patients do not have a detectable tumor, and men are also affected [2]. The clinical manifestation of nonparaneoplastic anti-NMDAR encephalitis (without ovarian teratoma) is similar to that of paraneoplastic anti-NMDAR encephalitis (with ovarian teratoma) [6]. In many cases, the medial temporal lobes and cerebral cortex are affected on MRI [2]. On the other hand, patients with anti-glutamate receptor (GluR) $\epsilon 2$ (NR2B) antibody have been reported to show an association with nonherpetic acute limbic encephalitis (NHALE), Rasmussen's encephalitis, and chronic forms of epilepsy partialis continua [7, 8]. Although anti-NMDAR antibody and anti-GluR $\epsilon 2$ antibody could be simultaneously detected in NHALE [6, 9], some patients had anti-NMDAR antibody but did not have anti-GluR antibody [10], and others vice versa [11]. Little is known about the clinical difference between anti-NMDAR antibody-only encephalitis and anti-GluR antibody-only encephalitis.

We herein report a man with anti-GluR antibody but without anti-NMDAR antibody, presenting with predominantly frontal lobar encephalitis, and discuss the clinical significance of this type of non-paraneoplastic anti-GluR encephalitis.

Case Report

A left-handed, 33-year-old man, an office worker who had graduated from university, presented with progressive speech disturbance in February 2013. He was noted to have difficulty finding words in the office and made grammatical errors on writing e-mails. He was referred to and admitted to our hospital 2 days after disease onset. On neurological examination, the patient exhibited fluctuating consciousness disturbance and difficulty saying words: he could only say 'yes'. He did not obey some simple verbal commands such as eye closing or tongue protrusion. When asked to perform dictation, he repeatedly wrote down a character that was a part of our oral command. He was diagnosed with global aphasia. Once he had raised his arms, he kept them raised until we forced him to stop (catalepsy). No neck stiffness or Kernig's sign was noted.

Laboratory findings were unremarkable. Lumbar puncture showed cerebrospinal fluid (CSF) lymphocytic pleocytosis (cells: 51/mm³, protein: 35 mg/dl), and an elevated IgG index (1.32, normal <0.7). HSV-IgM, HZV-IgM, and HIV antibodies were all negative. Antibodies to N-terminals of NMDA-type GluR including GluN2B ($\epsilon 2$, NR2B) and GluN1 ($\zeta 1$, NR1) [7], and those to the N-terminal of GluD2 ($\delta 2$) were all positive, and the antibody to the NMDAR NR1/NR2 complex (Dalmau's method) [1] was negative in both the CSF and serum. Magnetic resonance imaging (MRI) performed 2 weeks after onset revealed hyperintensity in diffusion-weighted images in the bilateral frontal and left parietal cortices (fig. 1). Electroen-

Hayata et al.: Anti-Glutamate $\epsilon 2$ Receptor Antibody-Positive and Anti-N-Methyl-D-Aspartate Receptor Antibody-Negative Lobar Encephalitis Presenting as Global Aphasia and Swallowing Apraxia

cephalography (EEG) showed diffuse semirhythmic 1- to 2-Hz δ waves with a small amount of 10-Hz α waves superimposed on the δ waves in P-O, which was similar to the ‘extreme delta brush’ in anti-NMDAR encephalitis [12].

On admission, the patient was able to take meals. However, oral intake decreased gradually, and he could not swallow purposely at 6 days after onset. Even if the patient put water in his mouth, the swallowing reflex did not occur, and water finally leaked out through the corners of his mouth. Although sialorrhea was not noted, he choked on his saliva at 10 days after onset, suggesting that voluntary oral transport of the trapped saliva was interrupted. As a result, he was dehydrated and required an intravenous drip. The patient exhibited bulging eyes, became mute and inattentive (he sometimes turned his eyes away while the doctor talked to him), with forced grasping that was more pronounced in the left hand. He was restless in the evening, and tried to leave the bed despite the infusion tube, and so required sedation with intravenous haloperidol. Suspecting herpetic encephalitis, we first administered intravenous acyclovir (1,500 mg/day) from 5 to 7 days after onset, which was ineffective and discontinued because of drug-induced acute renal injury. From 7 to 9 days after onset, he developed a transient partial seizure on the right side of his face and extremities.

Taking the possibility of an autoimmune mechanism into account, we then administered a total of 3 courses of intravenous corticosteroid pulse therapy (methylprednisolone at 1,000 mg/day for 3 days) from 10 to 25 days after onset, and subsequently gave him oral prednisolone at 30 mg/day that was tapered and discontinued for 6 weeks. Immediately after the first pulse therapy, the patient was able to repeat a syllable following the doctor’s example and responded properly to yes-no questions, such as ‘Are you Mr. (patient’s name)?’ He was able to take meals by himself 16 days after onset and spoke some sentences correctly 20 days after onset. EEG performed 23 days after onset showed a moderate amount of 10-Hz α waves with occasional 6- to 7-Hz θ waves.

SPECT with a ^{99m}Tc -ethylcysteinate dimer (ECD-SPECT) performed 3 weeks after onset revealed, for the mean cerebral blood flow (CBF), a reduced blood flow in both hemispheres [early picture (EP) method, left 32.8, right 32.2 ml/100 g/min] with the Patlak plot method and, for the regional CBF, significant hypoperfusion (uncorrected $p < 0.001$, by Statistical Parametric Mapping version 2) in the bilateral frontal convexity and mesial frontal gyri, and the left supramarginal gyrus (fig. 2).

Neuropsychological Assessment

The patient’s cognitive function was evaluated for the first time 21 days after onset. The Mini-Mental State Examination (MMSE) score was 24.7/30: mental arithmetic (serial 7) and auditory comprehension (3-step command) were impaired. The Frontal Assessment Battery (FAB) score was 13/18. The Western Aphasia Battery (Japanese edition) conducted 27 days after onset revealed that spontaneous speech was dysfluent (5/10), with stuttering, halting, and occasional phonemic paraphasia and phonetic distortion (e.g., [handan] \rightarrow [hannan]), suggesting slight apraxia of speech. Auditory comprehension (9.35/10), repetition (9.2/10), naming (9.3/10), reading (9.2/10), and writing (9.85/10) were minimally impaired. Overall, his language profile was rated as slight Broca’s aphasia with apraxia of speech. The Wechsler Adult Intelligence Scale-III conducted 4 weeks after onset revealed a nearly normal cognitive function: verbal IQ 84, performance IQ 80, and working memory 76. The digit span forward score was 4. The Wechsler Memory Scale-Revised conducted 33 days after onset revealed a normal memory function (verbal memory 110, visual memory 101). However, retrograde amnesia for the 3 weeks from onset to recovery remained.

Hayata et al.: Anti-Glutamate $\epsilon 2$ Receptor Antibody-Positive and Anti-N-Methyl-D-Aspartate Receptor Antibody-Negative Lobar Encephalitis Presenting as Global Aphasia and Swallowing Apraxia

The patient returned to work 2 months after onset. The MMSE score at this time was 29/30, the FAB score was 16/18 with word fluency of 7 words/min. Stuttering, halting speech, phonemic paraphasia, and phonetic distortion disappeared 3 months after onset. However, the working memory remained lower (digit span forward, 5) after 1 year. MRI performed 7 months after onset revealed a small area of hyperintensity in the left parietal cortex (fig. 1). In the follow-up SPECT performed 13 months after onset, the reduced blood flow recovered to the normal range (EP, left 46.9, right 46.9 ml/100 g/min) and the regional hypoperfusion was restricted to the diffuse areas of the frontal lobe (fig. 2).

Discussion

The patient presented with global aphasia, swallowing disturbance, abnormal behavior [catalepsy (maintaining a forced posture) and nocturnal delirium], and partial seizure. Global aphasia was characterized by scanty speech and motor perseveration in writing, which resolved to apraxia of speech a few days after corticosteroid pulse therapy.

The swallowing disturbance was voluntary in nature: he had difficulty transporting food to the pharyngeal cavity. In contrast, he swallowed saliva automatically; therefore, he did not exhibit sialorrhea. This automatic-voluntary dissociation in swallowing is characteristic of apraxia. It was clear that the patient did not initiate bolus transfer with a lack of lingual movement during the oral stage. Therefore, the symptom can be diagnosed as swallowing apraxia [13].

It is noteworthy that our patient presented with frontal lobar encephalitis. As described earlier, nonherpetic anti-NMDAR encephalitis usually involves the limbic cortex and is associated with several psychiatric symptoms [2–5]. On the other hand, the clinical features of anti-GluR antibody-positive encephalitis (GluR encephalitis) are similar to those of NMDAR encephalitis with ovarian tumor, except that paraneoplastic NMDAR encephalitis necessitates a longer hospitalization period [6]. It is suggested that in these patients with GluR encephalitis, anti-NMDAR antibody was also positive.

One problem is that in many reported cases of nonparaneoplastic anti-GluR encephalitis, anti-NMDAR antibody was not examined. Thus, the clinical difference between anti-NMDAR encephalitis and anti-GluR encephalitis remains unknown. It is suggested that our patient with lobar encephalitis without medial temporal involvement, marked cognitive impairment with a relatively preserved level of consciousness, and a favorable response to corticosteroid therapy, with nearly reversible cortical damage, characterizes anti-GluR antibody-only encephalitis.

It should also be noted that the lesion was difficult to detect on MRI, whereas the extent of the lesion was easily identifiable on SPECT. This discrepancy suggests that neuronal damage was too mild to produce cytotoxic edema, and only a small area of the left supra-marginal gyrus remained permanently injured. This reversible cortical damage may be another characteristic of anti-GluR antibody-only encephalitis.

Disclosure Statement

The authors declare that they have no conflict of interest.

Hayata et al.: Anti-Glutamate $\epsilon 2$ Receptor Antibody-Positive and Anti-N-Methyl-D-Aspartate Receptor Antibody-Negative Lobar Encephalitis Presenting as Global Aphasia and Swallowing Apraxia

References

- 1 Dalmau J, Tuzun E, Wu HY, Masjuan J, Rossi JE, Voloschin A, Baehring JM, Shimazaki H, Koide R, King D, et al: Paraneoplastic anti-N-methyl-D-aspartate receptor encephalitis associated with ovarian teratoma. *Ann Neurol* 2007;61:25–36.
- 2 Dalmau J, Gleichman AJ, Hughes EG, Rossi JE, Peng X, Lai M, Dessain SK, Rosenfeld MR, Balice-Gordon R, Lynch DR: Anti-NMDA-receptor encephalitis: case series and analysis of the effects of antibodies. *Lancet Neurol* 2008;7:1091–1098.
- 3 Dalmau J, Lancaster E, Martinez-Hernandez E, Rosenfeld MR, Balice-Gordon R: Clinical experience and laboratory investigations in patients with anti-NMDAR encephalitis. *Lancet Neurol* 2011;10:63–74.
- 4 Irani SR, Bera K, Waters P, Zuliani L, Maxwell S, Zandi MS, Friese MA, Galea I, Kullmann DM, Beeson D, et al: N-methyl-D-aspartate antibody encephalitis: temporal progression of clinical and paraclinical observations in a predominantly non-paraneoplastic disorder of both sexes. *Brain* 2010;133:1655–1667.
- 5 Titulaer MJ, McCracken L, Gabilondo I, Armangue T, Glaser C, Iizuka T, Honig LS, Benseler SM, Kawachi I, Martinez-Hernandez E, et al: Treatment and prognostic factors for long-term outcome in patients with anti-NMDA receptor encephalitis: an observational cohort study. *Lancet Neurol* 2013;12:157–165.
- 6 Takahashi Y, Yamazaki E, Nishimura S, Tsunogae H, Niwa K, Dalmau J, Imai K, Fujiwara T: Acute limbic encephalitis and NMDA type-glutamate receptor (in Japanese). *Rinsho Shinkeigaku* 2008;48:926–929.
- 7 Takahashi Y, Kubota Y, Yamasaki E, Matsuda K: Rasmussen encephalitis and non-herpetic acute limbic encephalitis (in Japanese). *Rinsho Shinkeigaku* 2008;48:163–172.
- 8 Takahashi Y, Mori H, Mishina M, Watanabe M, Kondo N, Shimomura J, Kubota Y, Matsuda K, Fukushima K, Shiroma N, et al: Autoantibodies and cell-mediated autoimmunity to NMDA-type GluR $\epsilon 2$ in patients with Rasmussen's encephalitis and chronic progressive epilepsy partialis continua. *Epilepsia* 2005;46(suppl 5):152–158.
- 9 Takahashi Y: Epitope of autoantibodies to N-methyl-D-aspartate receptor heteromers in paraneoplastic limbic encephalitis. *Ann Neurol* 2008;64:110–111, author reply 111–112.
- 10 Ishiura H, Matsuda S, Higashihara M, Hasegawa M, Hida A, Hanajima R, Yamamoto T, Shimizu J, Dalmau J, Tsuji S: Response of anti-NMDA receptor encephalitis without tumor to immunotherapy including rituximab. *Neurology* 2008;71:1921–1923.
- 11 Yamamoto F, Yamaguchi T, Tamaoka A: Case report; a case of anti-glutamate receptor antibody positive limbic encephalitis with positive various autoantibodies (in Japanese). *Nihon Naika Gakkai Zasshi* 2013;102:2057–2059.
- 12 Schmitt SE, Pargeon K, Frechette ES, Hirsch LJ, Dalmau J, Friedman D: Extreme delta brush: a unique EEG pattern in adults with anti-NMDA receptor encephalitis. *Neurology* 2012;79:1094–1100.
- 13 Logemann JA: Evaluation and Treatment of Swallowing Disorders, ed 2. Austin, Pro-Ed, 1998.

Hayata et al.: Anti-Glutamate $\epsilon 2$ Receptor Antibody-Positive and Anti-N-Methyl-D-Aspartate Receptor Antibody-Negative Lobar Encephalitis Presenting as Global Aphasia and Swallowing Apraxia

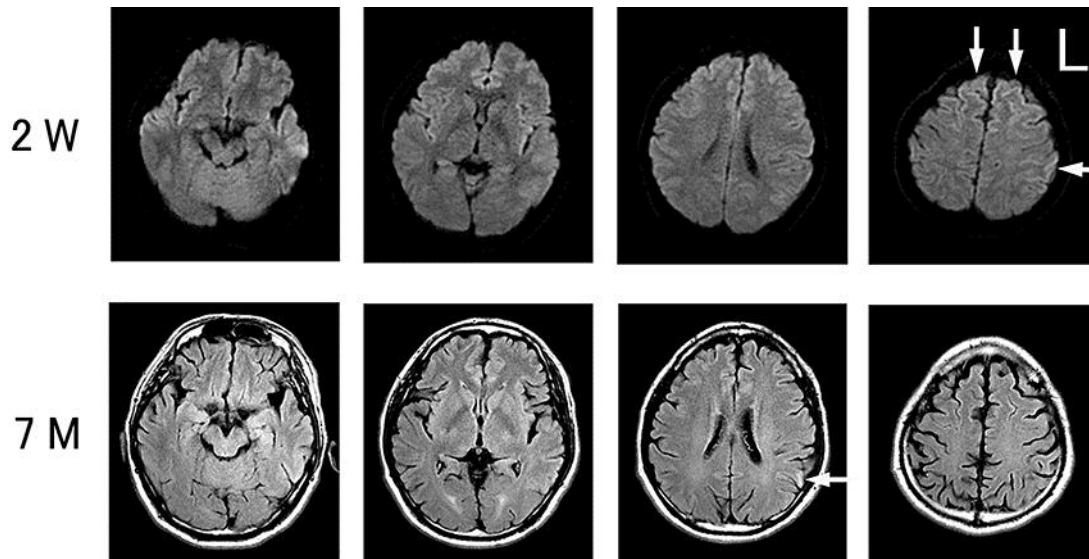


Fig. 1. MRI 2 weeks after onset (2 W) and 7 months later (7 M). Diffusion-weighted axial imaging performed 2 weeks after onset (upper panels) revealed hyperintensity in the bilateral frontal and left parietal cortices (arrows). Fluid-attenuated inversion recovery axial images obtained 7 months after onset (lower panels) revealed a high signal intensity in a small area of the left parietal cortex (arrow).

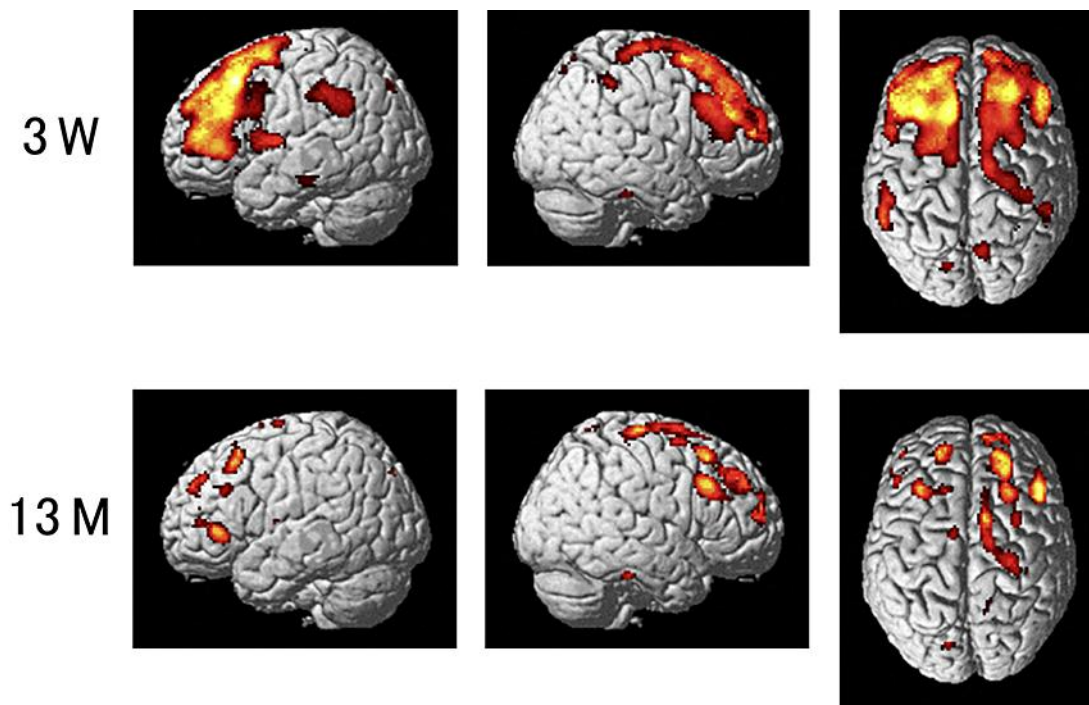


Fig. 2. ^{99m}Tc -ECD-SPECT images 3 weeks (3 W) and 13 months (13 M) after onset. ^{99m}Tc -ECD-SPECT using a 2-sample t test [patient vs. healthy subjects aged between 20 and 39 years ($n = 28$), uncorrected $p < 0.001$] in Statistical Parametric Mapping version 2 revealed hypoperfusion in the bilateral frontal convexity, mesial frontal gyri, and left supramarginal gyrus 3 weeks after onset (upper panels). Regional blood flow reduction was restricted to diffuse areas in the frontal lobes 13 months later (lower panels).