



## Case report

# Pneumococcal purpura fulminans in a 25-year-old patient with liver cirrhosis due to autoimmune hepatitis

Sarah J. Williamson<sup>a,\*</sup>, Rafael Ruiz-Gaviria<sup>b</sup>

<sup>a</sup> Department of Internal Medicine, MedStar Washington Hospital Center, 110 Irving Street NW, Washington, DC 20010, United States

<sup>b</sup> Department of Infectious Diseases, MedStar Washington Hospital Center, 110 Irving Street NW, Washington, DC 20010, United States

## ARTICLE INFO

## Keywords:

Purpura fulminans  
*Streptococcus pneumoniae*  
 Cirrhosis  
 Bacteremia  
 Coagulopathy

## ABSTRACT

Purpura fulminans (PF) is a skin disorder with high morbidity and mortality which is characterized by microvascular thrombosis and development of hemorrhagic necrosis. PF can be caused by acute infection, most commonly due to *Neisseria meningitidis*, followed by *Streptococcus pneumoniae*. Prior reports describe cases of pneumococcal PF occurring in patients with asplenia or hyposplenia, though cases have also been reported in otherwise healthy adults without known splenic disease. Herein, we report a young adult patient with cirrhosis due to autoimmune hepatitis who had not received pneumococcal vaccination and developed rapidly progressive fatal *S. pneumoniae* sepsis with PF.

## Introduction

Purpura fulminans (PF) is a life-threatening purpuric skin condition that develops as a result of microvascular occlusion with associated cutaneous necrosis. The disease is divided into three categories based on pathogenesis: neonatal PF, idiopathic PF, and acute infectious PF [1]. *Streptococcus pneumoniae* is a frequent cause of acute infectious PF, and approximately half of patients with pneumococcal PF have asplenia or hyposplenia [2]. We describe a case of acute infectious PF due to fulminant *S. pneumoniae* sepsis in a 25-year-old female with cirrhosis due to autoimmune hepatitis who had not received pneumococcal vaccination.

## Case

A 25-year-old woman with a history of autoimmune hepatitis presented with acute-onset excruciating bilateral lower extremity pain with edema, ascites, fever, chills, nausea, dizziness, and heavy menorrhagia. She reported having unprotected sexual intercourse two weeks prior to presentation. She had no history of tobacco, alcohol, or substance use. Medication history included acetaminophen and ibuprofen as needed. She previously was prescribed azathioprine and prednisone for the autoimmune hepatitis but reported not currently taking it. It was unclear when she last took immunosuppressive medication, but the prescriptions had not been filled in several months. She had not followed up

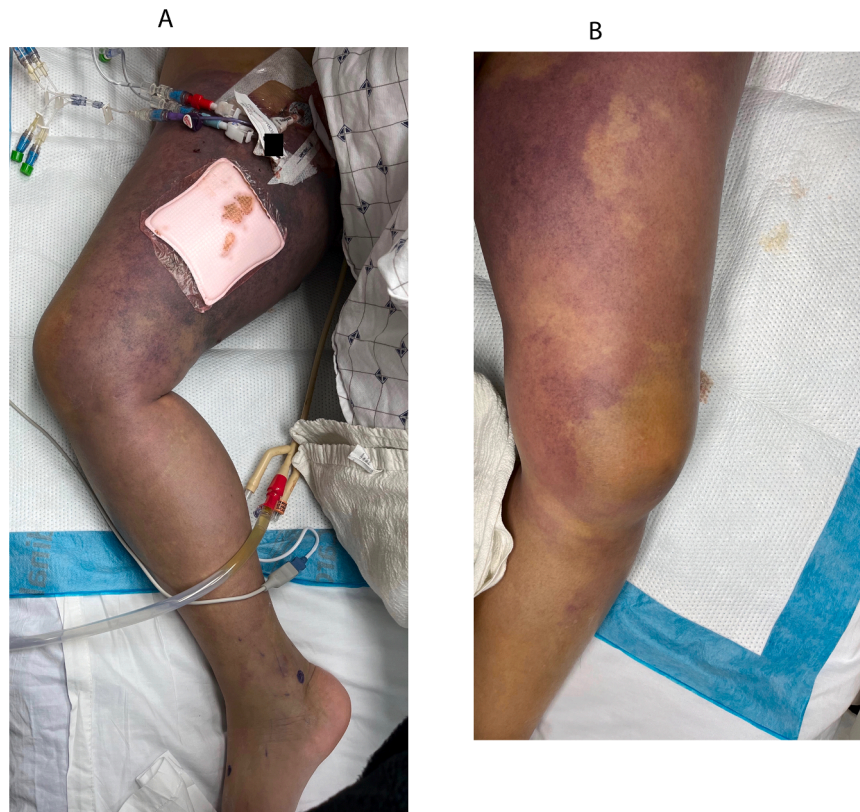
with gastroenterology for over eight months. She had no recent travel history and received vaccination for influenza and COVID-19 four months prior.

Upon presentation to the emergency department, she was hemodynamically unstable with blood pressure 67/39 mmHg, heart rate 129 beats per minute, respirations 33 per minute, and temperature 35.1 degrees Celsius. Physical exam was notable for jaundice, scleral icterus, abdominal ascites with fluid wave, and anasarca including the labia majora, labia minora, and bilateral lower extremities. Pelvic exam demonstrated an erythematous vaginal vault with minimal discharge and no vesicles, lesions, or retained foreign objects. Fine reticular violaceous patches developed on the right proximal thigh within several hours of presentation.

Initial laboratory abnormalities included lactic acidosis (lactic acid 13.1 mmol/L), creatinine 1.49 mg/dL, aspartate transaminase 56 units/L, alanine transaminase 62 units/L, total bilirubin 3.7 mg/dL with direct bilirubin 3.19 mg/dL, alkaline phosphatase 213 units/L, total protein 5.3 g/dL, albumin 1.4 g/dL, hemoglobin 5.2 g/dL, leukocytes 1.3 k/uL, platelets 90 k/uL, prothrombin time 37.9 s, and international normalized ratio 3.9. Beta-human chorionic gonadotropin test was negative. Peripheral smear noted occasional schistocytes. Paracentesis was done with peritoneal fluid analysis notable for leukocyte count 9821 with neutrophilic predominance (82 %). CT angiography of the chest, abdomen, pelvis, and bilateral lower extremities revealed cirrhosis with portal hypertension, large volume abdominal ascites, splenomegaly, and

\* Corresponding author.

E-mail addresses: [sarah.j.williamson@medstar.net](mailto:sarah.j.williamson@medstar.net) (S.J. Williamson), [rafael.e.ruizgaviria@medstar.net](mailto:rafael.e.ruizgaviria@medstar.net) (R. Ruiz-Gaviria).



**Fig. 1.** Development of purpura fulminans secondary to *Streptococcus pneumoniae* sepsis 16 h after admission. (A) Non-blanching ecchymosis with several flaccid bullae present on right lower extremity, covered by wound dressing. (B) Non-blanching ecchymosis on left thigh and shin.

generalized edematous wall thickening of the colon and rectum.

The patient was admitted to the medical intensive care unit and required intubation due to labored breathing and tachypnea. Early resuscitation was provided with intravenous fluids, blood products, and vasopressors. Broad-spectrum antibiotic therapy was initiated including vancomycin, piperacillin-tazobactam, doxycycline, and clindamycin due to concern for possible toxic shock syndrome. She received one dose of intravenous immunoglobulin.

Approximately 16 h after admission, large violaceous non-blanching ecchymoses were present extending from the bilateral proximal thighs to the calves, and several flaccid bullae developed (Fig. 1). Thirty-six hours after admission, the skin over the entire right leg, as well as the left proximal thigh to mid-shin, was dusky and violaceous with sharply demarcated borders adjacent to islands of unaffected skin. Various-sized bullae up to greater than 10 cm filled with red to black-colored fluid were present (Fig. 2).

Further laboratory tests included lactate dehydrogenase 298 units/L, fibrinogen 187 mg/dL, D-dimer > 20 mcg/mL, and urinalysis without signs of infection; salicylate level, acetaminophen level, *Chlamydia trachomatis* and *Neisseria gonorrhoea* nucleic acid amplification tests, and urine toxicology screen were negative. Peritoneal fluid culture was negative. Blood culture from admission grew pan-susceptible *Streptococcus pneumoniae*.

She had progressive hypoxia and shock despite maximal ventilator and vasopressor support, and the patient passed away within 48 h of admission. Autopsy showed a cirrhotic liver with an entirely nodular surface, diffuse alveolar damage, and over five liters of serous fluid in the abdominal compartment.

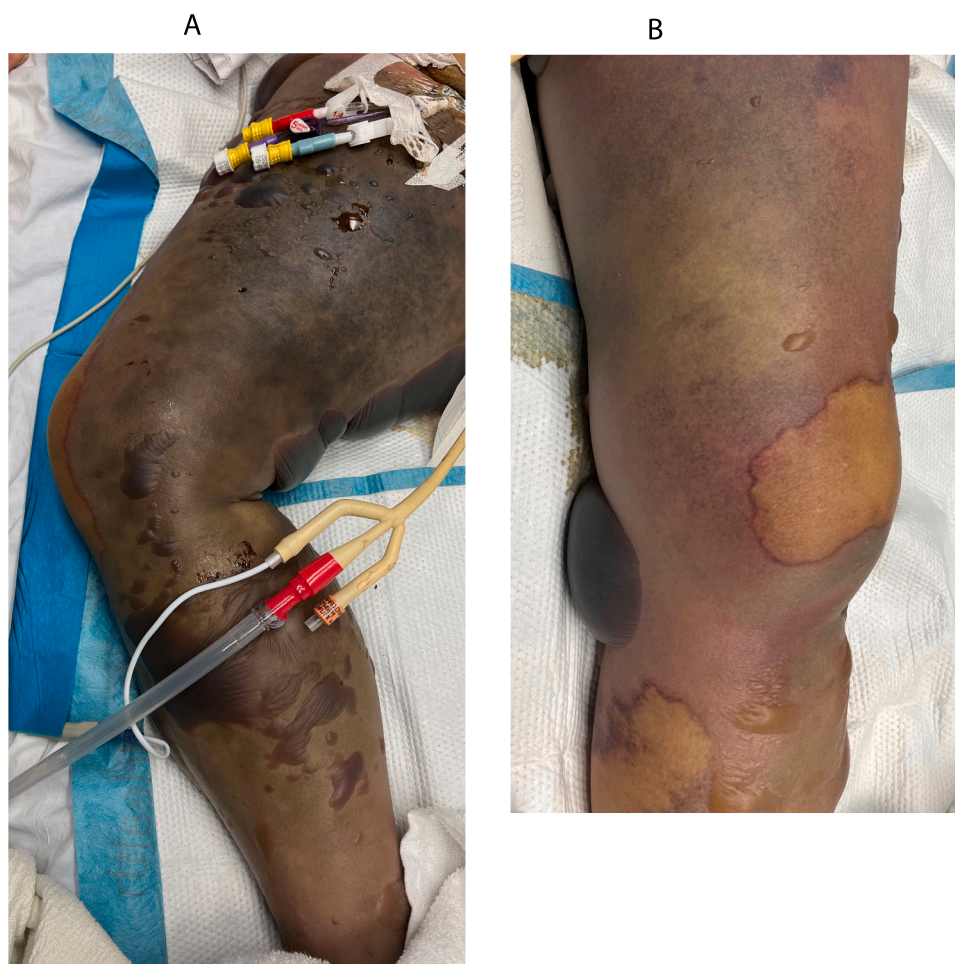
## Discussion

PF is a condition in which cutaneous microvascular thrombosis progresses to hemorrhagic necrosis. The characteristic lesion

morphology includes expanding non-blanching purpura with development of hemorrhagic vesicles and bullae, and sometimes gangrene [3]. The pathophysiology of acute infectious PF has still not been well studied, particularly related to *S. pneumoniae* infection. However, it has been well described that dysregulation of coagulation factors, specifically acquired protein C deficiency and/or defect, is involved, but most investigations have been performed with *N. meningitidis* [3,4].

Several recent reports have been published based on a 17-year multicenter retrospective cohort study performed in France which included patients hospitalized with infectious PF in intensive care units [2–6]. Infectious PF was shown to be associated with 41 % mortality and high morbidity in those who survived: almost one-third required limb amputation [5]. The most common infectious etiology of PF is *N. meningitidis* (64 %), followed by *S. pneumoniae* (22 %) [5]. Numerous case reports describe PF secondary to *S. pneumoniae* infection in the setting of asplenia or hyposplenia [7–11]. Patients who undergo splenectomy are at risk of overwhelming infection and sepsis, particularly due to encapsulated organisms, which are resistant to phagocytosis [12]. Pneumococcal infection is associated with the highest mortality rate in these patients, compared to other bacteria [12]. There have also been reports of pneumococcal PF in patients who are immunocompetent without asplenia or hyposplenia [13,14].

Our patient had no history of asplenia, but imaging and autopsy confirmed hepatic cirrhosis. Domingo et al. reported a case of PF secondary to *N. meningitidis* in a 47-year-old woman with untreated transfusion-acquired chronic hepatitis and cirrhosis noted on autopsy [15]. It was postulated that the patient may have had decreased splenic function due to cirrhosis with portal hypertension [15]. Our case supports this hypothesis as an additional example of a cirrhotic patient with likely associated functional hyposplenia who developed overwhelming sepsis and infectious PF due to another encapsulated organism. Contou et al. reported one patient in their cohort who had a history of cirrhosis and developed pneumococcal PF [2].



**Fig. 2.** Purpura fulminans progression by 36 h after admission. (A) Confluent dusky violaceous ecchymosis with numerous hemorrhagic bullae on entire right leg, with area of sharp demarcation visible on right knee. (B) Dusky gray-violet ecchymosis with sharp borders and various-sized serous and hemorrhagic bullae on left leg.

The management of PF depends on the subtype of disease pathogenesis: neonatal PF, idiopathic PF, or infectious PF. The diagnosis of infectious PF was not established in our patient until after her death when blood culture results became available, but she received supportive care in the medical intensive care unit with appropriate resuscitative measures, adequate timely antibiotic coverage, and multispecialty evaluation. Other treatment options which have been discussed in the literature for infectious PF include intravenous immunoglobulin, plasmapheresis, protein C, fresh frozen plasma, and hyperbaric oxygen, though no guidelines have been established [1,5,16].

Given her history of autoimmune hepatitis and chronic liver disease, our patient should have received the pneumococcal vaccination despite her young age, per guidelines established by the Centers for Disease Control and Prevention. She had not been vaccinated due to lack of health insurance and limited access to the healthcare system. Contou et al. reported that only 35 % of asplenic or hyposplenic patients in their cohort who developed pneumococcal PF had appropriately received pneumococcal vaccination [2].

In conclusion, this case adds to prior reports of acute infectious PF due to fulminant *S. pneumoniae* infection but, to our knowledge, is the only description of this condition in a patient with cirrhosis due to autoimmune hepatitis. PF carries a significant rate of mortality and morbidity, and this case highlights the importance of pneumococcal vaccination in patients with increased vulnerability to encapsulated organisms, as well as early recognition of the characteristic PF rash to prompt appropriate management including timely antibiotic

administration and establishment of a multidisciplinary care team.

#### Funding sources

This research did not receive any specific grant from funding agencies in the public, commercial, or not-for-profit sectors.

#### CRediT authorship contribution statement

Sarah Williamson, MD – Conceptualization, Writing – original draft, Writing – review & editing.

Rafael Ruiz-Gaviria, MD – Conceptualization, Writing – original draft, Writing – review & editing.

#### Ethical approval

Not applicable.

#### Consent

Written informed consent was obtained from the patient's next of kin for publication of this case report and accompanying images. A copy of the written consent is available for review by the Editor-in-Chief of this journal on request.



## Conflict of interest statement

The authors have no conflicts of interest to disclose.

## References

- [1] Edlich RF, Cross CL, Dahlstrom JJ, Long WB. Modern concepts of the diagnosis and treatment of purpura fulminans. *J Environ Pathol Toxicol Oncol Organ Int Soc Environ Toxicol Cancer* 2008;27(3):191–6. <https://doi.org/10.1615/jenvironpatholtoxicoloncol.v27.i3.30>.
- [2] Contou D, Coudroy R, Colin G, Tadié JM, Cour M, Sonnevile R, et al. Pneumococcal purpura fulminans in asplenic or hyposplenic patients: a French multicenter exposed-unexposed retrospective cohort study. *Crit Care Lond Engl* 2020;24(1):68. <https://doi.org/10.1186/s13054-020-2769-y>.
- [3] Lécuyer H, Borgel D, Nassif X, Coureuil M. Pathogenesis of meningococcal purpura fulminans. *Pathog Dis* 2017;75(3). <https://doi.org/10.1093/femspd/ftx027>.
- [4] Colling ME, Bendapudi PK. Purpura fulminans: mechanism and management of dysregulated hemostasis. *Transfus Med Rev* 2018;32(2):69–76. <https://doi.org/10.1016/j.tmr.2017.10.001>.
- [5] Contou D, Sonnevile R, Canoui-Poitrine F, Colin G, Coudroy R, Pène F, et al. Clinical spectrum and short-term outcome of adult patients with purpura fulminans: a French multicenter retrospective cohort study. *Intensive Care Med* 2018;44(9):1502–11. <https://doi.org/10.1007/s00134-018-5341-3>.
- [6] Contou D, de Prost N. HOPEFUL Study group. Clinical phenotype and outcomes of pneumococcal versus meningococcal purpura fulminans: a multicenter retrospective cohort study. *Crit Care* 2021;25(1):386. <https://doi.org/10.1186/s13054-021-03812-1>.
- [7] Asakura T, Higuchi A, Mori N. Streptococcus pneumoniae-induced purpura fulminans. *QJM* 2016;109(7):499–500. <https://doi.org/10.1093/qjmed/hcw060>.
- [8] Hale AJ, LaSalvia M, Kirby JE, Kimball A, Baden R. Fatal purpura fulminans and Waterhouse-Friderichsen syndrome from fulminant Streptococcus pneumoniae sepsis in an asplenic young adult. *IDCases* 2016;6:1–4. <https://doi.org/10.1016/j.idcr.2016.08.004>.
- [9] Komatsu M, Ishihara T, Manabe S, Kuwano K, Oki M, Yanagi H, et al. A case of overwhelming postsplenectomy infection caused by Streptococcus pneumoniae with fulminant purpura. *Tokai J Exp Clin Med* 2017;42(3):130–2.
- [10] Pancharoen C, Chatchatee P, Ngamphaiboon J, Thisyakorn U. Recurrent purpura fulminans associated with drug-resistant Streptococcus pneumoniae infection in an asplenic girl. *Pedia Infect Dis J* 2002;21(1):80–1. <https://doi.org/10.1097/00006454-200201000-00022>.
- [11] White C, Guarascio AJ, Draper HM. Fatal purpura fulminans and septic shock in asplenic patient with Streptococcus pneumoniae bacteremia. *J Am Pharm Assoc* 2014;54(1):88–90. <https://doi.org/10.1331/JAPhA.2014.14505>.
- [12] Tahir F, Ahmed J, Malik F. Post-splenectomy sepsis: a review of the literature. *Cureus* 2020;12(2):e6898. <https://doi.org/10.7759/cureus.6898>.
- [13] Nasrullah A, Javed A, Tariq U, Young M, Moeen Z, Balaan M. Purpura fulminans: a rare but fierce presentation of Pneumococcal sepsis. *Eur J Case Rep Intern Med* 2020;7(1):001373. [https://doi.org/10.12890/2019\\_001373](https://doi.org/10.12890/2019_001373).
- [14] Djurdjevic N, Taweeseed PT, Paulson M, LaNou A, Radovanovic M, Patel JN, et al. Septic shock and purpura fulminans due to Streptococcus pneumoniae bacteremia in an unvaccinated immunocompetent adult: case report and review. *Am J Case Rep* 2020;21:e923266. <https://doi.org/10.12659/AJCR.923266>.
- [15] Domingo P, Sancho F. Neisseria meningitidis and purpura fulminans in a woman with chronic liver disease. *Lancet Infect Dis* 2017;17(4):459. [https://doi.org/10.1016/S1473-3099\(16\)30191-8](https://doi.org/10.1016/S1473-3099(16)30191-8).
- [16] Kim MC, Patel J. Recognition and management of acute Purpura Fulminans: a case report of a complication of Neisseria meningitidis bacteremia. *Cureus* 2021;13(3):e13704. <https://doi.org/10.7759/cureus.13704>.