

# Outcomes of balloon vs basket catheter for clearance of choledocholithiasis: a systematic review and meta-analysis



## Authors

Ruchi Sharma<sup>1</sup>, Vikram Sharma<sup>1</sup>, Umang Singhal<sup>2</sup>, Madhusudhan Sanaka<sup>3</sup>

## Institutions

- 1 Department of Internal Medicine, University of Iowa Hospitals and Clinics, Iowa City, Iowa, United States
- 2 Department of Internal Medicine, Cleveland Clinic Foundation, Cleveland, Ohio, United States
- 3 Digestive Disease Institute, Department of Gastroenterology & Hepatology, Cleveland Clinic, Cleveland, Ohio, United States

submitted 28.2.2022

accepted after revision 18.7.2022

published online 20.7.2022

## Bibliography

Endosc Int Open 2022; 10: E1447–E1453

DOI 10.1055/a-1905-0251

ISSN 2364-3722

© 2022. The Author(s).

This is an open access article published by Thieme under the terms of the Creative Commons Attribution-NonDerivative-NonCommercial License, permitting copying and reproduction so long as the original work is given appropriate credit. Contents may not be used for commercial purposes, or adapted, remixed, transformed or built upon. (<https://creativecommons.org/licenses/by-nc-nd/4.0/>)

Georg Thieme Verlag KG, Rüdigerstraße 14,  
70469 Stuttgart, Germany

## Corresponding author

Ruchi Sharma, University of Iowa Hospitals and Clinics –  
Internal Medicine, 200 Hawkins Drive, Iowa City, IO 52243-  
1009

Fax: +1-319-353-8073

rush1012@gmail.com

ruchi-sharma@uiowa.edu

Supplementary material is available under  
<https://doi.org/10.1055/a-1905-0251>

## ABSTRACT

**Background and study aims** Endoscopic retrograde cholangiopancreatography (ERCP) is the mainstay for treatment of choledocholithiasis. It is unclear whether balloon or basket catheters are better for extraction of stones  $\leq 10$  mm in size. We performed a meta-analysis of studies comparing rates of complete stone extraction and adverse events after ERCP using balloon vs basket catheters for bile duct stones  $\leq 10$  mm in size.

**Methods** Cochrane database, PubMed, Web of Science, and Embase were searched from inception to October 2021. Randomized control trials comparing outcomes of balloon vs basket catheter were included. Data extraction of articles was carried out by two authors using predefined inclusion criteria. Metanalysis was carried out using the Revman 5.4.1. software using a random-effects model.

**Results** Three studies with a total of 508 patients were included in the final analysis. For common bile duct stones  $\leq 10$  mm, balloon catheters had higher complete stone clearance rates than basket catheters (relative risk 1.1, confidence interval 1.03, 1.18,  $P=0.006$ ). Heterogeneity among studies was low ( $\text{Tau}^2 = 0.0$ ;  $P=0.47$ ,  $I^2 = 0\%$ ). There was no difference in the rate of complications.

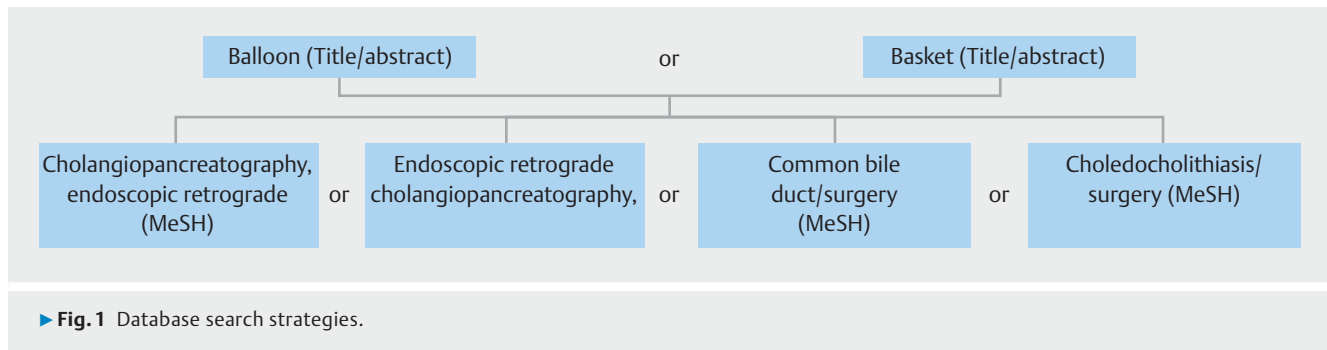
**Conclusions** Meta-analysis of three studies indicates that balloon catheters have a higher success rate compared to basket catheters for complete stone extraction for choledocholithiasis  $\leq 10$  mm with no significant difference in the rate of complications.

## Introduction

Endoscopic retrograde cholangiopancreatography (ERCP) is the standard of care for management of common bile duct (CBD) stones with a success rate of over 80% to 90% [1, 2]. Since the advent of cannulation of the ampulla of Vater in 1960s, and endoscopic sphincterotomy (EST) with stone extraction in 1970s, these procedures have virtually obviated the need for

surgical CBD exploration [3–5]. An estimated 1,606,850 ERCPs were carried out in the United States between 2007 and 2016 [6].

Bile duct stone (BDS) removal is recommended even if asymptomatic because they can lead to complications including obstructive jaundice, cholangitis, and pancreatitis [2, 7]. The initial approach is EST followed by BDS extraction with a catheter that uses either a balloon or basket for extraction.



This is usually sufficient for CBD stones  $\leq 10$  mm in diameter. Larger stones may require advanced methods such as mechanical lithotripsy (ML), laser lithotripsy, or cholangioscopic lithotripsy [2, 8]. Both the American Society for Gastrointestinal Endoscopy (ASGE) and the European Society of Gastrointestinal endoscopy (ESGE) have published guidelines for management of CBD stones, but there is no evidence to support the use of either device over the other [2, 7].

Each device has advantages and disadvantages. Conventional basket catheters have four wires that are used to trap and extract stones. Balloon catheters are inflated above the stone and pulled back sweeping the stone/s with them. ASGE prefers balloon catheters as basket catheters run the risk for impaction, a serious complication, especially with larger stones or inadequate sphincterotomy [1]. Balloon catheters can be deflated and easily removed in such a situation. In addition, small stones can slip through the wires of basket catheters [9]. Balloon catheters are inflated to occlude the CBD, and hence, may be better suited for smaller stones or sludge. In a survey, 98.6% American gastroenterologists preferred balloon catheters because they are considered safer, easier to use, and allow for balloon occlusion cholangiography (BOC) [2, 6]. ESGE does not have any preference. Many European and Japanese centers actually prefer basket catheters because they provide better traction, while balloon catheters can slip past stones, or push stones into the intrahepatic duct, cystic duct or the corner pocket at the lower end of the CBD during extraction [1, 9–11]. Basket catheters are considered more durable, while balloons can rupture [1, 11]. Some basket catheters can also be sterilized and re-used.

While there are some distinct advantages and disadvantages with the use of the respective catheters, both have been pre-

sumed to have similar efficacy [7]. In recent years, a small number of randomized controlled trials (RCTs) have been carried out to compare rates of complete stone extraction and complications using balloon vs basket catheters. Given the discrepancies in the results, we carried out a meta-analysis of these studies.

## Methods

Search strategies were developed by a health sciences librarian with expertise in systematic reviews and primary author for Cochrane database, PubMed, Web of Science, and Embase. Databases were searched from inception to October 2021. Mesh Terms used were 'cholangiopancreatography, endoscopic retrograde', 'choledocholithiasis/surgery', 'common bile duct/surgery' (► **Fig. 1**). To maximize sensitivity, no pre-established database filters were used. Citation list of included papers were searched using Scopus.

## Study selection

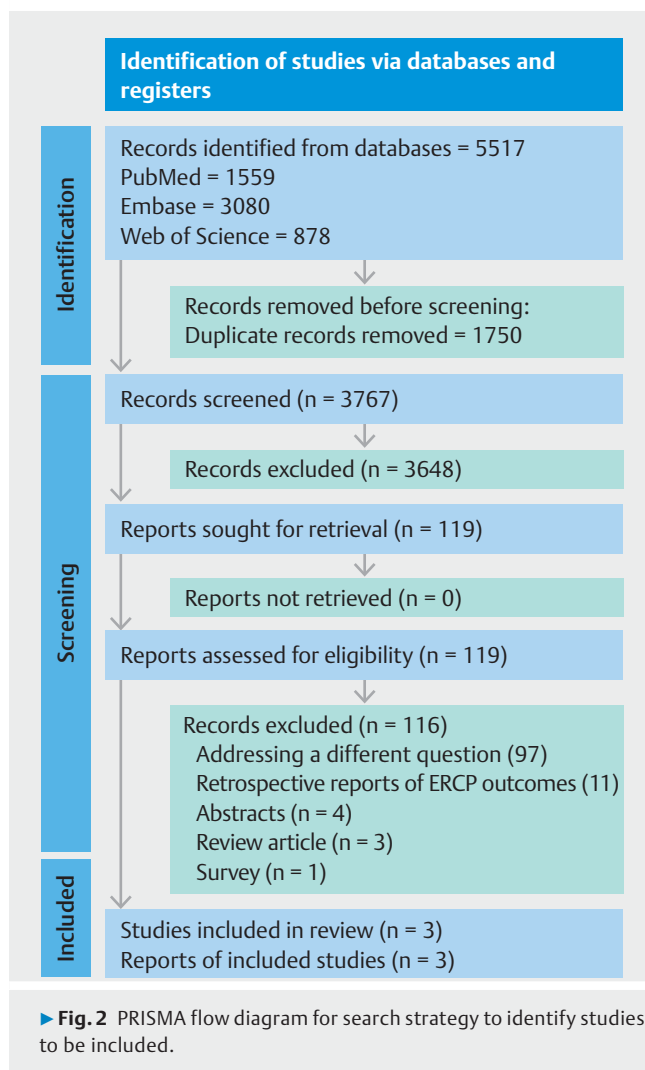
RCTs comparing balloon vs basket catheters for BDS extraction were included. All were well-designed high-quality studies (► **Table 1**). Retrospective and observational studies [12], letters to the editor, and abstracts [13] were excluded. R.S. and V.S. independently screened the database and agreed on final articles for inclusion (► **Fig. 2**). Data were collected independently by R.S. and V.S. and included the primary endpoint of complete stone clearance and complications of ERCP. Reasons for failure of complete stone clearance were recorded. The study was conducted according to the Preferred Items for Systematic Review and Meta-Analysis (PRISMA) guidelines.

► **Table 1** Assessment of the quality of case control studies based on the Newcastle-Ottawa scale.

Study	Study type	Blinding	Selection	Comparability	Outcome
Ekmektzoglou et al. [16]	RCT	Single	****	**	***
Ishiwatari et al. [14]	RCT	Single	****	**	***
Ozawa et al. [10]	RCT	No	****	**	***

RCT, randomized controlled trial.

The scale assigns up to four asterisks for comparability, two asterisks for selection, and three asterisks for outcome



## Study characteristics

### Study design

All studies were prospective, single country RCTs. The study by Ekmektzoglou et al. was a single-center RCT at a high-volume center in Greece with two participating endoscopists with >20 years' experience [9]. Studies by Ozawa et al. and Ishiwatari et al. were multicenter RCTs conducted in Japan [10, 14]. Ozawa et al. had six high-volume ERCP centers with endoscopists proficient in ERCP. Ishiwatari et al. had 12 high-volume centers with 39 endoscopists, 17 experts ( $\geq 4$  years' experience) and 22 trainees (<4 years' experience). If trainees were unsuccessful, the procedure was completed by an expert.

### Inclusion and exclusion criteria for patients

All studies included patients scheduled to undergo ERCP for choledocholithiasis. Ekmektzoglou et al. and Ishiwatari et al. included patients with BDS  $\leq 10$  mm and CBD diameter  $\leq 15$  mm, Ozawa et al. with BDS diameter  $\leq 11$  mm.

Common exclusion criteria included age (<18 years for the Greek study, <20 years for the Japanese studies), biliary stenosis/stricture, gastrectomy apart from Billroth-I, international

normalized ratio >1.5, platelet count <50,000/mL. Other exclusion criteria were prior ERCP, EST or stent insertion; endoscopic papillary large balloon dilatation (EPLBD), prophylactic pancreatic duct stenting, failure to reach papilla, difficult cannulation, cannulation failure, intrahepatic stones, active pancreatitis, severe cholangitis, severe cardiorespiratory disease, Eastern Cooperative Oncology Group performance status  $\geq 4$ , American Society for Anesthesiology status  $\geq 4$ , pregnant or breast feeding, inappropriate per physician's judgment, unable or unwilling to consent.

Ishiwatari et al. included patients with severe cholangitis or on anticoagulation. Patients underwent ERCP with stenting or nasobiliary drainage and were included after cholangitis or coagulopathy had resolved. Ekmektzoglou et al. excluded patients with difficult CBD cannulation as it could affect complication rates.

### Primary and secondary endpoints

Primary endpoint for all studies was rate of complete CBD clearance by the assigned catheter. Ozawa et al. additionally required this to be completed within 10 minutes from CBD cannulation.

Secondary endpoints included adverse events as defined by the ASGE Standards of Practice Committee [15, 16]. Two studies recorded time taken to complete the procedure [9, 14]. One study recorded radiation exposure [9]. For Ozawa et al., complete stone extraction in one endoscopic session, irrespective of initial extraction device, was a secondary endpoint.

### Randomization

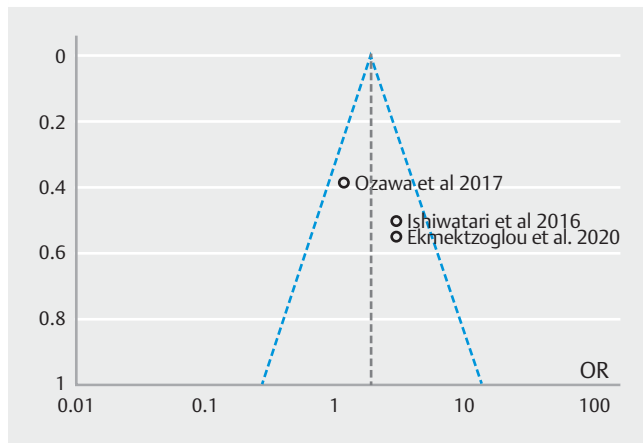
Patients were randomized 1:1 to either the balloon or basket group. Ozawa et al. and Ekmektzoglou et al. randomized patients after stones were identified and measured during ERCP [9, 10]. Ishiwatari et al. randomized patients based on pre-ERCP imaging and excluded them after randomization if they did not meet inclusion criteria on ERCP.

### Procedure techniques

All patients received EST. Ekmektzoglou et al. passed a fully-expanded four-wire basket beyond the stones and used it to capture and extract the stones. If this failed, the process was repeated with the basket partially closed. For multiple BDS, stones were removed individually starting with the most distal stone and moving proximally for both catheters. Complete stone clearance was assessed by contrast injection through the assigned catheter and confirmed on BOC. In case of incomplete clearance with balloon catheter, basket catheter was used and vice versa.

Ozawa et al. used a four-wire basket and multiple stones were removed individually starting with the most distal stone. The balloon catheter was inflated above the stone(s) and pulled back. Complete stone extraction was confirmed on cholangiogram presumably with the assigned catheter.

Ishiwatari et al. used two varieties of basket and balloon catheters. Both baskets had eight wires distally and four wires proximally. For all catheters stones were extracted individually starting with the most distal stone. Complete stone clearance



► **Fig. 3** Funnel plot for results of complete stone clearance.

was confirmed on cholangiogram through assigned catheter followed by balloon sweep and BOC.

In all studies, patients were discharged after 24 hours if no complications occurred. If complications occurred, patients were discharged after appropriate treatment.

### Statistical analysis

Statistical analysis was carried out using Review Manager 5.4.1 statistical package. Meta-analysis for each outcome of interest was conducted with a random-effects model using inverse variance weighting and relative risk as the main effects measure. Heterogeneity between studies was assessed with the  $I^2$  statistic,  $I^2 > 50\%$  and  $P < 0.05$  were considered significant. Funnel plot was generated to qualitatively assess for presence of publication bias (► **Fig. 3**). Results are reported as pooled estimates of the effect size with 95% confidence intervals and  $P$  value for

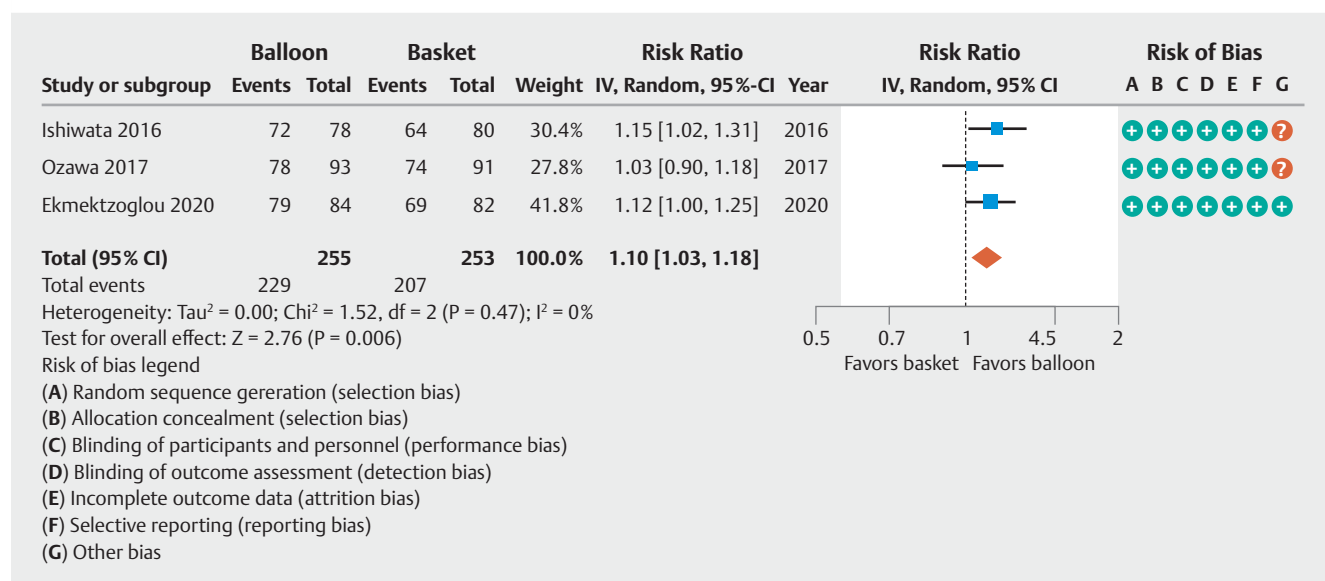
the overall effect. Risk of publication bias was assessed using a Funnel plot. A comprehensive risk of bias assessment was carried out by R.S. and V.S. using the Cochrane Collaboration's tool for assessing risk of bias.

### Results

Three studies were included in the meta-analysis with 255 patients in the balloon group and 253 patients in the basket group. Rate of complete stone clearance was higher in the balloon (229/255; 89.8%) vs basket (207/253; 81.8%) group and this difference was statistically significant on meta-analysis (RR 1.1, CI 1.03, 1.18,  $P = 0.006$ ). Heterogeneity among the studies was low ( $\text{Tau}^2 = 0$ ;  $P = 0.47$ ,  $I^2 = 0\%$ ) (► **Fig. 4**). The meta-analysis did not find any significant difference in the rate of complications such as pancreatitis, cholangitis, bleeding, and perforation (► **Table 2**) (supplementary figures).

Twenty-six patients in the balloon group did not achieve complete clearance, reasons being: 1) stone migrating into intrahepatic or cystic duct (6); 2) stone impaction above the papilla (4); 3) stone impaction in the corner pocket at the lower end of the CBD (4); 4) balloon slipping past the stone (4); 5) acute angulation or stenosis of CBD (4); 6) ML needed (3); and 7) stone lost to sight (1). Complete stone clearance was achieved by exchanging to a basket catheter in 11 patients, after EPLBD in one patient, and after ML in three patients. Fourteen patients required a second ERCP.

In the basket group, 46 patients failed to achieve complete stone clearance. The reasons were: 1) failure to capture the stone (17); 2) residual stone on BOC (9); 3) stone migrating into intrahepatic or cystic duct (6); 3) stone impaction above the papilla (4); 4) basket impaction (2); 5) stone lost to sight (2); 6) acute angulation or stenosis of the CBD (1); and 7) need for ML (1). The procedure time extended beyond 10 minutes



► **Fig. 4** Metanalysis showing that the rate of complete stone clearance in patients with common bile duct stones was significantly higher with use of balloon catheters compared to basket catheters.

► **Table 2** Pooled data for results for primary and secondary outcomes for studies included in the meta-analysis.

	Ekmektzoglou et al. 2020		Ozawa et al. 2016		Ishiwatari et al. 2015	
	Balloon	Basket	Balloon	Basket	Balloon	Basket
Time for complete stone clearance (minutes) <sup>1</sup>	4.06 (1.52–7.26)	4.52 (3.33–3.75)	N/A	N/A	6 (1–30)	7.8 (1–37)
Radiation (Gy) <sup>1</sup>	1245.45 (89.34–5634.34)	1534.43 (245.55–6824.44)	N/A	N/A	N/A	N/A
Pancreatitis	2	2	3	2	2	3
Bleeding	3	2	6	2	0	1
Cholangitis	0	0	1	2	5	6

Gy, gray; N/A, not applicable.

<sup>1</sup> Data represented in median and range.

(Ozawa et al.) in four patients, three of whom achieved complete clearance by persistent use of a basket catheter. Twenty-seven patients achieved complete clearance by exchange to a balloon catheter, six required ML, and 10 needed a second ERCP. Ozawa et al. have documented the need for ML as a reason for failure but did not specify why ML was needed. A funnel plot showed a symmetrical distribution of studies without evidence of publication bias (► **Fig. 3**). Review of individual studies for risk of bias did not reveal any high-risk features in the studies that could have significantly altered the study results.

## Discussion

ERCP is the first line treatment for management of choledocholithiasis and has a success rate of over 80% to 90% [1, 2]. In most cases an EST followed by stone extraction using either a balloon or basket catheter is sufficient. There is no clear consensus for which of these two is preferable. ASGE prefers balloon catheters because of risk of impaction with basket catheters [2]. ESGE has no preference, and many centers in Europe and Japan prefer basket catheters as they are sturdier and provide better traction [1, 11]. We carried out a meta-analysis of three RCT comparing the efficacy of balloon vs basket catheters for complete stone clearance for CBD stones ≤ 10 mm. Meta-analysis indicated that balloon catheter had greater success rate than basket catheters with no difference in the incidence of complications. This difference was statistically significant. However, there is a need for further RCTs to ascertain whether this also translates into a clinically significant difference for patients undergoing these procedures.

The most common reason for failure within the basket group was failure to grasp the stone. Traditional basket catheters have four wires through which stones, especially small stones, can slip [9]. A catheter with a different structure may overcome this issue [17]. For example, Ishiwatari et al. used a catheter with eight wires distally and had the lowest number of patients in whom failure to grasp the stone was a reason for failed extraction (2/17 or 11.8%) (► **Table 3**).

Ozawa et al. did not find a better outcome with balloon extraction in their study. However, they did mention that most of their endoscopists had preferentially used basket catheters

prior to the study. Thus, lesser experience with the balloon catheters may be a reason for lower success rates with the balloon catheter in their study.

One of the perceived downfalls of balloon catheters is that they can cause passage of stones into the intrahepatic or cystic duct, or the corner pocket at the lower end of the CBD. Combined results from the three studies show that stones passed into the intrahepatic or cystic duct in six patients in both the groups (► **Table 3**). Impaction at the lower end of the CBD was seen in eight patients in the balloon group (4 above the papilla and four in the corner pocket) and six patients in the basket group (4 above the papilla and two basket impaction) (► **Table 3**).

It is recommended that multiple stones be extracted individually starting with the most distal stone to prevent stone impaction [18]. This was adhered to in most cases, however according to the procedure description by Ozawa et al. they passed the balloon above the stone(s) before pulling them out. This could introduce procedural bias as it would increase the risk of stone impaction. All four cases of stone impaction at the corner pocket at the lower end of the CBD belong to this group indicating importance of removing stones individually (► **Table 3**).

An interesting finding by Ishiwatari et al. was that BOC is superior to conventional cholangiography for detecting residual stones. Residual stones not demonstrated on conventional cholangiography were found on BOC in nine patients (► **Table 3**). Clinical significance of residual stones is unclear [19, 20]. The treatment goal for choledocholithiasis is complete clearance [2]. While 2- to 3-mm stones may pass, larger stones can get impacted, especially with papillary edema in the aftermath of ERCP, causing cholangitis.

For Ishiwatari et al. the CBD was swept by a balloon prior to BOC and one can argue that had balloon sweep been omitted, residual stones may have been detected in an even greater number of patients in the basket group [21]. Ability to carry out BOC without changing the catheter is another advantage of a balloon catheter. Ozawa et al. found diameter < 6 mm to be independently associated with failed stone extraction.

Some minor differences were noted. Ozawa et al. had a cut-off ≤ 11 mm for BDS diameter, which was ≤ 10 mm for the other

**► Table 3** Pooled data for rate of complications, reasons for failure of stone extraction and final outcomes associated with patients undergoing CBD stone extraction using balloon vs basket catheters from all three studies.

	Balloon	Basket
Total patients	255	253
Complete stone clearance	229	207
<b>Complications</b>		
Pancreatitis	7	7
Cholangitis	6	8
Bleeding	9	5
Perforation	0	0
<b>Reason for failure of complete stone extraction</b>		
Failure to capture stone	0	17
Residual stone on BOC <sup>1</sup>	0	9
Stone migrated into intrahepatic or intracystic duct	6	6
Stone impaction above the papilla	4	4
Stone impaction in the corner pocket at the lower end of the CBD	4	0
Balloon slipped past stone	4	0
Procedure extended beyond 10 minutes <sup>2</sup>	0	4
Acute angulation or stenosis of the CBD	4	1
need for ML	3	1
Basket impaction	0	2
Stone lost to sight during procedure	1	2
<b>Final outcome</b>		
Exchange to basket/balloon catheter <sup>2</sup>	11	27
EPLBD needed	1	0
ML needed	3	6
second ERCP needed	14	10
Persistent use of same catheter beyond 10 minutes <sup>3</sup>	0	3

CBD, common bile duct; EPLBD, endoscopic papillary large balloon dilatation; ERCP, endoscopic retrograde cholangiopancreatography.

<sup>1</sup> Only applicable to Ishiwatari et al.

<sup>2</sup> Only applicable to Ozawa et al.

<sup>3</sup> Basket catheter was used in patients initially treated with balloon catheter and vice versa.

two studies. They did not have a cut-off for CBD diameter. Ekmeztoglou et al. was a single-center study with two highly skilled endoscopists ensuring minimal procedural variation. The Japanese studies were multicenter studies with multiple participating endoscopists. Ishiwatari et al. additionally involved trainees. While we would expect more variation with

methodology, it also makes the results of the study more generalizable.

Ekmeztoglou et al. and Ozawa et al. randomized patients after confirming CBD and BDS diameter on ERCP. Ishiwatari et al. randomized them based on pre-ERCP imaging. Exclusion of patients after randomization could introduce selection bias. Ishiwatari et al. used two different types of balloon and basket catheters, but there was no difference in rate of stone extraction within each group.

The limitation of our study is that only three RCT have been conducted on this topic, and these were only for stones  $\leq 10$  mm in diameter. Some disadvantages of basket catheters may be overcome with larger stones. There are also minor variations in the individual methodologies that may introduce a bias as discussed above.

## Conclusions

Meta-analysis of three studies showed that balloon catheters are superior to basket catheters for complete stone extraction for choledocholithiasis  $\leq 10$  mm with no significant difference in the rate of complications. These findings favor the use of balloon catheters over basket catheters for initial stone extraction for BDS  $\leq 10$  mm. The reason balloon catheters are used in the United States is safety. However, based on our study, balloon catheters may also be superior to basket catheters for stone extraction. These findings are relevant for review of current clinical practice in institutes and countries where use of basket catheters is the preferred method. More multicenter trials are needed to confirm the findings from our meta-analysis and guide practitioners regarding the most appropriate choice of catheters for stone extraction in patients with choledocholithiasis  $\leq 10$  mm in size. More studies are also needed to investigate the use of eight wired basket catheters, especially for smaller stones.

## Acknowledgments

The authors thank Jennifer Deberg, MLS, Hardin Library for the Health Sciences, for assistance with literature search.

## Competing interests

The authors declare that they have no conflict of interest.

## References

- [1] Seitz U, Bapaye A, Bohnacker S et al. Advances in therapeutic endoscopic treatment of common bile duct stones. *World J Surg* 1998; 22: 1133–1144
- [2] Maple JT, Ikenberry SO et al. ASGE Standards of Practice Committee. The role of endoscopy in the management of choledocholithiasis. *Gastrointest Endosc* 2011; 74: 731–744
- [3] McCune WS, Shorb PE, Moscovitz H. Endoscopic cannulation of the ampulla of Vater: a preliminary report. *Ann Surg* 1968; 167: 752–756

- [4] Classen M, Demling L. [Endoscopic sphincterotomy of the papilla of Vater and extraction of stones from the choledochal duct (author's transl)]. *Dtsch Med Wochenschr* 1974; 99: 496–497
- [5] Kawai K, Akasaka Y, Murakami K et al. Endoscopic sphincterotomy of the ampulla of Vater. *Gastrointest Endosc* 1974; 20: 148–151
- [6] Kröner PT, Bilal M, Samuel R et al. Use of ERCP in the United States over the past decade. *Endosc Int Open* 2020; 8: E761–E769
- [7] Manes G, Paspatis G, Aabakken L et al. Endoscopic management of common bile duct stones: European Society of Gastrointestinal Endoscopy (ESGE) guideline. *Endoscopy* 2019; 51: 472–491
- [8] Angsuwatcharakon P, Rerknimitr R. Cracking difficult biliary stones. *Clin Endosc* 2021; 54: 660–668
- [9] Ekmektzoglou K, Apostolopoulos P, Dimopoulos K et al. Basket versus balloon extraction for choledocholithiasis: a single center prospective single-blind randomized study. *Acta Gastroenterol Belg* 2020; 83: 577–584
- [10] Ozawa N, Yasuda I, Doi S et al. Prospective randomized study of endoscopic biliary stone extraction using either a basket or a balloon catheter: the BasketBall study. *J Gastroenterol* 2017; 52: 623–630
- [11] Itoi T, Wang HP. Endoscopic management of bile duct stones. *Dig Endosc* 2010; 22: S69–S75
- [12] Takeshita K, Asai S, Fujimoto N et al. Comparison of the effects of retrieval balloons and basket catheters for bile duct stone removal on the rate of post-ERCP pancreatitis. *Hepatobiliary Pancreat Dis Int* 2021; 20: 203–204
- [13] Choo L, Cho SS, Bell CJ et al. Extraction balloon is superior to wire basket technique in the management of CBD stones less than or equal to 10 mm – Preliminary results of a prospective, randomised trial. *Gastrointestinal Endoscopy* 2011; 73: AB357
- [14] Ishiwatari H, Kawakami H, Hisai H et al. Balloon catheter versus basket catheter for endoscopic bile duct stone extraction: a multicenter randomized trial. *Endoscopy* 2016; 48: 350–357
- [15] Chandrasekhara V, Khashab MA. ASGE Standards of Practice Committee. et al. Adverse events associated with ERCP. *Gastrointest Endosc* 2017; 85: 32–47
- [16] Cotton PB, Eisen GM, Aabakken L et al. A lexicon for endoscopic adverse events: report of an ASGE workshop. *Gastrointest Endosc* 2010; 71: 446–454
- [17] Yasuda I. Novel retrieval basket for small bile duct stones. *Dig Endosc* 2015; 27: 712
- [18] Binmoeller KF, Schafer TW. Endoscopic management of bile duct stones. *J Clin Gastroenterol* 2001; 32: 106–118
- [19] Mutignani M, Shah SK, Foschia F et al. Transnasal extraction of residual biliary stones by Seldinger technique and nasobiliary drain. *Gastrointest Endosc* 2002; 56: 233–238
- [20] Itoi T, Sofuni A, Itokawa F et al. Evaluation of residual bile duct stones by peroral cholangioscopy in comparison with balloon-cholangiography. *Dig Endosc* 2010; 22: S85–S89
- [21] Kadayifci A, Cemil Savas M. Do we overestimate the performance of the basket catheter for stone removal if the bile duct is swept with a balloon? *Endoscopy* 2016; 48: 867