

Soft tissue attenuation in middle ear on HRCT: Pictorial review

Arangasamy Anbarasu, Kiruthika Chandrasekaran, Sivasubramanian Balakrishnan

Department of Radiology and Imaging, SRL Diagnostic Hitech Scan Centres, RS Puram, Coimbatore, Tamil Nadu, India

Correspondence: Dr. Arangasamy Anbarasu, SRL Diagnostic Hitech Scan Centres, 178 Bhasyakaralu Street East, RS Puram, Coimbatore - 641 002, Tamil Nadu, India. E-mail: aanbarasu@gmail.com

Abstract

Middle ear disease is a common clinical entity; imaging, especially High resolution Computed Tomography (HRCT), plays a crucial role in diagnosis and assessing the disease extent, helping to decide appropriate management. Temporal bone imaging is challenging and involves thorough understanding of the anatomy, especially in relation to HRCT imaging. Most of the middle ear pathologies appear as “soft tissue” on imaging. Careful analysis of the soft tissue on the HRCT is crucial in achieving the right diagnosis; clinical information is essential and the imaging findings need correlation with clinical presentation and otoscopic findings. The purpose of this pictorial essay is to enlist the pathologies that present as soft tissue in middle ear and to provide a structured and practical imaging approach that will serve as a guide for confident reporting in daily practice.

Key words: Computed tomography; disease; HRCT; middle ear; soft tissue; temporal bone

Introduction

Middle ear disease is common, but has varied presentations and sequelae. Imaging plays an important role in the management of middle ear pathology. Temporal bone imaging is challenging and involves deep understanding of the anatomy, especially in relation to High Resolution Computed Tomography (HRCT) imaging. Cross-sectional imaging has evolved rapidly and has surpassed the radiography and plain film tomography.^[1,2] Most of the middle ear pathologies appear as soft tissue attenuation on HRCT.^[3,4] The final diagnosis is usually a combination of radiological and clinical findings.^[1,5]

Disorders of the middle ear are common in the population. Middle ear disease can present as ear pain, otorrhea, hearing impairment and other symptoms.^[6] The symptoms vary between individuals in character and intensity. Some of

the middle ear diseases (e.g., inflammation and neoplastic disease) can become serious medical problems if not identified and treated, with involvement of the inner ear, brain and systems beyond.^[7]

HRCT excels in the evaluation of the middle ear disease process and adjacent bone. In certain cases, routine and contrast-enhanced Magnetic Resonance Imaging (MRI) scores over HRCT in the evaluation of middle ear soft tissue; however, in most instances, it acts as a next step for confirmation and further characterization.^[1,8]

Careful and thorough evaluation is needed for the early diagnosis and treatment of the disease, to prevent complications and preserve hearing. The extent of disease often will determine the aggressiveness of the surgical approach.^[7,8] The various associated complications like facial nerve paralysis, labyrinthine fistula, and intracranial complications are well recognized preoperatively by careful interpretation of the appropriate imaging.

By following a methodical approach when assessing soft tissue in the middle ear, one can arrive at a correct diagnosis and comment on the extent of disease and the impending complications. This pictorial essay aims to provide such a systematic and easy approach. Post surgery related changes in middle ear are not included in this article.

Access this article online

Quick Response Code:



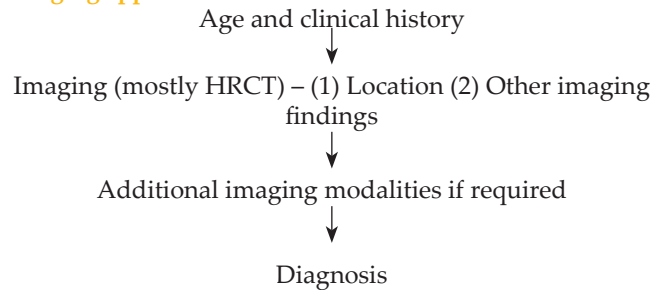
Website:
www.ijri.org

DOI:
10.4103/0971-3026.111483

Materials and Methods

Evaluation of middle ear soft tissue is most commonly done with HRCT using the “bone algorithm.” Unless a vascular abnormality, a tumor, or another enhancing lesion such as an intracranial abscess is suspected, studies are usually performed without intravenous contrast administration. At times it is necessary to use MRI for satisfactory tissue characterization.

Imaging approach



- Age group [Table 1] Pediatric or adult
- Clinical history [Table 2] Otagia (acute/chronic), otorrhea (acute/chronic), hearing loss (conductive or mixed), tinnitus (pulsatile or non-pulsatile), trauma
- Location [Table 3] Epitympanum, mesotympanum, hypotympanum
- Imaging findings: Location, extent, bony erosions, CT attenuation value, contrast enhancement (if any)

Imaging findings

Otomastoiditis

This is a common condition in both adults and children.^[7] On HRCT, the simple serous otitis (glue ear), effusion, and suppurative otitis – all may appear similar, but the ENT surgeon can usually differentiate with clinical history and examination findings. It is important to know what the referring consultant thinks when evaluating such cases. Ossicular chain is intact and bony erosions are rare (less than 10%). The aim of HRCT is to ensure that there is no underlying cholesteatoma or other complications.

Key HRCT findings - otomastoiditis: [Figure 1A and B]

- Soft tissue / fluid attenuation at middle ear, aditus, antrum and mastoid cells – i.e., around epitympanum, extending to mastoid
- No ossicular or bone erosion
- Fluid levels at the mastoid cells

Coalescent mastoiditis will result in loss of septae separating the cells in mastoid and may result in cavity formation [Figure 2]. Inflammatory debris can be present as linear strands within the middle ear, in previously inflamed, or infected ear;^[9] it cannot be differentiated from early cholesteatoma when there are no bony or ossicular chain

Table 1: Age group: Diagnostic considerations

Pediatric age group–middle ear ‘soft tissue’

Trauma
Acute otomastoiditis
Chronic otomastoiditis
Cholesteatoma
Langerhan’s cell histiocytosis

Adults

Trauma (blood)
Otomastoiditis
Cholesteatoma
Cholesterol granuloma
Paraganglioma (glomus)
Facial nerve neuroma
Dehiscent jugular bulb and aberrant carotid artery
Carcinoma
Metastasis

Table 2: Clinical history and diagnostic considerations

Clinical history and Diagnosis:

History of trauma, bleeding from ear-hemotympanum
Pain–otitis media, otomastoiditis, cholesteatoma
Otorrhea–cholesteatoma, CSOM
Hearing loss–cholesteatoma, CSOM
Pulsatile tinnitus–glomus, dehiscent jugular bulb, aberrant carotid artery

Table 3: Location within middle ear and diagnostic considerations

Epitympanum

Cholesteatoma
Otomastoiditis
Hemotympanum

Mesotympanum

Glomus tympanicum
Sinus cholesteatoma
Facial nerve schwannoma

Hypotympanum

Dehiscent jugular bulb
Aberrant carotid artery

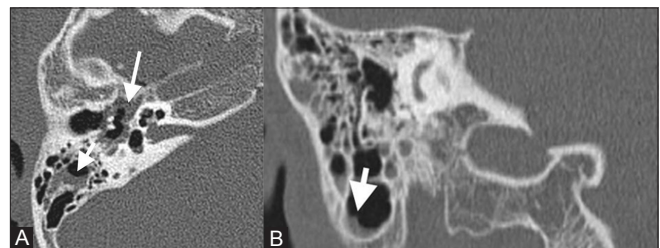


Figure 1 (A, B): HRCT axial and coronal images of the right temporal bone show soft tissue in the epitympanum (long arrow) and fluid level (short arrows in A and B) in the mastoid air cells. No bony erosions. The ossicles are intact - otomastoiditis

erosive changes.

Cholesteatoma

ENT surgeons, in most cases, will be able to suspect

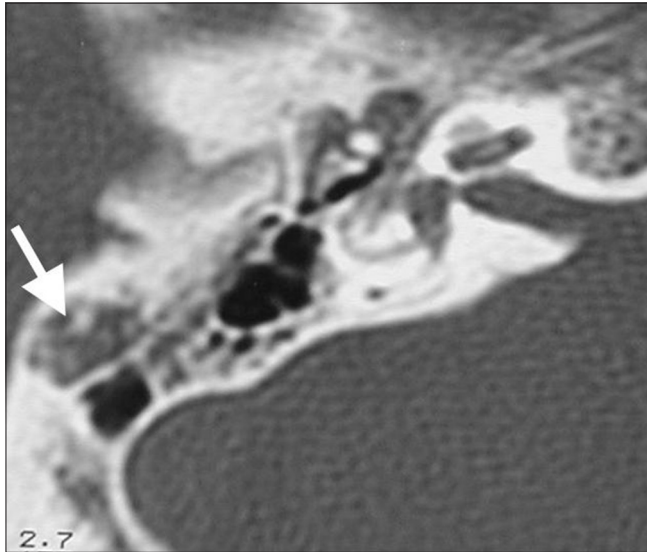

Figure 2: HRCT axial image of right temporal bone shows loss of bony septae (long arrow) resulting in coalescent mastoiditis

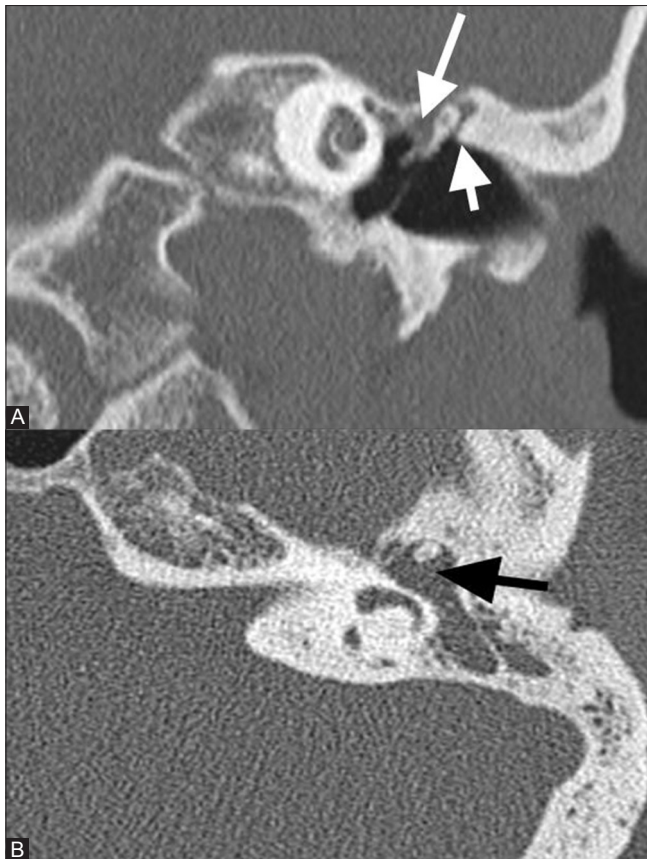


Figure 3 (A, B): Coronal and axial images of the left temporal bone show soft tissue in the epitympanum (long arrow) with blunting of the scutum (short arrow) and erosions of the ossicles (black arrow). There is sclerosis of the mastoid. Features are consistent with cholesteatoma

cholesteatoma clinically; the aim of imaging is to assess the extent of disease and exclude complications.^[10-12] The location of the lesions in relation to ossicles, i.e. lateral or medial, is also important from surgeon's point of view.

Key HRCT findings - cholesteatoma: [Figures 3A and B, and 4A and B]

- Soft tissue opacification in the attic, aditus (non-dependent location) and can reach mastoid air cells.
- Blunting / erosion of the scutum
- Ossicular erosions – long process of incus erosion is common
- Presence of disease in sinus tympani – sinus cholesteatoma
- Complications like erosions in the tegmen, semicircular canal, facial nerve canal and inner ear
- In cases of clinical suspicion of intracranial extension, contrast CT / MRI to rule out intracranial complications and extent

The classical features of cholesteatoma are present in only about 50% of the cases;^[9] in all other cases, it can be difficult to differentiate the appearance from otitis, based on HRCT appearances alone.

Congenital cholesteatoma [Figure 5A and B] is difficult to differentiate from acquired type, but clinical features may help; this is commonly seen in children with intact tympanic membrane and absence of previous otologic disease.^[9] Congenital cholesteatoma appears as well-margined expansile hypodense lesion.^[13] Differentiating them by imaging alone is difficult, but history and molecular biological techniques are helpful in differentiating them.

Trauma

Patients with history of trauma may present with bloody discharge, hearing loss, and later may present with CSF otorrhea.^[3] The extent and course of the fracture line, in relation to the long axis of the temporal bone, and the related complications are important in estimating the prognosis [Figures 6 and 7A, B].^[14] Occasionally the history of injury may not be available and the fracture may be very subtle; getting the correct clinical information and careful analysis of HRCT will avoid the pitfall.

Key HRCT findings – Trauma

- Fracture line: Longitudinal (along long axis) or transverse or complex.
- Soft tissue opacification in middle ear and mastoid air cells - blood.
- To look for ossicular disruption, facial nerve and inner ear involvement.

Facial nerve schwannoma

Patients usually of 30-40 years of age^[15] presenting with facial numbness, facial palsy, hearing loss, and tinnitus raise the clinical suspicion of facial nerve schwannoma. The

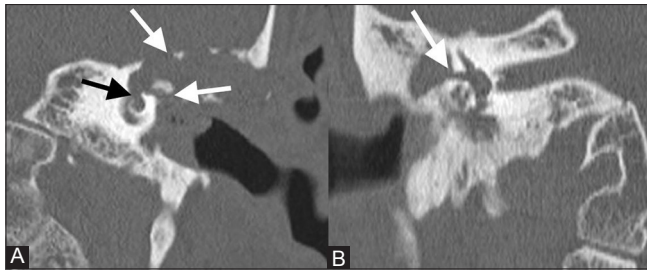


Figure 4 (A, B): Coronal image of the left temporal bone shows soft tissue opacification in the middle ear, sclerosis of mastoid, non-visualization of the ossicles, erosion of the facial nerve canal, tegmen (white arrows in A and B), lateral mastoid wall, and extension into the inner ear (black arrow). (B) Shows erosion of the lateral semicircular canal creating a labyrinthine fistula (white arrow) - complications of cholesteatoma

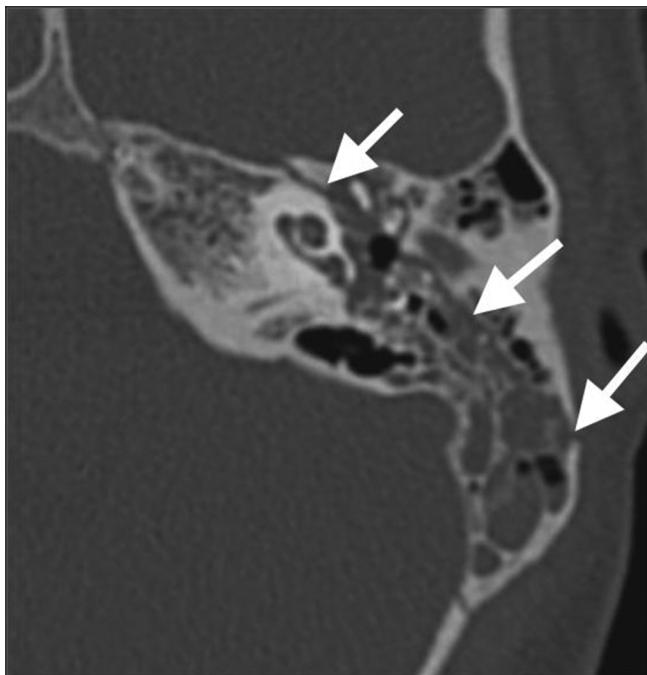


Figure 6: Axial image of the left temporal bone shows longitudinal fracture line through the mastoid and middle ear with displacement of the ossicles. Hemotympanum is noted

imaging appearance of facial nerve schwannoma has been described as an enhancing tubular mass (using T1-enhanced MR) within an enlarged facial nerve canal (using CT).^[15] Lesion enhancement is likely to be better appreciated on the MRI than CT.

Key HRCT findings – Facial nerve schwannoma [Figure 8]

- Smooth expansion of the facial nerve canal
- May show enhancement

MRI can differentiate facial nerve schwannomas from hemangioma, cholesterol granuloma, and meningioma.^[16]

Soft tissue in the middle ear presenting with pulsatile tinnitus

Pulsatile tinnitus raises the considerations of a vascular

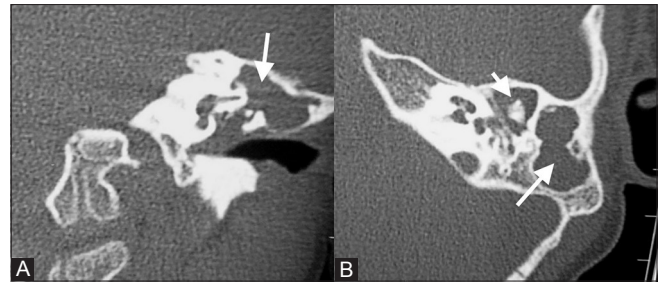


Figure 5 (A, B): Axial and coronal images of the left temporal bone show soft tissue in the middle ear and mastoid with erosion of the ossicles. The tympanic membrane appears intact. Given no history of discharge on clinical history, features suggest congenital cholesteatoma

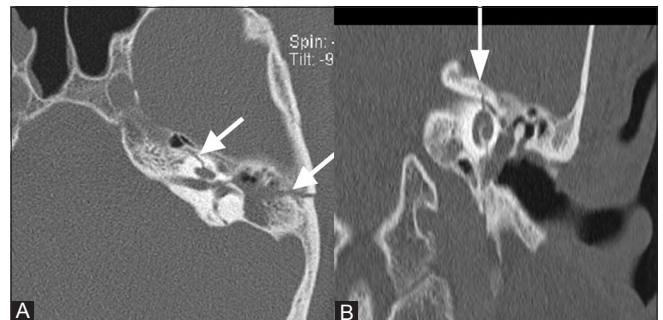


Figure 7 (A, B): Axial and coronal images of the left temporal bone demonstrating a complex fracture with a longitudinal component coursing through the mastoid and middle ear; transverse component coursing through the internal auditory canal and cochlea

tumor, a vascular malformation, and other congenital or acquired vascular abnormality.

The knowledge of whether the tinnitus is pulsatile or non-pulsatile, combined with clinical assessment, helps determine the most appropriate imaging study. Evaluation of the patient with pulsatile tinnitus needs an HRCT and contrast-enhanced CT.^[17] The diagnosis is made on the bone algorithm scans, and it may not be possible to appreciate enhancement of a small tumor confined to the middle ear on a CT study.

- *Glomus tympanicum (paraganglioma)* [Figures 9 and 10]: MRI shows the tumor enhancement better than CT, but CT delineates the anatomic extent of the tumor much more clearly.^[14,17] Middle ear adenoma is a differential diagnosis to consider; this is a rare epithelial tumour that can fill and surround the ossicles and shows, enhancement following contrast and no ossicular chain erosion; this lesion is commonly reported as glomus, due to similar imaging characteristics and clinical presentation.

Key HRCT findings - Glomus tympanicum

- Focal soft tissue on the cochlear promontory (Mesotympanum)
- Prominent contrast enhancement

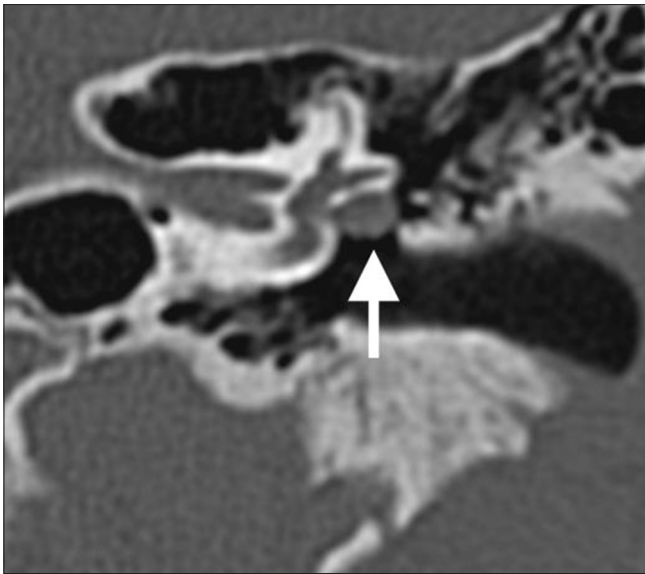


Figure 8: Coronal image of the left temporal bone demonstrating soft tissue with smooth expansion of the facial nerve canal (white arrow) – facial nerve schwannoma

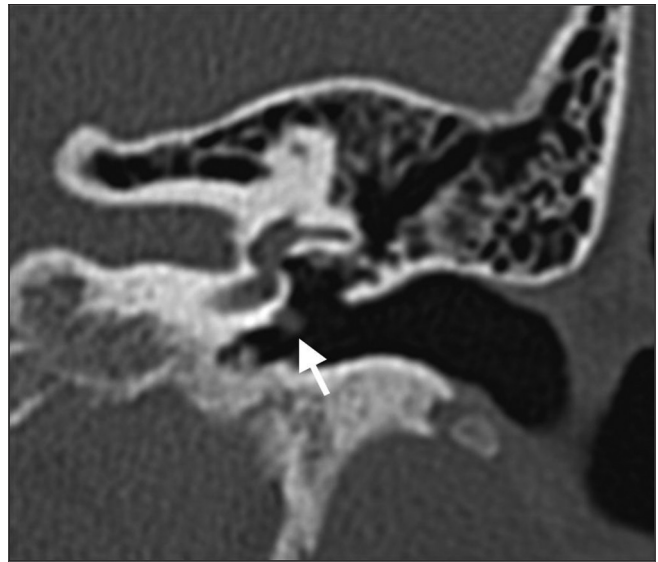


Figure 9: Coronal image of the left temporal bone shows focal soft tissue on the cochlear promontory (white arrow) – glomus tympanicum

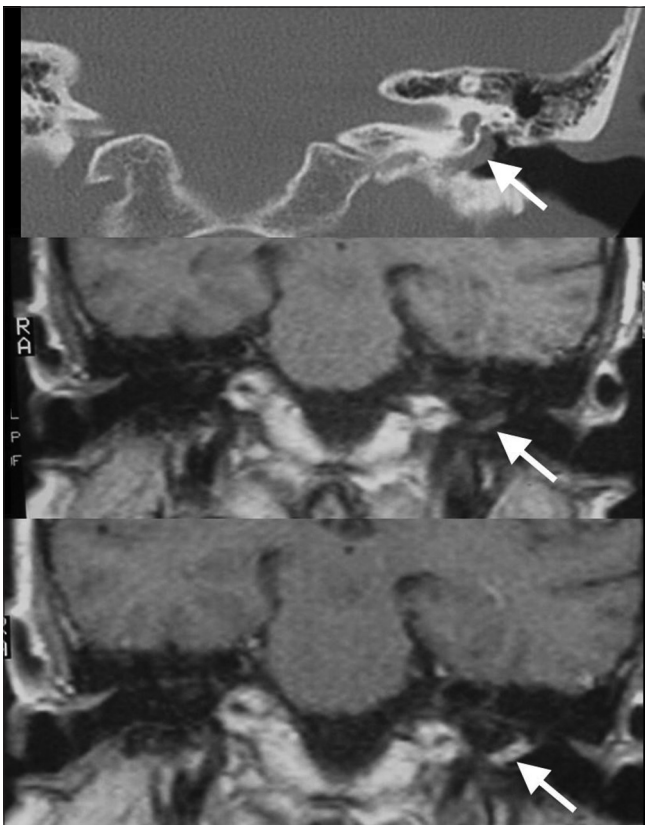


Figure 10: Coronal CT, MRI plain and contrast images of the left temporal bone show soft tissue mass over cochlear promontory with enhancement following contrast – glomus tympanicum

- *Glomus jugulotympanicum* [Figures 11A and B]: Glomus jugulare (paraganglioma) tumor that extends superiorly into the middle ear is called a glomus jugulotympanicum; bony margin erosions are present, suggestive of invasion.^[14,17] Contrast enhancement and

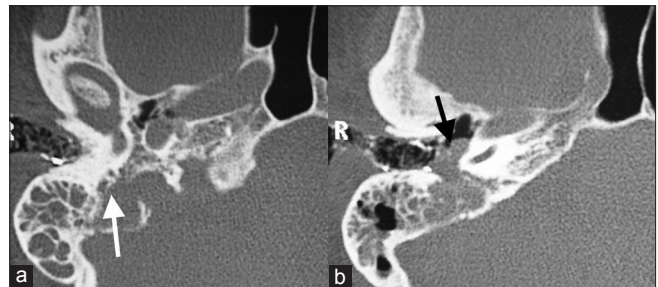


Figure 11 (A, B): Axial images of the right temporal bone show soft tissue mass lesion in the jugular fossa with irregular destruction of the jugular fossa (white arrow), jugular spine, adjacent bone, and extension of the mass into the middle ear cavity (black arrow) – glomus jugulotympanicum

MR imaging are needed for further evaluation; neck and brain may need to be assessed to exclude synchronous tumors.

Key HRCT findings – Glomus jugulotympanicum

- Irregular erosion of jugular fossa bony margins; erosion of carotico-jugular septum
- Soft tissue at jugular fossa extending to hypotympanum; can fill the middle ear.
- Avid enhancement following contrast
- *Aberrant carotid artery* [Figure 12]: The inferior tympanic canaliculus, which enlarges to accommodate the artery, resembles the carotid canal in both size and location. The aberrant carotid artery may be dehiscent or may be covered by cortical bone so that the otoscopic examination can sometimes be normal.^[14,17]

Key HRCT findings – Aberrant carotid artery

- Abnormal posterior course of the internal carotid artery projecting into the middle ear cavity

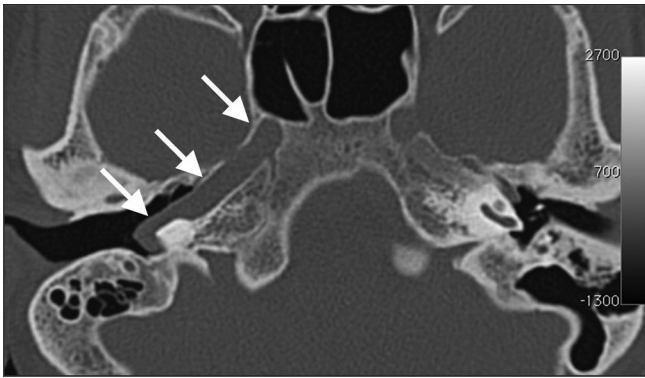


Figure 12: Axial image of the right temporal bone showing abnormal posterior course of the right internal carotid artery – aberrant right internal carotid artery coursing through the middle ear

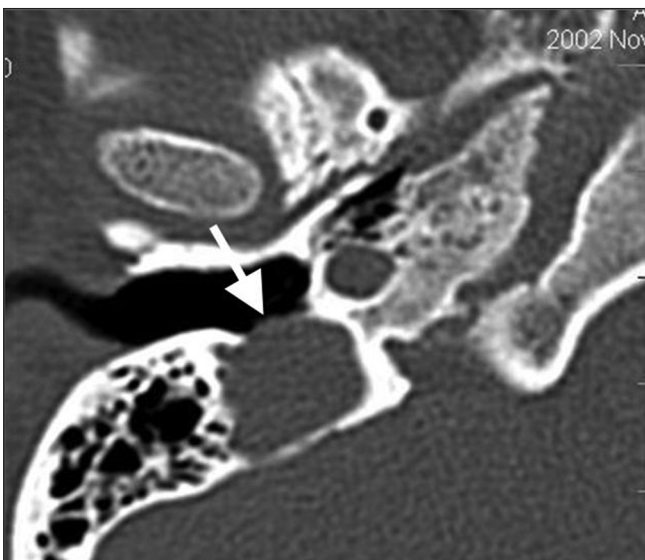


Figure 13: Axial image shows bony defect between the jugular bulb and middle ear cavity – dehiscent jugular bulb

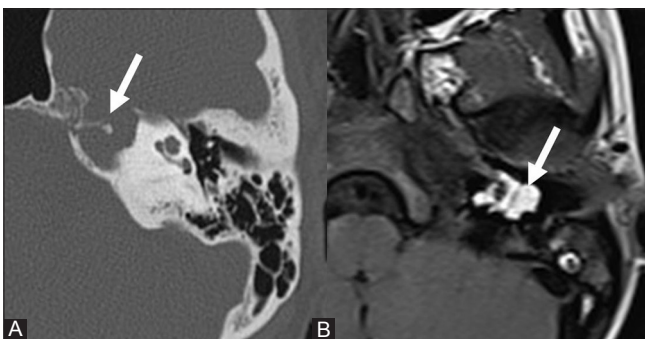


Figure 14 (A, B): Axial CT and MRI-T1 weighted image shows soft tissue expansile lesion in the petrous apex, the soft tissue being hyperintense on T1W MRI – cholesterol granuloma

- *Dehiscent jugular vein* [Figure 13]: Lacks a complete cortical covering. As a result, the vein bulges into the middle ear from below. A jugular bulb is considered “high riding” if it extends above the level of the floor of the internal auditory canal (IAC).

Key HRCT findings – Dehiscent jugular bulb

- Absence of cortical bone between the jugular fossa and the middle ear.
- Cholesterol granuloma [Figures 14A and B]

It is an innocuous disease that develops in the mastoid air cells in response to blockage of the cellular system by chronic infection.^[18] Cholesterol granuloma is bright on T1 and T2W sequences of MRI with or without T2 hypointense areas representing hemosiderin.^[14] CT demonstrates bone expansion with soft tissue attenuation at petrous apex or middle ear.^[14,18]

Conclusion

Approaching any middle ear pathology in the order of age, clinical history, location and imaging characteristics would enable us in making a correct diagnosis in most of the cases. It is always important to make a note about the extent of the disease, anatomical variants, and possible complications.^[19] This will serve as an efficient road map for the operating surgeon.

For all practical purposes,

- middle ear non-dependent soft tissue with bone erosions or ossicular destruction is almost always a cholesteatoma
- middle ear soft tissue with intact ossicles, the diagnosis is most commonly otomastoiditis; this needs correlation with history of ear discharge.
- in the absence of such history of discharge or trauma, think about a vascular mass and do contrast-enhanced scans; look out for relevant clinical features.

References

1. Som PM, Curtin HD. Text book on Head and Neck Imaging. 4th ed. Maryland Heights: Mosby; 2003.
2. Veillon F, Riehm S, Roedlich MN, Meriot P, Blonde E, Tongio J. Imaging of middle ear pathology. *Semin Roentgenol* 2000;35:2-11.
3. Trojanowska A, Drop A, Trojanowski P, Rosińska-Bogusiewicz K, Janusz Klatka, Bobek-Billewicz B. External and middle ear diseases: Radiological diagnosis based on clinical signs and symptoms. *Insights Imaging* 2012;3:33-48.
4. Lemmerling MM, De Foer B, VandeVyver V, Vercruyse JP, Verstraete KL. Imaging of the opacified middle ear. *Eur J Radiol* 2008;66:363-71.
5. Schwartz J, Hansberger RH. Imaging of the Temporal Bone. 3rd ed. New York: Thieme; 1998.
6. Bluestone D, Stool SE, Alper CM, Arjmand EM, Casselbrant ML, Dohar JE, Yellow RF. Pediatric Otolaryngology. 3rd ed. Philadelphia: W.B. Saunders; 1996
7. Vazquez E, Castellote A, Piqueras J, Mauleon S, Creixell S, Pumarola F, *et al.* Imaging of complications of acute mastoiditis in children. *Radiographics* 2003;23:359-72.
8. Maroldi R, Farina D, Palvarini L, Marconi A, Gadola E, Menni K, *et al.* Computed tomography and magnetic resonance imaging of pathologic conditions of the middle ear. *Eur J Radiol* 2001;40:78-93.
9. Hansberger HR. Handbook of Head and Neck Imaging. 2nd ed. Maryland Heights: Mosby; 1995.

10. Joselito LA, Gaurano JL, Joharjy IA. Middle ear cholesteatoma: Characteristic CT findings in 64 patients. *Ann Saudi Med* 2004;24:442-7.
11. Yates PD, Flood LM, Banerjee A, Clifford K. CT scanning of middle ear cholesteatoma: What does the surgeon want to know? *Br J Radiology* 2002;75:847-52.
12. Sethom A, Akkari K, Dridi I, Tmimi S, Mardassi A, Benzarti S, *et al.* Preoperative CT Scan in middle ear cholesteatoma. *Tunis Med* 2011;89:248-53.
13. Robert Y, Carcasset S, Rocourt N, Hennequin C, Dubrulle F, Lemaitre L. Congenital cholesteatoma of the temporal bone: MR findings and comparison with CT. *AJNR Am J Neuroradiol* 1995;16:755-61.
14. Offiah CE, Ramsden RT, Gillespie JE. Imaging appearances of unusual conditions of the middle and inner ear. *Br J Radiol* 2008;81:504-14.
15. Wiggins RH 3rd, Harnsberger HR, Salzman KL, Shelton C, Kertesz TR, Glastonbury CM. The many faces of facial nerve Schwannoma. *AJNR Am J Neuroradiol* 2006;27:694-9.
16. Chung JW, Ahn JH, Kim JH, Nam SY, Kim CJ, Lee KS. Facial nerve schwannomas: Different manifestations and outcomes. *Surg Neurol* 2004;62:245-52.
17. Weismann JL, Hirsch BE. Imaging of tinnitus. A review. *Radiology* 2000;216:342-9.
18. Martin N, Sterkers O, Mompoin D, Julien N, Nahum H. Cholesterol granulomas of the middle ear cavities: MR imaging. *Radiology* 1989;172:521-5.
19. Schmerber S, Lefournier V, Karkas A. What the surgeon cannot see and needs to see before middle ear surgery. *ORL J Otorhinolaryngol Relat Spec* 2010;72:145-58.

Cite this article as: Anbarasu A, Chandrasekaran K, Balakrishnan S. Soft tissue attenuation in middle ear on HRCT: Pictorial review. *Indian J Radiol Imaging* 2012;22:298-304.

Source of Support: Nil, **Conflict of Interest:** No.

New features on the journal's website

Optimized content for mobile and hand-held devices

HTML pages have been optimized of mobile and other hand-held devices (such as iPad, Kindle, iPod) for faster browsing speed.

Click on **[Mobile Full text]** from Table of Contents page.

This is simple HTML version for faster download on mobiles (if viewed on desktop, it will be automatically redirected to full HTML version)

E-Pub for hand-held devices

EPUB is an open e-book standard recommended by The International Digital Publishing Forum which is designed for reflowable content i.e. the text display can be optimized for a particular display device.


Click on **[EPub]** from Table of Contents page.

There are various e-Pub readers such as for Windows: Digital Editions, OS X: Calibre/Bookworm, iPhone/iPod Touch/iPad: Stanza, and Linux: Calibre/Bookworm.

E-Book for desktop

One can also see the entire issue as printed here in a 'flip book' version on desktops.

Links are available from Current Issue as well as Archives pages.

Click on  View as eBook