


Contents lists available at [ScienceDirect](https://www.sciencedirect.com)

International Journal for Parasitology: Parasites and Wildlife

journal homepage: [www.elsevier.com/locate/ijppaw](http://www.elsevier.com/locate/ijppaw)

## Lack of evidence of vertical transmission of *Karyolysus* blood parasites in Iberian green lizards (*Lacerta schreiberi*)<sup>☆</sup>

Renáta Kopena<sup>a,b,\*</sup>, José Martín<sup>b</sup>, Pilar López<sup>b</sup>, Igor Majláth<sup>c</sup>, Viktória Majláthová<sup>c</sup>

<sup>a</sup> Evolutionary Ecology Research Group, Institute of Ecology and Botany, ELKH Centre for Ecological Research, H-2163, Vácrátót, Alkotmány u. 2-4., Hungary

<sup>b</sup> Departamento de Ecología Evolutiva, Museo Nacional de Ciencias Naturales, CSIC, José Gutiérrez Abascal 2, E-28006, Madrid, Spain

<sup>c</sup> Institute of Biology and Ecology, Pavol Jozef Safarik University in Kosice, Šrobárova 2, 041 80, Kosice, Slovak Republic

### ARTICLE INFO

#### Keywords:

Vertical transmission  
*Karyolysus*  
Blood parasite  
*Lacerta schreiberi*  
Lizard

### ABSTRACT

To understand the spread of parasite and the persistence of infection in an ecological environment, it is essential to investigate their transmission possibilities. Vertical transmission of pathogens from mother to offspring is a fundamental opportunity, notwithstanding a relatively under-researched topic, especially in wildlife animals. We studied whether there is vertical transmission of a haemogregarinid blood parasite of Iberian green lizard (*Lacerta schreiberi*). To study infection of mothers, embryos and freshly hatched juveniles, their blood smears and molecular analyses of their tail tissue were used. Examining blood smears, seventy-one percent of females were found to be infected, but molecular analyses of all mothers showed positive results for the blood parasite. Based on molecular data the parasite was identified as a *Karyolysus* species. In contrast, no parasite was found in the blood smears of the freshly hatched juveniles, and we could not detect *Karyolysus* in the embryos or tail tissue of offspring using molecular methods either. Based on our results, vertical transmission of *Karyolysus* blood parasites is unlikely in the Iberian green lizard.

### 1. Introduction

Haemogregarines are one of the most common but poorly studied groups of blood parasites within the Apicomplexa phylum. Haemogregarines is a term used to comprehensively represent the genera in the families Hepatozoidae, Karyolysidae, Haemogregarinidae, and Dactylosomatidae of the suborder Adeleorina (Barta et al., 2012). Parasites of this group have very similar morphological characters, and their classification was originally based on lifecycle and host associations (Telford, 2009). For decades, their morphological descriptions and life cycle patterns were used for taxonomical identification, but recently molecular tools are available, allowing a more accurate identification and taxonomic placement (Karadjian et al., 2015). Haemogregarines are obligate heteroxenous parasites infecting diverse haematophagous invertebrate and vertebrate hosts. Haemogregarines can infect all vertebrate groups, and they are the most common blood parasites of reptiles (Telford, 2009).

To understand the spreading of parasites in the ecological environment, it is essential to know the transmission opportunities of the given

parasite. Haemogregarines have a complex life cycle; horizontal transmission needs a definitive invertebrate host, such as mosquitos, ticks, mites, and leeches, where sexual reproduction and sporogony of blood parasites take place, and a vertebrate intermediate host, where asexual reproduction occurs (Telford, 2009). There are alternative transmission opportunities: transovarial transmission in definitive host (*Karyolysus* genus; Haklová-Kočfíková et al., 2014), and also vertical transmission from mother to offspring in intermediate host (*Hepatozoon* genus; e.g. Forlano et al., 2005); however, the latter is a rarely studied subject. For example, *Hepatozoon canis* was found in newborn puppies from infected mother dogs (*Canis lupus familiaris*) (Forlano et al., 2005) and fetuses from an infected mother red fox (*Vulpes vulpes*) (Hodžić et al., 2018). Similarly, *Hepatozoon felis* was detected in the fetus from an infected domestic cat mother (*Felis catus*) (Baneth et al., 2013); thus, vertical transmission of haemogregarines, at least of *Hepatozoon* species, is generally likely in mammals. Nevertheless, in oviparous animals, the results are not that clear. *Haemogregarina bigemia* was not detected in any hatchlings from infected mothers of *Lipophrys pholis* fish (Davies and Johnston, 1976). In reptiles, there are only data from ovoviviparous

<sup>☆</sup> Note: Nucleotide sequence data reported in this paper are available in the GenBank™ databases under the accession number (MZ676083.1).

\* Corresponding author. Evolutionary Ecology Research Group, Institute of Ecology and Botany, ELKH Centre for Ecological Research, H-2163, Vácrátót, Alkotmány u. 2-4, Hungary.

E-mail address: [kopena.renata@ecolres.hu](mailto:kopena.renata@ecolres.hu) (R. Kopena).

<https://doi.org/10.1016/j.ijppaw.2021.08.008>

Received 28 June 2021; Received in revised form 19 August 2021; Accepted 19 August 2021

Available online 21 August 2021

2213-2244/© 2021 Published by Elsevier Ltd on behalf of Australian Society for Parasitology. This is an open access article under the CC BY-NC-ND license

(<http://creativecommons.org/licenses/by-nc-nd/4.0/>).

snakes; an unknown haemogregarine species was found in neonates of a heavily infected mother of the banded water snake (*Nerodia fasciata*) (Lowichik and Yaeger, 1987), and an unknown *Hepatozoon* species was detected in blood smears of laboratory-born offspring of infected western terrestrial garter snake females (*Thamnophis elegans*) (Kauffman et al., 2017).

Here, we aim to investigate the potential of vertical transmission of haemogregarines in an oviparous reptile, the Iberian green lizard (*Lacerta schreiberi*). For this, we captured wild pregnant female lizards, and incubated their eggs to get their offspring in the laboratory under controlled conditions (i.e. no exposition to invertebrate parasite vectors). We examined blood smears and used molecular analyses to detect the presence of haemogregarinid blood parasites in females and in their embryos and recently hatched juveniles. We expected that, if there were vertical transmission, some of the offspring from infected females might also show blood parasites, as this would be the only possible transmission route under the experimental situation.

## 2. Materials and methods

### 2.1. Sample collection

In 2012, 21 gravid female lizards were captured by lassoing in ‘Valle de La Fuenfría’ in the Guadarrama Mountains (40°44' N, 4°02' W; Madrid Province, Spain). Lizards were immediately transferred to ‘El Ventorrillo’ field station of the Museo Nacional de Ciencias Naturales (Madrid province, Spain), 5 km from the capture site where they were kept in captivity in outdoor individual terraria until egg laying (see details in Kopena et al., 2020). Eggs (n = 281) were incubated until the offspring was born (see Kopena et al., 2020). We ensured that hatchlings had not been exposed to possible invertebrate vectors of blood parasites by maintaining juveniles after hatching in clean, closed small boxes until samples were made. Blood smears of female lizards were made after egg laying, whereas blood smears of hatchlings (n = 181) were made within 24 h after hatching, in both cases blood was taken from the tail vein directly after collecting the end of the tail (ca. 4 mm) as genetic tissue sample. Tail samples were cut using a sterile scalpel blade and 70% ethanol for cleaning the skin surface. Collected tails were as small as possible and the damaged tail can regenerate quickly. Tail samples were stored in 96% ethanol at –20 °C until processing for molecular analysis. In addition, unhatched eggs (n = 100) were stored in 96% ethanol at –20 °C until checked for fertilization and processed for molecular analysis. Together, 46 fertilized but unhatched eggs were found. Development of fertilized unhatched eggs stopped in different developmental stages; thus, we collected DNA samples from three germinal discs, 38 area vascular/heart tissues, and five embryos. Females (after egg laying) and their offspring (after hatching) were released to capture sites of the mother after ensuring they were in good health condition.

### 2.2. Haemogregarine burden assessed by blood smears

Blood smears were air-dried, fixed in absolute methanol for 10 min, and stained in Giemsa diluted 1:9 with phosphate buffer (pH 7.2). The numbers of intraerythrocytic parasites were estimated at 1000x magnification (Nikon Eclipse E200) by counting the number of parasites per 2000 erythrocytes. The morphological diagnosis of parasites was based on photos taken using a Zeiss Axioskop 2 microscope (Zeiss) with a CMEX 10 Pro (Euromex) digital camera and measures made using ImageFocus Alpha software (Euromex). We measured maximum length and width of different developmental stages of the parasites, and maximum length and width of nuclei of gamonts; LW (length × width) and L/W (length/width) values were calculated.

### 2.3. DNA extraction, PCR amplification and sequencing

Genomic DNA was isolated from the tail tissue with Geneaid Tissue

Genomic DNA mini Kit (Geneaid Biotech, New Taipei City, Taiwan) following the manufacturer’s instructions. Isolated DNA was stored at –20 °C. PCR reactions were run in a 25 µl reaction mixture consisting of the 2.5 µl 10X DreamTaq Green buffer (20 pmol/µl MgCl<sub>2</sub>); 0.15 µl Thermo Scientific™ DreamTaq DNA Polymerase (5 U/µL) (0.5 µl dNTPs (10 pmol/µl); 1 µl of each primer (10 pmol/µl); 14.85 µl water for molecular biology and 5 µl of DNA. Verification of successful DNA isolation was assessed using microsatellite primers originally used for paternity analyses of sample lizards (Lv1r17 (F:AGC TCT GGA TCG AGA CAA CCT GG/R:TCT CTG AAG GAG ACC GGC TCC)) (Böhme et al., 2005). Molecular detection of blood parasites was performed by PCR reactions with HEPF300 (5' GTT TCT GAC CTA TCA GCT TTC GAC G 3')/HEP900 (5' CAA ATC TAA GAA TTT CAC CTC TGA C 3') primers targeting part of the 18S rRNA gene of haemogregarines. Amplification with HEP300/HEP900 primers was performed at 94 °C for 3 min (polymerase activation), 35 cycles at 94 °C for 30 s, annealing temperature at 60 °C for 30 s, 72 °C for 60 s and a final extension at 72 °C for 10 min (Ujvari et al., 2004).

In each PCR reaction, negative (ultrapure water) and positive (an already sequenced sample) controls were included. Amplicons were separated on a 1.5% agarose gel (Sigma-Aldrich, Buchs, Switzerland) in 1 × TAE Buffer (40 mM Tris, pH 7.8, 20 mM acetic acid, 2 mM EDTA). The gel was stained by Good View nucleic acid stain (SBS Gentech, China) and afterwards was visualized using a UV transilluminator. Obtained positive PCR products (approximately 600 bp) were purified with GenElute™ PCR Clean-Up Kit (Sigma-Aldrich, Buchs, Switzerland) and sequenced in a commercial sequencing facility (University of Veterinary Medicine, Košice, Slovak Republic), with all fragments sequenced in both directions.

Sequences were visualized, edited using MEGA X and checked by eye. Checked sequences were compared to the sequences available in GenBank by using the basic local alignment search tool (BLASTn 2.2.26).

## 3. Results

### 3.1. Haemogregarine burden in blood smears

Haemogregarine prevalence was estimated as the percentage of infected mothers (prevalence = 71%). Parasite median intensity was estimated for each infected host as the number of infected red blood cells found in approximately 2000 cells (median intensity = 29, CI<sub>95%</sub> = 18.8–50.0, intensity range = 1–109).

Two developmental stages of parasites were found in erythrocytes (Fig. 1a–f). Trophozoites varied in shape: reniform (Fig. 1a), oval (Fig. 1b) or slender (Fig. 1c). Their cytoplasm stained pale blue and was vacuolated. Nuclei spread across the whole width of the parasite was placed centrally. Trophozoites measured 13.4 (mean) ± 1.2 (SD) (range:10.4–15) µm × 4.3 ± 0.8 (2.2–6.1) µm (n = 18), LW = 57.4 ± 11.8 (36.8–81.6) µm<sup>2</sup>, L/W = 3.2 ± 0.6 (2.7–4.3). Gamonts (Fig. 1d–f) had slender shape with at least one recurved end. Cytoplasm of gamonts stained pale blue, no vacuoles were present. The nuclei of gamonts were usually elongated and filled the entire width of the parasite. Nuclei were placed centrally or were slightly shifted closer to the bend. Macro- and microgamonts were indistinguishable. Gamonts measured: 17.17 (mean) ± 1.3 (SD) (range: 13.6–19.8) µm × 3.8 ± 0.4 (2.9–5.5) µm (n = 117), LW = 65.6 ± 8.9 (47.5–99) µm<sup>2</sup>, L/W = 4.6 ± 0.6 (2.7–6.1). Nuclei measured: 6.2 ± 1.0 (4.3–9.8) µm × 5.1 ± 0.6 (3.3–6.9) µm (n = 102), LW = 31.7 ± 6.6 (20–62) µm<sup>2</sup>, L/W = 1.2 ± 0.3 (0.7–2). Nuclei were sometimes too diffuse to measure exact parameters, therefore, these nuclei were omitted in the measurements. In some cases, extracellular location of gamonts were observed. Infected host cells were significantly changed (Fig. 1a–f). Trophozoites caused strong hypertrophy of the erythrocyte with paler and enlarged nucleus and cytoplasm stained more in blue color (Fig. 1a–c). Alterations to host cell morphology caused by gamonts were milder. Cytoplasm color was paler than that of

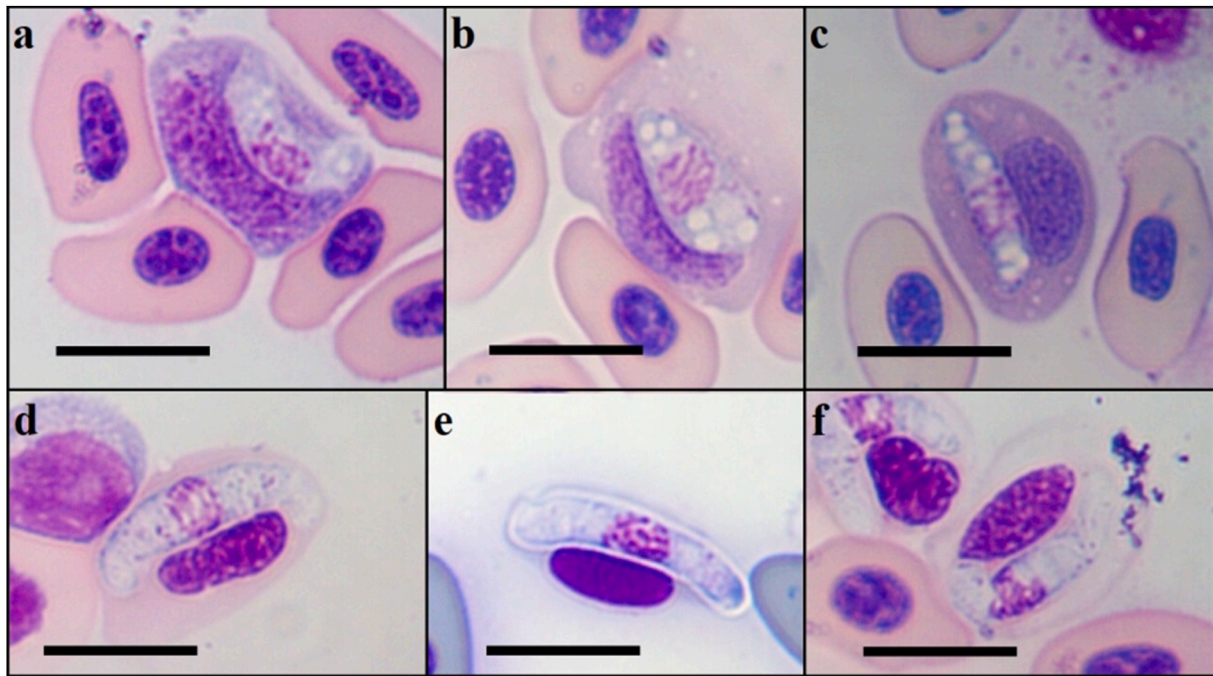


Fig. 1. *Karyolysus* sp. Trophozoite (a–c) and gamonts (d–f) found in blood smears of *L. schreiberi* lizards. Scalebar = 10  $\mu$ m.

uninfected cells and nuclei were enlarged, compressed and stained dark (Fig. 1d–f). In some cases, host cells completely lost their cytoplasm (Fig. 1e). In rare cases, gamonts were also observed outside the blood cell.

No haemogregarines were found in the smears made from blood obtained from freshly hatched juveniles of *L. schreiberi*.

### 3.2. PCR amplification, sequencing and identification

Using the pair of HEPF300/HEPR900 primers resulted in DNA amplification in all DNA samples extracted from females. In contrast, we did not detect haemogregarine infection in any of the samples extracted from eggs, embryos or freshly hatched juveniles. Based on results obtained from blood smears examination and PCR, the haemogregarinid parasites do not seem to be able to pass from mother to offspring by vertical transmission route in this lizard species.

The haemogregarinid DNA fragment amplified from the tail tissues of adult female *L. schreiberi* (GenBank accession no. MZ676083.1) showed a complete match (100%) with the sequence of haemogregarines previously detected in *Ixodes ricinus* ticks engorged on *L. schreiberi* lizards from Spain (GenBank accession no. MK497254.1). According to this genetic match and morphology, we identified blood parasites detected in females of *L. schreiberi* as *Karyolysus lacazei* (Labbé, 1894). However, we also found a complete match with a parasite sample from a Moroccan lizard considered as an unknown *Hepatozoon* species (GenBank accession no. HQ734798.1).

## 4. Discussion

Our results show that the studied *L. schreiberi* population had a high prevalence of infection by blood parasites belonging to the *Karyolysus* genus; however, their vertical transmission from mother to offspring is not supported by either blood smears examination or molecular methods.

Seventy-one percent of blood smears and hundred percent of PCR tests showed females to be infected, indicating that the blood parasites found were extremely widespread and likely highly adapted to this lizard species. The high prevalence is unlikely to be a consequence of

captivity, as the lizards were housed individually to avoid infection from mites of other infected individuals, and the prevalence based on blood smears was similar to that found in previous years in the same population when blood smears were made directly after capturing the lizards (i. e. a mean prevalence of around 80% in different years; Kopena, unpublished data). This result seems to be supported by the fact that in a previous study, Zechmeisterová et al. (2019) detected haemogregarinid parasites in ticks feeding on *L. schreiberi* captured at 300 km from our study population, with a prevalence of 50% on blood smears.

The sequences of the two parasites obtained from GenBank that revealed 100% homology with our sequence are probably the same haemoparasite, *Karyolysus* cf. *lacazei*. However, one of the sequences we obtained was identified as an unknown North African *Hepatozoon* species infecting the *Atlantolacerta* lizard genus (Maia et al., 2011). In the latter publication, the data were used only for phylogenetic comparison; the correct taxonomic classification of this parasite was not examined, neither morphological study nor photos have been published, so, unfortunately, there is no opportunity to compare with our parasite. The morphology of trophozoites was identical to those of *K. lacazei* (Zechmeisterová et al., 2019), and morphological characters of gamonts overlapped with earlier observed parameter ranges of *K. lacazei*; however, gamonts and their nuclei were shorter and thicker on average than in earlier studies (Reichenow, 1919; Svahn, 1975; Haklová-Kočíková et al., 2014; Zechmeisterová et al., 2019). Due to the small morphological differences and because we amplified only a short sequence of the 18S rRNA gene (605bp), the parasite cannot be reliably identified at the species level.

The role of the *Ophionyssus* mite as an invertebrate host where gamogony and sporogony occur (Reichenow, 1919; Svahn, 1975; Haklová-Kočíková et al., 2014) is essential in the life cycle of *Karyolysus*, requiring ingestion of infected mites. *Ophionyssus* mites are common parasites on the skin of *L. schreiberi* (Moraza et al., 2009). Merogony already occurs in the endothelial cells of the liver, lung, spleen, ovary, and heart of lizards (Reichenow, 1919; Svahn, 1975; Telford, 2009).

Vertical transmission of pathogens from mother to offspring is a relatively under-researched topic. We know only a few but very diverse pathogens (viruses, bacteria, and parasites) capable of vertical transmission (Robbins and Bakardjiev, 2012). Unfortunately, much of these

data come from human and veterinary research, so we have a negligible amount of data from wildlife. In general, the possibility of vertical transmission of infections are from the genital tract or blood of the mother (Robbins and Bakardjiev, 2012), so the way the embryo is nourished may also be important from a transmission point of view. In the only lecithotrophic species examined (i.e., *Lipophrys pholis* fish) (Davies and Johnston, 1976), vertical transmission has not been found, while in mammals with placentotrophy, vertical transmission was found (Hodžić et al., 2018; Baneth et al., 2013). Based on these findings, placentotrophy is likely to increase the opportunities for vertical transmission, but the actual mechanisms of transmission remain unknown and further research is needed. In reptiles, oviparity has evolved into viviparity on several occasions, making lecithotrophy a placentotrophy with varying development (see review in Stewart 2013), which could hide better opportunities for parasites to spread. The relatively developed placentotrophy of thamnophine snakes (Blackburn et al., 2017) could be the reason why the *Hepatozoon* species passed through the similarly developed placenta of *Nerodia fasciata* (Lowichik and Yaeger, 1987) and *Thamnophis elegans* snakes, even if in the latter case the maternal infection was low (0.004–2 parasites per 2000 erythrocytes) (Kauffman et al., 2017). In the present study, we were also able to molecularly examine a relatively large number of offspring and eggs, even from highly parasitized mothers. Based on the negative results of these samples, vertical transmission of this parasite from mother to offspring is unlikely for this oviparous lizard. However, in the case of lecithotrophic organisms, primarily those pathogens can pass into the egg by vertical transmission, which pathogens attack the gonads (see review in Valero et al., 2018 in fish, Graf et al., 2012 in a bird). Meronts of *K. lacazei* and its close relative, *Karyolysus lacertae*, have already been detected from the ovaries of lizards (Svahn, 1975), so the negative result we found may be somewhat surprising; however, we did not examine whether the ovaries of our sample animals were infected. Further research is needed to elucidate the possibility of vertical transmission of haemogregarines, not only involving several and evolutionarily different oviparous species, but also possible routes of infection (embryonic nourishing or gonadal spread).

#### Declaration of interests

The authors declare that they have no known competing financial interests or personal relationships that could have appeared to influence the work reported in this paper.

#### Acknowledgements

We thank Jesus Ortega for advice on incubation of lizard eggs and Gergely Balázs for help with CMEX 10 Pro digital camera. We also thank “El Ventorrillo” MNCN-CSIC Field Station and Eötvös Loránd University for use of their facilities. We thank also Barbora Majláthová for drawing the graphical abstract. This work was supported by the MICIIN [CGL 2011–24150/BOS] and the MINECO [CGL 2014–53523-P] to JM and PL, the JAEpre grant of CSIC and the Hungarian Slovak long-term bilateral state scholarship of the Tempus Public Foundation [AK 2018-2019/286214; AK 2019-2020/AK-KI-T-54] to RK, the project of Scientific Grant Agency of the Ministry of Education, Science, Research and Sport of the Slovak Republic and the Slovak Academy of Sciences [VEGA 2/0113/18] to IM and by the Slovak Research and Development Agency [APVV-19-0440] to VM. The captures and experiment enforced all the present Spanish laws and were performed under license (permit number: 10/072913.9/12) from the Environmental Organisms of Madrid

Community. Animal welfare standards and protocols of this study were supervised by the Bioethical Committee of the Spanish Research Council (CSIC).

#### References

- Baneth, G., Sheiner, A., Eyal, O., Hahn, S., Beauvais, J.P., Anug, Y., Talmi-Frank, D., 2013. Redescription of *Hepatozoon felis* (Apicomplexa: Hepatozoidae) based on phylogenetic analysis, tissue and blood form morphology, and possible transplacental transmission. *Parasites Vectors* 6, 102.
- Barta, J.R., Ogedengbe, J.D., Martin, D.S., Smith, T.G., 2012. Phylogenetic position of the adeleorinid coccidia (Myxozoa, Apicomplexa, Coccidia, Eucoccidiorida, Adeleorina) inferred using 18s rDNA sequences. *J. Eukaryot. Microbiol.* 59, 171–180. <https://doi.org/10.1111/j.1550-7408.2011.00607.x>.
- Blackburn, D.G., Anderson, K.E., Lo, A.R., Marquez, E.C., Callard, I.P., 2017. Placentation in watersnakes II: placental ultrastructure in *Nerodia erythrogaster* (colubridae: natricinae). *J. Morphol.* 278, 675–688.
- Böhme, M.U., Berendonk, T.U., Schlegel, M., 2005. Isolation of new microsatellite loci from the Green Lizard (*Lacerta viridis viridis*). *Mol. Ecol. Notes* 5, 45–47.
- Davies, A.J., Johnston, M.R.L., 1976. The biology of *Haemogregarina bigemina* Laveran & Mesnil, a parasite of the marine fish *Blennius pholis* Linnaeus. *J. Protozool.* 23, 315–320.
- Forlano, M., Scofield, A., Elisei, C., Fernandes, K.R., Ewing, S.A., Massard, C.L., 2005. Diagnosis of *Hepatozoon* spp. in *Amblyomma ovale* and its experimental transmission in domestic dogs in Brazil. *Vet. Parasitol.* 134, 1–7.
- Graf, B., Aigner, F., Liebhart, D., Marek, A., Prokofieva, I., Bachmeier, J., Hess, M., 2012. Vertical transmission and clinical signs in broiler breeders and broilers experiencing adenoviral gizzard erosion. *Avian Pathol.* 41, 599–604.
- Haková-Kočková, B., Hížňanová, A., Majláth, I., Račka, K., Harris, D.J., Földvári, G., Tryjanowski, P., Kokošová, N., Malčeková, B., Majláthová, V., 2014. Morphological and molecular characterization of *Karyolysus*—a neglected but common parasite infecting some European lizards. *Parasites Vectors* 7, 1–12.
- Hodžić, A., Mrowietz, N., Cezanne, R., Bruckschwaiger, P., Punz, S., Habler, V.E., Tomsik, V., Lazar, J., Duscher, G.G., Glawischig, W., Fuehrer, H.P., 2018. Occurrence and diversity of arthropod-transmitted pathogens in red foxes (*Vulpes vulpes*) in western Austria, and possible vertical (transplacental) transmission of *Hepatozoon canis*. *Parasitology* 145, 335–344.
- Karadjian, G., Chavatte, J.M., Landau, I., 2015. Systematic revision of the adeleid haemogregarines, with creation of *Bartazoon* n. g., reassignment of *Hepatozoon argantis* Garnham, 1954 to *Hemolivia*, and molecular data on *Hemolivia stellata*. *Parasite* 22, 31. <https://doi.org/10.1051/parasite/2015031>.
- Kauffman, K.L., Sparkman, A., Bronikowski, A.M., Palacios, M.G., 2017. Vertical transmission of *Hepatozoon* in the garter snake *Thamnophis elegans*. *J. Wildl. Dis.* 53, 121–125.
- Kopena, R., López, P., Majláthová, V., Martín, J., 2020. Sexually dichromatic coloration of female Iberian green lizards correlates with health state and reproductive investment. *Behav. Ecol. Sociobiol.* 74, 1–12.
- Lowichik, A., Yaeger, R.G., 1987. Ecological aspects of snake haemogregarine infections from two habitats in southeastern Louisiana. *J. Parasitol.* 73, 1109–1115.
- Maia, J.P., Harris, D.J., Perera, A., 2011. Molecular survey of *Hepatozoon* species in lizards from North Africa. *J. Parasitol.* 97, 513–517.
- Moraza, M.L., Irwin, N.R., Godinho, R., Baird, S.J., Bellocq, J.G., 2009. A new species of *Ophionyssus mégnin* (Acari: mesostigmata: macronyssidae) parasitic on *Lacerta schreiberi* bedriaga (reptilia: lacertidae) from the Iberian Peninsula, and a world key to species. *Zootaxa* 2007, 58–68.
- Reichenow, E., 1919. Der Entwicklungsgang der Hämoococcidien *Karyolysus* und *Schellackia* nov. gen. *Sitzungsberichte Ges. Naturforschender Freunde Berl.* 10, 440–447.
- Robbins, J.R., Bakardjiev, A.I., 2012. Pathogens and the placental fortress. *Curr. Opin. Microbiol.* 15, 36–43.
- Stewart, J.R., 2013. Fetal nutrition in lecithotrophic squamate reptiles: toward a comprehensive model for evolution of viviparity and placentation. *J. Morphol.* 274, 824–843.
- Svahn, K., 1975. Blood parasites of the genus *Karyolysus* (Coccidia, Adeleidae) in Scandinavian lizards. Description and life cycle. *Norw. J. Zool.* 23, 277–295.
- Telford Jr., S.R., 2009. Hemoparasites of the Reptilia: Color Atlas and Text. CRC Press, Taylor and Francis Group, Boca Raton, Florida, USA.
- Ujvari, B., Madsen, T., Olsson, M., 2004. High prevalence of *Hepatozoon* spp. (Apicomplexa, Hepatozoidae) infection in water pythons (*Liasis fuscus*) from tropical Australia. *J. Parasitol.* 90, 670–672.
- Valero, Y., Cuesta, A., Cammarata, M., Esteban, M.A., Chaves-Pozo, E., 2018. Immune-endocrine interactions in the fish gonad during infection: an open door to vertical transmission. *Fishes* 3, 24.
- Zechmeisterová, K., De Bellocq, J.G., Široký, P., 2019. Diversity of *Karyolysus* and *Schellackia* from the Iberian lizard *Lacerta schreiberi* with sequence data from engorged ticks. *Parasitology* 146, 1690–1698.