



Review Article

Neuroimaging of structural pathology and connectomics in traumatic brain injury: Toward personalized outcome prediction<sup>☆</sup>



Andrei Irimia<sup>a,\*</sup>, Bo Wang<sup>b</sup>, Stephen R. Aylward<sup>c</sup>, Marcel W. Prastawa<sup>b</sup>, Danielle F. Pace<sup>c</sup>, Guido Gerig<sup>b</sup>, David A. Hovda<sup>d</sup>, Ron Kikinis<sup>e</sup>, Paul M. Vespa<sup>d</sup>, John D. Van Horn<sup>a</sup>

<sup>a</sup> Laboratory of Neuro Imaging, Department of Neurology, University of California, Los Angeles, CA 90095, USA  
<sup>b</sup> Scientific Computing Institute, University of Utah, Salt Lake City, UT 84112, USA  
<sup>c</sup> Kitware, Inc., Clifton Park, NY 12065, USA  
<sup>d</sup> Brain Injury Research Center, Department of Neurosurgery, University of California, Los Angeles, CA 90095, USA  
<sup>e</sup> Surgical Planning Laboratory, Department of Radiology, Harvard Medical School, Boston, MA 02115, USA

ARTICLE INFO

Article history:  
 Received 19 June 2012  
 Received in revised form 14 August 2012  
 Accepted 15 August 2012  
 Available online 24 August 2012

Keywords:  
 Trauma  
 Neuroimaging  
 MRI/fMRI  
 Diffusion tensor  
 Outcome measures

ABSTRACT

Recent contributions to the body of knowledge on traumatic brain injury (TBI) favor the view that multimodal neuroimaging using structural and functional magnetic resonance imaging (MRI and fMRI, respectively) as well as diffusion tensor imaging (DTI) has excellent potential to identify novel biomarkers and predictors of TBI outcome. This is particularly the case when such methods are appropriately combined with volumetric/morphometric analysis of brain structures and with the exploration of TBI-related changes in brain network properties at the level of the connectome. In this context, our present review summarizes recent developments on the roles of these two techniques in the search for novel structural neuroimaging biomarkers that have TBI outcome prognostication value. The themes being explored cover notable trends in this area of research, including (1) the role of advanced MRI processing methods in the analysis of structural pathology, (2) the use of brain connectomics and network analysis to identify outcome biomarkers, and (3) the application of multivariate statistics to predict outcome using neuroimaging metrics. The goal of the review is to draw the community's attention to these recent advances on TBI outcome prediction methods and to encourage the development of new methodologies whereby structural neuroimaging can be used to identify biomarkers of TBI outcome.

© 2012 The Authors. Published by Elsevier Inc. All rights reserved.

Contents

1. Introduction . . . . .	2
2. Neuroimaging for structural analysis of TBI . . . . .	3
2.1. Promises of structural neuroimaging . . . . .	3
2.2. Pathology identification . . . . .	3
2.3. Tissue classification . . . . .	3
2.4. Morphometric and volumetric calculations . . . . .	5
2.5. Challenges and future directions . . . . .	6
3. Neuroimaging for connectomic analysis of TBI . . . . .	7
3.1. Diffusion imaging of TBI . . . . .	7
3.2. Personalized connectomic analysis . . . . .	8
3.3. Network-theoretic methods . . . . .	9

*Abbreviations:* AAL, Automatic Anatomical Labeling; ADC, apparent diffusion coefficient; ANTS, Advanced Normalization Tools; BOLD, blood oxygen level dependent; CC, corpus callosum; CT, computed tomography; DAI, diffuse axonal injury; DSI, diffusion spectrum imaging; DTI, diffusion tensor imaging; DWI, diffusion weighted imaging; FA, fractional anisotropy; FLAIR, Fluid Attenuated Inversion Recovery; fMRI, functional magnetic resonance imaging; FSE, Functional Status Examination; GCS, Glasgow Coma Score; GOS, Glasgow Outcome Score; GM, gray matter; GRE, Gradient Recalled Echo; HARDI, high-angular-resolution diffusion imaging; IBA, Individual Brain Atlas; LDA, linear discriminant analysis; MRI, magnetic resonance imaging; NINDS, National Institute of Neurological Disorders and Stroke; PCA, principal component analysis; PROMO, PROspective MOTion Correction; SPM, Statistical Parametric Mapping; SWI, Susceptibility Weighted Imaging; TBI, traumatic brain injury; TBSS, tract-based spatial statistics; WM, white matter; 3D, three-dimensional.

<sup>☆</sup> This is an open-access article distributed under the terms of the Creative Commons Attribution-NonCommercial-ShareAlike License, which permits non-commercial use, distribution, and reproduction in any medium, provided the original author and source are credited.

\* Corresponding author. Tel.: +1 310 206 2101; fax: +1 310 206 5518.

E-mail address: [andrei.irimia@loni.ucla.edu](mailto:andrei.irimia@loni.ucla.edu) (A. Irimia).

3.4.	Functional connectomics . . . . .	10
3.5.	Caveats of connectomic neuroimaging. . . . .	10
4.	Statistical models for TBI outcome prediction using structural neuroimaging . . . . .	11
4.1.	Significance of multivariate models . . . . .	11
4.2.	The role of CT in outcome prediction . . . . .	11
4.3.	Prognostication via diffusion imaging . . . . .	11
4.4.	Multivariate models for identifying biomarkers of outcome . . . . .	12
5.	Summary and conclusion . . . . .	14
	Acknowledgments . . . . .	14
	References . . . . .	14

## 1. Introduction

There are approximately 1.5 million new cases of non-fatal traumatic brain injury (TBI) in the US every year. Worldwide, the incidence of this condition has been estimated at one to five cases for every thousand people (Sosin et al., 1996; Thornhill et al., 2000), resulting in at least 6.8 million TBI cases every year. In the US, TBI is annually responsible for over 500,000 emergency room visits, 100,000 hospital admissions, 7000 deaths and 30,000 permanent disabilities. The financial burden of this condition amounts to over \$56 billion annually, of which ~56% are accounted for by moderate and severe cases. Whereas over one in four TBI cases is moderate, at least one in ten moderate TBI patients experiences long-term cognitive and behavioral impairment (McAllister et al., 2006), compared to one in two victims for moderate TBI. Thus, TBI is a high and growing concern for both biomedical and health research agencies and veteran benefit departments, which have called for renewed efforts dedicated to ameliorating outcome and quality of life.

Common areas of cognitive impairment caused by TBI include memory, information processing speed, attention and executive function, with many TBI patients experiencing degradation in all four even when their TBI is classified as mild (Parizel et al., 1998). Some studies have proposed that as many as one in three mild TBI victims has persistent long-term cognitive deficits (Binder, 1997; Binder et al., 1997), which can occur despite their brains appearing normal on conventional neuroimaging scans. Whereas age and clinical variables are stronger predictors of outcome than computed tomography (CT) abnormalities (Jacobs et al., 2010), the use of CT for outcome prediction has become more standardized following results from the IMPACT study, where outcome prediction for severe TBI relies partly on Marshall grading (Maas et al., 2007). Thus, although no standard predictive model of TBI outcome using MRI currently exists, the combined use of CT and standard magnetic resonance imaging (MRI) has become standard in TBI clinical care due to the advantages of using both techniques (Lee and Newberg, 2005). Nevertheless, the sensitivity of combined CT/MR to mild TBI remains undesirably low because these techniques can often fail to identify structural abnormalities in mild TBI patients (van der Naalt et al., 1999). In fact, as many as two out of three mild TBI patients appear healthy on anatomic MRI scans (Hofman et al., 2001), whereas non-hemorrhagic diffuse axonal injury (DAI) is virtually undetectable by CT and only difficult to detect by standard  $T_1$ -weighted MRI (Provenzale, 2010). Consequently, the multimodal use of CT and standard MRI can be insufficient for the purpose of accurately predicting the severity of TBI sequelae in mild cases, and achieving a satisfactory level of sensitivity may require the use of additional imaging techniques.

An important observation that is relevant when discussing the use of CT/MRI imaging for TBI outcome prediction concerns the sensitivity of these neuroimaging techniques. Suppose that recovery of consciousness is adopted as the measure of case outcome. It has been known (Tollard et al., 2009) that good outcome measured in this manner can occur in some patients despite positive findings of extensive pathology by CT/MR neuroimaging which might instead suggest poor prognosis. This implies that, for severe TBI, the specificity of CT/MR (i.e. the probability of negative findings by these techniques given that case outcome

is favorable) is lower than might be expected. In conclusion, if only CT and MR are used, multimodal neuroimaging can have either undesirably low sensitivity (mild TBI) or specificity (severe TBI). For reasons such as these, recent years have witnessed a sustained trend toward increasing the number of imaging techniques being used for TBI case evaluation and outcome prediction. Whereas the use of magnetic resonance spectroscopy (MRS) for outcome prediction is currently somewhat limited (Marino et al., 2011), one method that has been widely adopted to complement standard structural imaging techniques is diffusion tensor imaging (DTI). Because DTI can reveal in detail how TBI affects brain connectivity via DAI, the technique has the potential to offer much beneficial information to clinicians in their attempts to identify novel biomarkers that are predictive of outcome. Whereas the primary advantage of standard CT and MR is the ability of these techniques to provide volumetric or morphometric measures of brain structure, DTI is promising partly because it can be used to perform tractography and thereby extract connectivity measures (fiber tract length, connectivity density) for white matter (WM) connections. This allows one to obtain a very large number of connectivity metrics that can be analyzed using various techniques, including the armamentarium of network theory. Additionally, DTI can be combined with fMRI to infer patterns of functional connectivity in TBI. Thus, combining methods that yield volumetric and/or morphometric measures (i.e. CT, MR) with techniques that measure structural and functional connectivity (such as DTI and fMRI, respectively) appears to be the recipe of choice for future studies that aim to extend the capabilities of neuroimaging for the purpose of TBI clinical outcome prediction.

The purpose of this review is to summarize recent developments on the role of MRI and DTI in the search for novel structural neuroimaging biomarkers that have outcome prognostication value in TBI. The themes being explored in what follows cover notable trends in this area of research and highlight promising avenues of future investigation. These themes include

- (1) the role of advanced MRI processing methods in the analysis of structural pathology
- (2) the use of brain connectomics and network analysis to identify outcome biomarkers
- (3) the application of multivariate statistics to predict outcome using neuroimaging metrics.

Recent contributions to the field favor the view that multimodal neuroimaging and advanced MRI/DTI image processing have the potential to identify novel biomarkers and predictors of TBI outcome. This is particularly the case when such methods are appropriately combined with volumetric/morphometric analysis of brain structures and with the exploration of TBI-related changes in brain network properties at the level of the connectome. In this context, one goal of this article is to draw the community's attention to these recent advances by discussing a selected body of relevant literature. However, we would like to point out that the extent to which our own work is highlighted throughout the text is greater than would be warranted in the context of a typical review. This is because it is our desire to provide the reader with examples of graphical rendering techniques currently being used in the field without the logistic complexities incurred through

showcasing visualizations to which we have no access. As a result, this implies that our article might be better viewed as a ‘perspective’ in contrast to a truly comprehensive ‘review’, per se. Nevertheless, given that *NeuroImage: Clinical* does not presently include a designation for perspective articles, we have aimed to review and summarize a range of representative research reports covering important elements of structural, functional, and connectomic imaging in TBI.

## 2. Neuroimaging for structural analysis of TBI

### 2.1. Promises of structural neuroimaging

Throughout the past decade, TBI image analysis has been receiving increased attention in the medical image processing community due to the strong motivation of clinicians and health policy makers to develop and increase the use of quantitative tools that can allow one to perform analysis and visualization of complex injury-related pathology. Until recently, research that involved conventional MRI processing to identify markers of TBI outcome would often focus on quantifying intensity differences between contusions and healthy-appearing tissues using various modalities. While this type of analysis has been effective in providing important insight into TBI, voxel intensity analysis does not take full advantage of the capabilities that neuroimaging has to offer. In particular, with the advent and dissemination of three-dimensional (3D) brain visualization methods, a considerable amount of attention and effort has been allocated to the task of providing the ability to generate, manipulate and quantitatively characterize 3D models of TBI. Two important causes for the emergence of this trend are the need for 3D models of TBI that can be used for surgical planning, as well as the desire to identify volumetric and morphometric measures that can prognosticate clinical outcome. In this context, there has been increased understanding by the TBI neuroimaging community that volumetric and morphometric measures of TBI pathology can be prognostically correlated with various case outcome measures (see last section of this review).

Determining how the macroscopic profile of the brain changes in response to injury and/or treatment could help to identify cortical regions that are likely to experience atrophy and degeneration, and could consequently aid in the early formulation of targeted rehabilitation protocols. Utilizing quantitative brain morphological measures to assess changes in brain structure at a systematical level could also identify those brain regions that are particularly sensitive to TBI sequelae (Bigler, 2001). In addition, the atrophy profiles of brain areas that do not coincide with the locations of primary injuries may help researchers to understand how focal TBI can give rise to DAI and to secondary structural pathology far from the site of primary TBI. These specific aims are paramount to the extension of existing MRI neuroimaging techniques to the sophisticated exploration of TBI pathology.

Increased understanding of the potential advantages that prognostic studies can offer has also brought about renewed interest into the development of automated image processing methods that can allow researchers to extract brain volumetrics and morphometrics from large cohorts of TBI patients. Such interest is partly based on the awareness that, due to the heterogeneity of TBI, prognostic studies of outcome in this condition can require large sample sizes in order to achieve sufficient statistical power for prediction. Consequently, the key methodological hurdle that must be overcome in order to make structural neuroimaging a powerful tool for predicting TBI outcome is the current paucity of automated image processing methods that can allow researchers to analyze large numbers of TBI CT/MRI volumes without the need for excessive user input or intervention.

### 2.2. Pathology identification

To date, the number of studies that use neuroimaging volumetrics and morphometrics to identify outcome markers has been disappointingly low, in part because manual segmentation of TBI volumes

is laborious and resource-demanding when large sample sizes are involved. Generally, computational methods for volumetric and morphometric analysis (such as FreeSurfer; Dale et al., 1999; Desikan et al., 2006; Destrieux et al., 2010; Fischl et al., 1999a) are preferable to manual ones because of the reduced cost of the former and of the smaller amount of time that is required for their application. Many automatic methods can achieve an accuracy level that is comparable to that of manual methods, although this is most often the case for healthy populations or for disease groups whose anatomies do not differ appreciably from health. In the case of TBI, automated methods can fail, and the development and dissemination of accurate and reliable automatic segmentation and morphometry methods that are tailored for TBI remain goals of central importance to future progress in this area.

CT and structural MRI have been and remain techniques of key importance for the purpose of TBI multimodal neuroimaging. Within relatively short scan times, both  $T_1$ - and  $T_2$ -weighted MR imaging can offer highly accurate visual descriptions of water and fat distribution in both healthy-appearing and pathological tissues at high spatial resolutions. Similarly, CT has been very valuable for structural imaging of TBI, and more so than MRI in the first few days after injury. For example, pathology documented using CT has been found to be a clinically important risk factor in determining post-traumatic neurological deficits (Asikainen et al., 1999), and in categorizing CT abnormalities based on mesencephalic cistern status, midline shift, presence of surgical masses has helped to predict mortality in head injury cases (Englander et al., 2003). CT has also been useful to show that hypoxia in the pre-hospital setting significantly increases the odds of mortality after TBI controlled for multiple variables (Chi et al., 2006). A study by Lehtonen et al. (2005) examined the relationship between cortical lesion location observed via CT and brain injury outcome to conclude that frontal and fronto-temporal lesions detected acutely using CT were associated with poorer performance on neuropsychological measures of executive function and memory at rehabilitation discharge.

Information on TBI obtained from MRI/CT allows clinicians and researchers to localize and quantify focal lesions straightforwardly and to evaluate lesion loads. Additional MR sequence types such as Fluid Attenuated Inversion Recovery (FLAIR), Gradient-Recalled Echo (GRE)  $T_2$ -weighted imaging and Susceptibility Weighted Imaging (SWI) can increase the descriptive power of MRI by allowing researchers to distinguish between various types of lesions. FLAIR, a pulse sequence which uses inversion recovery to nullify cerebrospinal fluid (CSF) signal, has been widely used to associate hyperintensities in this modality with edema. GRE imaging and SWI, on the other hand, are commonly used to identify hemorrhages, which appear hypointense in these modalities. The use of these three sequences is very common in TBI because of their abilities to isolate pathology, and a combination of  $T_1$ ,  $T_2$ , FLAIR and SWI imaging has already been successfully used by Irimia et al. (2011) to obtain segmentations and 3D models of edema, hemorrhaging tissue, as well as healthy-appearing white matter (WM) and gray matter (GM).

### 2.3. Tissue classification

One significant methodological issue that must be taken into account when designing automatic TBI segmentation methods is the fact that TBI characterization from MRI often requires the combined use of several image channels in order to identify pathology. Thus, TBI neuroimaging is multimodal *par excellence*. Because MR volumes of TBI often contain skull fractures, multiple lesion types and associated tissue deformations, multi-channel segmentation of TBI volumes bears significant challenges, especially when such abnormalities are characterized by having a complex structure. Examples of both acute and chronic multi-channel MR image patient are shown in Fig. 1, where the challenging nature of TBI-related pathology is demonstrated. As this figure illustrates, TBI presents significant segmentation challenges

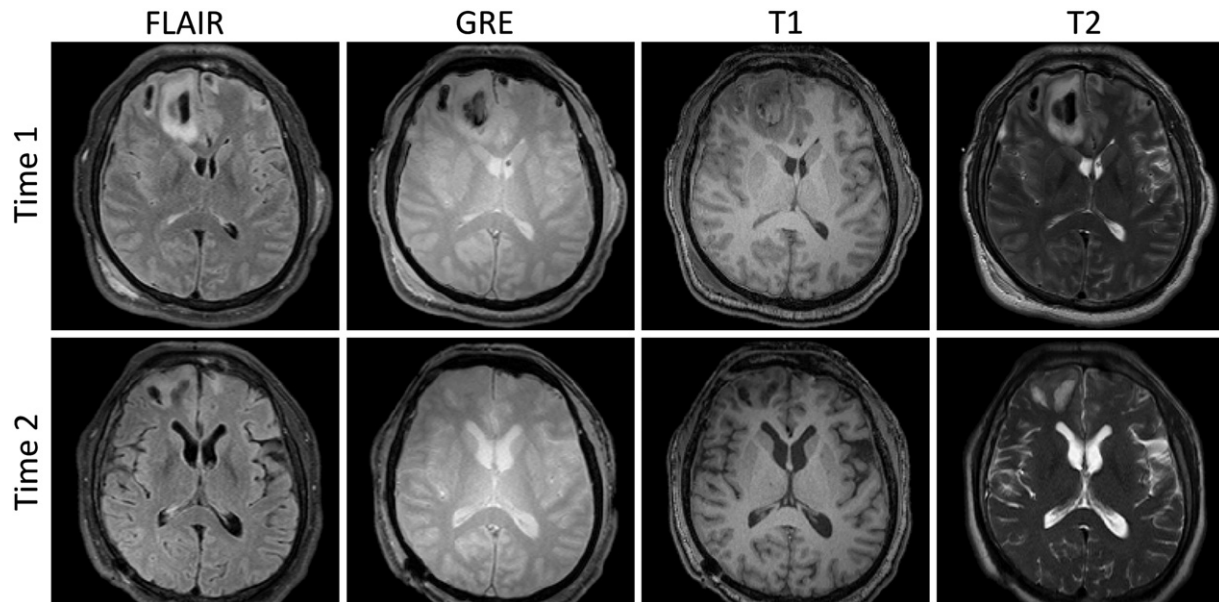


Fig. 1. Axial views of acute and chronic TBI in a sample subject.

due to the need to account for tissue classes other than healthy-appearing GM and WM. Depending on imaging sequence type, these tissues associated with pathology can have distinct intensities and spatial configurations. Moreover, ascertaining their physical and chemical content can pose substantial interpretative dilemmas even for experienced health care providers, which makes the development of robust image processing methods for TBI even more difficult.

Segmentation algorithms for MR images of healthy-appearing brains have been developed by a large number of investigators (see, for example, Van Leemput et al., 1999 and Zhang et al., 2001 for two early developments), and software packages for this task are both widely and freely available. Most such algorithms, however, are not designed to address pathology, which presents significant challenges because the locations and shapes of pathological structures are not easily predictable and, in certain MR modalities, some pathology patterns present image intensities and appearance that are similar to those of normal tissues. Generally, developers of TBI segmentation algorithms have inspired themselves from methods for the MR analysis of brain sclerosis and tumors, which present similar problems compared to TBI. In the case of sclerosis, Van Leemput et al. have proposed a method where regions affected by pathology are treated as outliers from healthy anatomy (Van Leemput et al., 2001), whereas Wu et al. (2006) introduced a k-nearest neighbor (kNN) method that uses multichannel MRI to differentiate between abnormal and healthy-appearing tissues. Recently, Geremia et al. (2011) proposed a method based on decision forests and, in the case of tumors, Prastawa et al. (2004, 2003) developed a method based on outlier detection and subject-specific modification of atlas priors. Similarly, Clark et al. (1998) introduced an automatic method for pathology segmentation that uses knowledge-based techniques. A level-set based tumor segmentation method has been developed by Ho et al., 2002, whereas Menze et al. (2010) have presented a generative model for brain tumor segmentation using multi-modal MR images. For the express purpose of TBI image analysis, Thatcher et al. (1997) have used fuzzy C-means, kNN and manual classification to segment 3D MR images of TBI patients, and Wang et al. (2012a, 2012b) have proposed the use of a personalized atlas for the segmentation of longitudinal TBI data. The essential ideas behind the latter method are to jointly segment images acquired at the acute and chronic stages, as well as to describe anatomical changes due to therapeutic intervention and recovery.

In traditional image processing approaches, individual images of longitudinal series are treated independently by separate segmentations.

A notable innovation suitable for TBI is that of Wang et al., who use information from all time points to improve segmentation and to additionally describe changes in healthy tissue and pathology (Fig. 2). Their segmentation method iteratively estimates the image appearance model as well as the spatial anatomical model that undergoes diffeomorphic deformation and non-diffeomorphic/topological changes. In this approach, the initialization step of the algorithm consists of manually selecting one or several primary lesion sites and then affinely registering normal brain atlas to the image at each time point. The initial coarse segmentation is then refined via a joint approach composed of Bayesian segmentation and of personalized atlas construction. This latter step estimates the average of the posteriors obtained from Bayesian segmentation at each time point, whereafter the estimated average is warped back to each time point so as to provide the updated priors for the next iteration of Bayesian segmentation. Once the user has performed the manual initialization (for example, by placing spheres at major lesion sites), the method automatically segments healthy structures (WM, GM, CSF) as well as different lesion types including hemorrhagic lesions, edema and chronic pathology.

Fig. 3 illustrates the construction of a personalized spatiotemporal atlas using the method of Wang et al. The longitudinal segmentation method makes use of information from multiple MR channels and from all time points to achieve a robust segmentation (Wang et al., 2012a, 2012b). The spatial transformations between any time point and the average space are obtained through the estimation of a subject-specific atlas with associated nonlinear deformations, and the tissue deformation between time points is made available by composition of the individual transformations or of their inverses. By means of a procedure such as this, a segmentation method used longitudinally can be modified to provide not only tissue and lesion segmentation but also information related to the amount and direction of deformation between tissues as measured at pairs of time points. The results of this type of process are clinically relevant because they provide quantitative measurements of lesions for each time point, as well as additional information on how tissues and/or pathology shrink or expand in time as a result of recovery.

Segmentations of lesions as imaged at two time points (acute and chronic) and visualization of the deformation field are shown in Fig. 4 for a sample subject. In this case, the deformation field specifies the direction and magnitude of displacement between time points and can be used to determine and evaluate structural changes in brain anatomy. A significant advantage of this type of framework is that it can handle different sets of modalities at each time point, thus

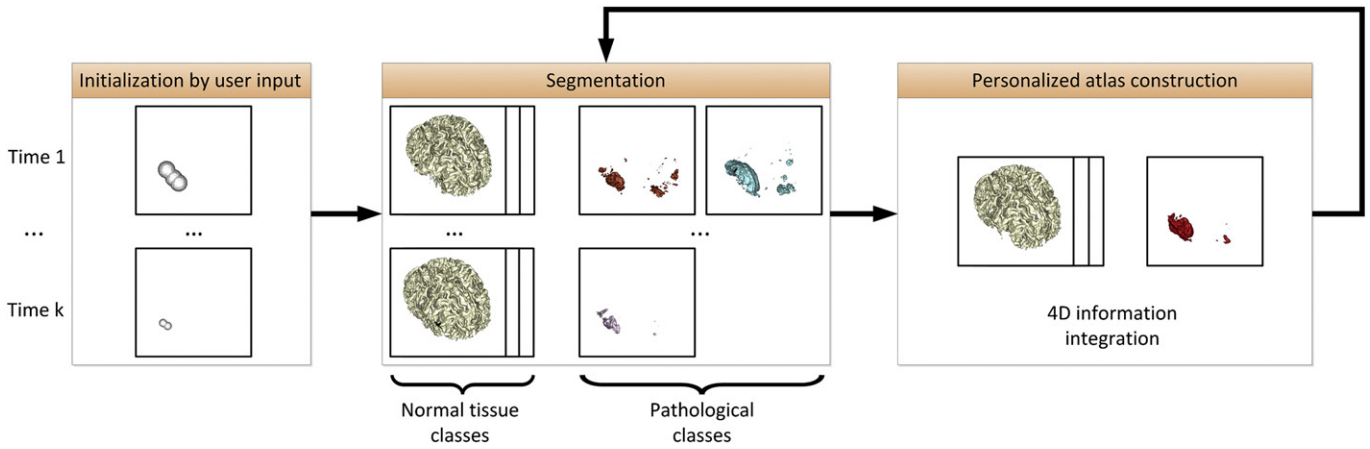


Fig. 2. Overview of semi-automatic segmentation using personalized atlas construction.

providing flexibility in the analysis of clinical scans. Results on a range of subjects (Wang et al., 2012a, 2012b) have demonstrated that joint analysis of TBI volumes acquired at different time points yields improved segmentation compared to independent analysis of the time points. Joint longitudinal segmentation methods such as that of Wang et al. are also important because they provide the ability to assess the value of novel outcome measures by means of Bayesian estimation and predictor–corrector methods. Such methods can allow one to predict outcome using neuroimaging metrics associated with the acute time point, and then to modify, correct or otherwise improve the predictive value of those metrics based on the evolution of the injury. Subsequently, outcome measures identified in this way can in theory be applied prospectively for further validation.

2.4. Morphometric and volumetric calculations

In addition to new and improved methods for volumetric analysis of TBI based on MRI, adaptable brain morphometry tools are also

needed to explore outcome prediction hypotheses, if only because it is conceivable that TBI-induced atrophy and/or regeneration can modify the shape of the cortex in ways that can forecast outcome. Morphometric methods frequently make use of MRI volume segmentations to fit a mesh of points to the surface of the brain and then parcellate its structures into regions using a population atlas as a structural prior and based on knowledge of the local curvature (Fischl and Dale, 2000; Fischl et al., 2001; Fischl et al., 2002; Fischl et al., 1999b; Fischl et al., 2004). Subsequently, volumetrics (cortical thickness, GM and WM volume, etc.) and morphometrics (curvature, folding index) can be computed for each cortical region, as has been done extensively in studies of aging (Salat et al., 2004) or disease (Kuperberg et al., 2003; Rosas et al., 2002). Although automatic cortical parcellation methods have been applied to TBI in the past, the caveat remains that errors due to the application of probabilistic tissue classification can frequently occur whenever TBI anatomy differs appreciably from health. Some studies where automatic parcellation was applied to TBI volumes have reported major topological defects,

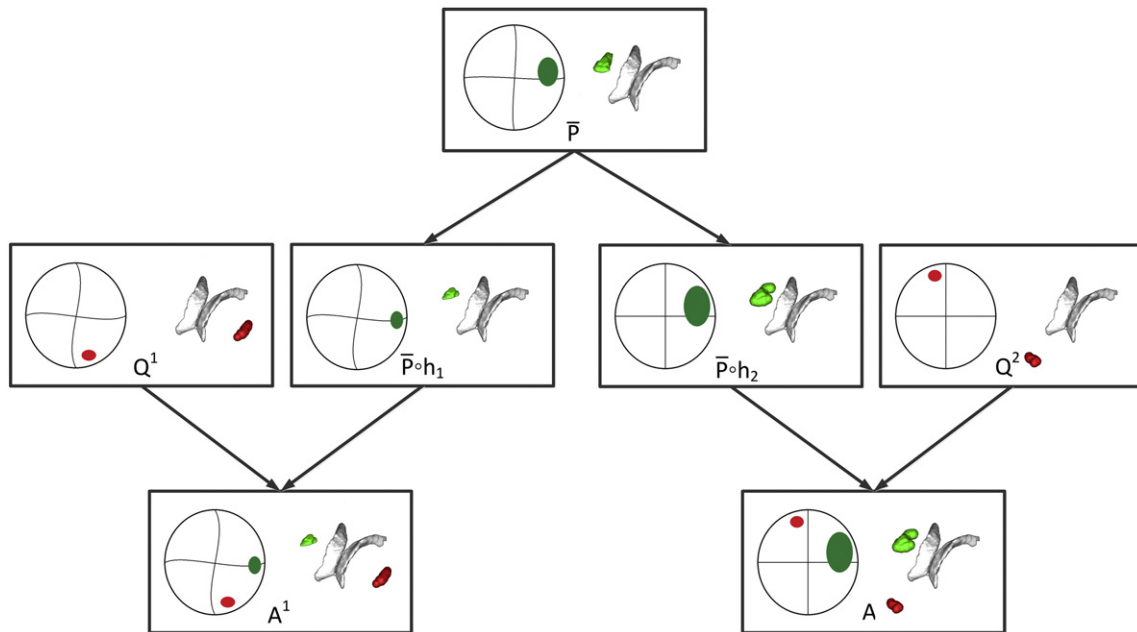
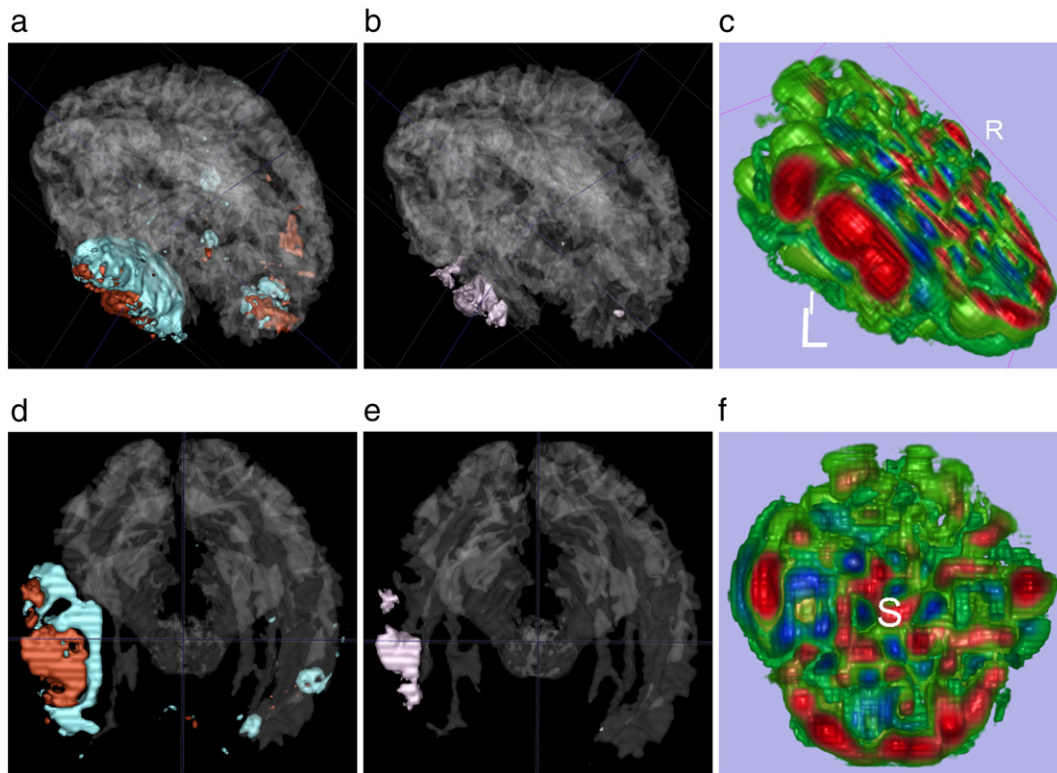


Fig. 3. Construction of a personalized spatiotemporal atlas using diffeomorphic and non-diffeomorphic components. The diffeomorphic component is the temporally global atlas  $\bar{P}$  that is mapped to each time point while preserving atlas topology. The non-diffeomorphic components are the temporally local probability density functions  $Q_t$  at each time point  $t$  that may change the topology between different time points. Regions that change diffeomorphically are colored in green, while regions that change topology are colored in red.



**Fig. 4.** Segmentation of lesions in both acute and chronic images and visualization of the deformation field via the Jacobian determinant. (a) 3D lesion segmentation of acute images, blue color indicates edema, brown color indicates bleeding, and the transparent color indicates white matter. (b) 3D lesion segmentation of chronic images, purple color indicates necrosis, and the transparent color indicates white matter. (c) Visualization of the deformation field via the determinant of the Jacobian, red color indicates tissue compression, green color indicates no change, blue color indicates tissue expansion. (d) Axial view of lesion segmentation of acute images. (e) Axial view of lesion segmentation of chronic images. (f) Axial view of visualization of the deformation field via the determinant of the Jacobian matrix.

failures to fit cortical surfaces, as well as subcortical segmentation errors (Strangman et al., 2010). Consequently, further methodological improvements in this area are needed.

With the extension of conventional morphometry methods to TBI analysis come numerous pitfalls and technological difficulties. Whereas sequences such as FLAIR,  $T_2$  and SWI can aptly localize focal pathology, one segmentation task that continues to remain problematic is that of identifying the boundary between WM from GM when tissues on both sides of it have been affected by trauma. In chronic TBI, scar tissue can also lead to overestimation of GM volume and/or underestimation of WM volume. Unfortunately, these issues bear relevance upon the accuracy of both volumetric and morphometric measures extracted from structural MRI because, on the one hand, improper segmentation of the WM/GM boundary can result in the inaccurate calculation of GM and WM volumes. On the other hand, errors of this kind can dramatically affect computed morphometric measures such as local curvature and the folding index of the cortical surface.

### 2.5. Challenges and future directions

Much of the popularity enjoyed by  $T_1$ - and  $T_2$ -weighted sequences in the image processing community is due to their excellent contrast properties, which allows WM and GM to be easily distinguished in the healthy brain. In TBI, however, injury to somata and axons causes lipoproteins and other intracellular material to be released into the extracellular space. This typically results in the alteration of fat and water contents in contusional and peri-contusional tissues, which can make lesioned WM and GM difficult to distinguish from each other in either  $T_1$ - or  $T_2$ -weighted scans (Fig. 1). Consequently, in both  $T_1$ - and  $T_2$ -weighted MR, edemic and hemorrhaging tissues can have comparable intensities, which can make their differentiation

problematic especially when visual inspection is performed solely based on these two techniques. Because many algorithms for segmentation and morphometry aim to identify the GM/WM boundary based on intensity differences in  $T_1$ - or  $T_2$  images, this implies that GM/WM segmentation can be particularly challenging in peri-contusional regions. Although significant, this problem is yet to receive appropriate attention by the neuroimaging and image processing communities.

Mapping tissue changes accurately can improve the accuracy of numerical methods which aim to calculate volumetric and morphometric measures. Quantifying tissue changes during recovery from TBI, however, can be particularly challenging because tissue movements and longitudinal changes in intensity are difficult to predict. From the standpoint of MR imaging of brain injury, there are three primary macroscopic tissue changes that occur over time, namely (1) global tissue deformations, (2) local changes in the lesion geometry and (3) local changes in the mixture of tissues and lesions due to such changes as healing or atrophy. Lesions which infiltrate or recede from healthy tissue, or which displace healthy tissue, confound most image registration methods and result in poor estimation of TBI volumetrics. Additionally, in the presence of such changes, classical deformable registration methods likely produce unrealistic deformation estimates and thereby inappropriately bias the estimation of morphometric measures. One family of techniques which attempt to address these challenges are deformable registration methods with weak and strong models of expected changes (e.g., with models of tumor growth) (Hogea et al., 2008; Prastawa et al., 2009). The registration accuracy of such models degrades when TBI lesion growth patterns as predicted by the algorithm do not match the lesion configuration of the subject for whom the MRI volumes acquired at different time points are being co-registered. To provide a remedy for this disadvantage, some authors (Brett et al., 2001; Lamecker and Pennec, 2010; Stefanescu et al., 2004) have introduced methods which ‘hide’

the areas in and around a lesion in order to avoid the negative influence of the former upon the registration. One drawback to such methods is that the registration in and around the lesion (where the results produced by the algorithm are often most clinically valuable) can be particularly poor because such areas often contain important registration information that is not being used. This can be the case despite the fact that one goal of TBI registration and segmentation remains, even in such cases, that of being able to distinguish background image deformations from foreground deformations with respect to an embedded geometric object (focal injury in this case). The recent geometric metamorphosis method developed by Niethammer et al. (2011) addresses these complexities by including a geometric shape model of pathology, such that deformations can be explicitly captured in conjunction with deformations in the underlying image. This model can be used to represent the geometric deformation modulo background deformation, thereby allowing accurate visualization and quantification of hemorrhagic recession (Fig. 5).

TBI heterogeneity calls for large sample sizes in order to identify robust neuroimaging markers of outcome. For this reason, the availability of software to perform automatic segmentation and morphometry of TBI is essential. Freely available tools that have been used for the analysis of structural TBI data include Statistical Parametric Mapping (SPM, Friston et al., 2006), Individual Brain Atlases SPM (IBA SPM, Tae et al., 2008), Automatic Anatomical Labeling (AAL, Tzourio-Mazoyer et al., 2002), and Advanced Normalization Tools (ANTS, Avants et al., 2008). Some of these packages contain image processing tools which may be particularly suitable for TBI, such as SPM's DARTEL (Pereira et al., 2010). This volume co-registration package combines skull stripping and bias correction with good results for atrophied brains in Alzheimer's Disease (AD) and Huntington's Disease (HD), as well as in semantic and frontotemporal dementia (Kuceyeski et al., 2011). Recently, Irimia et al. (2011) introduced and illustrated the combined use of multimodal TBI segmentation and time point comparison using 3D Slicer ([www.slicer.org](http://www.slicer.org)), a widely-used software environment whose TBI data processing solutions are openly available via the National Alliance for Medical Image Computing (NA-MIC, [www.na-mic.org](http://www.na-mic.org)). These authors performed semi-automatic tissue classification and 3D model generation for intra-patient time point comparison of TBI using multimodal volumetrics and clinical atrophy measures.

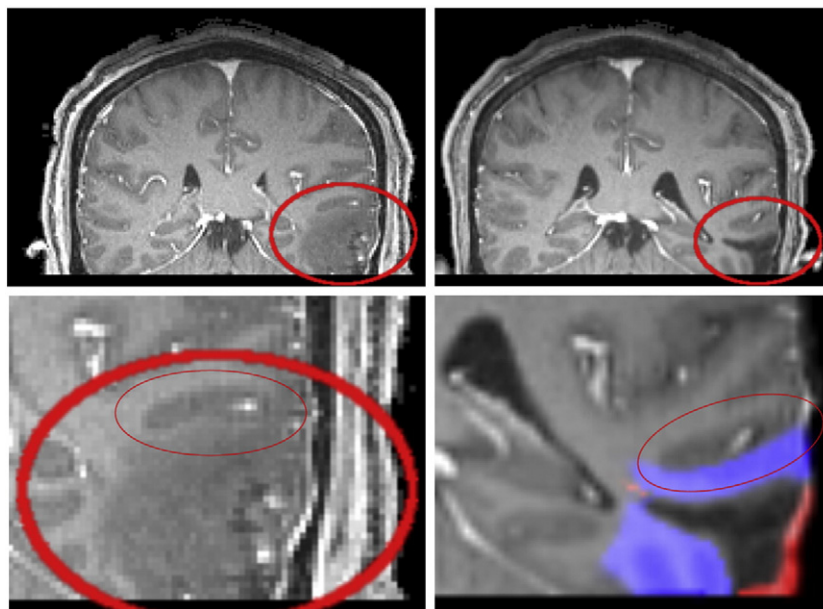
The authors identified and quantitatively assessed extra- and intra-cortical bleeding, edema, and DAI.

In conclusion, the foregoing discussion of TBI neuroimaging highlights the fact that the development and further refinement of TBI segmentation and morphometry methods should be granted more attention by the image processing community. Although segmentation and morphometry tools are very important for the purpose of computing accurate structural measures of TBI, the existing range of such tools is poor and many of them do not provide the ability to explore and accurately capture the longitudinal evolution of TBI lesions. Nevertheless, in spite of the difficulties outlined in this section, it remains the case that automation continues to make moderate-scale neuroanatomical studies of TBI realistically feasible. The use of automated segmentation followed by human review can significantly decrease the cost of implementing population- and subject-level studies of neurotrauma, and it is foreseeable that future improvements in these methods may one day allow researchers to undertake neuroimaging studies using samples of the TBI population that are comparable in size to those now being used by the AD and HD communities.

### 3. Neuroimaging for connectomic analysis of TBI

#### 3.1. Diffusion imaging of TBI

Diffusion imaging methods have been acknowledged to hold appreciable relevance to the improvement of TBI clinical care as a result of their ability to capture the effects of injury upon WM structure (Kraus et al., 2007; Rutgers et al., 2008; Vos and Bigler, 2011). In particular, the realization that focal lesions can lead to deficits in functions that are localized far from the primary injury has brought to the foreground the fact that the effects of DAI are easier to investigate using diffusion rather than conventional structural imaging. Acutely, acceleration/deceleration injuries result in water diffusion anisotropy changes because of restricted axoplasmic flow and increased flow across the axonal membrane (Kou et al., 2010). In diffusion weighted imaging (DWI), the apparent diffusion coefficient (ADC) quantifies the degree of diffusion restriction of water molecules caused by head injury in a voxel. It is a quantity which increases with vasogenic edema (where water diffuses into interstitial space) and decreases



**Fig. 5.** Comparison of acute (left) and chronic (right) MRI scans. Large ovals indicate the TBI lesion. Small ovals in bottom row indicate a brain structure that is deformed as the lesion heals. The blue region in the lower left image indicates tissue which has recovered during the healing process. Geometric metamorphosis automatically detects those regions in which tissue conversion (e.g., from lesion to healthy) has occurred.

with cytotoxic edema (where diffusion is restricted due to the presence of swollen ischemic cells). Thus, diffusion imaging techniques are useful for distinguishing between distinct types of edema and for identifying the mechanisms whereby such pathology can cause deterioration of function.

Because of the important advantages associated with structural neuroimaging methods in general and with diffusion imaging in particular, an NINDS panel recently proposed that neuroimaging should play a more important role in TBI classification so that TBI cases can be classified into more homogeneous categories based on neuroimaging criteria (Saatman et al., 2008). It has long been known that common sequences such as  $T_1$ ,  $T_2$ , FLAIR and SWI imaging can generate volumetrics and morphometrics of both healthy-appearing tissue as well as pathology. By comparison, DTI tractography methods allow one to map the macroscopic connections of the human brain, thereby providing a large amount of information that can allow one to infer the physical parameters of fiber tracts, such as length and density. Consequently, an important advantage of DTI that more research should focus on is the fact that this technique allows one to visualize axonal injury as the major pathological substrate of TBI.

As in the previously discussed case of conventional MRI, diffusion imaging techniques (high-angular-resolution diffusion imaging (HARDI), DWI, DTI and DSI) are complimentary and incremental in their abilities to generate quantitative metrics of brain connectivity. For example, image intensity in DWI reflects the rate of water diffusion at the location of each voxel, whereas DTI additionally allows researchers to capture the directionality of diffusion. Diffusion spectrum imaging (DSI) is a more recent technique which allows one to map complex fiber architectures by imaging the 3D spectra of tissues (Wedeen et al., 2005). These techniques can be very effectively combined with CT/MRI to study the effects of TBI upon specific WM structures in the brain and to identify abnormalities which other modalities cannot detect. In pediatric TBI, Sigmund et al. (2007) found that combined  $T_2$ , FLAIR and SWI imaging could provide a more accurate assessment of WM injury severity and detection of outcome-influencing lesions than CT. These authors found that the total volume of lesions detected on FLAIR and  $T_2$  images was, on average, at least four times greater than that detected on SWI. Nevertheless, the latter technique was found to be superior to the former two in its ability to detect micro-bleeds in WM, while diffusion techniques such as DWI were found to be capable of identifying DAI that is not visible on any of  $T_2$  Spin Echo,  $T_2^*$  GRE or FLAIR sequences. These and other relative merits of various diffusion and conventional neuroimaging modalities have been excellently evaluated by Metting et al. (2007), whose review the reader is encouraged to consult. An important conclusion of these studies is that diffusion imaging increases our ability to identify WM pathology, and that DWI/DTI/DSI sequences should be used to acquire data from TBI patients whenever this is possible.

DTI constitutes an excellent imaging modality for the noninvasive study of brain architecture, with recent advances in software and rendering allowing visualization of WM tracts in the entire brain within a time period that is clinically acceptable from the standpoint of acute care. Such advances indicate that it may now be feasible to extract TBI outcome biomarkers from diffusion data, and additionally to use these biomarkers to formulate treatments or interventions that rely on brain connectivity data to reverse or prevent further damage to WM. DTI is also well suited for the study of brain network properties in TBI patients, and even for investigating structural connectivity damage in TBI subjects of historical importance, as for example in the celebrated case of Phineas Gage (Van Horn et al., 2012). Because of the appreciable effect that DAI can have upon long-term outcome (Liew et al., 2009; Shigemori et al., 1992), it is foreseeable that clinical interventions tailored in response to specific changes in WM that occur acutely or sub-acutely may significantly affect survival rate and long-term outcome. Consequently, longitudinal studies of WM connections using diffusion neuroimaging should play a more prominent role in translational TBI research and more attention should be devoted to

the task of developing tools for the analysis of WM fibers and brain networks across subjects and time points.

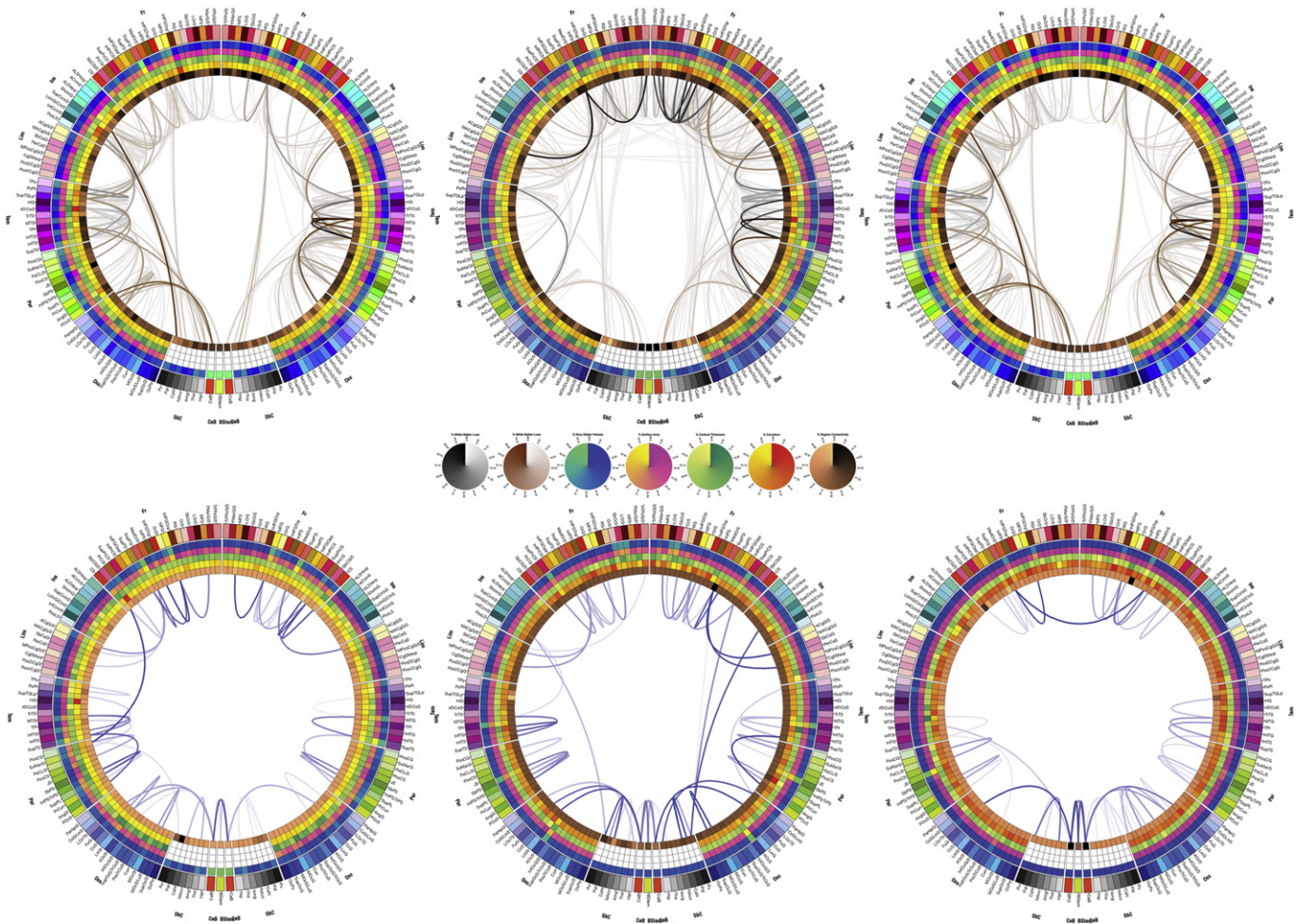
### 3.2. Personalized connectomic analysis

Although diffusion methods are suitable for the longitudinal study of WM connectivity, this topic has been insufficiently explored in TBI patients. Nonetheless, several studies have used diffusion imaging measurements to reveal that WM abnormalities can appear quickly after injury and then evolve dynamically over time (Mac Donald et al., 2007; Sharp and Ham, 2011) as a consequence of axonal injury and demyelination (Beaulieu et al., 1996; Song et al., 2002; Sun et al., 2008). One limitation of diffusion techniques is that, although diffusion imaging is very suitable for investigating the longitudinal evolution of brain connectivity, DTI scans can capture only snapshots of cerebral reorganization prompted by injury. Due to high attrition rates in many longitudinal TBI studies (Corrigan et al., 2003) and to TBI heterogeneity, investigators must often rely on small sample sizes to perform this type of research, which can appreciably curtail the predictive power of their statistical analyses. Consequently, it is important that more studies be undertaken where DTI scans are acquired at a number of time points after injury in a large patient population so that the acute effects of TBI upon brain network topology can be better understood. In particular, the acute period after TBI should be targeted because this is when important changes in brain connectivity occur. Typically, the first 4–6 h after injury is associated with cytoskeletal disruption followed by axonal disconnection between 1 and 7 days after the traumatic event (Gaetz, 2004). Because such damages to brain connectivity can result in deterioration of cognitive function that may persist for years (Povlishock and Katz, 2005), further efforts should be dedicated to the longitudinal use of DTI in the acute phase of TBI in order to understand the relationship between the structural remodeling of the brain, on the one hand, and long-term improvements or deterioration in motor and cognitive function, on the other hand.

To address the need for methods that allow one to investigate personalized profiles of WM atrophy in TBI, Irimia et al. (2012a) used DTI to introduce a patient-tailored approach to the graphical representation of WM change over time. These authors' method allows one to visualize brain connections affected by pathology and to relate patient injury profiles to the existing body of scientific and clinical knowledge on affected cortical structure function. The approach provides the ability to quantify WM atrophy for personalized connectomics and allows one to integrate such knowledge with other clinical case information to provide a more insightful picture on the neuroplasticity and neuro-degeneration patterns that occur in the TBI brain. The authors also introduced a circular representation wherein the parcellated gyral and sulcal structures of the cortex are displayed as a circle of radially aligned elements called a "connectogram" (Fig. 6). To calculate inter-region connectivity in the approach of Irimia et al., each fiber tract extremity is first identified and associated with the pair of parcellated regions which it connects. In the second step, the percentage change in the density of fibers previously selected is computed for each connection, using the formula  $\Delta = [D(t_2) - D(t_1)] / D(t_1)$ . Finally, those fibers that have computed changes in fiber density with absolute values greater than 20% ( $|\Delta| > 20\%$ , i.e. the top four fifths of the distribution of percentage changes) are displayed on a separate connectogram. For each pair of cortical regions, the change  $\Delta$  in the fiber density  $D$  between successive time points  $t_1$  and  $t_2$  is computed as a percentage of the fiber count at acute baseline based on the multimodal imaging data acquired at the two time points. A combination of conservative restrictions upon the selection of atrophied fibers (see Irimia et al., 2012a for details) can then allow one to confidently identify fibers undergoing a large amount of atrophy in a particular patient.

Personalized atrophy profiles in the fashion of those created by Irimia et al. can be used to identify WM connections that have suffered





**Fig. 6.** Connectograms for three sample TBI subjects. For complete details on how to interpret the connectogram, the reader is referred to Irimia et al. (2012b). The outermost ring shows the various brain regions arranged by lobe (fr—frontal; ins—insula; lim—limbic; tem—temporal; par—parietal; occ—occipital; nc—non-cortical; bs—brain stem; CeB—cerebellum) and ordered anterior-to-posterior. The color map of each region is lobe- and ROI-specific. The set of five rings (from the outside inward) reflects volumetric and morphometric measures. For non-cortical regions, only average regional volume is shown. Links represent the computed degrees of connectivity between segmented brain regions. In the top row, links represent connections that have been affected by primary TBI. In the bottom row, links represent connections that have suffered an appreciable degree of atrophy six months after injury.

from appreciable atrophy between acute and chronic time points. Such representations may be of interest to clinicians and to other medical professionals to gain insight on the effect of TBI upon a patient's clinical picture as well as to examine atrophy trajectories. Additionally, connectogram display of atrophy patterns allows one to identify studies from the current literature that have possible relevance to improving and tailoring patient rehabilitation protocols. Such studies describe cognitively demanding exercises that involve stimulus–response selection in the face of competing streams of information, including divided-attention tasks, verbal- and motor-response selection tasks that challenge faculties commonly affected by TBI.

### 3.3. Network-theoretic methods

Much of the promise that diffusion imaging techniques hold for the purpose of TBI outcome prediction stems from the latter's ability to investigate changes in brain network topology. Motor and cognitive functions such as attention, for instance, are frequently affected by TBI in ways which are difficult to quantify based on volumetric and morphometric measures alone. Instead, because these functions are dependent upon the integration and segregation properties of large-scale brain networks, the study of TBI and the formulation of treatments for this condition should incorporate knowledge of how

these networks are impaired by trauma (Sharp and Ham, 2011). Currently, DTI- and MRI-based diagnosis and assessment of TBI is often primarily qualitative and performed 'by eye' due to the unavailability of clinical tools for studying brain network properties and for elucidating changes to the structural connectivity of the brain (Kuceyeski et al., 2011). Thus, although there is considerable interest in how lesion location and size influence disability type and severity via alterations to WM connectivity patterns, the quantitative study of this relationship is in its infancy and requires further effort.

The understanding that brain network topology and dynamics modulate a vast array of brain functions that are affected by disease has prompted an increasing interest in the theoretical aspects of network analysis across the entire spectrum of neuroscience research (Dimitriadis et al., 2010). In TBI, there is growing demand for time-dependent network analysis methods that are able to capture and quantify the dynamic changes that brain connections undertake acutely as a result of primary TBI and sub-acutely in response to treatment and recovery. Thus, whereas brain network topologies were previously explored using static graphs, advances in the field have led to the development of methodologies that account for the continuous formation and dissolution of structural and functional links over multiple time scales. Dimitriadis et al. (2010), for example, proposed the concept of time-dependent network analysis based on weighted

graphs using metrics reflecting network segregation (clustering coefficient, local efficiency) and integration (characteristic path length). Using these network metrics in TBI research makes sense because previous studies have found that significant differences in these measures exist when comparing healthy adults to schizophrenics (Zalesky et al., 2011), AD patients (Lo et al., 2010) and normal aging (Wen et al., 2011). For these reasons, the use of network theory to explore pathology is particularly appealing, especially because this could reveal novel biomarkers of TBI outcome.

Research into how brain connectivity is affected by trauma has spurred renewed interest into particular aspects of network theory, such as the development and application of theoretical concepts that can address and model network properties and phenomena that occur in TBI, including cortical reorganization and resilience to injury. Because structure entails function, a structural description of brain connectivity will likely help to understand cortical function and to provide insight into brain network robustness and recovery from damage (Kaiser et al., 2007). The study of network properties such as clustering and hierarchical organization is useful for determining how brain rewiring can occur as a result of trauma, and which regions of the brain are most sensitive to injury.

Whereas appreciable WM loss can sometimes be compensated for by large-scale rewiring, focal damage to highly specialized areas (e.g. auditory cortex or language areas) can lead to significant decline in day-to-day functioning. Kaiser et al. (2007) and the references therein used theoretical network models to conclude that the type of injuries that are likely to result in appreciable deficits is that involves highly-connected hub nodes and bottleneck connections. A study by Varier et al. (2011) used a network model to reproduce known findings according to which (1) lesion effects to brain networks are greater for larger and multifocal lesions and (2) early lesions cause qualitative changes in system behavior that emerge after a delay during which effects are latent. Kuceyeski et al. (2011) used structural and diffusion MRI from 14 healthy controls to create spatially unbiased WM 'connectivity importance' maps that quantify the amount of brain network disruption that would occur if any particular brain region was lesioned. The authors then validated the maps by investigating the correlations of the importance of maps' predicted cognitive deficits in a group of 15 TBI patients with their cognitive test scores of memory and attention.

### 3.4. Functional connectomics

Although structural neuroimaging can reveal a wealth of relevant information which can be critical to the process of TBI clinical care and rehabilitation, the fact remains that next-generation methods for the study of this condition will require a synthesis of both neuro-anatomical (CT, MRI, DTI) as well as functional imaging methods such as fMRI. Thus, although the fMRI literature on TBI has been thoroughly reviewed elsewhere (Belanger et al., 2007; Hillary et al., 2002), it is nevertheless useful to indicate here how this technique can be useful for the purpose of investigating connectomic changes associated with brain injury.

A potential impediment associated with the application of fMRI to the study of TBI is the necessity to examine the effects of collecting or loose blood, including subarachnoid hemorrhage and subdural hematomas, as well as that of factors which may alter hemodynamic responses, including increased intracranial pressure (Hillary et al., 2002). Despite such difficulties associated with the quantification and interpretation of blood oxygen-level dependent (BOLD) signals, fMRI is likely to become increasingly beneficial for the purpose of illuminating how the brain overcomes the effects of injury by means of developing compensatory neural networks (NIH, 1998). For example, one study which examined brain activations while TBI patients performed a working memory task found that TBI patients displayed cerebral activation patterns which were more regionally dispersed and more lateralized to the right hemisphere (Christodoulou et al.,

2001). Similarly, a TBI case study (Scheibel et al., 2003) found increased frontal activation under a 2-back relative to a 1-back condition of working memory, with more extensive activation in two TBI subjects compared to controls. To measure improvements in cognitive ability following rehabilitation, Laatsch and Krisky (2006) used fMRI to investigate task performance in the context of a cognitive rehabilitation model and concluded that individuals with severe TBI can demonstrate improvements in neuropsychological testing even many years after injury. Another useful study by Karunanayaka et al. investigated covert verb generation in a pediatric TBI group and found significant differences in BOLD signal activation in peri-sylvian language areas between the TBI group and a control group, as well as significant associations between BOLD signal activation and performance on language-specific neuropsychological tests (Karunanayaka et al., 2007). Finally, an important study by Monti et al. (2010) used fMRI to show that a small proportion of patients in a vegetative or minimally conscious state have brain activation reflecting some awareness and cognition. All of these studies have indicated the usefulness of fMRI for investigating neuronal network reorganization after injury and, although the application of this technique to the study of TBI is still in its infancy, the findings listed above do indicate the potential utility of fMRI for the purpose of studying how the functional connectome changes with injury.

In addition to working memory and language, attention can also be highlighted as an aspect of brain function whose study is critical for understanding the effects of TBI. For example, Kramer et al. (2008) found that pediatric TBI patients exhibited attention task-related activations of frontal and parietal areas which were significantly greater than in healthy controls. Interestingly, the authors suggested that such hyper-activation of attention networks in TBI contrasted with the hypo-activation of attention networks which has been reported for attention-deficit/hyperactivity disorder. Interestingly, whereas Kramer et al. found over-activation of attention-related networks, Sanchez-Carrion et al. (2008) found that TBI patients had a hypo-activation of frontal lobe networks in several n-back working memory tasks, which indicates that the effects of TBI upon cognition likely consist of both hyper- and hypo-activation in response to exogenous stimuli, depending upon which brain function is being activated as well as upon the nature of the functional and structural networks involved.

### 3.5. Caveats of connectomic neuroimaging

There are a number of potential caveats regarding the use of DTI neuroimaging in TBI research. Firstly, movement in the MR scanner can be an important limitation because TBI patients are often agitated or confused in the acute phase of TBI. This can interfere with image acquisition and with the investigation of symptoms (Metting et al., 2007), and can also result in systematic errors related to connectivity calculations (Van Dijk et al., 2012). For this reason, recently introduced methods which address this limitation (such as PROspective MOTion Correction, PROMO, Brown et al., 2010) are likely to find wide implementation in the TBI neuroimaging field, and the application of both existing and novel motion correction algorithms may also greatly benefit the field of TBI neuroimaging in general. Another disadvantage of DTI data processing is that tractography remains a suboptimal analysis method, particularly when it comes to accounting for partial volume effects and crossing fibers. One drawback of probabilistic tractography is that this method assigns higher probabilities to shorter fibers, which can cause WM located close to GM to have a comparatively large number of tracts with high probability (Kuceyeski et al., 2011). Nevertheless, one study by Vaessen et al. (2010) showed that common graph-theoretical measures are more reproducible across subjects and scanning protocols even when structural connectivity measures are not as reproducible by comparison. In addition, recent advances using DSI indicate that this latter method

can effectively address the limitation of WM fiber crossings (Wedeen et al., 2008).

The investigative efforts described above as well as other studies of how TBI affects brain structure and function highlight the value of connectomic studies for the purpose of establishing robust biomarkers of TBI outcome. Because diffusion imaging techniques combined with tractography yield a very large number of connectogram descriptive variables, the potential of such studies to identify factors that are prognostic of TBI outcome is appreciable. Consequently, it is reasonable to expect that the near future will witness a vigorous proliferation of studies whose goal will be to investigate TBI connectivity in general and DAI in particular using the tools of diffusion imaging. At the same time, improvement in automatic segmentation methods for TBI is likely to motivate researchers to undertake studies of TBI connectivity based on sample sizes that are much larger than today, with corresponding increases in statistical power and significance despite the highly heterogeneous nature of TBI.

#### 4. Statistical models for TBI outcome prediction using structural neuroimaging

##### 4.1. Significance of multivariate models

Of great value to both clinicians and to the families of TBI patients would be the ability reliably to predict the recovery of consciousness as well as the evolution of cognitive and behavioral abilities in the long term. Such ability would dramatically change the way in which treatment and rehabilitation strategies are formulated, and may significantly reduce the financial burden of TBI upon the healthcare system. Furthermore, reliable outcome-predictive biomarkers could allow medical staff to more efficiently proportionate the level of care and to inform families on rehabilitation goals (Tollard et al., 2009). The importance of TBI predictive modeling is also highlighted by the fact that assessing the relative merits of various uni- and multimodal imaging techniques and derived biomarkers should take into account the extent to which increased sensitivity and specificity can alter clinical decision making (Carlos et al., 2003; Huseareau et al., 2009; Provenzale, 2010).

The heterogeneity of TBI is among the primary causes of the daunting complexity associated with the task of prognostic case evaluation. Because this condition frequently involves diffuse changes to brain structure which are difficult to quantify macroscopically, studies that have attempted to identify consistent patterns of injury that lead to a specific outcome have been fraught with intimidating difficulties. For these reasons, intra-individual—i.e. patient-tailored—studies whereby neuroimaging findings are correlated against outcome appear to constitute an ideal paradigm for future TBI research. A review of existing literature points out that a major obstacle in evaluating TBI outcome is the current lack of quantitative, consistent definitions of injury severity (van der Naalt, 2001; van der Naalt et al., 1999). Although conventional CT and MRI have become invaluable techniques for TBI critical care and treatment, most clinical decisions that involve these two modalities are based on qualitative—rather than quantitative—analyses of imaging findings (Tollard et al., 2009). This is undoubtedly suboptimal for the purpose of outcome prediction, as illustrated for instance in a study by Lee et al. (2008), where qualitative blinded assessments of CT and MR scans by human reviewers failed to identify neuroimaging markers that could reliably predict clinical outcome. Nevertheless, in spite of the need for accurate and precise TBI assessment standards, a large number of published studies that make use of quantitative TBI markers appear to confirm the incremental validity of using multimodal neuroimaging techniques compared to the traditional use of standard CT and MRI. Furthermore, an increasing number of studies indicate that TBI-related brain abnormalities obviated via multimodal imaging are partially correlated to clinical outcome variables (see Belanger et al., 2007 and the references therein). Thus, the creation of a site-independent, rigorously precise

and quantitative system for TBI lesion description and evaluation could significantly ease the process of implementing studies that aim to predict TBI outcome.

##### 4.2. The role of CT in outcome prediction

As previously detailed, CT can often be more sensitive than MRI for the detection and quantification of pathology within the first few days after injury (see Maas et al., 2007 and the references therein). Partly for this reason, the ability to predict outcome early after injury based on CT alone is a particularly attractive goal which has attracted appreciable efforts, though with mixed results. An early study by Ichise et al. (1994), for example, found that the antero-posterior ratio as computed from CT images was correlated with six tests of neuropsychological outcome, though the ventricle-to-brain ratio was correlated with only two such tests, despite being known to be a structural index of poor outcome. Englander et al. (2003) studied the association between early CT findings and the need for assistance for ambulation, activities of daily living and for supervision at the time of rehabilitation discharge. These authors found that individuals with midline shifts in excess of 5 mm were more likely to require assistance at discharge, and that 57% of such patients needed home supervision compared to fewer than 40% of patients with midline shifts of less than 5 mm. Patients with bilateral cortical contusions as revealed by CT were found to require more global supervision at rehabilitation discharge but not for ambulation. Importantly, individuals with mass lesions in excess of 15 cm<sup>3</sup> and who had inflammation with structural shifts of over 3 mm were found to have mortality rates greater than 50%. A study by Temkin et al. (2003) proposed the Functional Status Examination (FSE) as an outcome measure based on CT findings and found that it could dichotomize patients well based on recovery from one month to five years after injury. Additionally, this measure was found to have the ability of identifying individuals with functional problems as well as associated neuropsychological and emotional impairments as late as 5 years after injury. Maas et al. examined the predictive value of the Marshall CT classification with alternative CT models by means of logistic regression and recursive partitioning with bootstrapping techniques and found that the former classification indicated reasonable discrimination for the purpose of outcome prediction. The authors also found that discrimination could be improved by including intraventricular and traumatic subarachnoid hemorrhage and by detailed differentiation of mass lesions and basal cisterns, although individual CT predictors were preferable to the Marshall classification for prognostic purposes. An important contribution to the task of outcome prediction using CT is that of Yuh et al. (2008), who developed a computer algorithm for automatic detection of intracranial hemorrhage and mass effect in patients with suspected TBI. The authors found that their method was excellent for detection of these two phenomena in addition to that of midline shift, while maintaining intermediate specificity. In particular, software detection of the presence of at least one non-contrast CT feature of acute TBI demonstrated high sensitivity of 98% and high negative predictive value of 99%.

##### 4.3. Prognostication via diffusion imaging

It has long been known that patients with focal injuries to a specific part of the brain can experience long-term deficits related to cognitive functions that are localized in very different brain areas. Some modeling studies have indicated that cortical areas along the midline, including cingulate cortex, are particularly susceptible to DAI even in the absence of focal injuries to those areas, presumably due to the network topology of inter-hemispheric WM fibers (Alstott et al., 2009). This finding is even more interesting in light of the fact that autopsies of mild TBI patients indicate that the corpus callosum (CC), a region in the immediate vicinity of cingulate cortex, is quite

frequently affected by DAI (Blumbergs et al., 1995). Galloway et al. (2008) attempted to predict TBI outcome using DWI and found that the mean apparent diffusion coefficient (ADC) values associated with healthy-appearing WM could be used as an outcome predictor in pediatric cases of severe TBI. Other findings obtained using diffusion techniques—such as water diffusion abnormalities in contusion cases—have been associated with Glasgow Coma Score (GCS) values and with Rankin scores at patient discharge (Huisman et al., 2004), while reduced fractional anisotropy (FA) in the splenium has been correlated with cognitive dysfunction over one year after injury (Nakayama et al., 2006). In a related study, Wang et al. (2011) studied a cohort of 28 patients with mild to severe TBI to conclude that DTI tractography is a valuable tool for identifying longitudinal structural connectivity changes and for predicting patients' long term outcome. These authors found that, in agreement with the diverse outcomes of their study cohort, WM changes in patients were heterogeneous, ranging from improvements to deteriorations in structural connectivity. Another study by Bazarian et al. (2007) used DTI to detect clinically important axonal damage in cerebral WM within 72 h after injury using ROI analysis of FA values. The authors found that, compared to control subjects, mild TBI patients had WM voxel DTI trace values that were significantly lower in the left anterior internal capsule as well as maximum ROI-specific median FA values which were significantly higher in the posterior CC. These FA values were found to be correlated with 72-h post-concussive symptom (PCS) score and with neurobehavioral tests of visual motor speed as well as impulse control.

The usefulness of DTI to predict injury severity has received a large amount of scrutiny in the TBI community. Benson et al. (2007), for example, hypothesized that a global WM analysis of DTI data would be sensitive to DAI across a spectrum of TBI severity and injury-to-scan interval. The authors found that FA empirical distribution parameters (mean, standard deviation, kurtosis, skewness) were globally decreased in mild TBI compared to healthy controls, and furthermore that the statistical properties of FA distributions were correlated with injury severity as indexed by GCS and post-traumatic amnesia. Increased diffusion in the short DTI axis dimension, likely reflecting dysmyelination and axonal swelling, was found to account for most decreases in FA. The conclusions of the study were that (1) FA is globally decreased in mild TBI, possibly reflecting widespread effects of injuries, and that (2) FA changes seem to be correlated with injury severity, suggesting a potential role of DTI in the early diagnosis and prognosis of TBI. Another important study by Kraus et al. (2007) indicated that WM load was negatively correlated with performance in all cognitive domains and that DTI provides an objective means for determining the relationship of cognitive deficits to TBI, even in cases where the injury was sustained years prior to the evaluation. Similar findings were obtained by Wozniak et al. (2007), who showed that children with TBI showed slower processing speed, working memory and executive deficits, as well as greater behavioral dysregulation, and that supracallosal FA was correlated with motor speed and behavioral ratings in such patients. Ewing-Cobbs additionally found disruptions in callosal microstructure, and significant correlations between radial diffusion and/or FA in the isthmus, on the one hand, and working memory as well as motor and academic skills, on the other hand (Ewing-Cobbs et al., 2008). Another study involving a pediatric population found that DTI was superior to conventional MR in detecting WM injury at 3 months after injury in moderate to severe TBI. DTI measures were also found to be related to global outcome, cognitive processing speed, and speed of resolving interference in children with moderate to severe TBI. By contrast, in adults, Bendlin et al. found that neuropsychological function improved throughout the first year post-injury despite TBI affecting virtually all major fiber bundles in the brain including the CC, cingulum and uncinate fasciculus (Bendlin et al., 2008). Niogi et al. (2008) found that, in postconcussive syndrome, WM injury is correlated with impaired cognitive reaction time and that the most frequently affected WM

structures in the adult population investigated were the anterior corona radiata, uncinate fasciculus, genu of the CC, inferior longitudinal fasciculus, and cingulum bundle. These findings were largely replicated by Rutgers et al. (2008), who additionally found that supratentorial projection fiber bundles and fronto-temporo-occipital association bundles were also frequently affected in adult TBI patients. In conclusion, given that cognitive recovery from TBI correlates with the restoration of WM integrity, DTI as a neuroimaging technique is uniquely positioned to predict recovery in TBI patients (Belanger et al., 2007; Terayama et al., 1993) and should be used more widely in studies that aim to identify markers of TBI outcome.

A significant recent study which combines DTI with fMRI is that of Bonnelle et al. (2011), who showed that sustained attention impairments in TBI patients are associated with an increase in default mode network activation, particularly in the precuneus and posterior cingulate cortex. Additionally, these authors found that the functional connectivity of the former structure with the rest of the network at the beginning of an attention task was predictive of which patients would go on to exhibit impairments. This predictive information was present before the patients exhibited any behavioral evidence of sustained attention impairment, and the relationship was also identified in a subgroup of patients without focal brain damage. In another important study, Mayer et al. (2011) investigated whether functional connectivity inferred using DTI and resting-state fMRI could provide objective markers of injury as well as predict cognitive, emotional and somatic deficits in mild TBI patients semi-acutely and in late recovery. These authors found that their patient cohort demonstrated decreased functional connectivity within the default mode network and increased connectivity between the latter and lateral prefrontal cortex, with functional connectivity measures having high sensitivity and specificity for patient classification and deficit prediction.

#### 4.4. Multivariate models for identifying biomarkers of outcome

Neuroimaging methodologies allow researchers to gather very large number of descriptive statistics about the brain, either volumetric, morphometric, or connectomic. Nevertheless, the task of identifying biomarkers of TBI outcome from among such statistics is daunting because these predictors must have consistent prognostic value across the bulk of the TBI population in order to be useful. In this context, a neuroimaging biomarker is understood to be a neuroimaging-based progression indicator which describes physiological processes that change with TBI evolution (Brooks et al., 2003). Identifying such outcome metrics may require the collection of structural parameters from large samples of TBI cases. As discussed in previous sections, this is particularly challenging in the absence of robust algorithms for automatic TBI image segmentation and tractography. Currently, it can be difficult to perform advanced neuroimaging studies of TBI samples to identify outcome predictors with small to moderate size. Thus, the task of identifying outcome biomarkers that are both robust and sensitive when used separately from each other can be considerably more difficult when sample size is small. Consequently, it appears much more likely that a linear combination of (a possibly large number of) biomarkers may be required instead in order to achieve acceptable sensitivity and specificity with regard to outcome. In this context, it is not surprising that multivariate statistical models appear to offer the mathematical framework of choice for the task of finding those combinations of structural metrics that can best predict clinical TBI case evolution.

Multivariate statistical models have already had some success in identifying structural measures that correlate well with TBI outcome. For instance, Quattrocchi et al. (1991) used logistic regression to analyze CT scans and concluded that 34% of cases with intracranial hemorrhage revealed by CT scans acquired early after trauma were associated with poor outcome, compared to 61% of cases which additionally exhibited midline shifts and to 88% of cases where the midline shift

was 'out of proportion' to the intracranial hemorrhage. By contrast, a logistic regression analysis undertaken to determine the incidence of traumatic subarachnoid hemorrhage in TBI patients as detected by CT (Mattoli et al., 2003) showed that this condition and its grading alone do not assume significance in predicting unfavorable outcome. Galloway et al. (2008) used both linear and logistic regression analyses to determine the ability of individual or different combinations of clinical and neuroimaging variables to optimally predict outcome. Logistic regression is a type of regression analysis that can be used to predict the outcome of a binary dependent variable (e.g. poor vs. good outcome) based on one to several predictor variables. This method of statistical analysis was also implemented by Andrews et al. (2002), who used it in addition to decision tree analysis to predict recovery in 124 TBI patients by using admission variables and physiological data. Logistic regression was used in this latter study to determine the relative influence of age, admission GCS, injury severity score (ISS) and other factors. Tollard et al. (2009) used another multivariate technique called linear discriminant analysis (LDA) to determine whether the combined use of DTI and MRS could reliably predict clinical outcome in 43 patients at one year after severe TBI. LDA is a multivariate statistical analysis method closely related to analysis of variance (ANOVA) and is frequently used in pattern recognition and machine learning to identify a linear combination of features which optimally separates a set of object into classes. In TBI, for example, LDA might allow a researcher to group patients into distinct outcome groups by means of a linear classifier that includes various neuroimaging measures. Tollard et al. found that LDA of DTI/MRS measures could separate without overlap patients with unfavorable outcome from those with favorable outcome and from controls with up to 86% sensitivity and 97% specificity. Maximally discriminant measures identified were supra- and infratentorial FA, as well as the NAA to creatine ratio in the pons, thalamus and insula.

An important recent study with promising results with respect to TBI outcome prediction is that of Strangman et al. (2010). These authors investigated the relationship between changes in brain structure prompted by TBI and changes in neuropsychological ability following rehabilitation. Specifically, MRI brain morphometry methods and automatic segmentation tools were used to quantify longitudinal changes in cortical region volumes and to determine whether and which regions of the brain can be used to reliably predict memory rehabilitation outcome. Strangman et al. recruited 50 TBI subjects of all severities, who then participated in a memory rehabilitation program emphasizing internal memory strategies. Primary outcome measures were collected longitudinally, both immediately and one month after therapy, and a multivariate statistical analysis was implemented to identify biomarkers that were predictive of rehabilitation. The authors thus found several brain regions that provided significant predictions of rehabilitation outcome, including the volume of the hippocampus, thalamus, lateral prefrontal cortex and cingulate cortex. They concluded that morphometric brain measures may be of appreciable predictive value with respect to cognitive rehabilitation. These and other studies indicate that brain morphometry and structural analysis are of considerable interest, and that more efforts should therefore be dedicated to the task of applying multivariate statistical methods to neuroimaging data in order to identify robust outcome predictors.

One advantage of DTI is that this modality can produce a large array of metrics which can be longitudinally correlated with measures of long-term functional outcome. Sidaros et al. (2008) found that acute-stage DTI parameters for patients with unfavorable outcome tend to deviate more from control values than for patients with favorable outcome. Similarly, a significant reduction in ADC values associated with peripheral WM was found by Galloway et al. (2008) in pediatric subjects with unfavorable outcome. Although DTI has been recognized as a sensitive biomarker of TBI WM injuries with potential for prognostic assessment, few longitudinal studies have followed DTI changes over time. One notable exception is the study of Sidaros et al. cited above, who followed 30 adult TBI patients over an entire year to identify

imaging biomarkers that were predictive of outcome. Acutely, the authors found reduced FA in all TBI patients compared to controls, presumably due to decreased diffusivity parallel—and increased diffusivity perpendicular—to axonal fiber direction. FA in the cerebral peduncle at the acute scan was found to correlate with 1-year Glasgow Outcome Score (GOS), and FA in the internal capsule was found to increase over time in patients with favorable outcome.

Kinnunen et al. (2011) implemented a method called tract-based spatial statistics (TBSS) that had been proposed by Smith et al. (2006) to explore whether the location of WM abnormalities can predict cognitive impairment. TBSS is a novel voxel-based method for investigating WM structure which allows complex patterns of WM damage to be isolated and quantified with respect to cognitive impairment. Upon co-registration and alignment of WM tracts across subjects, this technique implements statistical calculations that allow for comprehensive analyses of tract structure in a way that is robust to injury-related atrophy effects (Kinnunen et al., 2011). The group found that changes in fornix structure as revealed by DTI could predict associative memory performance, in that individuals with higher FA in the WM of the fornix had better memory performance. Their study highlights the complex and insufficiently explored relationship between WM damage and cognitive impairment, as well as the large number of quantitative parameters provided by DTI that can be investigated as potential biomarkers of cognitive recovery or decline. Sharp et al. (2011) used a multivariate analysis of resting-state fMRI to conclude that TBI patients exhibited increased functional connectivity within the default mode network at rest compared to controls. In addition, patients with the highest functional connectivity had the least cognitive impairment, and functional connectivity at rest also predicted brain activation patterns during an attention task. The authors concluded that their results supported a direct relationship between WM organization within the brain's structural core, functional connectivity in the default mode network and cognitive function after brain injury.

Of considerable interest to clinicians is the ability to quantify the longitudinal evolution of various brain regions in response to TBI recovery and rehabilitation, and some progress has already been achieved in this direction. For example, the tools proposed by Irimia et al. (2011) allow cross-correlation of multimodal metrics from structural imaging (e.g., structural volume, atrophy measurements) with clinical outcome variables and with other potential factors predictive of recovery. The workflows described by these authors are also suitable for TBI clinical practice and for patient monitoring, particularly with regard to assessing damage extent and measuring neuroanatomical change over time. With knowledge of general location, extent, and degree of change, metrics obtained using this type of software can be associated with clinical measures and subsequently used to suggest viable treatment options.

Recent neuroimaging studies reiterate the fact that the current trend in TBI outcome prediction is to use multivariate statistical classification methods in order to identify groups of neuroimaging variables that can optimally cluster patients into outcome groups. Thus, Tollard et al. identified their outcome biomarkers by implementing an LDA where the robustness of outcome classification was tested using a bootstrap procedure. These authors took advantage of an important feature of LDA, which is to dichotomize the TBI patient sample into a test data set and another training data set. This allows one to build a discriminant function of neuroimaging measures with putative predictive value and to assign test cases to exactly one TBI outcome category (e.g. healthy control, favorable outcome, or unfavorable outcome) using a maximum likelihood criterion according to a strong classification procedure. Similarly to Tollard et al., Strangman and colleagues also used a multivariate prediction model to identify biomarkers of TBI outcome. In their approach, however, linear regression models were used to predict functional outcome based on anatomical measures. On the other hand, Kuceyeski et al. (2011) used principal

component analysis (PCA) to create a combined cognitive score that has maximal variance over healthy and TBI-affected populations and which can presumably describe all cognitive functions of interest. Similarly, Yuh et al. (2012) used PCA to demonstrate the interdependence of certain outcome-predictive variables extracted from CT data. Importantly, they demonstrated that midline shift, cistern effacement, subdural hematoma volume and GCS score were related to one another, and concluded that the importance of these measures may be related to their status as surrogate measures of a more fundamental underlying clinical measure, e.g. the severity of the intracranial mass effect.

Thus, recent studies appear to confirm that TBI outcome prediction models should not assume that outcome biomarkers consist of a single (or group of very few) structural measures. Instead, it seems more likely that a linear combination of measures should be used instead as the underlying modeling assumption, and that the outcome being predicted should not be a single clinical or neuropsychological test score, but rather of combination thereof. This type of modeling allows for greater flexibility in the choice of predictive parameters while simultaneously keeping to a minimum the assumptions being made about the statistical problem under investigation.

## 5. Summary and conclusion

Brain region specificity is thought to play an important role in TBI outcome type and severity, although these mechanisms of causation have not been adequately elucidated. Consequently, investigating the timeline of TBI abnormalities and subsequent recovery, as well as assessing how such abnormalities contribute to long-term cognitive and behavioral symptoms, are important basic research questions related to TBI. In humans, the use of CT/MRI alone has been found insufficient for the purpose of addressing these questions, partly because the sensitivity and specificity of these techniques are dissatisfactory when used by themselves. This realization has provided appreciable impetus to the paradigm of multimodal imaging, whereby a variety of complementary MR sequences (FLAIR, SWI, etc.), diffusion imaging techniques (HARDI, DTI, DSI) and functional imaging (fMRI) have gained popularity with both clinicians and TBI researchers.

One particular advantage of multimodal TBI imaging is that combining volumetric/morphometric measures (as extracted from standard CT/MR) with structural and functional connectivity measures (provided by DTI and fMRI, respectively) allows one to systematically search for neuroimaging biomarkers that can predict outcome. On the one hand, structural neuroimaging of TBI via MR/CT can help researchers to determine how the gross anatomy of the brain changes in response to injury and treatment. On the other hand, these modalities allow one to quantify atrophy and regeneration, with potential for the development of patient-tailored rehabilitation protocols. Similarly, DTI allows one to infer the network properties of the TBI brain and to study how DAI can affect cortical functions that are localized far from the injury site. Finally, fMRI allows one to study the roles of nodes and edges in such cortical networks in the context of how TBI modulates functional responses to trauma.

Whenever large sample sizes are required for TBI neuroimaging research, the availability of software tools for automatic segmentation, morphometry and tractography is paramount. The biggest challenge in making such tools available and reliable is the presence of anatomical outliers in TBI data, which makes the application of conventional segmentation metrics highly problematic. The reliability of morphometric methods in TBI is also questionable in many cases, particularly when the WM/GM boundary cannot be identified due to changes in image intensity caused by pathology. It is particularly challenging to quantify longitudinal anatomical changes that occur with recovery, although recent progress via geometric metamorphosis, personalized atlas construction and connectogram modeling has been encouraging.

In spite of the difficulties and pitfalls of TBI neuroimaging summarized above, an encouraging amount of progress has been recorded through the use of neuroimaging to predict clinical outcome. In particular, multivariate statistical models have been applied with some success to identify prognostic measures that are robust over TBI samples of moderate size. It can be expected that future improvement in such models, coupled with advances in automated TBI image processing methods, may lead to the identification of volumetric/morphometric/connectomic structural variables which can predict motor and cognitive outcome in detail. Additionally, such improvements may help clinicians to generate personalized TBI profiles which can be tailored to address the individual needs of each brain injury patient.

## Acknowledgments

This work was supported by (1) the National Alliance for Medical Image Computing (NA-MIC) ([www.na-mic.org](http://www.na-mic.org)), under the National Institutes of Health Roadmap Initiative (2U54EB005149 to R. K., sub-award to J. D. V. H.) and by (2) the National Institute of Neurological Disorders and Stroke (P01NS058489 to P. M. V. and D. A. H.). The authors would also like to thank S.-Y. Matthew Goh, Carinna M. Torgerson and the dedicated staff in the Laboratory of Neuro Imaging at the University of California, Los Angeles for their support and assistance.

## References

- Alstott, J., Breakspear, M., Hagmann, P., Cammoun, L., Sporns, O., 2009. Modeling the impact of lesions in the human brain. *PLoS Computational Biology* 5, e1000408.
- Andrews, P.J., Sleeman, D.H., Statham, P.F., McQuatt, A., Corruble, V., Jones, P.A., Howells, T.P., Macmillan, C.S., 2002. Predicting recovery in patients suffering from traumatic brain injury by using admission variables and physiological data: a comparison between decision tree analysis and logistic regression. *Journal of Neurosurgery* 97, 326–336.
- Asikainen, I., Kaste, M., Sarna, S., 1999. Early and late posttraumatic seizures in traumatic brain injury rehabilitation patients: brain injury factors causing late seizures and influence of seizures on long-term outcome. *Epilepsia* 40, 584–589.
- Avants, B., Duda, J.T., Kim, J., Zhang, H., Pluta, J., Gee, J.C., Whyte, J., 2008. Multivariate analysis of structural and diffusion imaging in traumatic brain injury. *Academic Radiology* 15, 1360–1375.
- Bazarian, J.J., Zhong, J., Blyth, B., Zhu, T., Kavcic, V., Peterson, D., 2007. Diffusion tensor imaging detects clinically important axonal damage after mild traumatic brain injury: a pilot study. *Journal of Neurotrauma* 24, 1447–1459.
- Beaulieu, C., Does, M.D., Snyder, R.E., Allen, P.S., 1996. Changes in water diffusion due to Wallerian degeneration in peripheral nerve. *Magnetic Resonance in Medicine* 36, 627–631.
- Belanger, H.G., Vanderploeg, R.D., Curtiss, G., Warden, D.L., 2007. Recent neuroimaging techniques in mild traumatic brain injury. *The Journal of Neuropsychiatry and Clinical Neurosciences* 19, 5–20.
- Bendlin, B.B., Ries, M.L., Lazar, M., Alexander, A.L., Dempsey, R.J., Rowley, H.A., Sherman, J.E., Johnson, S.C., 2008. Longitudinal changes in patients with traumatic brain injury assessed with diffusion-tensor and volumetric imaging. *NeuroImage* 42, 503–514.
- Benson, R.R., Meda, S.A., Vasudevan, S., Kou, Z., Govindarajan, K.A., Hanks, R.A., Millis, S.R., Makki, M., Latif, Z., Coplin, W., Meythaler, J., Haacke, E.M., 2007. Global white matter analysis of diffusion tensor images is predictive of injury severity in traumatic brain injury. *Journal of Neurotrauma* 24, 446–459.
- Bigler, E.D., 2001. Quantitative magnetic resonance imaging in traumatic brain injury. *The Journal of Head Trauma Rehabilitation* 16, 117–134.
- Binder, L.M., 1997. A review of mild head trauma. Part II: clinical implications. *Journal of Clinical and Experimental Neuropsychology* 19, 432–457.
- Binder, L.M., Rohling, M.L., Larrabee, G.J., 1997. A review of mild head trauma. Part I: meta-analytic review of neuropsychological studies. *Journal of Clinical and Experimental Neuropsychology* 19, 421–431.
- Blumbers, P.C., Scott, G., Manavis, J., Wainwright, H., Simpson, D.A., McLean, A.J., 1995. Topography of axonal injury as defined by amyloid precursor protein and the sector scoring method in mild and severe closed head injury. *Journal of Neurotrauma* 12, 565–572.
- Bonnelle, V., Leech, R., Kinnunen, K.M., Ham, T.E., Beckmann, C.F., De Boissezon, X., Greenwood, R.J., Sharp, D.J., 2011. Default mode network connectivity predicts sustained attention deficits after traumatic brain injury. *Journal of Neuroscience* 31, 13442–13451.
- Brett, M., Leff, A.P., Rorden, C., Ashburner, J., 2001. Spatial normalization of brain images with focal lesions using cost function masking. *NeuroImage* 14, 486–500.
- Brooks, D.J., Frey, K.A., Marek, K.L., Oakes, D., Paty, D., Prentice, R., Shults, C.W., Stoessl, A.J., 2003. Assessment of neuroimaging techniques as biomarkers of the progression of Parkinson's disease. *Experimental Neurology* 184 (Suppl. 1), S68–S79.
- Brown, T.T., Kuperman, J.M., Erhart, M., White, N.S., Roddey, J.C., Shankaranarayanan, A., Han, E.T., Rettmann, D., Dale, A.M., 2010. Prospective motion correction of high-resolution magnetic resonance imaging data in children. *NeuroImage* 53, 139–145.

- Carlos, R.C., Axelrod, D.A., Ellis, J.H., Abrahamse, P.H., Fendrick, A.M., 2003. Incorporating patient-centered outcomes in the analysis of cost-effectiveness: imaging strategies for renovascular hypertension. *AJR American Journal of Roentgenology* 181, 1653–1661.
- Chi, J.H., Knudson, M.M., Vassar, M.J., McCarthy, M.C., Shapiro, M.B., Mallet, S., Holcroft, J.J., Moncrief, H., Noble, J., Wisner, D., Kaups, K.L., Bennick, L.D., Manley, G.T., 2006. Prehospital hypoxia affects outcome in patients with traumatic brain injury: a prospective multicenter study. *The Journal of Trauma* 61, 1134–1141.
- Christodoulou, C., DeLuca, J., Ricker, J.H., Madigan, N.K., Bly, B.M., Lange, G., Kalnin, A.J., Liu, W.C., Steffener, J., Diamond, B.J., Ni, A.C., 2001. Functional magnetic resonance imaging of working memory impairment after traumatic brain injury. *Journal of Neurology, Neurosurgery & Psychiatry* 71, 161–168.
- Clark, M.C., Hall, L.O., Goldfog, D.B., Velthuisen, R., Murtagh, F.R., Silbiger, M.S., 1998. Automatic tumor segmentation using knowledge-based techniques. *IEEE Transactions on Medical Imaging* 17, 187–188.
- Corrigan, J.D., Harrison-Felix, C., Bogner, J., Dijkers, M., Terrill, M.S., Whiteneck, G., 2003. Systematic bias in traumatic brain injury outcome studies because of loss to follow-up. *Archives of Physical Medicine and Rehabilitation* 84, 153–160.
- Dale, A.M., Fischl, B., Sereno, M.I., 1999. Cortical surface-based analysis. I. Segmentation and surface reconstruction. *NeuroImage* 9, 179–194.
- Desikan, R.S., Segonne, F., Fischl, B., Quinn, B.T., Dickerson, B.C., Blacker, D., Buckner, R.L., Dale, A.M., Maguire, R.P., Hyman, B.T., Albert, M.S., Killiany, R.J., 2006. An automated labeling system for subdividing the human cerebral cortex on MRI scans into gyral based regions of interest. *NeuroImage* 31, 968–980.
- Destrieux, C., Fischl, B., Dale, A., Halgren, E., 2010. Automatic parcellation of human cortical gyri and sulci using standard anatomical nomenclature. *NeuroImage* 53, 1–15.
- Dimitriadis, S.I., Laskaris, N.A., Tsiarka, V., Vourkas, M., Micheloyannis, S., Fotopoulos, S., 2010. Tracking brain dynamics via time-dependent network analysis. *Journal of Neuroscience Methods* 193, 145–155.
- Englander, J., Cifu, D.X., Wright, J.M., Black, K., 2003. The association of early computed tomography scan findings and ambulation, self-care, and supervision needs at rehabilitation discharge and at 1 year after traumatic brain injury. *Archives of Physical Medicine and Rehabilitation* 84, 214–220.
- Ewing-Cobbs, L., Prasad, M.R., Swank, P., Kramer, L., Cox Jr., C.S., Fletcher, J.M., Barnes, M., Zhang, X., Hasan, K.M., 2008. Arrested development and disrupted callosal microstructure following pediatric traumatic brain injury: relation to neurobehavioral outcomes. *NeuroImage* 42, 1305–1315.
- Fischl, B., Dale, A.M., 2000. Measuring the thickness of the human cerebral cortex from magnetic resonance images. *Proceedings of the National Academy of Sciences of the United States of America* 97, 11050–11055.
- Fischl, B., Sereno, M.I., Dale, A.M., 1999a. Cortical surface-based analysis. II: inflation, flattening, and a surface-based coordinate system. *NeuroImage* 9, 195–207.
- Fischl, B., Sereno, M.I., Tootell, R.B., Dale, A.M., 1999b. High-resolution intersubject averaging and a coordinate system for the cortical surface. *Human Brain Mapping* 8, 272–284.
- Fischl, B., Liu, A., Dale, A.M., 2001. Automated manifold surgery: constructing geometrically accurate and topologically correct models of the human cerebral cortex. *IEEE Transactions on Medical Imaging* 20, 70–80.
- Fischl, B., Salat, D.H., Busa, E., Albert, M., Dieterich, M., Haselgrove, C., van der Kouwe, A., Killiany, R., Kennedy, D., Klaveness, S., Montillo, A., Makris, N., Rosen, B., Dale, A.M., 2002. Whole brain segmentation: automated labeling of neuroanatomical structures in the human brain. *Neuron* 33, 341–355.
- Fischl, B., van der Kouwe, A., Destrieux, C., Halgren, E., Segonne, F., Salat, D.H., Busa, E., Seidman, L.J., Goldstein, J., Kennedy, D., Caviness, V., Makris, N., Rosen, B., Dale, A.M., 2004. Automatically parcellating the human cerebral cortex. *Cerebral Cortex* 14, 11–22.
- Friston, K., Ashburner, J., Kiebel, S., Nichols, T., Penny, W., 2006. *Statistical Parametric Mapping: The Analysis of Functional Brain Images*. Academic Press.
- Gaetz, M., 2004. The neurophysiology of brain injury. *Clinical Neurophysiology* 115, 4–18.
- Galloway, N.R., Tong, K.A., Ashwal, S., Oyoyo, U., Obenaus, A., 2008. Diffusion-weighted imaging improves outcome prediction in pediatric traumatic brain injury. *Journal of Neurotrauma* 25, 1153–1162.
- Geremia, E., Clatz, O., Menze, B.H., Konukoglu, E., Criminisi, A., Ayache, N., 2011. Spatial decision forests for MS lesion segmentation in multi-channel magnetic resonance images. *NeuroImage* 57, 378–390.
- Hillary, F.G., Steffener, J., Biswal, B.B., Lange, G., DeLuca, J., Ashburner, J., 2002. Functional magnetic resonance imaging technology and traumatic brain injury rehabilitation: guidelines for methodological and conceptual pitfalls. *The Journal of Head Trauma Rehabilitation* 17, 411–430.
- Ho, S., Bullitt, E., Gerig, G., 2002. Level set evolution with region competition: automatic 3-D segmentation of brain tumors. *Proceedings of the 16th International Conference on Pattern Recognition*. August 11–15, 2002. IEEE Computer Society, Quebec City, Canada, pp. 532–535 (ISBN 0-7695-1695-X).
- Hofman, P.A., Stapert, S.Z., van Kroonenburgh, M.J., Jolles, J., de Kruijk, J., Wilmink, J.T., 2001. MR imaging, single-photon emission CT, and neurocognitive performance after mild traumatic brain injury. *AJNR American Journal of Neuroradiology* 22, 441–449.
- Hoge, C., Davatzikos, C., Biros, G., 2008. An image-driven parameter estimation problem for a reaction-diffusion glioma growth model with mass effects. *Journal of Mathematical Biology* 56, 793–825.
- Huisman, T.A., Schwamm, L.H., Schaefer, P.W., Koroshetz, W.J., Shetty-Alva, N., Ozsunar, Y., Wu, O., Sorensen, A.G., 2004. Diffusion tensor imaging as potential biomarker of white matter injury in diffuse axonal injury. *AJNR American Journal of Neuroradiology* 25, 370–376.
- Husereau, D., Morrison, A., Battista, R., Goeree, R., 2009. Health technology assessment: a review of international activity and examples of approaches with computed tomographic colonography. *Journal of the American College of Radiology* 6, 343–352.
- Ichise, M., Chung, D.G., Wang, P., Wortzman, G., Gray, B.G., Franks, W., 1994. Technetium-99m-HMPAO SPECT, CT and MRI in the evaluation of patients with chronic traumatic brain injury: a correlation with neuropsychological performance. *Journal of Nuclear Medicine* 35, 217–226.
- Irimia, A., Chambers, M.C., Alger, J.R., Filippou, M., Prastawa, M.W., Wang, B., Hovda, D.A., Gerig, G., Toga, A.W., Kikinis, R., Vespa, P.M., Van Horn, J.D., 2011. Comparison of acute and chronic traumatic brain injury using semi-automatic multimodal segmentation of MR volumes. *Journal of Neurotrauma* 28, 2287–2306.
- Irimia, A., Chambers, M.C., Torgerson, C.M., Filippou, M., Hovda, D.A., Alger, J.R., Gerig, G., Toga, A.W., Vespa, P.M., Kikinis, R., Van Horn, J.D., 2012a. Patient-tailored connectomics visualization for the assessment of white matter atrophy in traumatic brain injury. *Frontiers in Neurology* 3, 10.
- Irimia, A., Chambers, M.C., Torgerson, C.M., Van Horn, J.D., 2012b. Circular representation of human cortical networks for subject and population-level connectomic visualization. *NeuroImage* 60, 1340–1351.
- Jacobs, B., Beems, T., Stulemeijer, M., van Vugt, A.B., van der Vliet, T.M., Borm, G.F., Vos, P.E., 2010. Outcome prediction in mild traumatic brain injury: age and clinical variables are stronger predictors than CT abnormalities. *Journal of Neurotrauma* 27, 655–668.
- Kaiser, M., Martin, R., Andras, P., Young, M.P., 2007. Simulation of robustness against lesions of cortical networks. *European Journal of Neuroscience* 25, 3185–3192.
- Karunanayaka, P.R., Holland, S.K., Yuan, W., Altaye, M., Jones, B.V., Michaud, L.J., Walz, N.C., Wade, S.L., 2007. Neural substrate differences in language networks and associated language-related behavioral impairments in children with TBI: a preliminary fMRI investigation. *NeuroRehabilitation* 22, 355–369.
- Kinnunen, K.M., Greenwood, R., Powell, J.H., Leech, R., Hawkins, P.C., Bonnelle, V., Patel, M.C., Counsell, S.J., Sharp, D.J., 2011. White matter damage and cognitive impairment after traumatic brain injury. *Brain* 134, 449–463.
- Kou, Z., Wu, Z., Tong, K.A., Holshouser, B., Benson, R.R., Hu, J., Haacke, E.M., 2010. The role of advanced MR imaging findings as biomarkers of traumatic brain injury. *The Journal of Head Trauma Rehabilitation* 25, 267–282.
- Kramer, M.E., Chiu, C.Y., Walz, N.C., Holland, S.K., Yuan, W., Karunanayaka, P., Wade, S.L., 2008. Long-term neural processing of attention following early childhood traumatic brain injury: fMRI and neurobehavioral outcomes. *Journal of International Neuropsychological Society* 14, 424–435.
- Kraus, M.F., Susmaras, T., Caughlin, B.P., Walker, C.J., Sweeney, J.A., Little, D.M., 2007. White matter integrity and cognition in chronic traumatic brain injury: a diffusion tensor imaging study. *Brain* 130, 2508–2519.
- Kuceyeski, A., Maruta, J., Niogi, S.N., Ghajar, J., Raj, A., 2011. The generation and validation of white matter connectivity importance maps. *NeuroImage* 58, 109–121.
- Kuperberg, G.R., Broome, M.R., McGuire, P.K., David, A.S., Eddy, M., Ozawa, F., Goff, D., West, W.C., Williams, S.C., van der Kouwe, A.J., Salat, D.H., Dale, A.M., Fischl, B., 2003. Regionally localized thinning of the cerebral cortex in schizophrenia. *Archives of General Psychiatry* 60, 878–888.
- Laatsch, L., Krisky, C., 2006. Changes in fMRI activation following rehabilitation of reading and visual processing deficits in subjects with traumatic brain injury. *Brain Injury* 20, 1367–1375.
- Lamecker, H., Pennec, X., 2010. Atlas to image-with-tumor registration based on demons and deformation inpainting. *MICCAI Workshop on Computational Imaging Biomarkers for Tumors—From Qualitative to Quantitative (CIBT 2010)*, Beijing, China.
- Lee, B., Newberg, A., 2005. Neuroimaging in traumatic brain imaging. *NeuroRx* 2, 372–383.
- Lee, H., Wintermark, M., Gean, A.D., Ghajar, J., Manley, G.T., Mukherjee, P., 2008. Focal lesions in acute mild traumatic brain injury and neurocognitive outcome: CT versus 3T MRI. *Journal of Neurotrauma* 25, 1049–1056.
- Lehtonen, S., Stringer, A.Y., Millis, S., Boake, C., Englander, J., Hart, T., High, W., Macciocchi, S., Meythaler, J., Novack, T., Whyte, J., 2005. Neuropsychological outcome and community re-integration following traumatic brain injury: the impact of frontal and non-frontal lesions. *Brain Injury* 19, 239–256.
- Liew, B.S., Johari, S.A., Nasser, A.W., Abdullah, J., 2009. Severe traumatic brain injury: outcome in patients with diffuse axonal injury managed conservatively in Hospital Sultanah Aminah, Johor Bahru—an observational study. *The Medical Journal of Malaysia* 64, 280–288.
- Lo, C.Y., Wang, P.N., Chou, K.H., Wang, J., He, Y., Lin, C.P., 2010. Diffusion tensor tractography reveals abnormal topological organization in structural cortical networks in Alzheimer's disease. *Journal of Neuroscience* 30, 16876–16885.
- Maas, A.I., Steyerberg, E.W., Butcher, I., Dammers, R., Lu, J., Marmarou, A., Mushkudiani, N.A., McHugh, G.S., Murray, G.D., 2007. Prognostic value of computerized tomography scan characteristics in traumatic brain injury: results from the IMPACT study. *Journal of Neurotrauma* 24, 303–314.
- Mac Donald, C.L., Dikranian, K., Bayly, P., Holtzman, D., Brody, D., 2007. Diffusion tensor imaging reliably detects experimental traumatic axonal injury and indicates approximate time of injury. *Journal of Neuroscience* 27, 11869–11876.
- Marino, S., Ciurleo, R., Bramanti, P., Federico, A., De Stefano, N., 2011. 1H-MR spectroscopy in traumatic brain injury. *Neurocritical Care* 14, 127–133.
- Mattioli, C., Beretta, L., Gerevini, S., Veglia, F., Citerio, G., Cormio, M., Stocchetti, N., 2003. Traumatic subarachnoid hemorrhage on the computerized tomography scan obtained at admission: a multicenter assessment of the accuracy of diagnosis and the potential impact on patient outcome. *Journal of Neurosurgery* 98, 37–42.
- Mayer, A.R., Mannell, M.V., Ling, J., Gasparovic, C., Yeo, R.A., 2011. Functional connectivity in mild traumatic brain injury. *Human Brain Mapping* 32, 1825–1835.
- McAllister, T.W., Flashman, L.A., McDonald, B.C., Saykin, A.J., 2006. Mechanisms of working memory dysfunction after mild and moderate TBI: evidence from functional MRI and neurogenetics. *Journal of Neurotrauma* 23, 1450–1467.
- Menze, B.H., Van Leemput, K., Lashkari, D., Weber, M.A., Ayache, N., Golland, P., 2010. A generative model for brain tumor segmentation in multi-modal images. *Medical Image Computing and Computer-Assisted Intervention* 13, 151–159.

- Metting, Z., Rodiger, L.A., De Keyser, J., van der Naalt, J., 2007. Structural and functional neuroimaging in mild-to-moderate head injury. *Lancet Neurology* 6, 699–710.
- Monti, M.M., Vanhauwenhuyse, A., Coleman, M.R., Boly, M., Pickard, J.D., Tshibanda, L., Owen, A.M., Laureys, S., 2010. Willful modulation of brain activity in disorders of consciousness. *The New England Journal of Medicine* 362, 579–589.
- Nakayama, N., Okumura, A., Shinoda, J., Yasokawa, Y.T., Miwa, K., Yoshimura, S.I., Iwama, T., 2006. Evidence for white matter disruption in traumatic brain injury without macroscopic lesions. *Journal of Neurology, Neurosurgery & Psychiatry* 77, 850–855.
- Niethammer, M., Hart, G.L., Pace, D.F., Vespa, P.M., Irimia, A., Van Horn, J.D., Aylward, S.R., 2011. Geometric metamorphosis. *Medical Image Computing and Computer-Assisted Intervention* 14, 639–646.
- NIH, 1998. Rehabilitation of persons with traumatic brain injury. NIH Consensus Statement 16, 1–41.
- Niogi, S.N., Mukherjee, P., Ghajar, J., Johnson, C., Kolster, R.A., Sarkar, R., Lee, H., Meeker, M., Zimmerman, R.D., Manley, G.T., McCandliss, B.D., 2008. Extent of microstructural white matter injury in postconcussive syndrome correlates with impaired cognitive reaction time: a 3T diffusion tensor imaging study of mild traumatic brain injury. *AJNR American Journal of Neuroradiology* 29, 967–973.
- Parizel, P.M., Ozsarlak, Van Goethem, J.W., van den Hauwe, L., Dillen, C., Verlooy, J., Cosyns, P., De Schepper, A.M., 1998. Imaging findings in diffuse axonal injury after closed head trauma. *European Radiology* 8, 960–965.
- Pereira, J.M., Xiong, L., Acosta-Cabrero, J., Pengas, G., Williams, G.B., Nestor, P.J., 2010. Registration accuracy for VBM studies varies according to region and degenerative disease grouping. *NeuroImage* 49, 2205–2215.
- Povlishock, J.T., Katz, D.I., 2005. Update of neuropathology and neurological recovery after traumatic brain injury. *The Journal of Head Trauma Rehabilitation* 20, 76–94.
- Prastawa, M., Bullitt, E., Moon, N., Van Leemput, K., Gerig, G., 2003. Automatic brain tumor segmentation by subject specific modification of atlas priors. *Academic Radiology* 10, 1341–1348.
- Prastawa, M., Bullitt, E., Ho, S., Gerig, G., 2004. A brain tumor segmentation framework based on outlier detection. *Medical Image Analysis* 8, 275–283.
- Prastawa, M., Bullitt, E., Gerig, G., 2009. Simulation of brain tumors in MR images for evaluation of segmentation efficacy. *Medical Image Analysis* 13, 297–311.
- Provenzale, J.M., 2010. Imaging of traumatic brain injury: a review of the recent medical literature. *AJR American Journal of Roentgenology* 194, 16–19.
- Quattrocchi, K.B., Prasad, P., Willits, N.H., Wagner Jr., F.C., 1991. Quantification of midline shift as a predictor of poor outcome following head injury. *Surgical Neurology* 35, 183–188.
- Rosas, H.D., Liu, A.K., Hersch, S., Glessner, M., Ferrante, R.J., Salat, D.H., van der Kouwe, A., Jenkins, B.G., Dale, A.M., Fischl, B., 2002. Regional and progressive thinning of the cortical ribbon in Huntington's disease. *Neurology* 58, 695–701.
- Rutgers, D.R., Toulgoat, F., Cazejust, J., Fillard, P., Lasjaunias, P., Ducreux, D., 2008. White matter abnormalities in mild traumatic brain injury: a diffusion tensor imaging study. *AJNR American Journal of Neuroradiology* 29, 514–519.
- Saatman, K.E., Duhaime, A.C., Bullock, R., Maas, A.I., Valadka, A., Manley, G.T., 2008. Classification of traumatic brain injury for targeted therapies. *Journal of Neurotrauma* 25, 719–738.
- Salat, D.H., Buckner, R.L., Snyder, A.Z., Greve, D.N., Desikan, R.S., Busa, E., Morris, J.C., Dale, A.M., Fischl, B., 2004. Thinning of the cerebral cortex in aging. *Cerebral Cortex* 14, 721–730.
- Sanchez-Carrion, R., Gomez, P.V., Junque, C., Fernandez-Espejo, D., Falcon, C., Bargallo, N., Roig-Rovira, T., Ensenat-Cantalops, A., Bernabeu, M., 2008. Frontal hypoactivation on functional magnetic resonance imaging in working memory after severe diffuse traumatic brain injury. *Journal of Neurotrauma* 25, 479–494.
- Scheibel, R.S., Pearson, D.A., Faria, L.P., Kotrla, K.J., Aylward, E., Bachevalier, J., Levin, H.S., 2003. An fMRI study of executive functioning after severe diffuse TBI. *Brain Injury* 17, 919–930.
- Sharp, D.J., Ham, T.E., 2011. Investigating white matter injury after mild traumatic brain injury. *Current Opinion in Neurology* 24, 558–563.
- Sharp, D.J., Beckmann, C.F., Greenwood, R., Kinnunen, K.M., Bonnelle, V., De Boissezon, X., Powell, J.H., Counsell, S.J., Patel, M.C., Leech, R., 2011. Default mode network functional and structural connectivity after traumatic brain injury. *Brain* 134, 2233–2247.
- Shigemori, M., Kikuchi, N., Tokutomi, T., Ochiai, S., Kuramoto, S., 1992. Coexisting diffuse axonal injury (DAI) and outcome of severe head injury. *Acta Neurochirurgica Supplementum (Wien)* 55, 37–39.
- Sidaros, A., Engberg, A.W., Sidaros, K., Liptrot, M.G., Herning, M., Petersen, P., Paulson, O.B., Jernigan, T.L., Rostrup, E., 2008. Diffusion tensor imaging during recovery from severe traumatic brain injury and relation to clinical outcome: a longitudinal study. *Brain* 131, 559–572.
- Sigmund, G.A., Tong, K.A., Nickerson, J.P., Wall, C.J., Oyoyo, U., Ashwal, S., 2007. Multimodality comparison of neuroimaging in pediatric traumatic brain injury. *Pediatric Neurology* 36, 217–226.
- Smith, S.M., Jenkinson, M., Johansen-Berg, H., Rueckert, D., Nichols, T.E., Mackay, C.E., Watkins, K.E., Ciccarelli, O., Cader, M.Z., Matthews, P.M., Behrens, T.E., 2006. Tract-based spatial statistics: voxelwise analysis of multi-subject diffusion data. *NeuroImage* 31, 1487–1505.
- Song, S.K., Sun, S.W., Ramsbottom, M.J., Chang, C., Russell, J., Cross, A.H., 2002. Demyelination revealed through MRI as increased radial (but unchanged axial) diffusion of water. *NeuroImage* 17, 1429–1436.
- Sosin, D.M., Sniezek, J.E., Thurman, D.J., 1996. Incidence of mild and moderate brain injury in the United States, 1991. *Brain Injury* 10, 47–54.
- Stefanescu, R., Commowick, O., Malandain, G., Bondiau, P., Ayache, N., Pennec, X., 2004. Non-rigid atlas to subject registration with pathologies for conformal brain radiotherapy. *Medical Image Computing and Computer-Assisted Intervention (MICCAI)*, Rennes, France, pp. 704–711.
- Strangman, G.E., O'Neil-Pirozzi, T.M., Supelana, C., Goldstein, R., Katz, D.I., Glenn, M.B., 2010. Regional brain morphometry predicts memory rehabilitation outcome after traumatic brain injury. *Frontiers in Human Neuroscience* 4, 182.
- Sun, S.W., Liang, H.F., Cross, A.H., Song, S.K., 2008. Evolving Wallerian degeneration after transient retinal ischemia in mice characterized by diffusion tensor imaging. *NeuroImage* 40, 1–10.
- Tae, W.S., Kim, S.S., Lee, K.U., Nam, E.C., Kim, K.W., 2008. Validation of hippocampal volumes measured using a manual method and two automated methods (FreeSurfer and IBASPM) in chronic major depressive disorder. *Neuroradiology* 50, 569–581.
- Temkin, N.R., Machamer, J.E., Dikmen, S.S., 2003. Correlates of functional status 3–5 years after traumatic brain injury with CT abnormalities. *Journal of Neurotrauma* 20, 229–241.
- Terayama, Y., Meyer, J.S., Kawamura, J., Weathers, S., 1993. Cognitive recovery correlates with white-matter restitution after head injury. *Surgical Neurology* 39, 177–186.
- Thatcher, R.W., Camacho, M., Salazar, A., Linden, C., Biver, C., Clarke, L., 1997. Quantitative MRI of the gray-white matter distribution in traumatic brain injury. *Journal of Neurotrauma* 14, 1–14.
- Thornhill, S., Teasdale, G.M., Murray, G.D., McEwen, J., Roy, C.W., Penny, K.I., 2000. Disability in young people and adults one year after head injury: prospective cohort study. *BMJ* 320, 1631–1635.
- Tollard, E., Galanaud, D., Perlberg, V., Sanchez-Pena, P., Le Fur, Y., Abdennour, L., Cozzone, P., Lehericy, S., Chiras, J., Puybasset, L., 2009. Experience of diffusion tensor imaging and 1H spectroscopy for outcome prediction in severe traumatic brain injury: Preliminary results. *Critical Care Medicine* 37, 1448–1455.
- Tzourio-Mazoyer, N., Landeau, B., Papathanassiou, D., Crivello, F., Etard, O., Delcroix, N., Mazoyer, B., Joliot, M., 2002. Automated anatomical labeling of activations in SPM using a macroscopic anatomical parcellation of the MNI MRI single-subject brain. *NeuroImage* 15, 273–289.
- Vaessen, M.J., Hofman, P.A., Tijssen, H.N., Aldenkamp, A.P., Jansen, J.F., Backes, W.H., 2010. The effect and reproducibility of different clinical DTI gradient sets on small world brain connectivity measures. *NeuroImage* 51, 1106–1116.
- van der Naalt, J., 2001. Prediction of outcome in mild to moderate head injury: a review. *Journal of Clinical and Experimental Neuropsychology* 23, 837–851.
- van der Naalt, J., Hew, J.M., van Zomeran, A.H., Sluiter, W.J., Minderhoud, J.M., 1999. Computed tomography and magnetic resonance imaging in mild to moderate head injury: early and late imaging related to outcome. *Annals of Neurology* 46, 70–78.
- Van Dijk, K.R., Sabuncu, M.R., Buckner, R.L., 2012. The influence of head motion on intrinsic functional connectivity MRI. *NeuroImage* 59, 431–438.
- Van Horn, J.D., Irimia, A., Torgerson, C.M., Chambers, M.C., Kikinis, R., Toga, A.W., 2012. Mapping connectivity damage in the case of Phineas Gage. *PLoS One* 7, e37454.
- Van Leemput, K., Maes, F., Vandermeulen, D., Suetens, P., 1999. Automated model-based tissue classification of MR images of the brain. *IEEE Transactions on Medical Imaging* 18, 897–908.
- Van Leemput, K., Maes, F., Vandermeulen, D., Colchester, A., Suetens, P., 2001. Automated segmentation of multiple sclerosis lesions by model outlier detection. *IEEE Transactions on Medical Imaging* 20, 677–688.
- Variar, S., Kaiser, M., Forsyth, R., 2011. Establishing, versus maintaining, brain function: a neuro-computational model of cortical reorganization after injury to the immature brain. *Journal of International Neuropsychological Society* 17, 1030–1038.
- Vos, P.E., Bigler, E.D., 2011. White matter in traumatic brain injury: dis- or dysfunction? *Neurology* 77, 810–811.
- Wang, J.Y., Bakhadirov, K., Abdi, H., Devous Sr., M.D., Marquez de la Plata, C.D., Moore, C., Madden, C.J., Diaz-Arrastia, R., 2011. Longitudinal changes of structural connectivity in traumatic axonal injury. *Neurology* 77, 818–826.
- Wang, B., Prastawa, M.W., Irimia, A., Chambers, M.C., Vespa, P.M., Van Horn, J.D., Gerig, G., 2012. A patient-specific segmentation framework for longitudinal MR images of traumatic brain injury. In: Haynor, D.R., Ourselin, S. (Eds.), *Proceedings of the SPIE*. San Diego, CA, USA. February 4, 2012. 8413, pp. 831402 (7 pp.).
- Wang, B., Prastawa, M.W., Awate, S.P., Irimia, A., Chambers, M.C., Vespa, P.M., Van Horn, J.D., Gerig, G., 2012b. Segmentation of serial MRI of TBI patients using personalized atlas construction and topological change estimation. *IEEE International Symposium on Biomedical Engineering*, San Diego, CA.
- Wedeen, V.J., Hagmann, P., Tseng, W.Y., Reese, T.G., Weisskoff, R.M., 2005. Mapping complex tissue architecture with diffusion spectrum magnetic resonance imaging. *Magnetic Resonance in Medicine* 54, 1377–1386.
- Wedeen, V.J., Wang, R.P., Schmahmann, J.D., Benner, T., Tseng, W.Y., Dai, G., Pandya, D.N., Hagmann, P., D'Arceuil, H., de Crespigny, A.J., 2008. Diffusion spectrum magnetic resonance imaging (DSI) tractography of crossing fibers. *NeuroImage* 41, 1267–1277.
- Wen, W., Zhu, W., He, Y., Kochan, N.A., Reppermund, S., Slavin, M.J., Brodaty, H., Crawford, J., Xia, A., Sachdev, P., 2011. Discrete neuroanatomical networks are associated with specific cognitive abilities in old age. *Journal of Neuroscience* 31, 1204–1212.
- Wozniak, J.R., Krach, L., Ward, E., Mueller, B.A., Muetzel, R., Schnoebelen, S., Kiragu, A., Lim, K.O., 2007. Neurocognitive and neuroimaging correlates of pediatric traumatic brain injury: a diffusion tensor imaging (DTI) study. *Archives of Clinical Neuropsychology* 22, 555–568.
- Wu, Y., Warfield, S.K., Tan, I.L., Wells III, W.M., Meier, D.S., van Schijndel, R.A., Barkhof, F., Guttman, C.R., 2006. Automated segmentation of multiple sclerosis lesion subtypes with multichannel MRI. *NeuroImage* 32, 1205–1215.



- Yuh, E.L., Gean, A.D., Manley, G.T., Callen, A.L., Wintermark, M., 2008. Computer-aided assessment of head computed tomography (CT) studies in patients with suspected traumatic brain injury. *Journal of Neurotrauma* 25, 1163–1172.
- Yuh, E.L., Cooper, S.R., Ferguson, A.R., Manley, G.T., 2012. Quantitative CT improves outcome prediction in acute traumatic brain injury. *Journal of Neurotrauma* 29, 735–746.
- Zalesky, A., Fornito, A., Seal, M.L., Cocchi, L., Westin, C.F., Bullmore, E.T., Egan, G.F., Pantelis, C., 2011. Disrupted axonal fiber connectivity in schizophrenia. *Biological Psychiatry* 69, 80–89.
- Zhang, Y., Brady, M., Smith, S., 2001. Segmentation of brain MR images through a hidden Markov random field model and the expectation-maximization algorithm. *IEEE Transactions on Medical Imaging* 20, 45–57.