

A Case of Severe Thoracoabdominal Impalement by a Steel Bar

Ki Tae Kim, M.D., Pil Won Seo, M.D.

Department of Thoracic and Cardiovascular Surgery, Dankook University College of Medicine

A 53-year-old man arrived at the trauma center with a steel bar penetrating from the epigastrium to the right scapula. He was hypotensive and hypoxic, and immediate resuscitation and basic evaluation were performed. An emergency operation was performed due to an unstable hemodynamic state. Multiple injuries were confirmed in the right lower lobe, posterior chest wall, diaphragm, and liver lateral segment. Right lower lobectomy and liver lateral sectionectomy were performed following removal of the bar. The patient recovered without additional hemorrhage after the surgery, and was transferred to a rehabilitation institution with periodic follow-up.

Key words: 1. Penetrating
2. Thoracic injuries
3. Lobectomy

Case report

A 53-year-old man arrived at Dankook University Hospital trauma center with a steel bar impaling his torso. He had fallen at a construction site, from a height of about 15 m. A steel bar entered his chest, passed through the epigastrium and exited posteriorly at the right scapula (Fig. 1A). The diameter of the bar was about 2.5 cm, and the bar protruded from both sides (20 cm anteriorly and 30 cm posteriorly). The patient was carefully transferred to a resuscitation bed and placed in a semi-reclining position to avoid further manipulation of the impaled object. The patient had unstable vital signs on arrival showing a blood pressure of 87/49 mm Hg with signs of hypoxemia (PaO₂ 55 mm Hg, SpO₂ 85%), a heart rate of 124 bpm, and a low hemoglobin level of 11.2 mg/dL. Immediate resuscitation procedures, such as intubation and central line access, were

performed. Closed thoracostomy was performed due to hemothorax, which was revealed by chest X-ray, and about 2,000 mL of fresh blood was drained (Fig. 1B, C). Systolic blood pressure was slightly elevated to 90 mm Hg after transfusion; however, a large amount of hemoptysis and bleeding from the external wound persisted. The hemoglobin level decreased from 11.2 mg/dL to 6.5 mg/dL for 20 minutes despite the transfusion.

Emergency operation for exploration and removal of the bar was planned in consultation with an experienced hepatobiliary surgeon. Due to the penetrated bar, it was impossible to position the patient in the operation room. Thus, prior to the operation the posterior segment of the steel bar just above the skin level was cut off with an electric saw.

The patient was placed in the semilateral position under general anesthesia. The endotracheal tube was exchanged for a double-lumen tube. A large, right

Received: January 12, 2016, Revised: July 5, 2016, Accepted: July 6, 2016, Published online: December 5, 2016

Corresponding author: Pil Won Seo, Department of Thoracic and Cardiovascular Surgery, Dankook University Hospital, Dankook University College of Medicine, 201 Manghyang-ro, Dongnam-gu, Cheonan 31116, Korea (Tel) 82-41-550-6269 (Fax) 82-41-556-0524 (E-mail) pwseo@dankook.ac.kr

© The Korean Society for Thoracic and Cardiovascular Surgery. 2016. All right reserved.

© This is an open access article distributed under the terms of the Creative Commons Attribution Non-Commercial License (<http://creativecommons.org/licenses/by-nc/4.0>) which permits unrestricted non-commercial use, distribution, and reproduction in any medium, provided the original work is properly cited.

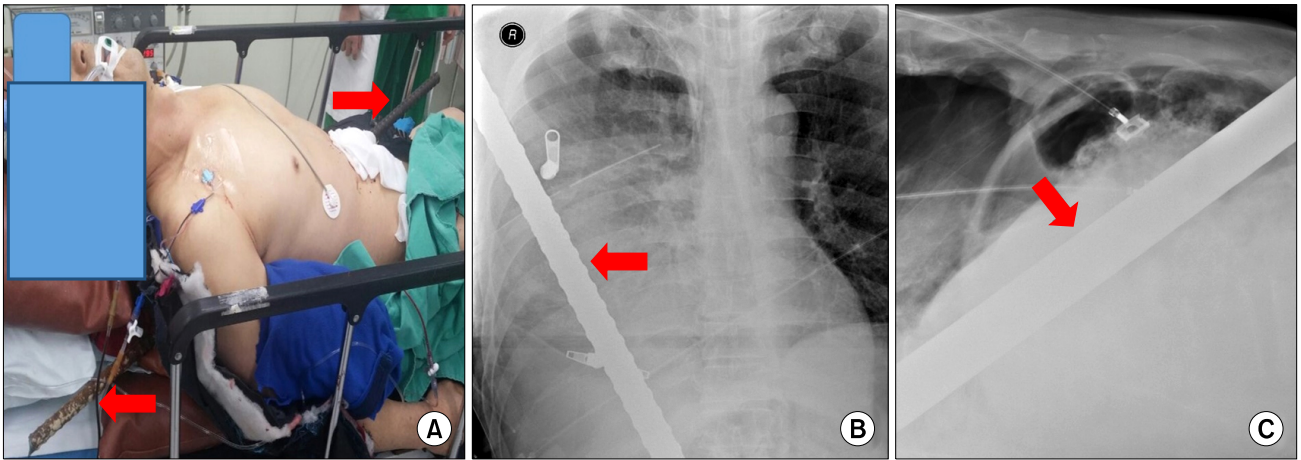


Fig. 1. (A) The patient was placed in a semi-reclining position. The steel bar penetrated his torso from the epigastrium to the right scapula (arrows). (B, C) Chest X-ray taken after tube thoracostomy. The impaling object was visible (arrows) in the right chest (B) and abdomen (C).

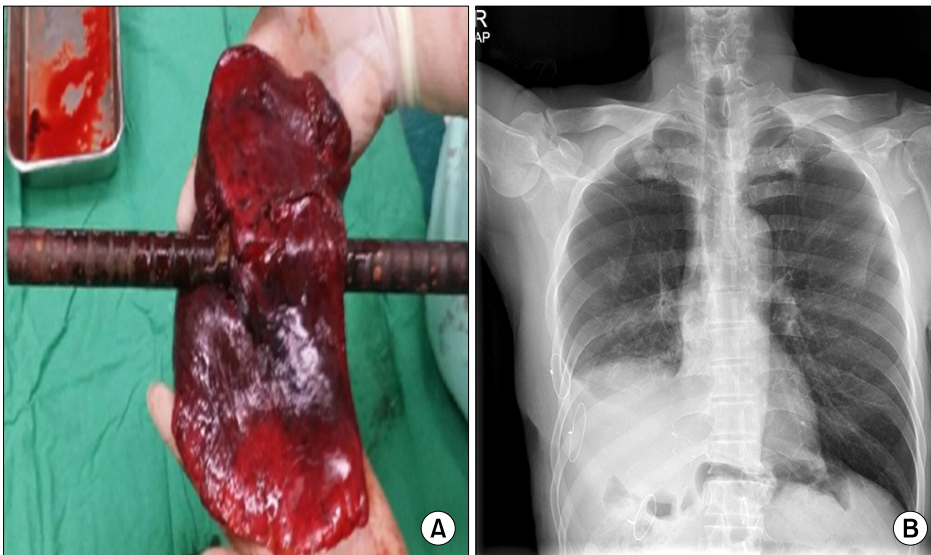


Fig. 2. (A) The right lower lobe was penetrated by the steel bar. (B) A chest X-ray was taken just before discharge.

side thoracoabdominal incision was made from the posterior chest to the middle line of the abdomen to cover the entire penetrated area. After anatomic exposure, the steel bar was removed carefully in order to handle the bleeding promptly. Primary exploration was performed by both teams in sequence. In the pleural space, only the right lower lobe was completely penetrated, and bleeding from the hole in the posterior chest wall was observed. While the exploration for thoracic cavity, Gauze packing and manual compression for bleeding control were performed. After acute damage control, a right lower lobectomy

was performed because the bleeding from the lung was most notable and hemoptysis persisted. Two-lung ventilation was started following extraction of the right lower lobe (Fig. 2A), and bleeding from the pleural space and hemoptysis were controlled successfully. In the abdominal cavity, the lateral segment of the liver was penetrated, but no other organs were injured. Lateral sectionectomy of the liver was performed, which stabilized the patient's vital signs. Drains from both sides were located and the diaphragm was repaired using intermittent silk sutures. The chest and abdomen were closed in a layer-by-layer

er manner, including the defect in the posterior chest wall.

The patient became stable without additional bleeding from the drains, and was extubated without sequelae on postoperative day 2. The chest tube was removed on postoperative day 4. Open reduction and screw fixation for the right distal femur fracture, which was acquired during the fall injury, was performed on postoperative day 13. The patient became stable enough to be transferred to a smaller institution for rehabilitation and was discharged on postoperative day 37. The patient is currently regularly followed up through the outpatient department and his present-day performance status is excellent.

Discussion

Thoracoabdominal impalement is one of the most severe types of penetrating trauma injuries [1]. These injuries usually involve vital organs such as the heart, lung, or the great vessels. Fatal conditions such as hypoxemia, airway obstruction, hemorrhage, cardiac tamponade, and aspiration can lead to death within 30 minutes to 3 hours. However, it is reported that patients with these conditions who are immediately transferred alive to a hospital have a high probability of survival [1,2]. Therefore, cautious extrication from the scene and rapid transportation to a trauma center are crucial factors for a survival outcome. Compared to right thoracic injury, left-side injury has higher mortality and morbidity because of the location of the heart and aorta [1,2].

One of the important principles of managing impaled patients is that the penetrating object should not be removed outside of the operating theater. The piercing object in situ has a tamponade effect on the surrounding vasculature, which itself has a hemorrhage control effect [3]. Bleeding from the external wound or hemoptysis cannot be controlled if the foreign object is removed without preparation. Therefore, minimal manipulation during transportation is essential to avoid further organ damage.

Positioning the patient on a bed without manipulation is also problematic. Placing the patient in the supine position is difficult because the impaling object usually protrudes from the patient's back. A semi-reclining position is recommended for intubation and basic radiologic evaluation, and facilitated by

placing several pillows beneath the patient's back [1,3]. A sitting position or lateral decubitus position are alternatives in this scenario [3]. Carefully severing the penetrating object immediately above the level of the skin can shorten the object. This can prevent unintentional dislodgement and facilitate positioning of the patient on the operating bed [3].

Radiographic or other time-consuming examinations should not delay definitive management [1]. Double-lumen tube intubation is the ideal option if lung parenchymal injury accompanying hemoptysis is suspected. However, in practice, there are many restrictions such as inadequate position, lack of time for resuscitation, and poor hemodynamic status. Wide surgical exposure to cover the entire injured area should be performed, involving sternotomy, thoracotomy, laparotomy, or both. In this case, a large right thoracoabdominal incision was made for simultaneous hemorrhage control in both the thorax and abdomen, so that injured organs, chest wall, lung, diaphragm, and liver could be visualized. While left thoracoabdominal incisions are familiar to surgeons due to thoracoabdominal aortic operations, right thoracoabdominal exposure is performed considerably less frequently. In addition, wide debridement is recommended by removing as much necrotic tissue as possible because the impaled object is likely to be severely contaminated. However, lung preservation is desirable to prevent empyema formation [4].

We reviewed a case of massive thoracoabdominal impalement. This type of injury is very rare and can be uncomfortable for physicians to treat. In many cases, the extent of injury is obscure, and there is limited time for evaluation and resuscitation due to poor vital signs. Rapid and safe prehospital activity is crucial for survival. Additionally, the impaled object should not be removed before the patient reaches the operating theater. The outcome of impalement injury can be improved by appropriate treatment by a multidisciplinary surgical team.

Conflict of interest

No potential conflict of interest relevant to this article was reported.

References

1. Sawhney C, D'souza N, Mishra B, Gupta B, Das S. *Management of a massive thoracoabdominal impalement: a case report*. Scand J Trauma Resusc Emerg Med 2009;17:50.
2. Ayandipo OO, Irabor D, Afuwape O, Adeoye P, Salami M. *Multiple thoracoabdominal impalement injuries*. Prehosp Disaster Med 2012;27:88-9.
3. Lunevicius R, O'ullivan A. *Unusual management of thoracoabdominal impalement injury to the right hemiliver and diaphragm*. Chin J Traumatol 2014;17:41-3.
4. Winfield RD, Parr AG, Ang DN, et al. *A case of dual thoracoabdominal impalement in vehicular trauma*. Am Surg 2008;74:757-60.