

Endoscopic radial incision and cutting for Crohn's Disease-associated intestinal stricture: a pilot study



Authors

Rintaro Moroi¹, Hisashi Shiga¹, Masatake Kuroha¹, Yoshitake Kanazawa¹, Kotaro Nochioka², Yoichi Kakuta¹, Yoshitaka Kinouchi¹, Atsushi Masamune¹

Institutions

- 1 Division of Gastroenterology, Tohoku University Hospital, Miyagi, Japan
- 2 Clinical Research, Innovation and Education Center, Tohoku University Hospital, Miyagi, Japan

submitted 21.6.2019

accepted after revision 12.9.2019

Bibliography

DOI <https://doi.org/10.1055/a-1027-6921> |
 Endoscopy International Open 2020; 08: E81–E86
 © Georg Thieme Verlag KG Stuttgart · New York
 eISSN 2196-9736

Corresponding author

Rintaro Moroi, MD, PhD, Division of Gastroenterology,
 Tohoku University Hospital, 1-1, Seiryō-cho, Aoba-ku,
 Sendai, Miyagi, 980-8574, Japan
 Fax: +81-22-717-7177
rinta@med.tohoku.ac.jp

ABSTRACT

Background and study aims Intestinal stricture associated with Crohn's disease (CD) is usually treated by endo-

scopic balloon dilation (EBD) or stricture plasty. Although EBD is effective and safe for such strictures, refractory stricture after EBD poses a problem. Hence, other novel approaches for these refractory strictures are required. On the other hand, the efficacy of radial incision and cutting (RIC) method for esophageal stricture after esophagogastric surgery is reported. In this pilot study, we adopted the RIC technique for five CD patients with refractory intestinal stricture to dilate their strictures. We conducted the RIC procedure using an electric needle knife with a ceramic tip on the top of the needle. Four cases were of anastomotic stricture after ileocecal resection and the remaining one case was of stricture due to mucosal healing. The RIC procedure was successful for all five patients. Average procedure time was 18.6 minutes. One patient developed delayed bleeding after RIC. There were no cases of perforation. RIC could be an alternative therapy for intestinal stricture associated with CD. Further studies should be conducted to clarify its efficacy and safety.

University Hospital Medical Network Clinical Trials Registry
 UMIN000033145

TRIAL REGISTRATION: Single-Center, single-arm, Non-randomized, prospective, pilot study UMIN000033145 at <http://www.umin.ac.jp>

Introduction

Crohn's disease (CD) is a chronic inflammatory bowel disease that causes intestinal complications such as stricture and fistula. These are usually treated by endoscopic balloon dilation (EBD) [1] or surgical procedures, including intestinal resection and strictureplasty. Because repeated intestinal resections lead to potential risk of short bowel syndrome, EBD is considered to be more suitable compared to surgery. Although EBD is effective and safe for intestinal stricture in patients with CD [2, 3], it has several problems. One of the problems is the relatively high recurrence rate of stricture [4, 5]. A review article showed that 73.5% and 42.9% of patients with intestinal stricture underwent re-dilation and surgical resection, respectively,

at 24 months after EBD [3]. Another problem is that EBD needs to be performed several times to obtain adequate dilation, which contributes to lengthening the admission period. Therefore, other novel approaches for intestinal stricture associated with CD are required.

As a new technique to solve the abovementioned problems, radial incision and cutting (RIC) has been reported in a study [6]. The RIC method was developed for dilating refractory stricture after surgical resection for esophagogastric diseases by incising the stricture with an endoscopic electrical knife. The aforementioned study also reported improvement in dysphasia and long-term patency of RIC compared with those of EBD.

In this pilot study, we performed RIC to dilate intestinal stricture associated with CD of five patients.

▶ **Table 1** Patients and their backgrounds.

No	Sex	Age (year)	Montreal classification	Previous operation	Stricture location	Stricture type	Stricture length	Current therapy	Procedure time (min)	Success or failure	Adverse event	Hospital stay after RIC (day)
1	M	56	ileocolonic	IR, PRSI	Anastomosis after IR	Secondary	< 1 cm	Infliximab, elemental diet	17	Success	None	23
2	M	34	ileocolonic	IR	Anastomosis after IR	Secondary	< 1 cm	Adalimumab, azathiopurine	12	Success	None	7
3	F	25	ileocolonic	IR	Anastomosis after IR	Secondary	< 1 cm	Adalimumab, mesalazine	11	Success	Delayed bleeding	11
4	M	45	ileocolonic	IR	Anastomosis after IR	Secondary	1 cm	Mesalazine, elemental diet	23	Success	None	6
5	M	49	colonic	none	Rectum	Primary	2 cm	Infliximab, azathiopurine	30	Success	None	6

Primary stricture is defined as a stricture due to mucosal healing.

Secondary stricture is defined as an anastomotic stricture after intestinal resection.

IR, ileocecal resection; PRSI, partial resection of the small intestine; RIC, radial incision and cutting.

Case report

Patients

This study was conducted as a pilot study under the approval of our institutional review board (2018-2-92).

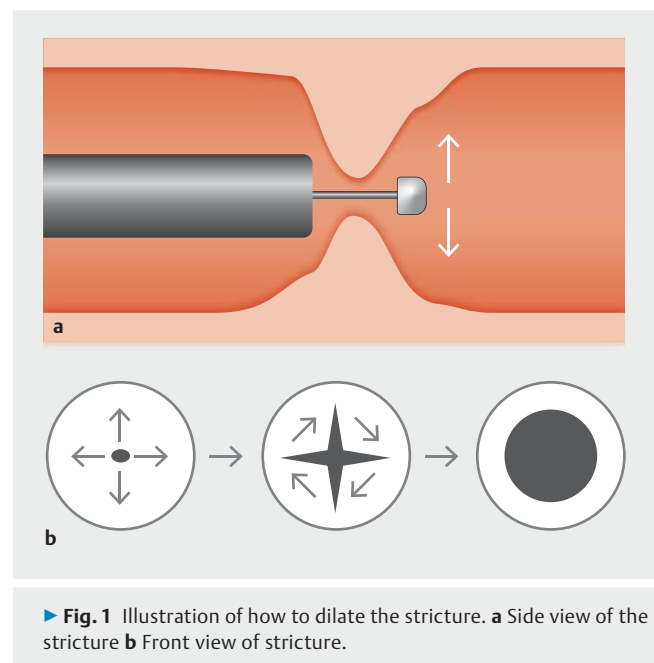
From November 2018 to May 2019, we performed RIC in five patients with CD with intestinal stricture. Written informed consent was obtained from all the patients. The list of the patients and their backgrounds is summarized in ▶ **Table 1**. Major inclusion criteria were as follows: (1) presence of intestinal stricture through which a scope could not pass and (2) previous history of EBD (refractory stricture). Intestinal stricture associated with CD was classified into two types according to the cause of stricture formation: (1) primary stricture due to mucosal healing and (2) secondary stricture (anastomotic stricture after intestinal resection). Both stricture types were eligible for inclusion in the study.

Procedure

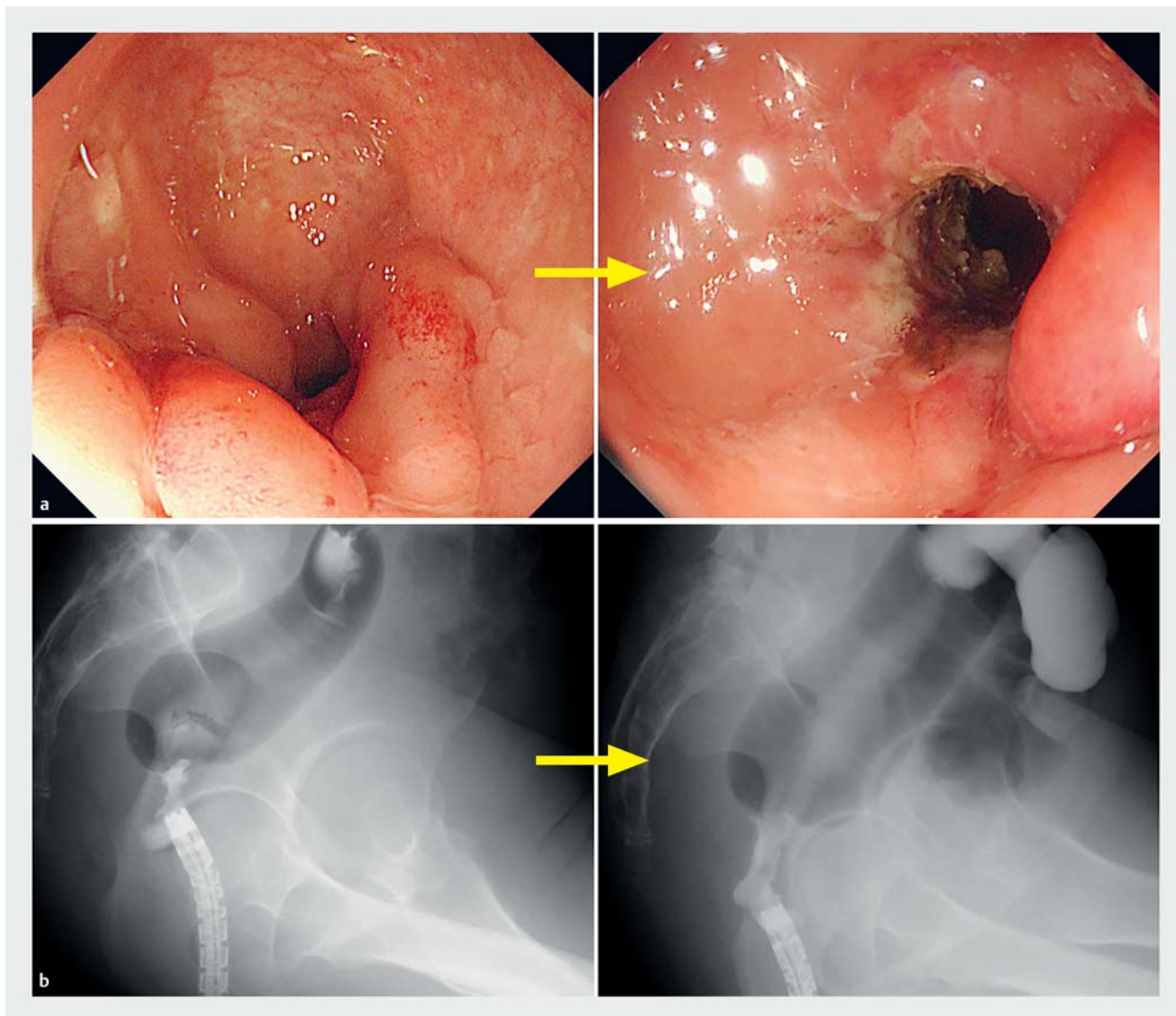
The RIC procedure was performed based on the method reported in previous studies [6–9] (▶ **Fig. 1**). For the purpose of mucosal incision, IT knife nano (Olympus Medical Science, Tokyo, Japan) was used in all cases. Stricture lengths were estimated at previous examinations under radiology. Technical success was defined as the scope passage. The procedure time was calculated from the beginning to the end of cutting.

Results

Four patients were male. The average age and disease duration were 41.8 years and 8.8 years, respectively. Four patients had secondary stricture after ileocecal resection, measuring 1 cm or less. The remaining patient had primary stricture of 2 cm in length (▶ **Fig. 2**). Four cases were of ileocolitis type and the other was of colitis type. The list of therapies for CD was as fol-



▶ **Fig. 1** Illustration of how to dilate the stricture. **a** Side view of the stricture **b** Front view of stricture.



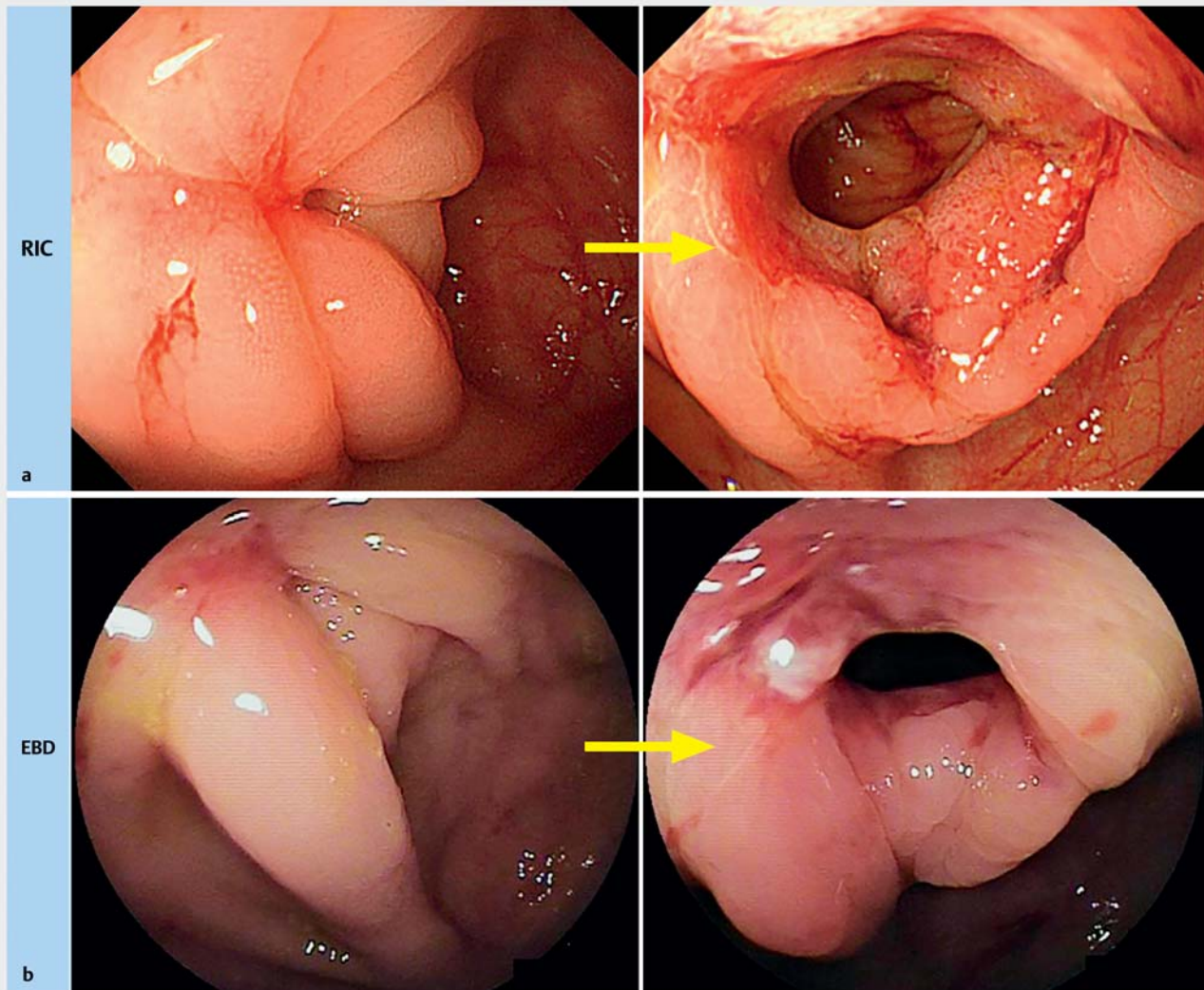
► **Fig. 2** Endoscopic and radiologic view in patient number 5. **a** Before RIC (left) and just after RIC (right) in patient number 5. **b** Before RIC (left) and just after RIC (right). Endoscopic dilation was observed radiologically.

lows: infliximab: two cases, adalimumab: two cases, azathioprine: two cases, mesalazine: two cases, elemental diet: two cases. All patients were not under antiplatelets or anticoagulant drugs.

The RIC procedure was successful in all five cases (► **Table 1**). Most patients were observed to have dilations larger than that created by EBD (► **Fig. 3**). The average procedure time was 18.6 minutes. There were no cases of perforation. Although patient number 3 developed delayed bleeding twice after RIC, endoscopic hemostasis with a coagulation device was successfully achieved (► **Fig. 4**). The average hospital stay after RIC was 10.6 days. In all patients, occlusive symptoms including abdominal bloating and nausea were decreased after RIC.

Discussion

We successfully conducted RIC in five CD patients with intestinal strictures. There are some case reports regarding RIC for colorectal strictures [7–9] after surgery for colorectal cancers. However, there is only one report about endoscopic dilation resembling RIC for CD intestinal stricture [10]. The technique was called Needle-Knife Strictureotomy (NKSt). NKSt incises the stricture to dilate it in a manner similar to RIC. However, NKSt usually dilates the stricture using a needle electric knife without a ceramic tip. In contrast, the IT knife nano used in RIC has a ceramic tip on the top of its needle. This ceramic tip is considered to be useful for preventing perforation. Although NKSt technically resembles RIC, the devices used in each procedure are different. To our knowledge, this is the first report of RIC for intestinal stricture associated with CD.

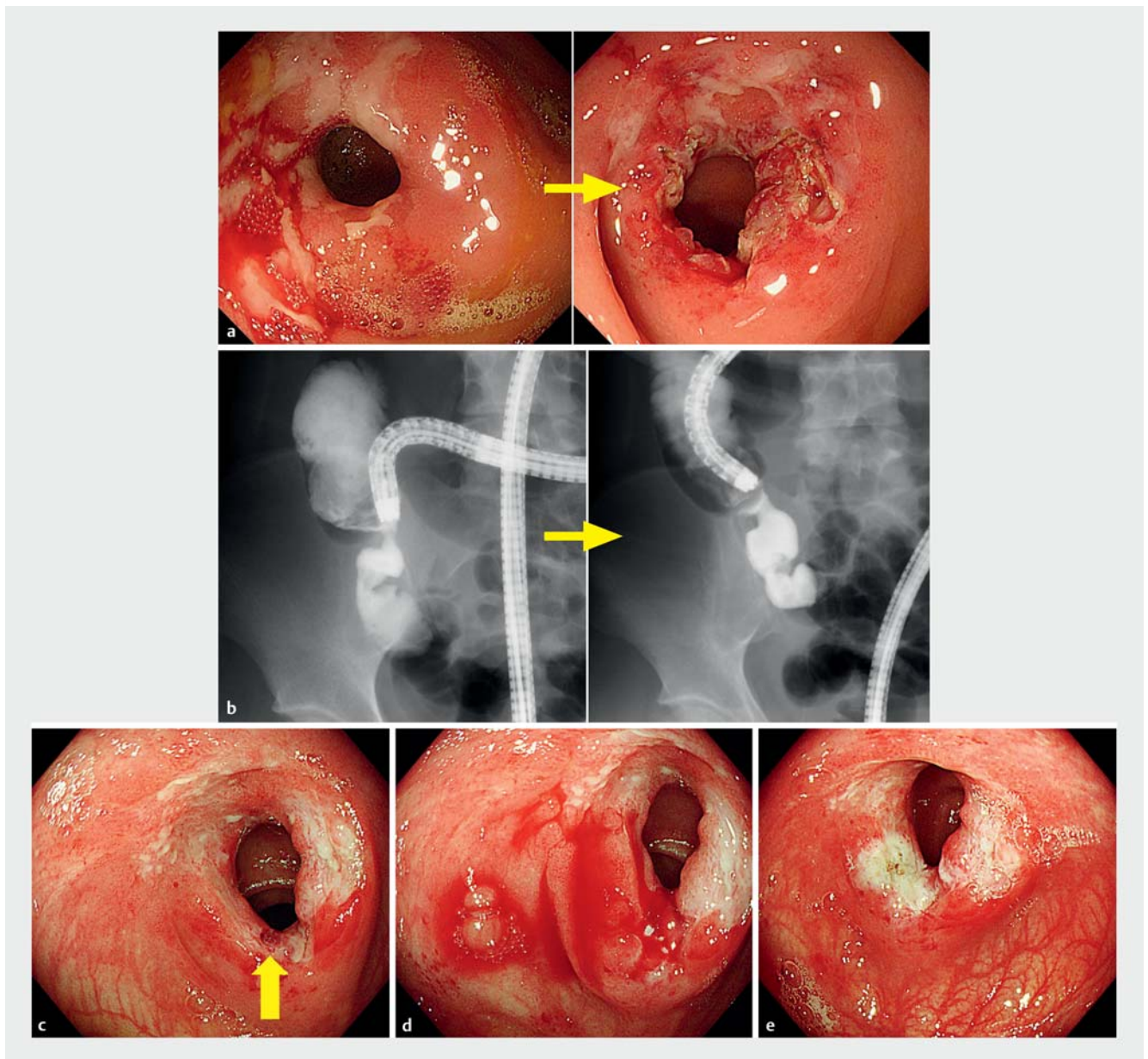


► **Fig. 3** The endoscopic view in patient number 1. **a** Before RIC (left) and 11 days after RIC (right) in patient number 1. Anastomosis dilation was larger compared with the dilation obtained after EBD. **b** Before EBD (left) and just after EBD (right) in the same patient.

This case series demonstrated several benefits of RIC over EBD. First, RIC demonstrated larger dilation compared to EBD in our case series. Intestinal strictures, especially anastomotic strictures, consist of fibrotic changes which prevent the balloon from dilating. Therefore, it is reasonable to cut the fibrotic tissue. The second benefit is that RIC might shorten the admission period. It usually takes two to three EBDs in one session to dilate the stricture to a sufficient diameter while avoiding perforation, which leads to the long admission period. In contrast, most of our patients could be discharged from the hospital around one week after only one RIC procedure. The admission period of patient number 1 was over 3 weeks because of other examinations of CD. In patient number 3, endoscopic hemostasis, which led to a longer admission period, was performed because the patient developed delayed bleeding twice after RIC.

There are several issues to be clarified. First, adverse events such as bleeding and perforation could occur. In the current study, no cases of perforation existed. Although one of the five

patients developed delayed bleeding, endoscopic hemostasis was safely performed. Other case series of RIC for colorectal anastomosis and NKSt also report performance of these techniques safely and with low complication rates (delayed bleeding: 0% to 3.3%, perforation: 0% to 0.4%) [7–10]. Second, the indication for RIC is controversial. There is no clear indication for RIC at present. In our case series, four cases developed intestinal stricture due to surgical anastomosis and the remaining one developed rectal stricture due to mucosal healing. Although the causes of developing intestinal stricture were different, our results indicate that RIC is able to dilate any type of stricture (primary or secondary) which is 2 cm or less in length. We need an increased number of patients to further investigate indications of RIC. Third, long-term patency is unclear. Although EBD is effective and safe for CD intestinal stricture [2, 3], EBD has a relatively high frequency of recurrence [4, 5]. One report compared long-term patency after RIC with that after EBD for esophagogastric stricture [6], stating that RIC for



► **Fig. 4** Endoscopic and radiologic view in patient number 3. **a** Before RIC (left) and just after RIC (right) in patient number 3. **b** Before RIC (left) and just after RIC (right). Endoscopic dilation was observed radiologically. **c** Five days after RIC. Good dilation and an exposed vessel were observed (yellow arrow). **d** Active bleeding from the vessel. **e** Endoscopic hemostasis was achieved using a coagulation device.

intestinal stricture might also provide a long-term patency compared to conventional EBD.

Conclusion

RIC might be an alternative therapy for CD-associated intestinal stricture. Further studies are warranted to clarify its efficacy and safety.

Competing interests

None

References

- [1] Hirai F. Current status of endoscopic balloon dilation for Crohn's disease. *Intest Res* 2017; 15: 166–173
- [2] Hirai F, Andoh A, Ueno F et al. Efficacy of endoscopic balloon dilation for small bowel strictures in patients with Crohn's disease: A nationwide, multi-center, open-label, prospective cohort study. *J Crohn Colitis* 2017; doi:10.1093/ecco-jcc/jjx159
- [3] Bettenworth D, Gustavsson A, Atreja A et al. A pooled analysis of efficacy, safety, and long-term outcome of endoscopic balloon dilation therapy for patients with stricturing crohn's disease. *Inflam Bowel Dis* 2017; 23: 133–142

- [4] Endo K, Takahashi S, Shiga H et al. Short and long-term outcomes of endoscopic balloon dilatation for Crohn's disease strictures. *World J Gastroenterol* 2013; 19: 86–91
- [5] Kanamori A, Sugaya T, Tominaga K et al. Endoscopic balloon dilation for stenotic lesions in Crohn's disease. *Turkish J Gastroenterol* 2017; 28: 117–124
- [6] Muto M, Ezoe Y, Yano T et al. Usefulness of endoscopic radial incision and cutting method for refractory esophagogastric anastomotic stricture (with video). *Gastrointest Endosc* 2012; 75: 965–972
- [7] Asayama N, Nagata S, Shigita K et al. Effectiveness and safety of endoscopic radial incision and cutting for severe benign anastomotic stenosis after surgery for colorectal carcinoma: a three-case series. *Endosc Int Open* 2018; 6: E335–E339
- [8] Osera S, Ikematsu H, Odagaki T et al. Efficacy and safety of endoscopic radial incision and cutting for benign severe anastomotic stricture after surgery for lower rectal cancer (with video). *Gastrointest Endosc* 2015; 81: 770–773
- [9] Harada K, Kawano S, Hiraoka S et al. Endoscopic radial incision and cutting method for refractory stricture of a rectal anastomosis after surgery. *Endoscopy* 2015; 47: (Suppl. 01): E552–E553
- [10] Lan N, Shen B. Endoscopic stricturotomy with needle knife in the treatment of strictures from inflammatory bowel disease. *Inflam Bowel Dis* 2017; 23: 502–513