


Correlation between Individual Anthropometric Characteristics and Anterior Cruciate Ligament Tibial Fovea Measurements*

Correlação entre características antropométricas individuais e as medidas da fôvea tibial do ligamento cruzado anterior

Julio Cesar Gali^{1,2}  David Braz Del Giglio^{1,2} Luís Fernando Patriarcha^{1,2} Bruno Azi Pacileo Cruz^{1,2}
Julio Cesar Gali Filho³

¹Department of Orthopedics, Faculty of Medical and Health Sciences, Pontifícia Universidade Católica de São Paulo, Sorocaba, SP, Brazil

²Knee Surgery Service, Hospital Santa Lucinda, Sorocaba, SP, Brazil

³Sports Orthopedics and Traumatology Center, Sorocaba, SP, Brazil

Address for correspondence Julio Cesar Gali, PhD, Rua Caracas 418, Sorocaba, SP, 18046-718, Brasil (e-mail: juliogali@note.med.br).

Rev Bras Ortop 2020;55(1):88–94.

Abstract

Objective To evaluate possible connections between the weight and height of patients submitted to total knee arthroplasty (TKA), with the length, width and area of the anterior cruciate ligament (ACL) fovea, as verified during surgery.

Methods A total of 33 proximal tibial joint surfaces, obtained from TKA tibial sections of 33 patients, were used in the present study. The ACL was resected with a delicate scalpel to expose the ACL tibial fovea. Then the periphery of this fovea was delimited with a marker pen by means of small dots. Each piece was photographed, and the ACL tibial fovea length, width, and area were measured with the ImageJ (National Institutes of Health, Bethesda, MD, USA) software. Statistical analysis studied the correlation between anthropometrics data of the patients and the measurements of the ACL tibial fovea.

Results The ACL tibial fovea length, width, and area were, respectively, 11.7 ± 2.0 mm, 7.1 ± 1.4 mm and 151.3 ± 22.2 mm². There was a statistically significant relationship between the height of the patients and the width of the ACL tibial fovea. The width of the ACL fovea could be predicted by the formula: width = $107.294 - (133.179 \times \text{height}) + (44.009 \times \text{squared height})$.

Conclusion The height of the patients may predict the width of the ACL tibial fovea, and therefore, may allow surgeons to choose the more adequate graft for each patient in ACL reconstruction.

Keywords

- ▶ tibia
- ▶ anterior cruciate ligament
- ▶ anatomy

Resumo

Objetivo Avaliar possíveis relações entre o peso e altura de pacientes submetidos à artroplastia total do joelho com o comprimento, largura e área da fôvea do ligamento cruzado anterior, verificados na cirurgia.

* The present study was conducted at the Department of Orthopedics, Faculty of Medical and Health Sciences of the Pontifícia Universidade Católica de São Paulo, Sorocaba, SP, Brazil.

Palavras-chave

- ▶ tibia
- ▶ ligamento cruzado anterior
- ▶ anatomia

Métodos Um total de 33 superfícies articulares tibias proximais, obtidas nos cortes tibiais de artroplastia total do joelho de 33 pacientes, foram utilizadas no presente estudo. O ligamento cruzado anterior foi dissecado cuidadosamente e ressecado com bisturi delicado, para expor sua fôvea. Depois, a periferia dessa fôvea foi demarcada por pequenos pontos, com um marcador. Cada peça foi fotografada e as medições do comprimento, largura e área da fôvea tibial do ligamento cruzado anterior foram feitas com o programa ImageJ (National Institutes of Health, Bethesda, MD, EUA). A análise estatística avaliou a correlação entre os dados antropométricos dos pacientes com as medidas da fôvea tibial do ligamento cruzado anterior.

Resultados O comprimento, a largura e a área médios da fôvea tibial do ligamento cruzado anterior foram, respectivamente $11,7 \pm 2,0$ mm, $7,1 \pm 1,4$ mm e $151,3 \pm 22,2$ mm². Houve relação estatisticamente significativa entre a altura dos pacientes e a largura da fôvea tibial do ligamento cruzado anterior. A largura da fôvea do ligamento cruzado anterior pôde ser predita pela fórmula: largura = $107,294 - (133,179 \times \text{altura}) + (44,009 \times \text{altura ao quadrado})$.

Conclusão A altura dos pacientes pôde prever a largura da fôvea tibial do ligamento cruzado anterior e, assim, pode ajudar os cirurgiões escolher o enxerto mais adequado para cada paciente, nas reconstruções do ligamento cruzado anterior.

Introduction

The number of anterior cruciate ligament (ACL) reconstructions in the period between 1994 and 2006 increased by 50%, especially among women and people < 20 and > 40 years old.¹ The outcome of ACL reconstruction depends on the biological response of the patient, the surgical technique, and rehabilitation. The current trend is to perform anatomical reconstructions, defined as those with the intention of seeking the functional restoration of the ACL to its native dimensions, collagen orientation and insertion sites in order to try to reproduce normal anatomy, restore kinematics and provide long-term joint health.²

A more recent conception is that reconstructions need to be individualized. Since no two ACLs are the same, the graft must be shaped for each individual.³ Since ACL reconstruction can be considered a graft transplant, its size should be especially evaluated. However, in most reconstructive surgeries using autologous grafts, the size of the ACL is mainly determined by the size of the graft obtained and not by the measurement of the ACL insertion. If the surgeon could predict the size of the ACL tibial insertion before surgery, he could also choose the most appropriate autograft size.⁴

Therefore, anticipating the dimensions of the ACL insertion can be valuable for better surgical planning. This can be done by CT scan^{5,6} or magnetic resonance imaging (MRI),⁷⁻¹¹ but it can also be predicted by the individual physical characteristics.^{3,4}

In this decade, some authors sought to correlate the weight and height of patients with the size of their tibial ACL insertion. These studies were conducted in the United States³ and in South Korea.¹¹⁻¹³ Therefore, a study is important to evaluate if there is any correlation between the weight and height of the patients and the ACL tibial foveal dimensions in the Brazilian population, composed of a mixture of ethnicities, particularly

African descendant, Portuguese, Italian, South-American Native, Spanish, German, Japanese, Polish, Arab or Semite.¹⁴

The objective of this study was to evaluate possible correlations between the weight and height of patients undergoing total knee arthroplasty (TKA) and the length, width and area of the ACL tibial fovea found in TKA. Our hypothesis was that the preoperative evaluation of the anthropometric characteristics of our patients could anticipate the ACL tibial fovea dimensions.

Methods

We have obtained the approval of the Ethics Committee of our institution for the present study (CAAE: 21220013.6.00 00.5373, opinion: 509.126). Information on the weight and height of the patients was obtained from the medical records of the Hospital of the Institution where the study was performed.

From September 2014 to June 2017, 74 TKAs were performed in our service. Only knees whose ACLs had normal macroscopic appearance were included in our study. Exclusion factors were history of previous joint trauma, infectious or inflammatory diseases that could alter the ACL tibial insertion, macroscopic morphological alterations of the ACL and presence of osteophytes around the tibial insertion of the ACL at the time of evaluation. In cases of bilateral surgery, only one knee (right or left) was chosen by lot (head or tails). Thus, 41 knees were excluded from our investigation, 7 (9.4%) because they were from patients who had bilateral arthroplasty, and 34 due to macroscopic changes in the normal anatomy of the ACL or the presence of osteophytes that altered ACL insertion (45.9%).

Thus, our final sample consisted of 33 knees from 33 patients. Nineteen were women (57.6%) and 14 were men

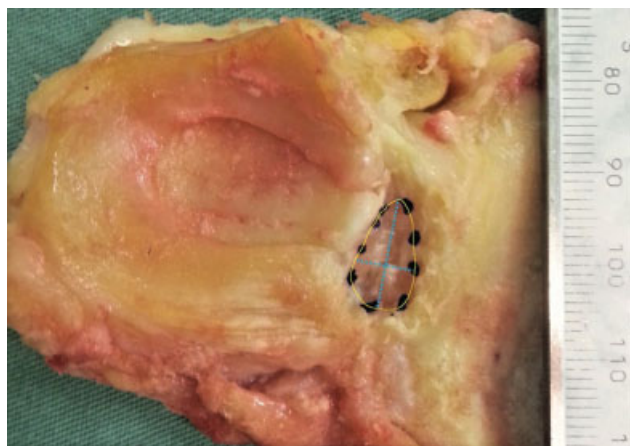

Fig. 1 Superior view of the tibial superior articular face, removed at arthroplasty, with the delimitation of the ACL fovea and the definition of its length and width. Source: File provided by the institution.

(42.4%). Eighteen knees were right (54.5%) and 15 were left (45.5%). The average age of the subjects was 69.5 years old (± 7.3), the median weight was 78.4 kg (± 12.3) and the average height was 1.58 m (± 0.08).

Each piece, corresponding to the proximal tibial portion, taken at the tibial section of the TKA, was evaluated by the same surgeon, senior of the team, after surgery, with a four-times magnifying lens. After thorough ACL dissection, it was resected with a delicate scalpel to expose its tibial fovea, a depression between the intercondylar eminences corresponding to the tibial insertion of the ACL.⁵ The fovea was delimited, in its periphery, by means of small dots, with a marker pen. A millimeter ruler was placed next to the pieces to serve as a parameter for measurements, and each of them was photographed with a Nikon D3100 (Nikon, Tokyo, Japan) digital camera, which was positioned parallel to the plane of the examination table of the pieces.

All of the measurements were made subsequently, using the ImageJ (National Institutes of Health, Bethesda, MD, USA) software, by another member of the staff. The length of the ACL tibial fovea was defined as its largest axis in the anteroposterior direction, and its width as its largest axis in the lateromedial direction, perpendicular to the anteroposterior axis. To measure the area, the previously demarcated dots

were joined in the computer (**► Figure 1**). We also obtained the ratio between the length and width of the ACL tibial fovea. The measurements were made twice, and the average of the values obtained was used.

Statistical Analysis

We used multivariate analysis of variance (MANOVA) to interpret the results, since the sample can be considered small, and has three interrelated variables (width, length and area). Thus, we adopted as a strategy the application of a one-factor MANOVA (gender) and two covariates (height and weight) and, simultaneously with the MANOVA, we performed the confidence interval calculations and multiple comparisons adjusted by *bootstrap* ($n = 1.000$; with bias correction) to pinpoint where the significant differences were.

To examine the normality of each of the variables, the Shapiro-Wilk test was used, with a 5% significance level, and we rejected univariate normality in all dependent variables except length. The Levene test was used for genders and sides and, in all variables, we do not reject the hypothesis of homogeneity of variances (**► Table 1**).

Results

The mean length, width and area of the ACL tibial fovea were, respectively, 11.7 ± 2.0 mm; 7.1 ± 1.4 mm and 151.3 ± 22.2 mm². On average, the ACL fovea length was 1.64 times the width. In 27 knees (81.8%) the length of the ACL tibial fovea was < 14 mm and in 28 patients (84.8%) the fovea width was < 8 mm. The full results are described in **► Table 2**.

All of the individual correlations were significant, but none of the coefficients exceeded 0.90, the limit of multicollinearity. We found a statistically significant relationship only between patient height and ACL tibial foveal width. The relationship between these two variables is displayed in **► Figure 2**. In this figure, there is a value that stands out, but which did not seem to us to be an extreme value (*outlier*), given that a height of 1.85 m is perfectly plausible. There was a quadratic relationship between height and width, which fit much better than a linear relationship (**► Figure 3**).

The adjustment of this chart straight line by Ordinary Least Squares (OLS) returned an adjusted R² of 0.369, while the

Table 1 Sample Homogeneity and Normality

	Levene*			Shapiro-Wilk		
	Statistic	DF	Sig.	Statistic	DF	Sig.
Age	0.686	31	0.414	0.957	33	0.208
Weight	0.173	31	0.68	0.973	33	0.554
Height	2.337	31	0.136	0.928	33	0.030
Width	0.929	31	0.343	0.850	33	0.000
Length	0.437	31	0.514	0.977	33	0.680
Area	1.967	31	0.171	0.831	33	0.000

Abbreviation: DF, degrees of freedom (sample size - the number of estimated parameters).

Source: File provided by the institution.

*Grouping variable: Gender.

Table 2 Distribution of patients and all outcomes

PATIENT	AGE	GENDER	WEIGHT	HEIGHT	SIDE	WIDTH	LENGTH	AREA
			Kg	m		mm	mm	mm ²
1	69	F	51	1.48	R	5.96	10.27	50.4
2	72	M	73	1.62	L	6.29	10.10	52.8
3	60	M	79	1.65	L	7.55	14.27	78.9
4	67	F	80	1.58	R	7.03	12.16	61.8
5	66	F	77	1.53	L	7.92	11.92	67.1
6	72	M	108	1.64	L	6.48	9.70	49.4
7	75	F	80	1.50	R	5.09	9.56	35.8
8	68	F	85	1.57	R	6.76	9.52	49.2
9	81	M	70	1.70	R	7.22	10.97	52.3
10	79	F	69	1.50	L	6.99	11.38	51.2
11	81	M	70	1.70	L	6.11	9.44	51.3
12	62	F	77	1.56	L	7.87	14.62	88.2
13	62	M	76	1.78	R	8.75	15.86	90.8
14	58	F	72	1.50	R	6.96	10.13	47.7
15	74	M	81	1.60	R	8.33	12.98	76.6
16	64	M	71	1.62	R	7.52	11.68	68.0
17	70	F	94	1.58	L	7.60	12.65	70.4
18	83	F	89	1.55	L	7.13	10.85	51.0
19	62	F	84	1.60	R	7.00	10.75	52.9
20	58	M	88	1.64	L	8.46	12.20	66.5
21	72	F	63	1.50	L	5.13	8.62	33.4
22	62	F	62	1.49	R	6.96	13.26	68.9
23	60	M	92	1.64	R	7.32	11.89	61.9
24	68	M	66	1.58	R	8.16	14.10	96.6
25	73	F	60	1.50	L	4.87	10.69	40.0
26	71	M	84	1.58	R	6.56	11.54	56.2
27	65	F	90	1.55	R	4.98	13.11	54.0
28	66	F	73	1.45	L	7.13	11.84	66.0
29	77	M	76	1.64	R	6.23	13.13	60.1
30	64	F	108	1.60	L	7.34	10.00	53.7
31	73	F	77	1.55	R	5.90	8.06	37.3
32	83	F	75	1.53	R	7.74	14.51	84.1
33	79	M	88	1.85	L	12.80	16.69	151.3
MINIMUM	58.00	H 14	51.00	1.45	R 18	4.87	8.06	33.40
MAXIMUM	83.00	M 19	108.00	1.85	L 15	12.80	16.69	151.30
MEAN	69.58		78.42	1.59		7.10	11.77	62.90
STANDARD DEVIATION	7.391001		12.36434	0.086446		1.430719	2.052747789	22.29646111

Source: File provided by the institution.

quadratic curve adjustment returned an adjusted R2 value of 0.471. The R2 value of this model was 0.71, indicating that 71% of the ACL tibial foveal width variations can be explained by the height variation of the patients. The coefficient values of the quadratic model, all significant at the 5% confidence level, were: $\text{Width} = 107.294 - (133.179 \times \text{height}) + (44.009 \times \text{height squared})$.

Discussion

The main finding of our study was that the width of the ACL tibial fovea found in knees of individuals undergoing TKA was related to the height of the patient. In 45.9% of our initial series, there were macroscopic changes in the normal ACL anatomy or osteophytes around the ligament insertion.

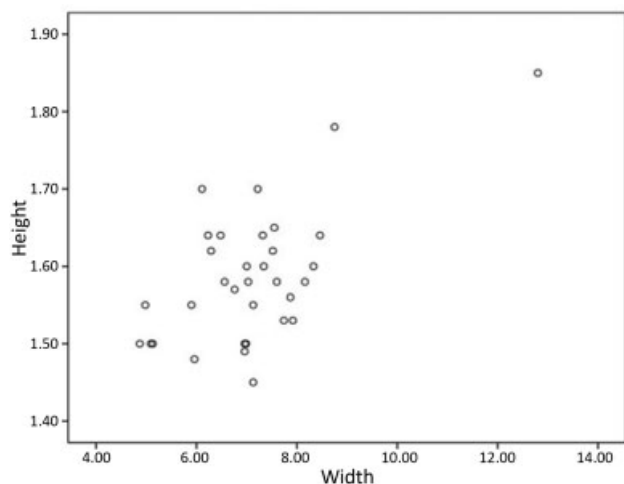


Fig. 2 Relationship between the variables of height and width of the patients and the tibial insertion of the ACL. Source: File provided by the institution.

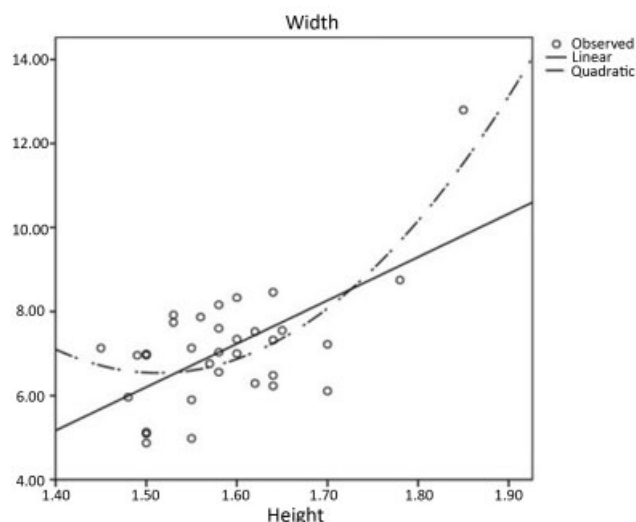


Fig. 3 Quadratic relationship between the variables of height and width of the patients and the ACL tibial insertion. Source: File provided by the institution.

Douglas et al,¹⁵ in 95 patients undergoing TKA, found no ACL in 12% of the patients and macroscopic abnormalities in 45.2% of the subjects. Lee et al¹⁶ evaluated the integrity of the ACL in 107 knees submitted to TKA. In 41 patients (39%) the ligament was deficient at the time of surgery, and 31% of these could remember an episode consistent with an ACL injury or a history of previous instability. To Mullaji et al,¹⁷ 40% of arthritic knees at the time of arthroplasty showed severely degenerated ACLs.

In 27 knees (81.8%) of our sample, the length of the ACL fovea was < 14 mm, and in 28 patients (84.8%) its width was < 8 mm. In our methodology, we resected the tibial portion of the ACL and measured its fovea. This assessment method differed from most studies found in the literature, in which the tibial insertion area of the ACL was measured outlining its periphery, which also includes expansions of its fixation. That is why our measurements are very similar to

those obtained by Purnell et al,⁵ and smaller than those of the other authors. Another possible explanation for our measurements being smaller than those of other authors was that the height of our patients was relatively low ($1.59 \pm 0.08\text{m}$) and, as the ACL fovea width was related to the height of the patients, its measures were also smaller. The comparison between our results and those of other authors, by the various modes of evaluation, is found in ► **Table 3**.^{3-13,18-24}

In fact, Lord et al²⁵ published a study of the function of the ACL tibial insertion fibers in the resistance of anterior and rotational displacements, with robotics, in six degrees of freedom of movement. They concluded that the central, posterior and lateral fibers of the ACL tibial insertion play a secondary role in the restriction of tibial displacements and that the most important fibers are the anterior and the anteromedial peripheral portion. However, we cannot be sure that this happens *in vivo*, given the array of interactions of static and dynamic restrictors responsible for knee stabilization in the various simultaneous three-dimensional movements that happen during the daily activities of the human being.

In our view, the graft is different from the original ligament, so it does not necessarily have to reproduce the same measurements of this ligament, but rather have similar failure force and stiffness to the primary ligament. In our study, the ACL insertion length was 1.64 times the width size, so the latter is the limiting factor in determining the graft diameter to be used.

Hamada et al²⁶ reported that the graft should not cover the entire ligament insertion area, as they have greater mechanical properties than the native ACL and become hypertrophic after implantation. In contrast, LaPrade et al²⁷ believe that the prediction of the width of the ACL tibial insertion has been neglected, and large grafts can damage the roots of the anterior or posterior lateral meniscus.

Our measurements were made on knees of patients during TKA. There was a positive correlation between patient height and ACL tibial foveal width. Kopf et al³ quantified ACL insertion measurements in 137 patients during ACL reconstructions. The mean length of the tibial insertion of the ACL was between 16 and 18 mm in 66.4% of the subjects. There was a significant positive correlation between the weight and height of the patients and the length of the ACL tibial insertion ($p < 0.05$). However, the delimitation of the tibial insertion, in arthroscopy, was made with electrocautery, and measurements were made with a ruler, which can generate a subjectivity bias.

Ichiba et al⁷ evaluated ACL tibial insertion measurements in 100 MRIs of 100 patients, 50 men and 50 women. For these authors, the average length of this insertion in men was 16.1 mm and, in women, 14.3 mm (mean 15.2 ± 1.9 mm). There was a significant correlation between insertion length and weight and height of the patients ($p < 0.05$). The width and tibial insertion area of the ACL were not evaluated by the authors.

Park et al¹² published the results of ACL tibial insertion measurements made in 127 patients during TKA. Measurements were made at the peripheral margin of the ligament insertion. The average length of the ACL tibial insertion was 13.8 mm (10.0–18.0 mm), and the average width was 9.8 mm

Table 3 Description of the various ACL tibial insertion measures, authors, year of publication, reference and method of evaluation

Reference	Length (mm)	Width (mm)	Ratio L/W	Area (mm ²)
Morgan et al. ¹⁸ (1995) ^a	18	10	1.8	NE
Park et al. ¹² (2015) ^a	13.8	9.8	1.4	NE
Park et al. ¹³ (2017) ^a	14.3	10.2	1.4	NE
Tállay et al. ¹⁹ (2008) ^a	19.5 ± 2.6	10.3 ± 1.9	1.89	NE
Kim et al. ¹¹ (2018) ^a	13.8	7.2	1.91	NE
Kopf et al. ³ (2011) ^b	17,0 ± 2,0	AM 9,2 ± 1,1 PL 7,0 ± 1,0	–	NE
Guenther et al. ⁸ (2017) ^b	16.3 ± 1.6	9.7 ± 1.4	1.65	123.8 ± 21.5
Guenther et al. ²⁰ (2017) ^b	16.1 ± 2.6	9.6 ± 1.5	1.67	NE
Edwards et al. ²¹ (2007) ^c	18 ± 2	9 ± 2	2.0	NE
Purnell et al. ⁵ (2008) ^c	10.7 ± 1.3	7.4 ± 1.2	1.44	NE
Ferretti et al. ²² (2012) ^c	18.1 ± 2.8	9 ± 2	2.0	NE
Siebold et al. ²³ (2015) ^c	12.6 ± 2.3	NE	–	110.9 ± 14.7
Fujimaki et al. ²⁴ (2016) ^c	NE	NE	–	175.8 ± 64.3
Tampere et al. ⁶ (2017) ^c	NE	NE	–	159.2
Iriuchishima et al. ⁴ (2015) ^c	NE	NE	–	133.8 ± 31.3
Guenther et al. ⁸ (2017) ^{d,*}	16.6 ± 1.3	10.2 ± 1.0	1.62	132.8 ± 15.7
Guenther et al. ⁸ (2017) ^{d,**}	16.7 ± 1.3	10.4 ± 0.9	1.60	136.7 ± 15.4
Tashiro et al. ⁹ (2017) ^d	15.6 ± 1,8	14.5 ± 2.2	1.07	182.7 ± 41.1
Ichiba et al. ⁷ (2014) ^d	15.2 ± 1.9	NE	–	NA
Araki et al. ¹⁰ (2017) ^d	NE	NE	–	134.7 ± 22.9
Kim et al. ¹¹ (2018) ^a	12.4	8.8	1.40	NA
Araki et al. ¹⁰ (2017) ^e	NE	NE	–	135.2 ± 15.1
Our results ^a	11.7 ± 2.0	7.1 ± 1.4	1.64	151.3 ± 22.29

Abbreviations: AM, anteromedial; NE, not evaluated; PL, posterolateral.

Source: File provided by the institution.

^ain arthroplasties.

^bin arthroscopies.

^cin the dissection of corpses.

^dby magnetic resonance.

^eby laser scan.

*observer 1.

**observer 2.

(6.3–13.5 mm). Tibial length < 14 mm was found in 53.5% of the patients. There was a significant correlation between ACL insertion length and weight and height of the patients. Width was significantly related to weight, but correlation was poor.

In a most recent article, Park et al.¹³ reported prospective data on ACL tibial insertion measurements performed in 209 patients, during TKA, in which the peripheral margins of the ACL insertion were also marked. In this study, the average length of the ACL tibial insertion was 14.3 mm (10.0–19.7 mm), and the average width was 10.2 mm (6.3–13.7 mm). The insertion length was < 14mm in 46.5% of the studied population. The width of the ACL insertion in the tibia was associated with weight by multivariable linear regression.

Our study has some limitations. Although we excluded the knees with macroscopic morphological ligament changes and those with osteophytes around the tibial insertion of

the ACL, the mean age of our population (69.5 years old) is higher than that of individuals who undergo ACL surgical reconstruction. Our sample may be considered small, but it is larger than several previously published studies.^{5,6,22–24} In addition, MANOVA was specifically chosen to interpret the results because we considered the sample small. Finally, all of the measurements were made by a single member of our group, which may be a bias generator, although they were performed twice, and the mean results were used.

Conclusions

The width of the ACL tibial fovea could be predicted by the height of the patients, providing a means to help the surgeon in the choice of the most suitable graft for each patient in ACL reconstructions.

Conflict of Interests

The authors have no conflict of interests to declare.

References

- 1 Mall NA, Chalmers PN, Moric M, et al. Incidence and trends of anterior cruciate ligament reconstruction in the United States. *Am J Sports Med* 2014;42(10):2363–2370
- 2 van Eck CF, Lesniak BP, Schreiber VM, Fu FH. Anatomic single- and double-bundle anterior cruciate ligament reconstruction flow-chart. *Arthroscopy* 2010;26(02):258–268
- 3 Kopf S, Pombo MW, Szczodry M, Irrgang JJ, Fu FH. Size variability of the human anterior cruciate ligament insertion sites. *Am J Sports Med* 2011;39(01):108–113
- 4 Iriuchishima T, Ryu K, Aizawa S, Fu FH. Proportional evaluation of anterior cruciate ligament footprint size and knee bony morphology. *Knee Surg Sports Traumatol Arthrosc* 2015;23(11):3157–3162
- 5 Purnell ML, Larson AI, Clancy W. Anterior cruciate ligament insertions on the tibia and femur and their relationships to critical bony landmarks using high-resolution volume-rendering computed tomography. *Am J Sports Med* 2008;36(11):2083–2090
- 6 Tampere T, Van Hoof T, Cromhecke M, et al. The anterior cruciate ligament: a study on its bony and soft tissue anatomy using novel 3D CT technology. *Knee Surg Sports Traumatol Arthrosc* 2017;25(01):236–244
- 7 Ichiba A, Kido H, Tokuyama F, Makuya K, Oda K. Sagittal view of the tibial attachment of the anterior cruciate ligament on magnetic resonance imaging and the relationship between anterior cruciate ligament size and the physical characteristics of patients. *J Orthop Sci* 2014;19(01):97–103
- 8 Guenther D, Irarrázaval S, Albers M, et al. Area of the tibial insertion site of the anterior cruciate ligament as a predictor for graft size. *Knee Surg Sports Traumatol Arthrosc* 2017;25(05):1576–1582
- 9 Tashiro Y, Lucidi GA, Gale T, et al. Anterior cruciate ligament tibial insertion site is elliptical or triangular shaped in healthy young adults: high-resolution 3-T MRI analysis. *Knee Surg Sports Traumatol Arthrosc* 2018;26(02):485–490
- 10 Araki D, Thorhauer E, Tashman S. Three-dimensional isotropic magnetic resonance imaging can provide a reliable estimate of the native anterior cruciate ligament insertion site anatomy. *Knee Surg Sports Traumatol Arthrosc* 2018;26(05):1311–1318
- 11 Kim SH, Lee HJ, Park YB, Jeong HS, Ha CW. Anterior Cruciate Ligament Tibial Footprint Size as Measured on Magnetic Resonance Imaging: Does It Reliably Predict Actual Size? *Am J Sports Med* 2018;46(08):1877–1884
- 12 Park YB, Song YS, Kim SC, Park YG, Ha CW. The size of tibial footprint of anterior cruciate ligament and association with physical characteristics in Asian females. *Arch Orthop Trauma Surg* 2015;135(07):985–992
- 13 Park YB, Ha CW, Kim HJ, Park YG. Preoperative prediction of anterior cruciate ligament tibial footprint size by anthropometric variables. *Knee Surg Sports Traumatol Arthrosc* 2017;25(05):1638–1645
- 14 Schwartzman S. Fora de foco: diversidade e identidades étnicas no Brasil. *Novos Estud CEBRAP* 1999;55:83–96
- 15 Douglas MJ, Hutchison JD, Sutherland AG. Anterior cruciate ligament integrity in osteoarthritis of the knee in patients undergoing total knee replacement. *J Orthop Traumatol* 2010;11(03):149–154
- 16 Lee GC, Cushner FD, Vigoritta V, Scuderi GR, Insall JN, Scott WN. Evaluation of the anterior cruciate ligament integrity and degenerative arthritic patterns in patients undergoing total knee arthroplasty. *J Arthroplasty* 2005;20(01):59–65
- 17 Mullaji AB, Marawar SV, Simha M, Jindal G. Cruciate ligaments in arthritic knees: a histologic study with radiologic correlation. *J Arthroplasty* 2008;23(04):567–572
- 18 Morgan CD, Kalman VR, Grawl DM. Definitive landmarks for reproducible tibial tunnel placement in anterior cruciate ligament reconstruction. *Arthroscopy* 1995;11(03):275–288
- 19 Tállay A, Lim MH, Bartlett J. Anatomical study of the human anterior cruciate ligament stump's tibial insertion footprint. *Knee Surg Sports Traumatol Arthrosc* 2008;16(08):741–746
- 20 Guenther D, Irarrázaval S, Nishizawa Y, et al. Variation in the shape of the tibial insertion site of the anterior cruciate ligament: classification is required. *Knee Surg Sports Traumatol Arthrosc* 2017;25(08):2428–2432
- 21 Edwards A, Bull AM, Amis AA. The attachments of the anteromedial and posterolateral fibre bundles of the anterior cruciate ligament: Part 1: tibial attachment. *Knee Surg Sports Traumatol Arthrosc* 2007;15(12):1414–1421
- 22 Ferretti M, Doca D, Ingham SM, Cohen M, Fu FH. Bony and soft tissue landmarks of the ACL tibial insertion site: an anatomical study. *Knee Surg Sports Traumatol Arthrosc* 2012;20(01):62–68
- 23 Siebold R, Schuhmacher P, Fernandez F, et al. Flat midsubstance of the anterior cruciate ligament with tibial “C”-shaped insertion site. *Knee Surg Sports Traumatol Arthrosc* 2015;23(11):3136–3142
- 24 Fujimaki Y, Thorhauer E, Sasaki Y, Smolinski P, Tashman S, Fu FH. Quantitative In Situ Analysis of the Anterior Cruciate Ligament: Length, Midsubstance Cross-sectional Area, and Insertion Site Areas. *Am J Sports Med* 2016;44(01):118–125
- 25 Lord BR, El-Daou H, Zdanowicz U, Śmigielski R, Amis AA. The role of fibres within tibial attachments of the ACL in resisting tibial displacements. *Knee* 2017;24(06):12
- 26 Hamada M, Shino K, Horibe S, Mitsuoka T, Toritsuka Y, Nakamura N. Changes in cross-sectional area of hamstring anterior cruciate ligament grafts as a function of time following transplantation. *Arthroscopy* 2005;21(08):917–922
- 27 LaPrade CM, Smith SD, Rasmussen MT, Hamming MG, Wijdicks CA, Engebretsen L, et al. Consequences of tibial tunnel reaming on the meniscal roots during cruciate ligament reconstruction in a cadaveric model, Part 1: The anterior cruciate ligament. *Am J Sports Med* 2015;43(01):200–206