

# A Novel Technique for Cervical Microscopic Foraminotomy Utilizing Spinous Process Splitting: Microscopic Mini-Open Foraminotomy

Shota Ikegami, Masashi Uehara, Yoshinari Miyaoka, Shugo Kuraishi, Hiroki Oba, Ryo Munakata, Takashi Takizawa, Takayuki Kamanaka, Terue Hatakenaka and Jun Takahashi

*Department of Orthopaedic Surgery, Shinshu University School of Medicine, Matsumoto, Japan*

## Abstract:

**Introduction:** In this study, we present “microscopic mini-open foraminotomy (MicroMOF)” as a new, less invasive method for posterior cervical foraminotomy.

**Technical Note:** Using surgical microscope guidance, the spinous process is hemi-split, and the posterior muscle is detached from the lamina subperiosteal surface. Bony resection is then performed obliquely from medial posterior to lateral anterior under lateral-tilted surgical field exposure. MicroMOF has been performed successfully for cervical radiculopathy and cervical spondylotic amyotrophy, which achieved postoperative symptom improvement with few complications.

**Conclusions:** The novel MicroMOF foraminotomy technique has been found to protect the nerve root and vertebral artery and help preserve muscle and cervical facet joint bone.

## Keywords:

foraminotomy, cervical spondylotic amyotrophy, cervical radiculopathy, microscopic surgery, minimally invasive surgery

Spine Surg Relat Res 2021; 5(6): 431-436

dx.doi.org/10.22603/ssrr.2021-0055

## Introduction

Cervical nerve root decompression by posterior cervical foraminotomy has already been widely used for cervical foraminal lesions, including cervical radiculopathy and cervical spondylotic amyotrophy (CSA)<sup>1,2)</sup>.

There is a long history of attempts in making foraminotomy less invasive. Decompression using a small-skin incision intramuscular approach with a micro-endoscope has been reported<sup>3,4)</sup>. While good outcomes have been reported, the technique requires time to master. Takahashi et al. also reported favorable results for small-skin incision surgery using a tubular retractor, a technique referred to as the “mini-open foraminotomy (MOF).”<sup>5)</sup> Uehara et al. later modified the procedure to include a blade retractor<sup>6)</sup>. There are also reports of foraminotomy using a surgical microscope<sup>7,8)</sup>. Further, Shiraishi et al. developed an intermuscular approach to the cervical facet joint for foraminotomy<sup>9)</sup>.

Temporary worsening of neurological symptoms may occur after foraminotomy, possibly from technical issues. Since 2017, we have been performing a modified version of

MOF, called “microscopic MOF (MicroMOF),” for patients with cervical radiculopathy and CSA. In this present report, we describe the lower invasiveness, safety, and adequate decompression of this technique for posterior foraminotomy.

## Technical Note

Intraoperative patient position for MicroMOF is the same as that for conventional posterior cervical spine surgery, with the patient in the prone position on the hall frame and secured to the operating table by skull clamps. The operator then stands on the contralateral side of the decompression.

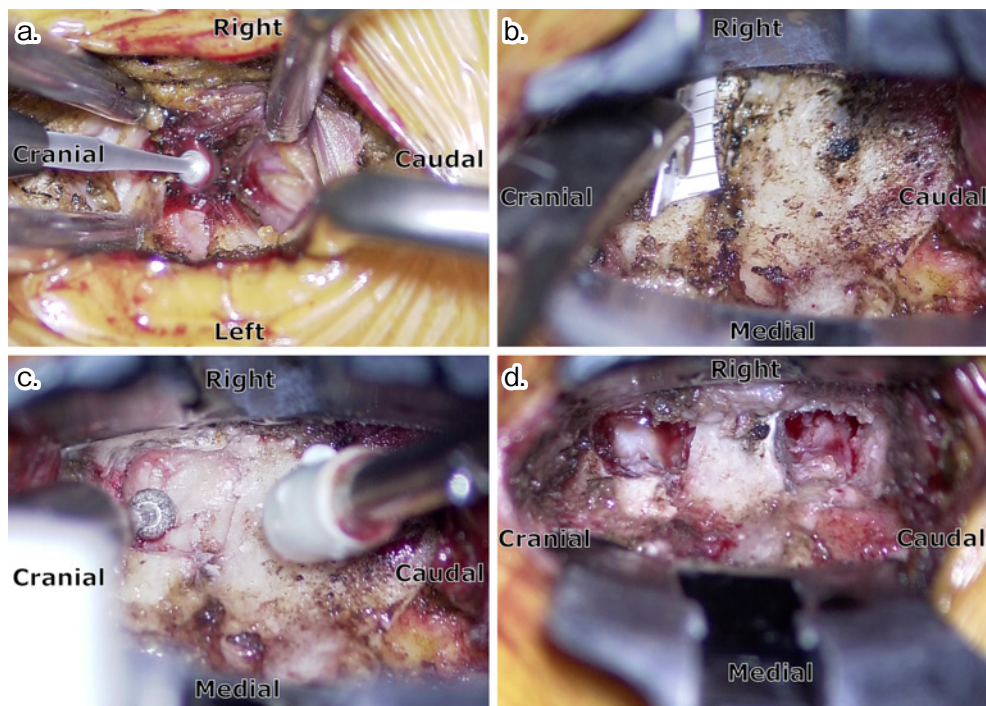
A skin incision is made on the midline between the spinous processes (SPs) surrounding the decompression intervertebral levels. The length of the incision can vary, depending on the size of the retractor; an incision of less than 4 cm is sufficient for a two-intervertebral level case.

Unilateral exposure is performed with the assistance of a surgical microscope in accordance with the SP splitting in Shiraishi skip laminectomy<sup>10)</sup>. The nuchal ligament is divided by the midline. The division reaches the tops of the

Corresponding author: Shota Ikegami, sh.ikegami@gmail.com

Received: March 16, 2021, Accepted: May 21, 2021, Advance Publication: June 30, 2021

Copyright © 2021 The Japanese Society for Spine Surgery and Related Research



**Figure 1.** The decompression procedure.

*Notes:* a. spinous process splitting; b. setting of decompression entry; c. bone resection with a high-speed drill; d. after decompression (two-level case).

SPs of the decompression intervertebral level. Kelly or Pean forceps are generally used for dividing tissue; however, electrocautery may be used judiciously in difficult cases. The SP to be split is on the cranial side of the decompression intervertebral level. Two Shiraishi retractors (modified Gelpi self-retaining retractors with blunt-ended arms)<sup>9)</sup> are then each inserted between the right/left interspinous muscles of the cranial and caudal sides of the split SP. A high-speed drill of 2-3 mm diameter is used to midline split the SP. Only the decompression side process is separated from the base (Fig. 1a). The supralaminar muscles are then detached under the periosteum to the middle of the facet joint. On the caudal side of the lamina, the muscle is attached to the bone and thus requires dissection using electrocautery. After exposure, the retractors are changed. A tip fan-out retractor is fit in this procedure. The surgical microscope should be placed so that it looks obliquely into the decompression side from the contralateral side.

The size and location of the decompression entry point on the facet joint should be planned in advance via computed tomography (CT). A 6-8-mm small square is common (Fig. 1b). The entry point for decompression should not reach beyond half of the lateral mass in order to preserve facet joint stability. A 3-4 mm diameter high-speed drill is used to carefully remove the inferior and superior articular processes for locating the deep part (Fig. 1c). The medial bone is generally thinner, while the lateral bone is thicker at the facet joint resection site in foraminotomy, which are more pronounced in this technique since the decompression direction is oblique. Accordingly, the decompression depth in the lat-

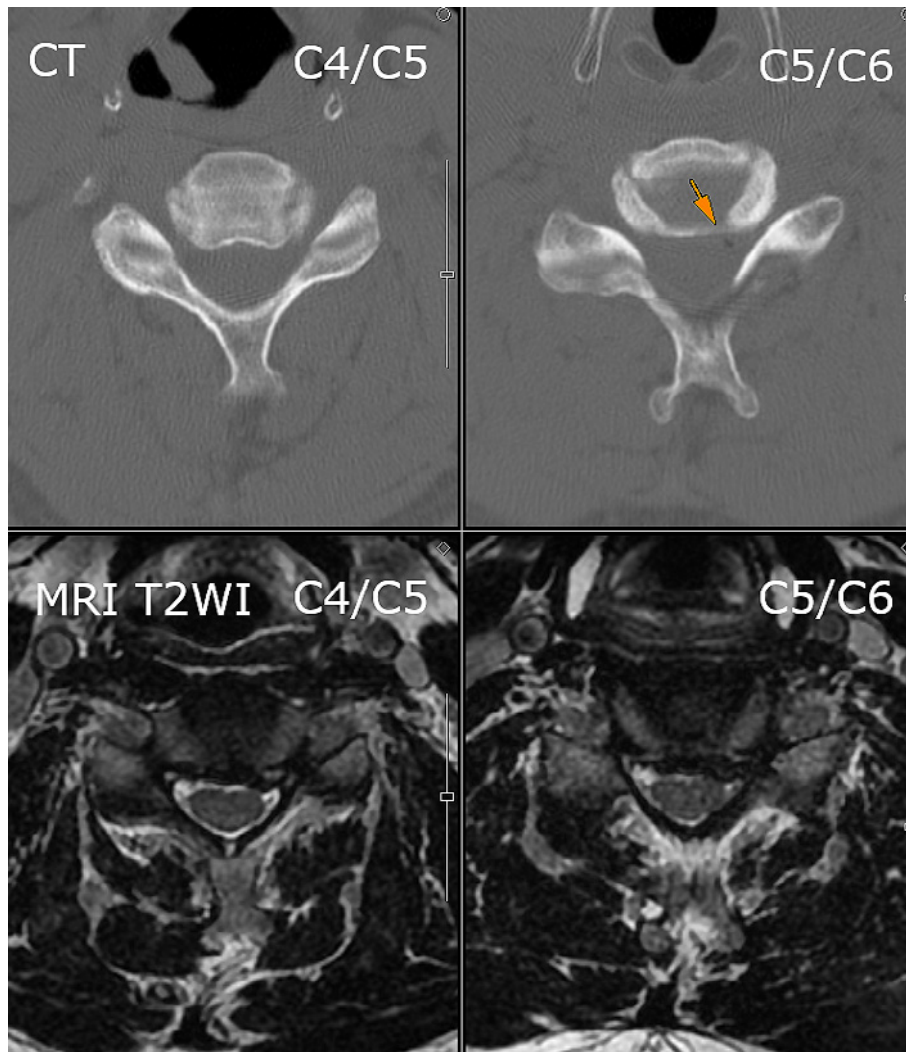
eral direction often exceeds 10 mm. The edge of the drill osteotomy is then trimmed with a small curette. Decompression is sufficient in the cranial-caudal direction when the upper and lower vertebral pedicles can be touched with a probe. In the lateral direction, decompression is adequate when a small probe can be easily inserted between the bone and nerve root. The capsule of the nerve root can be spared if the dorsal bone of the nerve root is sufficiently resected (Fig. 1d).

Hemostasis should be checked thoroughly, with suction drainage ideally placed in the epidural space. The transected SP is then sutured to the nontransected SP. Postoperative treatment is the same as that after general cervical decompression surgery. Mobility without a collar can be possible the day after surgery, with hospitalization for approximately 1 week.

## Case Presentations

### Case 1

A 46-year-old man in the demolition industry noticed difficulty bending his left elbow 2 years before surgery. He was under observation by his physician for a C5/C6 foramen disorder 6 months preoperatively. He then became unable to raise his left upper arm 1 month before surgery. Manual muscle testing (MMT) showed a decrease in deltoid and bicep muscles to 2 and 3, respectively. Magnetic resonance imaging (MRI) revealed disc bulges in the left cervical foramen at C4/C5 and C5/C6 (Fig. 2). CT showed that



**Figure 2.** Preoperative CT and MRI of case 1.

*Notes:* Orange arrow indicates disc herniation including gas.

*Abbreviations:* CT, computed tomography; MRI T2WI, T2-weighted magnetic resonance imaging.

the C5/C6 bulge contained gas. MicroMOF for the C4/C5 left side was performed for a ventral root disorder of the left C5 nerve root due to disc herniation (Fig. 3). The C5/6 left side was also decompressed, as it was previously symptomatic. Intraoperative bleeding was negligible, but with no complications postoperatively. MMT scores were observed to improve by one level immediately after surgery and were almost normal 6 months afterward.

### Case 2

A 59-year-old male truck driver experienced left upper extremity pain 2 years prior to surgery. His left ring and little fingers were numb, with chronic pain in the ulnar left hand, forearm, and upper arm. As per his CT, narrowing of the C7/T1 left foramen was determined, which could be due to osteophyte formation in the uncovertebral joint (Fig. 4). He was then diagnosed as having left C8 radiculopathy. After unsuccessful conservative treatment, he underwent MicroMOF for the C7/T1 left side (Fig. 5). No remarkable

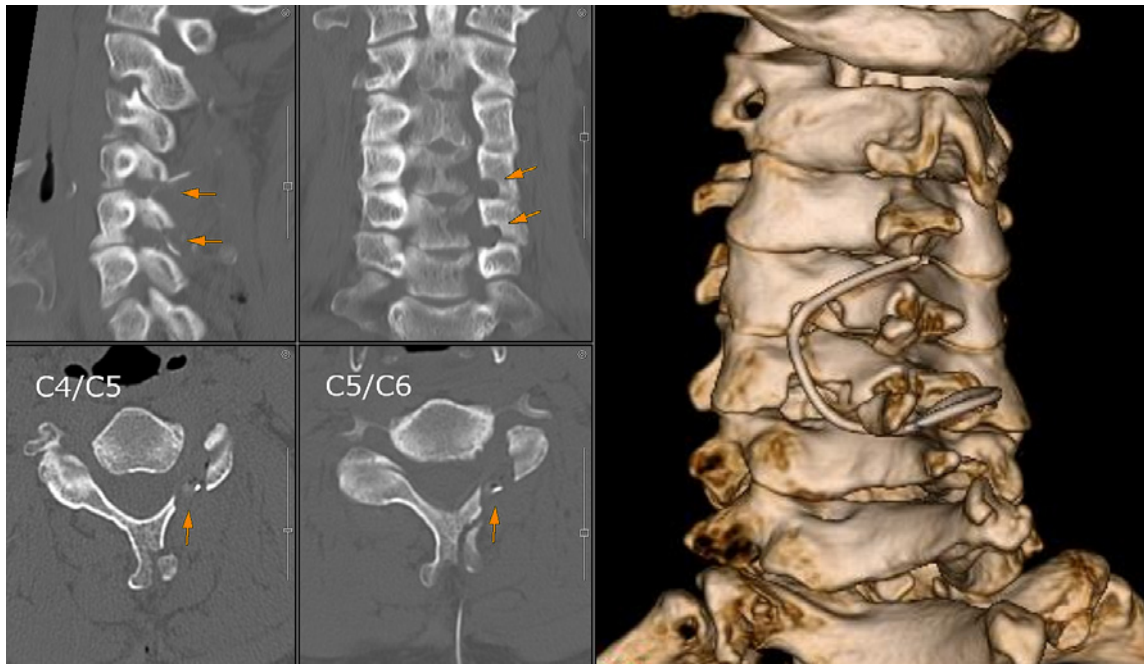
bleeding or postoperative complications were noted. His left upper limb pain and numbness disappeared immediately after surgery.

### Discussion

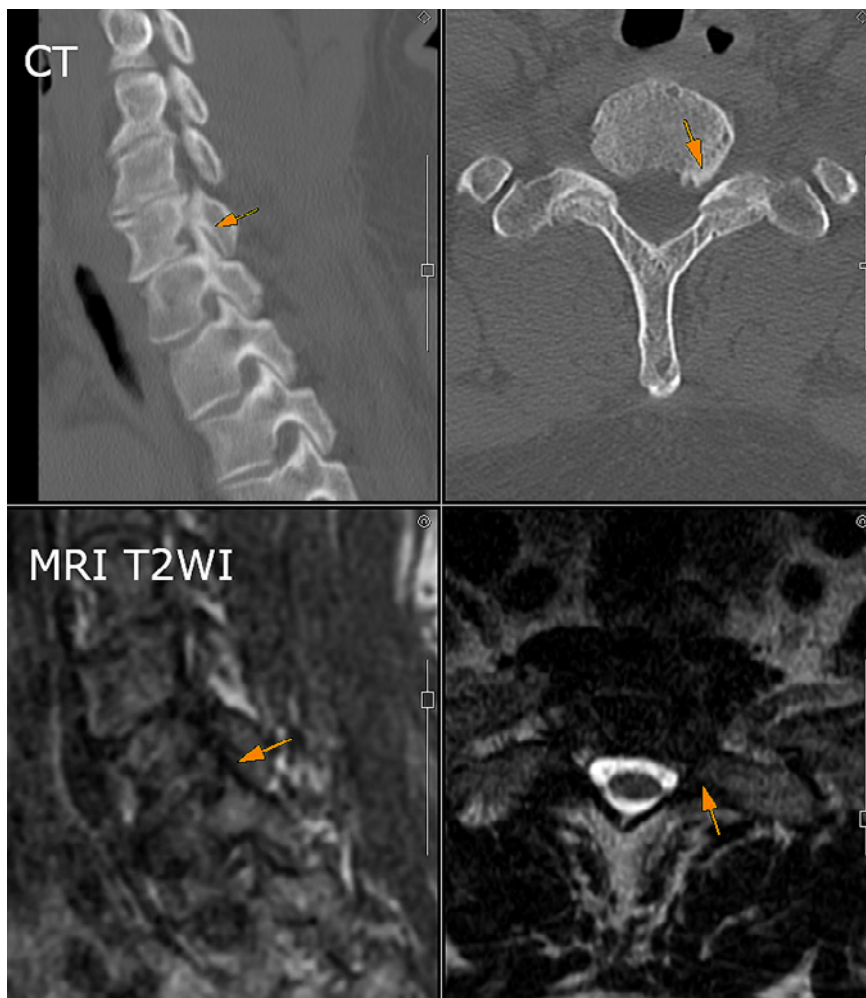
Conceived and developed by Shiraishi, SP splitting in the skip laminectomy procedure is described as an epoch-making method achieving minimally invasive posterior decompression of the spinal cord from an approach different from that of endoscopy that can preserve muscle attachment on bone. A surgical microscope ensures a clear surgical field<sup>10</sup>. In our development of MicroMOF, we aimed to perform contralateral oblique decompression on the back of the nerve root in posterior foraminotomy. Shiraishi's hemi-splitting of SPs and use of a microscope have helped achieve this goal.

There are two main routes to reach the decompression area in posterior foraminotomy: (1) dissect and retract later-

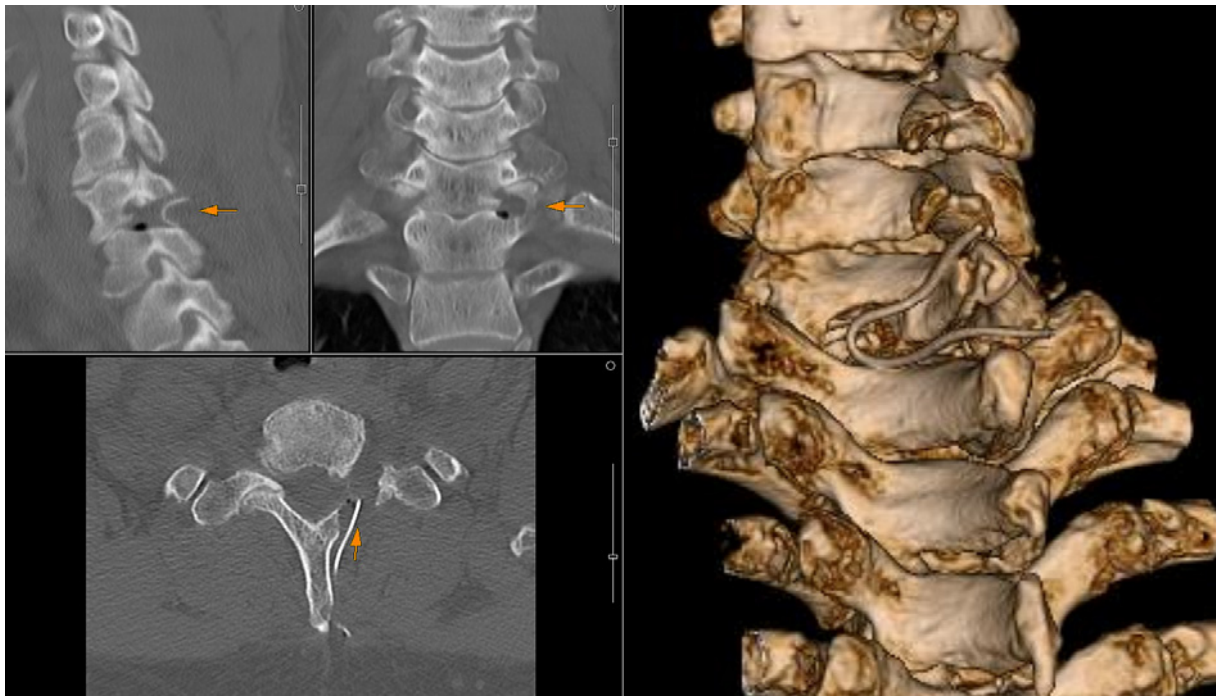




**Figure 3.** Postoperative CT of case 1.  
*Notes:* Orange arrows indicate decompressed hole.

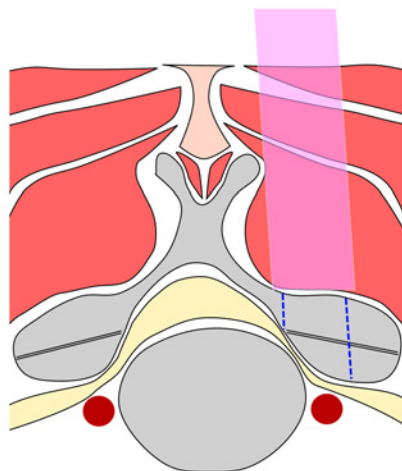


**Figure 4.** Preoperative CT and MRI of case 2.  
*Notes:* Orange arrows indicate narrowing foramen.  
*Abbreviations:* CT, computed tomography; MRI T2WI, T2-weighted magnetic resonance imaging.

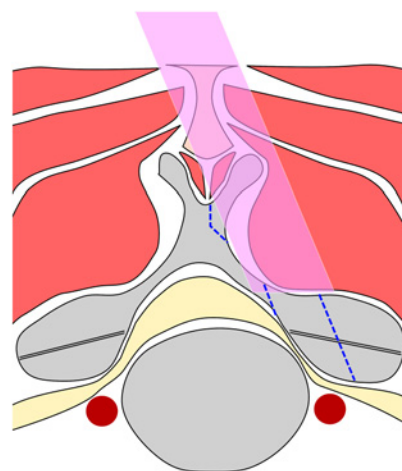


**Figure 5.** Postoperative CT of case 2.  
*Notes:* Orange arrows indicate decompressed hole.

**a. Paramedian approach and P-A decompression**



**b. Median approach and oblique decompression**



**Figure 6.** Difference in decompression direction between the paramedian approach and the median oblique MicroMOF approach.

*Notes:* Most minimally invasive procedures, such as endoscopic surgery, use a paramedian approach. An oblique approach enables both lateral decompression and bone preservation, and the direction of force during bone resection is away from the direction of nerve root pushing.

ally the posterior muscle along the vertebral lamina from the midline and (2) incise paravertebrally and directly reach the decompression point intramuscularly. While the former is less prone to disorientation, it tends to require larger dissection to fully retract laterally. Meanwhile, the latter has the opposite characteristics and additionally requires more attention to bleeding due to intramuscular penetration. Our MicroMOF is categorized as the former route, but the retrac-

tion is in the dorsolateral direction, making it easier to obtain a good field of view with reduced muscle dissection and bony exposure. Minimizing electrocautery in muscle dissection can also result in less damage. Meanwhile, the surgical microscope enables bright and clear exposure during surgery.

MicroMOF is advantageous since it allows decompression along the nerve root by creating an oblique surgical field.

Hemi-splitting the cervical SP, which has a large horizontal width, has a considerable effect in directing the surgical field laterally. Normally, the surgical field is set from directly above the decompression point, with the decompression direction toward the nerve root (Fig. 6a). In MicroMOF, however, decompression is directed laterally toward the dorsal side of the nerve root (Fig. 6b), which, in turn, reduces the possibility of injuring the nerve root or vertebral artery. Whereas large bone resection behind the nerve root may create facet joint instability, lateral oblique decompression facilitates preservation of facet joint bone.

The main disadvantage of MicroMOF is fracture risk of the residual SP. In one of our cases, the remaining C7 SP fractured on the second postoperative day, although pain was minimal and the postoperative course was good. When splitting the long and thin C6 or C7 SPs, it is important to avoid a large or deep split, making sure to remove only the small fragment of bone attached to the muscle and ligament from the tip of the SP. Obtaining an oblique surgical field there may be challenging. Removing ventral disc hernias and osteophytes with this procedure is not recommended due to the risk of nerve root injury and epidural bleeding. Anterior surgery options may be considered if the ventral components are to be securely resected. Another barrier to adoption for MicroMOF is a need for familiarity with microscopic techniques. For three-dimensional decompression in an oblique surgical field, adequate preoperative decompression planning by CT or other means is required as well. Wider exposure is advised in the early stages of MicroMOF adaptation toward decompression with the minimum exposure necessary.

In conclusion, MicroMOF is a novel technique for posterior cervical foraminotomy that incorporates a surgical microscope to hemi-split the SP and perform oblique decompression behind the nerve root. This method thus minimizes damage to the posterior muscles and easily preserves cervical facet joint bone.

**Conflicts of Interest:** The authors declare that there are no relevant conflicts of interest.

**Sources of Funding:** None.

**Author Contributions:** SI devised the surgical procedure

and wrote the report. MU, YM, SK, HO, RM, TT, TK, and TH provided practical advice for improving the surgical procedure. JT developed the technique serving as the basis of this procedure and gave advice prior to each procedure. All authors have approved the contents of the report.

**Ethical Approval:** None as this report is a technical note, not a clinical study.

## References

1. Frykholm R. Cervical nerve root compression resulting from disc degeneration and root sleeve fibrosis. *Acta Chir Scand.* 1951;160:1-149.
2. Scoville WB. Cervical spondylosis treated by bilateral facetectomy and laminectomy. *J Neurosurg.* 1961;18:423-8.
3. Adamson TE. Microendoscopic posterior cervical laminoforaminotomy for unilateral radiculopathy: results of a new technique in 100 cases. *J Neurosurg (spine).* 2001;95(1 Suppl):51-7.
4. Fessler RG, Khoo LT. Minimally invasive cervical microendoscopic foraminotomy: an initial clinical experience. *Neurosurgery.* 2002;51(5 Suppl):S37-45.
5. Takahashi J, Aoki K, Ogihara N, et al. Mini open foraminotomy (MOF) for cervical radiculopathy: technical note. *Open Spine J.* 2009;1:1-4.
6. Uehara M, Takahashi J, Kuraishi S, et al. Mini open foraminotomy for cervical radiculopathy: a comparison of large tubular and trimline retractors. *Asian Spine J.* 2015;9(4):548-52.
7. Boehm H, Greiner-Perth R, El-Saghir, et al. A new minimally invasive posterior approach for the treatment of cervical radiculopathy: surgical technique and preliminary results. *Eur Spine J.* 2003;12(3):268-73.
8. Furukawa M, Kamata M, Kuramoto T, et al. Surgical results of microscopic cervical foraminotomy for cervical radiculopathy presenting drop finger and proposal of classification based on drop finger patterns. *Spine Surg Relat Res.* 2020;4(1):23-30.
9. Shiraishi T. A new technique for exposure of the cervical spine laminae. Technical note. *J Neurosurg.* 2002;96(1 Suppl):122-6.
10. Shiraishi T. Skip laminectomy--a new treatment for cervical spondylotic myelopathy, preserving bilateral muscular attachments to the spinous processes: a preliminary report. *Spine J.* 2002;2(2):108-15.

Spine Surgery and Related Research is an Open Access journal distributed under the Creative Commons Attribution-NonCommercial-NoDerivatives 4.0 International License. To view the details of this license, please visit (<https://creativecommons.org/licenses/by-nc-nd/4.0/>).