



Case report

Axial flap for giant basal cell carcinoma of the anterior chest wall: Case report



Monica Bellynda^a, Andhika Aji Nugroho^a, Affandi Wiramur^b, Kristanto Yuli Yarso^{c,*}

^a Department of General Surgery, Faculty of Medicine, Universitas Sebelas Maret, Indonesia

^b Department of Plastic Reconstructive and Aesthetics Surgery, Faculty of Medicine, Universitas Sebelas Maret, Indonesia

^c Department of Oncology Surgery, Faculty of Medicine, Universitas Sebelas Maret, Indonesia

ARTICLE INFO

Keywords:

Giant basal cell carcinoma
Anterior chest wall mass
Axial flap
Case report

ABSTRACT

Introduction and importance: Anterior chest wall Giant Basal Cell Carcinoma (GBCC) is rare amongst GBCC cases and results in a large defect that is challenging to resect and reconstruct. It requires multidisciplinary approach to prevent recurrence.

Case presentation: A 72-year-old man with giant basal cell carcinoma at the anterior chest wall measuring 10 × 6 cm. Wide resection of 1 cm margin with axial flap was performed to close the defect. The follow-up report stated that the patient was satisfied with the result and there was no recurrence observed.

Clinical discussion: Review of literatures concludes that GBCC is excised with a minimum of 4-6 mm margin outside the tumor area. The axial IMAP flap is ideal to close the upper chest wall defect because of the better aesthetic outcome compared to other conventional flaps, especially in stable elderly male, patients with noninfected wound. Increased skin laxity and more relaxed skin tension associated with aging allows easier tissue mobilization and transfer to close the defect.

Conclusion: Axial flap for GBCC in anterior chest wall is ideal, safe, and has the advantage of aesthetic reasons of suitable skin tone, particularly for stable elderly male patients.

1. Introduction

Skin cancer is one of the most common cancers in the world and consists of melanoma and non-melanoma skin cancer (NMSC). Basal Cell Carcinoma (BCC) is a slow-growing skin malignancy. Metastasis is rare in BCC, which is treated by excision of the tumor tissue area with a safe margin of 4–6 mm under microscopic control [1–4]. GBCC is a basal cell cancer measuring more than 5 cm. GBCC is malignant, fast-growing, and may cause metastasis. GBCC located in the anterior chest wall is rare. GBCC therapy requires multidisciplinary approach to prevent recurrences and to achieve aesthetic result [5–7]. This study has been reported in accordance with the SCARE criteria and a written informed consent was taken from the patient for publication of this writing and images [8].

2. Presentation of case

We present a case of a 72-year-old Javanese man presented to the oncology clinic with a lump on his chest that has developed for the past

7 years. Initially, the lump was black-colored with a size of a marble. It was painless but itchy. He reported no history of smoking or alcohol consumption. No genetic and syndromic abnormalities, drug allergies, previous surgical history were reported. The physical examination revealed an ulcerating mass with a size of 10 × 6 cm on the anterior chest wall with an uneven surface and irregular edges that bleed easily (Fig. 1).

A chest CT scan with contrast was performed, with the result of malignant soft tissue mass on the anterior chest wall attached to the body of the sternum without any bone destruction (Fig. 2). To confirm the diagnosis, we took a biopsy examination that identified the lump as a BCC with nodular and infiltrative type. The patient then planned to have a tumor resection and reconstruction by surgical oncologist and plastic surgeon. A wide tumor resection with 1 cm margin was done, leaving a bony and soft tissue defect with a size of 12 × 7 cm (Fig. 3). The specimen was then sent to the pathologist to ensure that the margin was tumor-free.

The defect was reconstructed with tension-free internal mammary artery perforator (IMAP) axial flap from the second and third intercostal

* Corresponding author at: Universitas Sebelas Maret, Jl. Ir Sutami 36, Kentingan, Jebres, Surakarta 57126, Central Java, Indonesia.

E-mail address: yarsaonko@gmail.com (K.Y. Yarso).

<https://doi.org/10.1016/j.ijscr.2021.106154>

Received 8 May 2021; Received in revised form 27 June 2021; Accepted 27 June 2021

Available online 29 June 2021

2210-2612/© 2021 The Authors. Published by Elsevier Ltd on behalf of IJS Publishing Group Ltd. This is an open access article under the CC BY-NC-ND license

(<http://creativecommons.org/licenses/by-nc-nd/4.0/>).

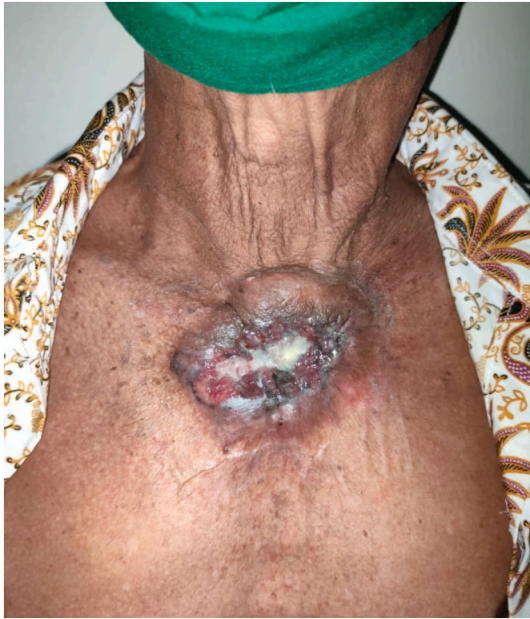

Fig. 1. Preoperative view of necrotizing mass on anterior chest wall.

pedicle arteries. Then, the flap was depicted with an elliptical line and a central axis in a horizontal flap position, parallel to the ribs. A flap of 5–8 cm was required for primary closure of the donor site. The medial half of the superior incision was made to the fascia until the perforator vessels appeared then the remaining flaps were re-incised and rotated to cover the defect. The viability of the distal part of the flap was confirmed by bleeding from the margins. The patient was followed up three months and one year post operatively. There was no new lesion and the patient was satisfied with the result (Fig. 4).

3. Discussion

The principle of treatment in cases of BCC is surgery without adjuvant therapy [9]. The ideal surgery for BCC is to do wide resection with safety margin under microscopic control [10]. The National Comprehensive Cancer Network (NCCN) guidelines categorized BCC as low and high risks based on the histological subtype, size, and risk of recurrence. For well-defined, low-risk tumors, the NCCN recommends 4-mm margins to achieve a complete excision rate of 95% whereas, for high-risk lesions, 4 to 6-mm margins are suggested [11].

This patient sought for medical advice after a 7-year history of a growing mass in his chest. He worked as a farmer and lived in a farmhouse in a rural area, had a low income, and had no formal education. Low educational level, economic condition, and residence location was the main reason why he had neglected the mass and delayed searching

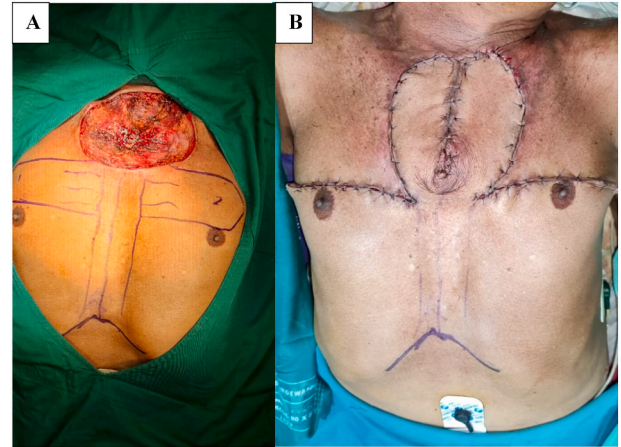


Fig. 3. Intraoperative view showing excision of the mass 1 cm from the margin (A) and axial flap was used to close the defect (B).

for medical care. Other studies also reported the same factors that lead people not to seek medical advice [12,13].

Perforator flap technique has the advantage on bony-base defect closure. Cases of large defect on anterior chest wall defect closure and breast reconstruction with IMAP flap have been noted [14]. The axial IMAP flap has an advantage in its ability to reconstruct the entire length of the sternum and upper anterior chest wall compared to conventional flaps such as pectoralis major, rectus, and omental flaps. It is also ideal in male and elderly patients with noninfected wound. Increased skin laxity and more relaxed skin tension associated with aging allow easier tissue mobilization and transfer to close the defect [15].

4. Conclusion

GBCC requires comprehensive and multidisciplinary approach to excise the mass and reconstruct the wide defect. The use of axial IMAP flap, especially in stable elderly male patient is ideal for anterior chest wall reconstruction. It has the advantage of aesthetic reasons of suitable skin tone than other donor sites for flaps. It is also safe and results from this patient showed no recurrence.

Guarantor

Monica Bellynda

Sources of funding

This research did not receive any specific grant from funding agencies in the public, commercial, or not-for-profit sectors.

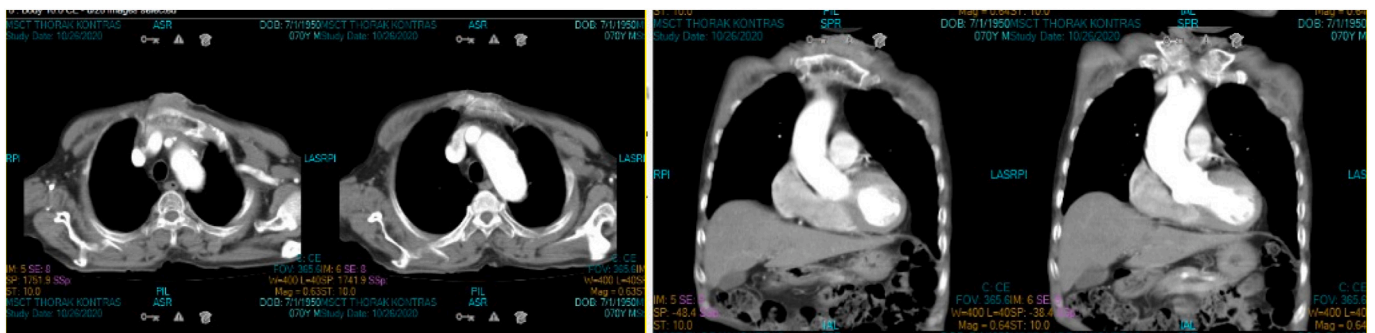


Fig. 2. Thoracic CT Scan with contrast showed a mass on anterior chest wall.

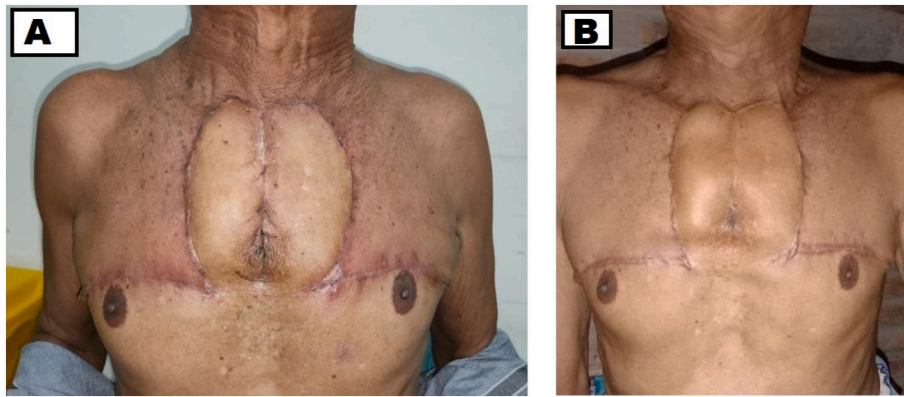


Fig. 4. Patient followed up 3 months postoperatively (A) and one year post operatively (B). There was no new lesion and the patient was satisfied with the result.

Ethical approval

This type of study does not require any ethical approval by our institution.

Consent

Written informed consent was obtained from the patient for publication of this case report and accompanying images. A copy of the written consent is available for review by the Editor-in-Chief of this journal on request.

Research registration

Not applicable. This is not a clinical trial or 'First in Man' study.

Provenance and peer review

Not commissioned, externally peer-reviewed.

CRediT authorship contribution statement

Monica Bellynda, Andhika Aji Nugroho, Affandi Wiramur, Kristanto Yuli Yarso: study concept, surgical therapy for this patient.

Monica Bellynda, Andhika Aji Nugroho: Data Collection, Writing Original draft preparation.

Affandi Wiramur, Kristanto Yuli Yarso: Senior author and the manuscript reviewer.

Monica Bellynda, Andhika Aji Nugroho: Editing – Writing.

All authors read and approved the final manuscript.

Declaration of competing interest

The authors declare no conflict of interest.

References

- [1] L.M. Nystrom, C.P.J. Gibbs, D. Singhal, C.T.J. Klodell, Giant basal cell carcinoma of the anterior chest wall with bone invasion, *Eur. J. Cardio-Thoracic Surg. Off. J. Eur. Assoc. Cardio-Thoracic Surg.* 45 (2014) 945–946, <https://doi.org/10.1093/ejcts/ezt416>.
- [2] L.F. Dwita, A. Hafiz, Modified cervicofacial flap for temporal region reconstruction post basal cell carcinoma excision, *Oto Rhino Laryngol. Indones.* 51 (2020) 167–173, <https://doi.org/10.32637/orli.v50i2.325>.
- [3] A. Newman, D. Ventarola, J. To, Necrotic chest wall mass: atypical presentation of giant basal cell carcinoma, *Am. Surg.* 86 (2020) 1556–1558, <https://doi.org/10.1177/0003134820934422>.
- [4] N.A. Elshamma, A. Al Qabbani, H.M. Alkatan, M.M. Al-Qattan, The use of forehead flaps in the management of large basal cell carcinomas of the medial canthus/medial lower eyelid in Saudi patients, *Saudi J. Ophthalmol. Off. J. Saudi Ophthalmol. Soc.* 27 (2013) 223–225, <https://doi.org/10.1016/j.sjopt.2013.07.005>.
- [5] P.J.F. Santos, C. Prendergast, A. Leis, Giant anterior chest wall basal cell carcinoma: an approach to palliative reconstruction, *Case Rep. Oncol. Med.* (2016) 5067817, <https://doi.org/10.1155/2016/5067817>.
- [6] M.-A. Yazdani Abyaneh, P. Engel, A. Slominski, B. Ragsdale, R. Agag, D. Cramer, J. A. Carlson, Giant basal cell carcinomas express neuroactive mediators and show a high growth rate: a case-control study and meta-analysis of etiopathogenic and prognostic factors, *Am. J. Dermatopathol.* 39 (2017) 189–194, <https://doi.org/10.1097/DAD.0000000000000640>.
- [7] M.R. Vaca-Aguilera, E. Guevara-Gutiérrez, J.G. Barrientos-García, A. Tlacuilo-Parra, Giant basal cell carcinoma: clinical-histological characteristics of 115 cases, *Int. J. Dermatol.* 58 (2019) 1430–1434, <https://doi.org/10.1111/ijd.14455>.
- [8] R.A. Agha, T. Franchi, C. Sohrabi, G. Mathew, A. Kerwan, The SCARE 2020 guideline: updating consensus Surgical CAse REport (SCARE) guidelines, *Int. J. Surg.* 84 (2020) 226–230, <https://doi.org/10.1016/j.ijssu.2020.10.034>.
- [9] K. Djawad, E. Arisandi, A.R. Nuridin, S. Wahab, in: *Combination of Advancement and Rotation Flap for Large Defect Closure of Basal Cell Carcinoma on the Cheek, Lip and Nose Vol.* 3943, 2020, pp. 3939–3943.
- [10] A.N.B. Kauvar, T.J. Cronin, R. Roenigk, G. Hruza, R. Bennett, Consensus for nonmelanoma skin cancer treatment: basal cell carcinoma, including a cost analysis of treatment methods, *Dermatologic Surg. Off. Publ. Am. Soc. Dermatologic Surg.* 41 (2015) 550–571, <https://doi.org/10.1097/DSS.0000000000000296>.
- [11] C.K. Bichakjian, T. Olencki, S.Z. Aasi, M. Alam, J.S. Andersen, D. Berg, G. M. Bowen, R.T. Cheney, G.A. Daniels, L.F. Glass, R.C. Grekin, K. Grossman, S. A. Higgins, A.L. Ho, K.D. Lewis, D.D. Lydiatt, K.S. Nehal, P. Nghiem, E.A. Olsen, C. D. Schmultz, A. Sekulic, A.R. Shaha, W.L. Thorstad, M. Tuli, M.M. Urist, T.S. Wang, S.L. Wong, J.A. Zic, K.G. Hoffmann, A. Engh, Basal cell skin cancer, version 1.2016, NCCN Clinical Practice Guidelines in Oncology, *J. Natl. Compr. Canc. Netw.* 14 (2016) 574–597, <https://doi.org/10.6004/jnccn.2016.0065>.
- [12] E. Varga, I. Korom, Z. Raskó, E. Kis, J. Varga, J. Oláh, L. Kemény, Neglected basal cell carcinomas in the 21st century, *J. Skin Cancer.* 2011 (2011) 392151, <https://doi.org/10.1155/2011/392151>.
- [13] K. Bin Siddique, S. Khan, S. Haque, M.I. Sizear, A. Alam, M. Haque, Socioeconomic status & health seeking behavior of rural people: a cross sectional study in Fatikchori, Chittagong, *MOJ Public Heal.* 4 (2016).
- [14] M. Bellynda, K.Y. Yarsa, Breast sharing flap: a serial case, *Int. Med. J.* 25 (2020) 3039–3043.
- [15] R.Y. Kannan, The internal mammary artery perforator flap and its subtypes in the reconstruction of median sternotomy wounds, *J. Thorac. Cardiovasc. Surg.* 152 (2016) 264–268, <https://doi.org/10.1016/j.jtcvs.2016.01.053>.