



# Feasibility and Morbidity for the Use of MR-Guided Laser-Induced Thermotherapy for the Treatment of Skull Base Tumors: A Report of Three Cases

Jesse D. Lawrence<sup>1</sup> Robert Marsh<sup>1</sup>

<sup>1</sup>Department of Neurosurgery, West Virginia University, Morgantown, West Virginia, United States

J Neurol Surg Rep 2023;84:e46–e50.

**Address for correspondence** Jesse D. Lawrence, MD, Department of Neurosurgery, West Virginia University, 1 Medical Center Drive, Morgantown, WV 26505, United States (e-mail: jesse.lawrence@hsc.wvu.edu).

## Abstract

**Background** Laser-induced thermotherapy (LITT) is a minimally invasive technique that has been demonstrated as an effective treatment of many pathologies; however, it has never been investigated for the use in skull base tumors.

**Case Series** Three patients underwent LITT for treatment of skull base meningiomas. All three patients were determined to be poor candidates for open resection. Each patient was treated with a single laser fiber. Postoperative imaging confirmed ablation zones along the tract of the catheter in all three patients. Ablation zones were estimated to be 9 to 20% of the intended to treat tumor volume. Two of three treated patients suffered cranial nerve injury following the procedure with one patient diagnosed with neurotrophic keratitis and one patient with symptoms consistent with anesthesia dolorosa.

**Conclusion** LITT is a technically feasible, minimally invasive treatment modality for skull base lesions. Significant risk to cranial nerves and small ablation zones afforded by a single cannula placement proposes serious obstacles. Further investigation is warranted prior to using this technique outside of a palliative indication.

## Keywords

- ▶ laser interstitial thermal therapy
- ▶ meningioma
- ▶ minimally invasive
- ▶ operative feasibility
- ▶ skull base tumor

## Introduction

Laser-induced thermotherapy (LITT) is a minimally invasive treatment modality utilized for targeted thermal ablation of solid tumors and abnormal tissue.<sup>1</sup> Unlike other minimally invasive treatment systems previously used for targeted therapy such as radiowaves, microwaves, or ultrasonography, prior systems failed to achieve a high degree of precision. Simultaneously, continued progress in magnetic resonance imaging (MRI) sequence acquisition and processing created the ability to follow treatment effect in real time.

Graham et al demonstrated that it was possible to quantify with continuous MRI acquisition the damage produced with the tissue heating with LITT.<sup>2</sup> After a decade of development of both techniques and the approval of United States Food and Drug Administration for its use in humans in 2007, the use of MR-guided LITT (MRgLITT) was confirmed as a safe therapy.<sup>3,4</sup>

This technique has already been used previously in many neurological pathologies such as intracranial tumors,<sup>5–9</sup> epilepsy,<sup>10</sup> and chronic pain syndromes<sup>11</sup>; as well as to treat non-neurological masses such as carcinomas of the head and

received  
April 22, 2022  
accepted after revision  
December 23, 2022  
accepted manuscript online  
March 23, 2023

DOI <https://doi.org/10.1055/a-2061-3075>.  
ISSN 2193-6358.

© 2023. The Author(s).

This is an open access article published by Thieme under the terms of the Creative Commons Attribution-NonDerivative-NonCommercial-License, permitting copying and reproduction so long as the original work is given appropriate credit. Contents may not be used for commercial purposes, or adapted, remixed, transformed or built upon. (<https://creativecommons.org/licenses/by-nc-nd/4.0/>)

Georg Thieme Verlag KG, Rüdigerstraße 14, 70469 Stuttgart, Germany

neck,<sup>12,13</sup> pulmonary, hepatic, breast, abdominal, bone, and prostate tumors in a satisfactory manner.<sup>14–18</sup>

In spite of the multitude of pathologies in which MRgLITT has been demonstrated as an effective treatment, it has never been tested in skull base tumors. These types of tumors due to their location and histology usually involve complex surgeries as well as the use of radiotherapy.<sup>19,20</sup> This series of three patients depicts the feasibility and morbidity of this minimally invasive technique and provides a justification for the judicious and not widespread use of LITT for the treatment of skull base lesions. Institutional review board approval was obtained prior to case study, protocol #1912831851. Individual consent was waived as no protected health information is reported.

## Case Reports

### Case 1

A 77-year-old male with a left sphenoid wing meningioma previously received open craniotomy for resection followed by 3 to 4 treatments of stereotactic radiosurgery and subsequent endoscopic endonasal resection for recurrence. Patient presented with a constellation of generalized weakness with a prior fall and episodic altered mental status. Physical exam revealed left eye blindness with left ptosis and absent left eye extraocular movements. MRI revealed a 5.3 × 3.8 × 4.6 cm left sphenoid wing meningioma with invasion of the left cavernous sinus and encasement of the third cranial nerve and left internal carotid artery (ICA) with narrowing. Further appreciated was vasogenic edema of the frontal and temporal lobes resulting in partial effacement of the lateral ventricle and 6 mm of mid-line shift (►Fig. 1).

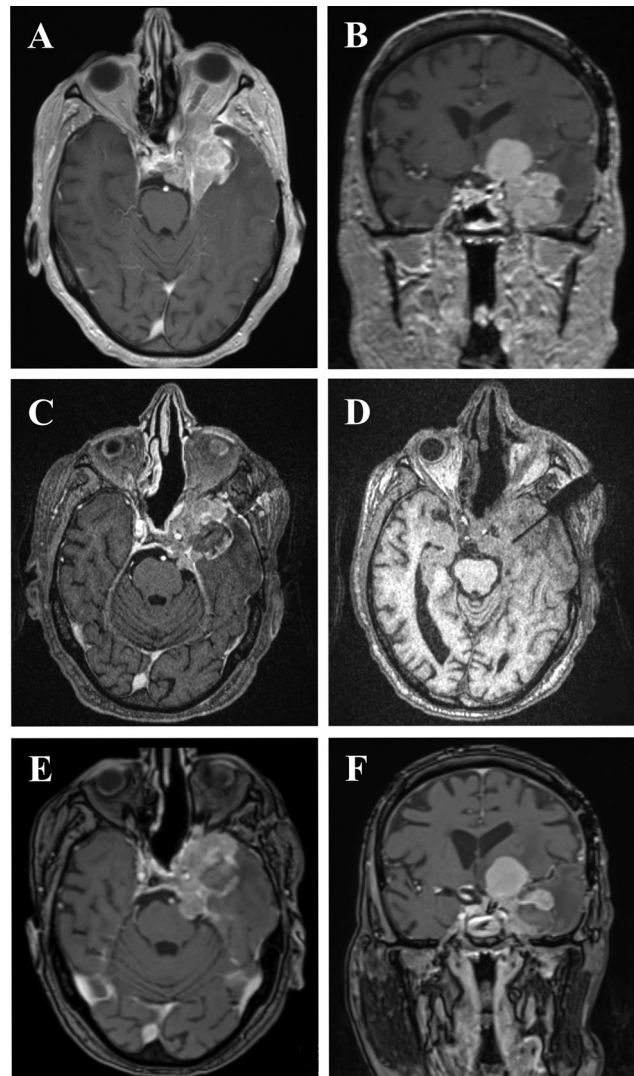
Patient underwent minimally invasive MRgLITT with targeting of the temporal portion of the lesion. Patient had no complications or new cranial nerve deficits. He was discharged home on postoperative day (POD) 3.

Postop MRI completed approximately 7 weeks following surgery revealed ablation of the meningioma along the laser fiber tract without recurrence and improved frontal and temporal vasogenic edema. Patient had a waxing-and-waning course. He was diagnosed with pneumonia (PNA) and developed worsened responsiveness. Family opted for hospice on POD 60.

### Case 2

A 67-year-old female diagnosed with left trigeminal neuralgia secondary to left trigeminal schwannoma, was initially managed with left craniotomy for subtotal resection of the tumor followed by intensity-modulated radiation therapy for the residual lesion in the cavernous sinus. She subsequently experienced recurrent episodic facial pain and underwent gamma knife radiosurgery followed by trigeminal nerve rhizotomy. Of note, patient has a significant cardiac history with a cardiac pacemaker.

Patient presented with recurrent face pain consisting of both atypical facial pain and episodic pain in the V1 distribution triggered by talking and eating. MRI revealed schwannoma invading the left cavernous sinus with compression of Meckel's cave (►Fig. 2).



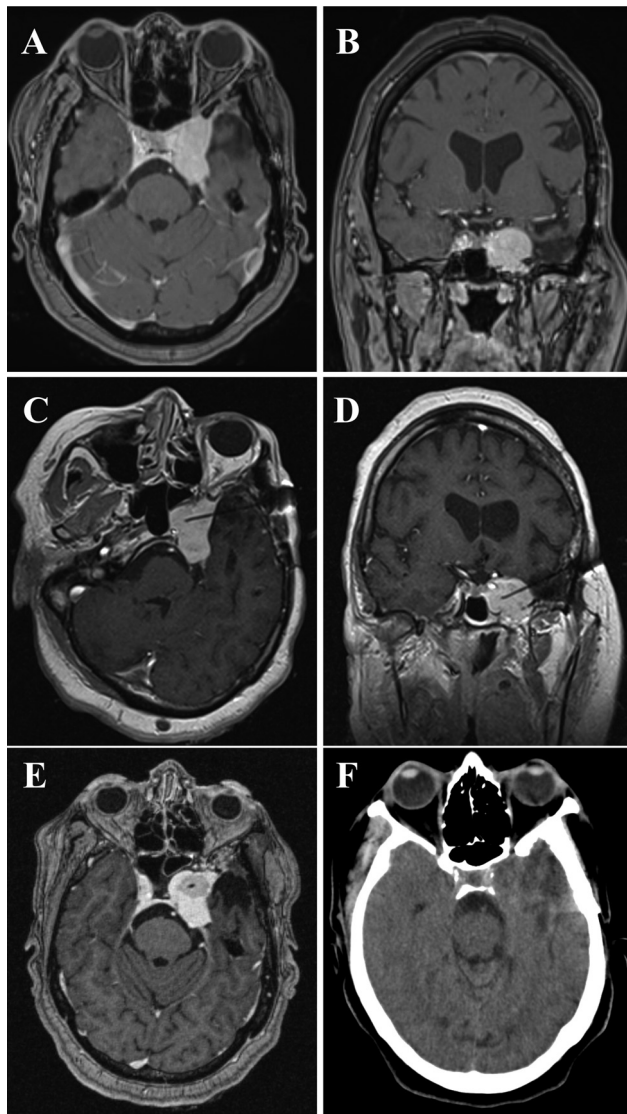
**Fig. 1** Preoperative (A, B), intraoperative (C, D), and postoperative (E, F) imaging for patient 1.

Patient underwent MRgLITT with targeting of the antero-medial aspect of the tumor. Patient had no immediate postoperative complications. Patient reported immediate postop resolution of V1 distribution pain with mild V2/V3 pain. She was discharged POD 7.

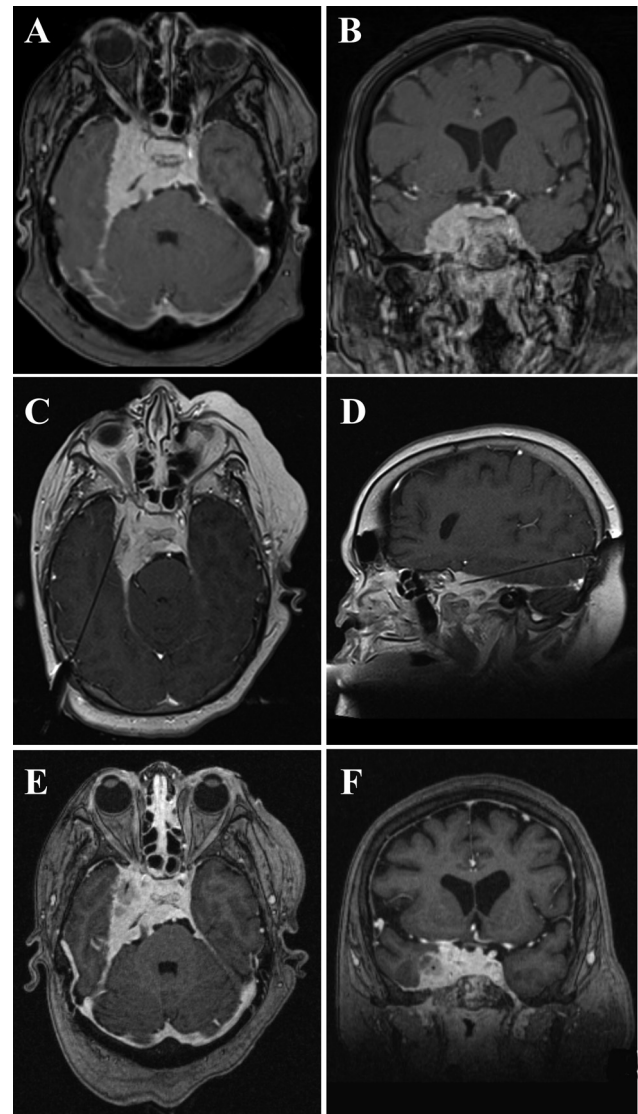
Patient continued to report improvement in facial pain at 2-week follow-up. At subsequent 4-week follow-up, she reported onset of atypical facial pain with left facial hypoesthesia. She went on to receive trigeminal nerve stimulator and then cingulotomy. Patient currently reports only mild left-sided facial pain.

### Case 3

A 52-year-old female with morbid obesity (body mass index [BMI] of 72) and no prior history of intracranial tumor presented for workup following a fall. She reported headache (HA), intermittent dizziness, and black spots in vision. Physical exam revealed no cranial nerve deficits. MRI showed a right petrous apex meningioma with extension to the right cavernous sinus, encasement and stenosis of the right ICA, and extension into the optic canal, foramen rotundum,



**Fig. 2** Preoperative (A, B), intraoperative (C, D), and postoperative (E, F) imaging for patient 2.



**Fig. 3** Preoperative (A, B), intraoperative (C, D), and postoperative (E, F) imaging for patient 3.

foramen ovale, superior orbital fissure, and right internal auditory canal (→Fig. 3).

Patient was determined a poor candidate for surgery secondary to BMI. She underwent MRgLITT with targeting of the right lateral aspect. Patient suffered postoperative V1 distribution numbness and neurotrophic keratitis. She was discharged on POD 2.

Patient had persistent neurotrophic keratitis following recovery and subsequently underwent right lateral permanent tarsorrhaphy. She later reported hearing loss and underwent external beam radiation therapy.

### Operative Technique

Laser ablation was performed using the Visualase Thermal Therapy System (Medtronic Inc, Dublin, Ireland). Trajectories for cannula placement were planned preoperatively based on orientation and volume of the lesions. Trajectories chosen were along the long axis of the lesions to maximize cytor-

duction while avoiding sulci, eloquent tissue, ventricles, and vasculature.

The LITT procedure used was similar to that reported by other groups.<sup>5</sup> Patients were brought to the operating room and placed under general anesthesia. An MR-compatible head frame was applied to the patient and secured by three pins. Patients were registered to stereotactic guidance using preoperative imaging. Using stereotaxis, the cannula was placed using the preoperative plan of cannula placement. The laser applicator was inserted into the target and secured in place. A postapplicator intraoperative computed tomography scan was obtained to confirm placement. Sterile scrub was broken, and the patient was transported to the MRI suite. T1 noncontrasted pretreatment images and a test dose at markedly lower power was initially performed to confirm the laser applicator was functional and not damaged during transport. Treatment exposure was performed. All doses were monitored by the surgeon to confirm that thermal ablation zone was sufficient. Following ablation, the laser

applicator was removed in the MRI suite. All patients received immediate enhanced MRI imaging and follow-up imaging at 1 month and further intervals.

Pretreatment test doses were performed for temperature calibration before treatment dosing at each ablation zone. In some instances, multiple pretreatment doses were performed due to machine error. Multiple treatment ablations were utilized along the path of the cannula. Treatment power and duration was determined to optimize area of ablation. Three target temperature criteria were set for each treatment ablation, two within the site of ablation and one outside the site of ablation.

## Discussion

No current work discusses the specific feasibility of treating meningiomas when located on the skull base with LITT. Tumors along the skull base demonstrate an increased complexity and propose a risk of injury to cranial nerves and brainstem structures during treatment. To our knowledge, this is the first publication describing the use of minimally invasive technique of LITT for treating skull base meningiomas.

The use of LITT for the treatment of convexity meningiomas, recurrent meningiomas, and dural-based lesions has been previously reported. Ivan et al reported on the treatment of four dural-based lesions with convexity or

paramedian location w/ tumor control in 4 of 5 at time of last follow-up and no neurologic deficit following the procedure.<sup>21</sup> Rammo et al reported on the treatment of four meningiomas and showed increasing tumor destruction at 2 weeks postop with no extent of tumor destruction being greater than the original tumor suggesting good conformation of the destruction.<sup>22</sup>

In our series of three patients, our goal was to show the feasibility of thermal ablation of skull base lesions. Cytoreduction along the laser cannula as evidenced by postoperative imaging confirms both the accessibility of these lesions to laser fiber placement, as well as successful ability to reach the targeted ablative temperature. Tumor ablation had an additional effect of reduced cerebral edema as seen in case 1 (►Fig. 1).

Tumor ablation volumes compared against total tumor volume and intention to treat volume, determined as volume of tumor amenable to resection, showed very little cytoreduction (►Table 1). Patients 2 and 3 had similar volumes of ablation with the same energy profile per LITT. Patient 1 had nearly four times greater volume of ablation with less energy profile per LITT parameters (►Table 1). The reason for the difference in these ablation volumes is unclear but potentially related to the internal composition of the tumor.

Cranial nerves face a significant risk to injury during thermal ablation of skull base lesions. Unlike vascular structures which act as heat sinks and thus subvert thermal injury,

**Table 1** Laser interstitial thermal therapy treatment parameters

Patient	Tumor volume (cm <sup>3</sup> )	Intention to treat tumor volume (cm <sup>3</sup> )	Ablation volume (cm <sup>3</sup> )	Ablation zone	Power of shot (Watts)	Time of shot (s)
1	39	20.2	5.8	1	4.5	56
					11.25 <sup>a</sup>	95 <sup>a</sup>
				2	4.5	69
				4.5	29	
					11.25 <sup>a</sup>	79 <sup>a</sup>
2	12.4	9.4	1.5	1	15	50
					65	27
				75	68	
				11.25 <sup>a</sup>	126 <sup>a</sup>	
			2	4.65	19	
				4.65	46	
					11.25 <sup>a</sup>	160 <sup>a</sup>
3	25.6	12.8	1.5	1	15	50
					65	27
				75	68	
				11.25 <sup>a</sup>	126 <sup>a</sup>	
			2	4.65	19	
				4.65	46	
					11.25 <sup>a</sup>	160 <sup>a</sup>

<sup>a</sup>Treatment shot.

cranial nerves are susceptible to injury from increased temperature. Two of three patients experienced cranial nerve injuries as a result of treatment.

Benefits of tumor ablation and reduced cerebral edema must be weighed against high risk for cranial nerve injury and low ablation volumes by single laser fiber placement. This technique may play some role in palliative treatment of skull base lesions but indications must be weighed for each individual patient.

## Conclusion

LITT for the treatment of skull base lesions is a technically feasible intervention. While this intervention does result in cytoreduction and may reduce cerebral edema, there is significant risk for cranial nerve injury and ablation volumes afforded by a single laser fiber is small. Further investigation would be recommended before using this technique outside of a palliative indication.

### Previous Presentations

Presented as a prerecorded oral presentation at the NASBS 2021 virtual annual conference under the title: MR-guided Laser Induced Thermotherapy (MRgLITT) as a feasible new treatment for skull base tumors.

*Both authors contributed equally to this work.*

### Conflict of Interest

None declared.

## References

- Feyh J, Gutmann R, Leunig A, et al. MRI-guided laser interstitial thermal therapy (LITT) of head and neck tumors: progress with a new method. *J Clin Laser Med Surg* 1996;14(06):361–366
- Graham SJ, Chen L, Leitch M, et al. Quantifying tissue damage due to focused ultrasound heating observed by MRI. *Magn Reson Med* 1999;41(02):321–328
- Lewis EC, Weil AG, Duchowny M, Bhatia S, Ragheb J, Miller I. MR-guided laser interstitial thermal therapy for pediatric drug-resistant lesional epilepsy. *Epilepsia* 2015;56(10):1590–1598
- Patel P, Patel NV, Danish SF. Intracranial MR-guided laser-induced thermal therapy: single-center experience with the Visualase Thermal Therapy System. *J Neurosurg* 2016;125(04):853–860
- Carpentier A, Chauvet D, Reina V, et al. MR-guided laser-induced thermal therapy (LITT) for recurrent glioblastomas. *Lasers Surg Med* 2012;44(05):361–368
- Norred SE, Johnson JA. Magnetic resonance-guided laser induced thermal therapy for glioblastoma multiforme: a review. *BioMed Res Int* 2014;2014:761312
- Rahmathulla G, Recinos PF, Valerio JE, Chao S, Barnett GH. Laser interstitial thermal therapy for focal cerebral radiation necrosis: a case report and literature review. *Stereotact Funct Neurosurg* 2012;90(03):192–200
- Rahmathulla G, Recinos PF, Kamian K, Mohammadi AM, Ahluwalia MS, Barnett GH. MRI-guided laser interstitial thermal therapy in neuro-oncology: a review of its current clinical applications. *Oncology* 2014;87(02):67–82
- Raimbault A, Cazals X, Lauvin MA, Destrieux C, Chapet S, Cottier JP. Radionecrosis of malignant glioma and cerebral metastasis: a diagnostic challenge in MRI. *Diagn Interv Imaging* 2014;95(10):985–1000
- Curry DJ, Gowda A, McNichols RJ, Wilfong AA. MR-guided stereotactic laser ablation of epileptogenic foci in children. *Epilepsy Behav* 2012;24(04):408–414
- Harsh V, Viswanathan A. Surgical/radiological interventions for cancer pain. *Curr Pain Headache Rep* 2013;17(05):331
- Sercarz JA, Bublik M, Joo J, et al. Outcomes of laser thermal therapy for recurrent head and neck cancer. *Otolaryngol Head Neck Surg* 2010;142(03):344–350
- Vogl TJ, Mack MG, Müller P, et al. Recurrent nasopharyngeal tumors: preliminary clinical results with interventional MR imaging-controlled laser-induced thermotherapy. *Radiology* 1995;196(03):725–733
- Brace CL, Hinshaw JL, Lubner MG. Thermal ablation for the treatment of abdominal tumors. *J Vis Exp* 2011;(49):x
- Vogl TJ, Naguib NN, Lehnert T, Nour-Eldin NE. Radiofrequency, microwave and laser ablation of pulmonary neoplasms: clinical studies and technical considerations—review article. *Eur J Radiol* 2011;77(02):346–357
- van den Bosch M, Daniel B, Rieke V, Butts-Pauly K, Kermit E, Jeffrey S. MRI-guided radiofrequency ablation of breast cancer: preliminary clinical experience. *J Magn Reson Imaging* 2008;27(01):204–208
- Streitparth F, Teichgräber U, Walter T, Schaser KD, Gebauer B. Recurrent osteoid osteoma: interstitial laser ablation under magnetic resonance imaging guidance. *Skeletal Radiol* 2010;39(11):1131–1137
- Sommer G, Bouley D, Gill H, Daniel B, Pauly KB, Diederich C. Focal ablation of prostate cancer: four roles for magnetic resonance imaging guidance. *Can J Urol* 2013;20(02):6672–6681
- Vrionis FD, Kienstra MA, Rivera M, Padhya TA. Malignant tumors of the anterior skull base. *Cancer Contr* 2004;11(03):144–151
- Lund V, Howard DJ, Wei WI. Endoscopic resection of malignant tumors of the nose and sinuses. *Am J Rhinol* 2007;21(01):89–94
- Ivan ME, Diaz RJ, Berger MH, et al. Magnetic resonance-guided laser ablation for the treatment of recurrent dural-based lesions: a series of five cases. *World Neurosurg* 2017;98:162–170
- Rammo R, Scarpace L, Nagaraja T, Lee I. MR-guided laser interstitial thermal therapy in the treatment of recurrent intracranial meningiomas. *Lasers Surg Med* 2019;51(03):245–250