

Mini-Review

Krzysztof Celejewski*, Ryszard Pogorzelski, Sadegh Toutounchi, Ewa Krajewska, Tomasz Wołoszko, Małgorzata Szostek, Wawrzyniec Jakuczun, Patryk Fiszer, Małgorzata Legocka, Zbigniew Gałązka

Adrenal incidentaloma – diagnostic and treating problem – own experience

<https://doi.org/10.1515/med-2018-0043>

received January 2, 2018; accepted May 5, 2018

Abstract: Introduction. Incidentaloma is defined as an tumor diagnosed accidentally using imaging studies performed due to other indications. The aim of this paper was to describe the diagnostic and treatment problems experienced by patients with adrenal incidentaloma in a clinical practice.

Material and methods. In years 2009-2012 there were 33(16,5%) adrenal tumors diagnosed incidentally out of 200 cases treated due to adrenal pathology. The group consisted of 54 patients aged 27-77. In 15(45,5%) patients the diagnosis was made based on ultrasound examination, while in 18(54,5%) the tumor was visualized in CT/MRI.

Results. Only after the diagnostics was finalized, in which in all cases no signs of hormonal activity were detected, 26(78,8%) patients were qualified for the surgery. In 7(21,2%) cases no indications for such a management were found. The latter group was followed-up and in all patients the indications for the surgery arose due to enlargement of the tumor or/and the existence of hormonal activity. Our observations suggest that the incident finding of adrenal tumor is an indication of long-term observation. The analysis of our material shows that all patients observed needed surgical treatment.

Conclusions. The small adrenal tumors under follow-up have a tendency to enlarge and acquire hormonal activity. Long-term observation significantly increases the

costs of treatment in that group, which eventually results in surgical management.

Keywords: Incidentaloma; Adrenal tumors; Adrenalectomy

1 Introduction

The term incidentaloma refers to an adrenal tumor diagnosed accidentally using diagnostic modalities performed due to other indications that are not directly connected with adrenal pathology. The frequency of incidentalomas is estimated to be between 3 to 10% in general population, and seems to be closely related to age.

In elderly people the pathology is diagnosed more often [1-3]. Incidental diagnosis of the adrenal tumor compels certain diagnostic, treating, financial, as well as deontological management, as a consequence of the fact that in over 30% of cases the pathology needs surgical treatment. In the rest of cases, these are benign lesions or hormonally inactive adrenal glands hypertrophy that are present, which can be followed-up and treated conservatively. However, the qualification for the particular method of management needs detailed laboratory and imaging diagnostics, which greatly increases the costs of treatment in patients [4]. Based on the current literature, the incidentaloma in pathological examination is proven to be in fact as follows: hormonally inactive adenoma of the adrenal gland, subclinical Cushing's syndrome, pheochromocytoma, myelolipoma, ganglioneuroma, aldosteroma, cancer of the adrenal gland, distant cancer metastases, cysts and other uncommon lesions [5,6]. The authors of the paper present the problem on the basis of retrospective analysis that was performed on patients treated in our Clinic for the last four years.

*Corresponding author: Krzysztof Celejewski, Medical University of Warsaw, Warszawa, Poland, E-mail: medicel.celejewski@gmail.com
Ryszard Pogorzelski, Sadegh Toutounchi, Ewa Krajewska, Tomasz Wołoszko, Małgorzata Szostek, Wawrzyniec Jakuczun, Patryk Fiszer, Zbigniew Gałązka, General and Endocrine Surgery of Medical University of Warsaw, Poland
Małgorzata Legocka, Department of General and Endocrine Surgery, Medical University of Warsaw, Poland

2 Material and methods

In years 2009-2012 there were 200 patients treated due to adrenal tumors in Department of General and Endocrine Surgery of Medical University of Warsaw. In that group, there were 33 (16,5%) patients, in whom the adrenal lesion was diagnosed during the diagnostics performed due to other reasons. The treating group consisted of 17 (51,5%) women and 16 (48,5%) men, aged 27-77 years, mean 54. In 15 (45,5%) patients an adrenal tumor was visualized in transabdominal ultrasound examination, while in the next 16 (48,5%) cases in computed tomography of chest and abdomen. In 2 (6,0%) cases the lesions were found in magnetizing resonance imaging performed due to discopathy. Imaging studies of the abdomen were conducted due to suspicion of various pathologies, predominantly diseases of urinary tracts and pancreas. As for the indication for computed tomography of chest, in the majority of cases these were parenchymal lung diseases, although in 3 cases routine follow-up CT was made in 6 months since thoracic surgery due to cancer. Adrenal tumors were localized on the right side in 18 (54,5%) patients, and in 15 (45,5%) on the left. In the paper, the indications for primary imaging studies of the chest and abdomen were analyzed, which lead to the diagnosis of incidentaloma. Furthermore, the results of pathological examinations of postsurgical specimen in comparison with the findings of other authors were presented. Finally, the most important issues of a laparoscopic approach in the surgical treatment of adrenal tumors were discussed.

Ethical approval: The research related to human use has been complied with all the relevant national regulations, institutional policies and in accordance the tenets of the Helsinki Declaration.

3 Results

All the patients with a tumor diagnosed had an endocrinological evaluation and in no individual hormonal activity was found. 26 (78,8%) patients were qualified for the surgery due to the large diameters of lesions (over 45 mm). The remaining 7 (21,2%) individuals with smaller tumors were qualified for follow-up, which lasted 4-11 years. Finally, those patients were operated on, as a consequence of significant enlargement of the tumor and, in one case of the longest follow-up, the overproduction of cortisol in 11th year of observation.

All the patients were operated on. In 32 (97%) cases a transperitoneal laparoscopic adrenalectomy was performed. Intraoperative in figure 1,2,3. Only in one case (3%) an open approach was necessary due to the high possibility of infiltrating tumor. 12 patients (36,4%) underwent previously one or more abdominal surgeries and in no case it was proved to be an important obstacle at the time of performing laparoscopy. In some cases before the exact adrenalectomy, there was a necessity to free adhesions, which only slightly increased the time of the procedure. In 5 (15,2%) cases the right-sided laparoscopic adrenalectomy was combined with cholecystectomy. In all cases the indication for a surgery was symptomatic cholelithiasis. Furthermore, it should be emphasized that in all cases diagnostics for cholelithiasis lead to the diagnosis of an adrenal lesion.

As for the results of pathological examination of specimens obtained, in 22 (66,7%) cases either adenoma of adrenal glands or nodular adrenocortical hypertrophy were found. In 6 (18,2%) cases primary or metastatic neoplasms were diagnosed. Finally, in the remaining 5 (15,1%) other uncommon pathologies were present (tab. 1).

4 Discussion

As a result of a greater availability of diagnostic imaging modalities of both abdomen and chest, incidental diagnosis of pathologies localized in the adrenal glands considerably increased. In the literature the frequency is estimated to be approximately 10% [2,3]. However, in some reports based on large series from single centers the percentage of incidentalomas diagnosed exceeds 16% [7]. A

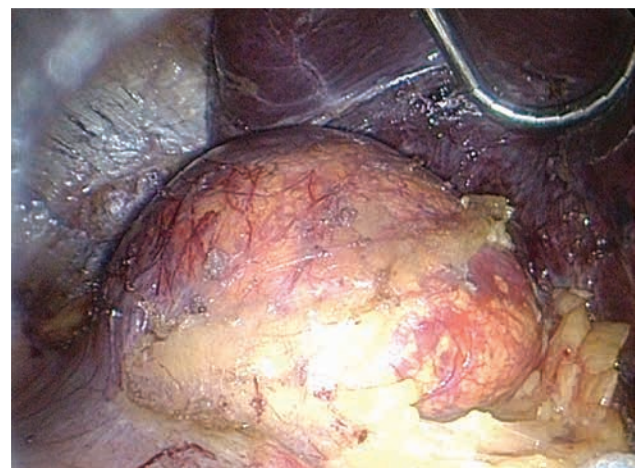


Figure 1: Right incidental adrenal tumor - angiomiolipoma. Intraoperative view.

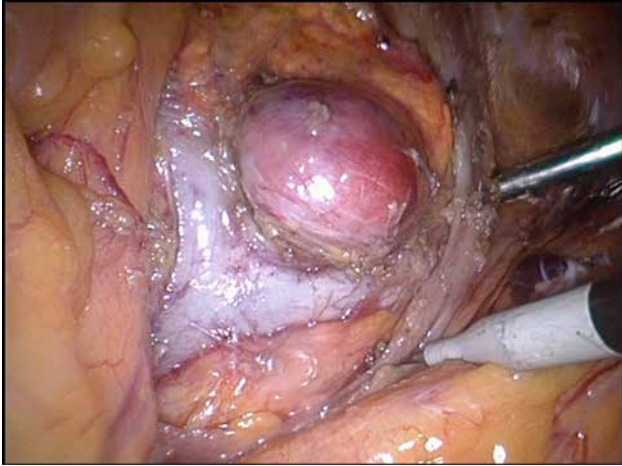


Figure 2: Left-sided incidental adrenal tumor – pheochromocytoma; intraoperative view

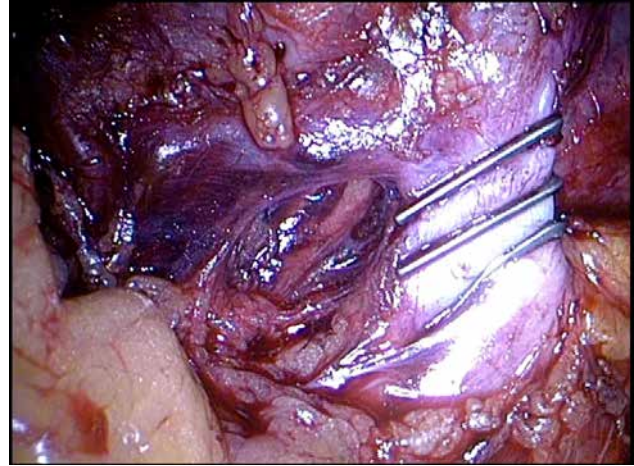


Figure 3: Left-sided adrenalectomy - the stage of cutting the adrenal vein

similar tendency was observed in our clinic, with a 16,5% of incidentaloma's cases.

There is no doubt that the frequency of accidentally diagnosed adrenal lesions is closely connected with age. In younger patients incidentaloma is found in about 1%, in people up to 50 years old in 3%, while above 50 years even in 15% of human population. Incidental visualization of an adrenal nodule evokes many suspicions and questions in diagnosing physician as far as the character, hormonal activity and qualification for certain management are concerned. There is practically no doubt as for the management of those tumors of the diameter over 40 mm, suspicious of malignant potential, as well as hormonally active lesions. In such cases, after an appropriate preoperative preparation patients are qualified for the surgery. There is no consensus as for the lesions smaller than 40 mm and hormonally inactive (3).

However, in our experience that is based on a few years of follow-up, in all patients non-qualified for the adrenalectomy a constant increase in a tumor's diameter was observed, while in one case hipercortizolemia was developed. In order to determine the character of the lesion, especially in cases non-qualified primarily for the surgery, imaging studies, mainly computed tomography, magnetic resonance and positron emission tomography are of the greatest significance. The imaging modalities complement one another and enable qualitative assessment of adrenal lesions with high specificity [8]. As a consequence, a safe routine follow-up of small and hormonally inactive lesions is feasible. Fine needle biopsy still has its place, but several constraints diminish its diagnostic significance, e.g. risk of bleeding, tumor seeding of both primary and metastatic origin. It is non-diagnostic in 80% of cases and causes up to 20% of complications. Due to that fact, there is limited interest in that procedure [6,9].

Table 1: Comparison of results from our materials and other authors

Pathological diagnosis	Our material N(33/200)%	Arnaldi et al (3) N(100/380)/%	Aron et al (10) %	Bittner IV et al (4) %
Adenoma of adrenal gland	16 (48,5)	63 (63,0)	41,0	61,0
Adrenocortical nodular hypertrophy	5 (15,2)			
Myelolipoma	3 (9,1)	6 (6,0)	9,0	10,0
Metastates to adrenal glands	5 (15,2)	3 (3,0)	19,0	2,5
Adrenal gland carcinoma	1 (3,0)	4 (4,0)	10,0	4,7
Pheochromocytoma	1 (3,0)	7 (7,0)	8,0	5,1
Cyst	1 (3,0)			6,0
Cushing's syndrome	1 (3,0)	15 (15,0)		5,3
Aldosteroma		2 (2,0)		
Overall:	33 (100)	100(100)	87,0*	94,6*

*predominant lesions

Nowadays, the standard in surgical management is a laparoscopic adrenalectomy, which is performed in both hormonally active and inactive tumors. Its superiority over open surgery is indisputable [10]. Laparoscopic adrenalectomy is recommended and performed in primary and metastatic tumors. In the latter cases, several limitations remain, e.g. great tumor dimensions, infiltration of surrounding tissues and anatomical structures, the possibility of tumor fragmentation and tumor spreading. In all cases, in which the risk of fragmentation at the time of dissection is high and safe removal of a tumor with a margin of adipose tissue is unfeasible, a conversion to open surgery should take place. Furthermore, the authors' claim there is no difference in terms of oncologic radicality between open and laparoscopic access [11,13].

What should be emphasized is that incidentalomas non-qualified primarily for surgical treatment represent a significant problem in out patient's offices due to the fact that the tumors have to be followed-up, especially as far as the growth dynamics and the state of hormonal activity are concerned. Moreover, hormonal activity may arise at the different moments of follow-up. Laboratory and imaging studies are not always sufficient to diagnose and determine the character of a tumor. Repeating them increases the cost of treatment and enforces the clinicians to search for new effective diagnostic modalities in cases of incidentalomas [4,13]. From the clinical point of view, what is important is what is hidden behind the joint term incidentaloma. Definite diagnosis is established only after final pathological report of the specimen obtained. The results coming from our material and other authors are compiled and presented in Table 1.

In our material, apart from adenoma of adrenal gland, in few cases multiple adrenocortical nodular hypertrophy was diagnosed. However, when presenting these two pathologies together one receives the percentage of 63,7%, which corresponds with the results of other authors [5,6,12,14].

ConclusionIn the presented material all the small nodules found accidentally in adrenal glands increased in its diameter over 45 mm during the follow-up between 4 to 11 years.

Periodical controls, imaging and laboratory studies greatly increase the costs of treatment in such patients during the few years of follow-up.

Conflict of interest statement: Authors state no conflict of interest

References

- [1] Becker J, Woloszyn J, Bold R. et al. The adrenal incidentaloma: an opportunity to improve patient care. *J Gen Intern Med.* 2018;33:256-257
- [2] Lee J-M, Kim MK, Ko S-H. et al. Clinical guidelines for the management of adrenal incidentaloma. *Endocrinol Metab.* 2017;32:200-218
- [3] Androulakis II, Kaltsas G, Piaditis G, et al. The clinical significance of adrenal incidentalomas. *Eur J Clin Invest.* 2011;41(5):552-560
- [4] Wang TS, Cheung K, Roman SA, et al. A cost-effectiveness analysis of adrenalectomy for nonfunctional adrenal incidentalomas: Is there a size threshold for resection? *Surgery* 2012;152:1125-1132
- [5] Arnaldi G, Boscaro M. Adrenal incidentaloma. *Best Practice & Research Clinical Endocrinology & Metabolism.* 2012;26:405-413
- [6] Bittner IV JG, Brunt LM. Evaluation and management of adrenal incidentaloma. *Journal of Surgical Oncology.* 2012;106:557-564
- [7] Grogan RH, Mitmaker E, Vriens MR, et al. Adrenal incidentaloma: does an adequate workup rule out surprises. *Surgery.* 2010;148(2):392-397
- [8] Podgórska J, Cieszanowski A, Bednarczuk T. Adrenal imaging. *Pol J Endocrinol* 2012;63(1):71-81
- [9] Nieman LK. Approach to the patient with an adrenal incidentaloma. *J Clin Endocrinol Metab.* 2010;95(9):4106-4113
- [10] Lubikowski J, Kiedrowicz B, Szajko M, et al. Laparoscopic adrenalectomy for functioning and non-functioning adrenal tumors. *Pol J Endocrinol* 2011;62(6):512-516
- [11] Zografos GN, Vasiliadis G, Farfaras AN, et al. Laparoscopic surgery for malignant adrenal tumors. *JSLs* 2009;13(2):196-202
- [12] Aron D, Terzolo M, Cawood TJ. Adrenal incidentalomas. *Best Practice & Research Clinical Endocrinology & Metabolism.* 2012;26:69-82
- [13] Foltyn W, Strzelczyk J, Marek B et al. The usefulness of determining the serum concentrations of vascular endothelial growth factor (VEGF) and its soluble type 2 (sVEGF) in the differential diagnosis of adrenal incidentalomas. *Pol J Endocrinol* 2012;63(1):22-28
- [14] Pogorzelski R, Toutounchi S, Fiszer P. et al. The local spread of pheochromocytoma after adrenalectomy with a rupture of the tumor capsule at the time of the surgery. *Open Med.* 2015;10:335-337