

Simplified hybrid repair with true lumen recycling for retrograde renovisceral perfusion in a complex chronic aortic dissection

Ricardo Castro-Ferreira, MD,^{a,b} Paulo Gonçalves Dias, MD,^a Sérgio Moreira Sampaio, MD,^{a,c} José Fernando Teixeira, MD,^a and Mario Lachat, PhD,^d Porto, Portugal; and Zürich, Switzerland

ABSTRACT

A 59-year-old man was referred with complicated chronic type B aortic dissection. Despite the false lumen's being dominant in terms of caliber and limb perfusion, visceral arteries originated in a 9-mm true lumen. A staged approach was performed: open aortobi-iliac bypass with preservation of both lumens to the infrarenal aorta, with reinforcement of the aorta and anastomosis with Dacron (wrap technique); exclusion of the dissection by endografting all of the false lumen with three successive thoracic endoprostheses; and maintenance of true lumen perfusion using two periscopes with self-expanding nitinol stents. The patient remains asymptomatic after 1 year of follow-up. (*J Vasc Surg Cases and Innovative Techniques* 2018;4:226-30.)

Keywords: Chronic type B aortic dissection; Parallel grafts; Periscope; Hybrid repair; Thoracoabdominal aneurysm

Aggressive medical therapy and close surveillance of the aorta remain the foundation of management of chronic type B aortic dissection (CTBAD).¹ Recent European Society for Vascular Surgery guidelines highlight that the development of symptoms and maximal aneurysm diameter >50 mm mandate immediate evaluation for surgery.¹ At present, the best management of CTBAD remains elusive as there have been no randomized controlled trials comparing the available techniques—open repair, thoracic endovascular aortic repair, and branched or fenestrated endovascular aneurysm repair (B/F-EVAR).² Furthermore, the sheer complexity of some CTBAD cases makes a standardized approach impossible. We describe a particularly challenging case of type B aortic dissection in which a novel and creative stepped approach was successfully undertaken. The patient has consented to the publication of this manuscript.

CASE REPORT

A 59-year-old man with a history of acute type A dissection underwent open repair of the aortic arch with Dacron with reimplantation of the supra-aortic arteries 18 years ago. Early in 2016, he was referred with a CTBAD complicated by type I thoracoabdominal aortic aneurysm, thrombosed right common iliac artery aneurysm (60-mm thoracic aorta and 50-mm abdominal aorta; 40 mm in the right common iliac artery), and thrombosed left internal iliac and right renal arteries (Fig 1). The dissection had an apparent origin in the Dacron-descending thoracic aorta anastomosis. Despite that the false lumen (FL) was dominant in terms of caliber and limb perfusion, all remaining visceral arteries—left renal, mesenteric, and celiac—originated in the true lumen (TL), which had a diameter of just 9 mm (Fig 1). Clinically, the patient had severe claudication of the right limb (Rutherford class 3), erectile dysfunction, and episodic lumbar pain. There were no pulses in the right leg, and the ankle-brachial index was 0.4.

A stepped approach treatment was performed. In the first step, infrarenal aortic replacement was undertaken with the aortic anastomosis about 4 cm distal from the distal left renal artery and with local resection of the dissection membrane for preservation of flow to both aortic lumens. In addition, the native aorta in between the left distal renal artery and the graft was reinforced with a collar of Dacron graft surplus (wrap technique). The Dacron wrap was fixed by simple stitches to both the juxtarenal aorta and the bypass distal to the anastomosis (Figs 2 and 3). Revascularization of the right limb was achieved by anastomosis of the graft limb to the external iliac artery. Theoretically, this step would exclude the right common iliac artery aneurysm and revascularize the right limb, reinforce the aorta, and secure access for the next step. The second step consisted of the endovascular part of the hybrid procedure. The dissection was excluded by endografting the entire FL with three successive thoracic endoprostheses (34 mm × 34 mm × 20 cm, 34 mm × 34 mm × 20 cm, and 34 mm × 34 mm × 15 cm

From the Serviço de Angiologia e Cirurgia Vascular, Centro Hospitalar de São João, Porto^a; Departamento de Cirurgia e Fisiologia, Unidade de Investigação Cardiovascular,^b and Centro de Investigação em Tecnologias e Serviços de Saúde,^c Faculdade de Medicina da Universidade do Porto, Porto; and Universitätsspital Zürich, Zürich.^d

Author conflict of interest: none.

Correspondence: Ricardo Castro-Ferreira, MD, Faculdade de Medicina da Universidade do Porto, Physiology and Cardiothoracic Surgery, Alameda Prof Hernâni Monteiro, 4200-319 Porto, Portugal (e-mail: cferreira.ricardo@gmail.com).

The editors and reviewers of this article have no relevant financial relationships to disclose per the Journal policy that requires reviewers to decline review of any manuscript for which they may have a conflict of interest.

2468-4287

© 2018 The Author(s). Published by Elsevier Inc. on behalf of Society for Vascular Surgery. This is an open access article under the CC BY-NC-ND license (<http://creativecommons.org/licenses/by-nc-nd/4.0/>).

<https://doi.org/10.1016/j.jvscit.2018.03.006>




Fig 1. Schematic image of the imaging findings when the patient was referred to the vascular department: type I thoracoabdominal aortic aneurysm, thrombosed right common iliac artery aneurysm (60-mm thoracic aorta and 50-mm abdominal aorta; 40 mm in the right common iliac artery), and thrombosed right renal and left internal iliac arteries. The dissection had an apparent origin in the Dacron-descending thoracic aorta anastomosis. The false lumen (FL) was dominant and compressed the true lumen (TL), which had just 1-cm diameter. All remaining visceral arteries—left renal, superior mesenteric, and celiac—originated in the TL.




Fig 2. Schematic image of the first step in treatment—open aortoiliac bypass with preservation of both lumens in the infrarenal aorta, with additional reinforcement of the infrarenal aorta and anastomosis with Dacron (wrap technique).

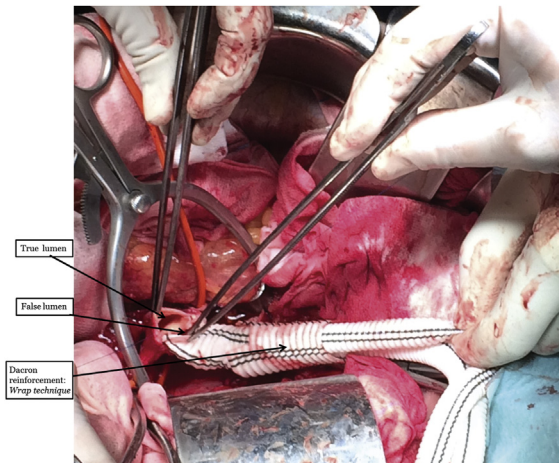


Fig 3. Intraoperative photograph highlighting both lumens in the infrarenal aorta and the Dacron that will further reinforce the infrarenal aorta and anastomosis (wrap technique).

CORE TAG; W. L. Gore & Associates, Flagstaff, Ariz). Perfusion to the renovisceral vessels through the TL was maintained using two self-expanding nitinol stents (10- × 94-mm Wallstent; Boston Scientific, Marlborough, Mass) deployed from distal infrarenal aorta and extending up to the celiac trunk (periscope technique; Fig 4; Video, online only). Three percutaneous arterial accesses were performed under local anesthesia—left brachial for aortic arch imaging and control of the left subclavian artery; right femoral for the selective catheterization of the FL; and left femoral for the selective catheterization of the TL. Three successive thoracic endoprosthesis were deployed using the right femoral access, and two self-expanding nitinol stents were installed through the left femoral artery. The distal landing zone was in the 4 cm of reinforced infrarenal aorta created in the first step. Final angiography showed total aneurysm exclusion and documented patency of the visceral arteries maintained by both periscope stents in the TL (Video). This procedure was done under spinal cord ischemia prevention using a spinal drainage catheter. The second step was performed 1 month after the aortobi-iliac bypass. The patient was discharged under anticoagulant (rivaroxaban, 20 mg for 1 month) and antiplatelet (aspirin, 100 mg indefinitely) therapy. He remains asymptomatic, with no relevant imaging findings after 16 months of follow-up (Fig 5).

DISCUSSION

This particular case highlights that in some complex scenarios, the patient is a poor candidate for any of the standard approaches for CTBAD. Conventional open thoracoabdominal replacement was initially evaluated, especially considering the young age of the patient. It would have included replacement of the descending aorta, the abdominal aorta, and the common iliac arteries in a patient already presenting with reduced spinal perfusion (including bilateral hypogastric occlusion). Besides, the previous aortic arch surgery would pose

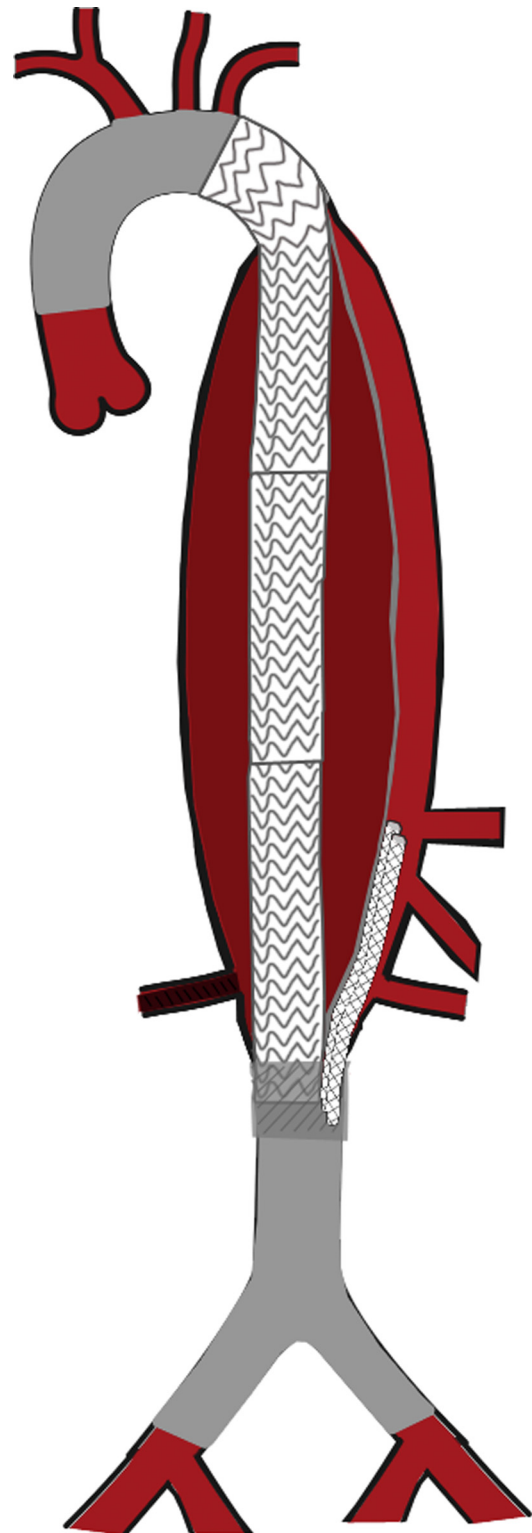


Fig 4. Schematic image of the second step in treatment—exclusion of the dissection's origin by endografting of the entire false lumen (FL) with three successive thoracic endoprosthesis. The proximal landing zone was just distal to the left subclavian artery. The distal landing zone was in the infrarenal aorta reinforced by the Dacron. True lumen (TL) perfusion was maintained by two periscopes with self-expanding bare-metal nitinol stents.

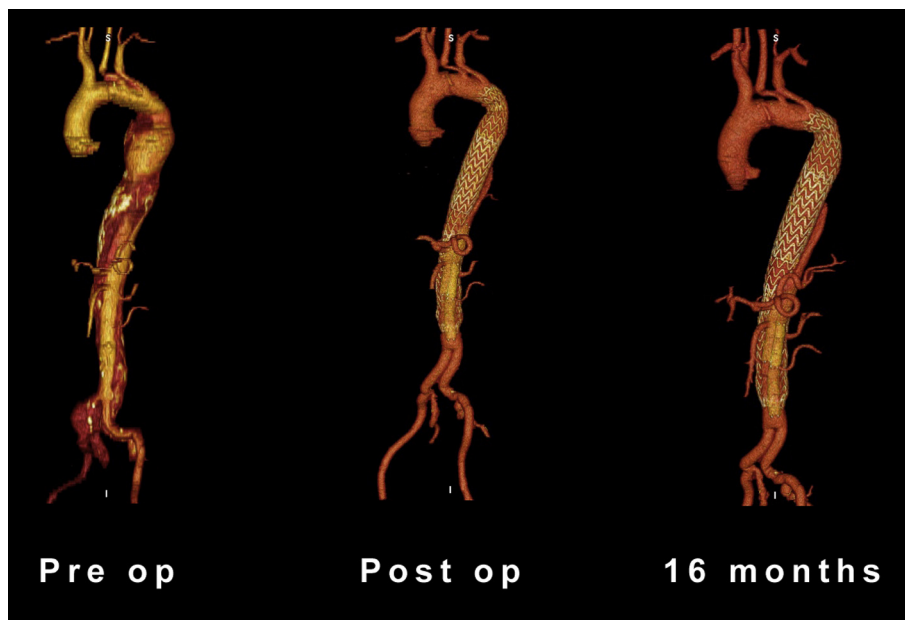


Fig 5. Preoperative, postoperative, and 16-month three-dimensional computed tomography angiography reconstructions. Total coverage of the thoracoabdominal aorta can be appreciated. The celiac trunk and superior mesenteric and left renal arteries are all successfully perfused through true limb salvage using two periscopes.

additional challenges for a new open repair. Therefore, and especially considering the high paraplegia risk of conventional open thoracoabdominal surgery in such a situation, a less risky solution was needed. A complete endovascular option was rejected because of endovascular technical challenges—the visceral arteries originated from a TL with just 1-cm diameter, which would not be compatible with B/F-EVAR. In addition, there was significant risk of losing the lower renal artery, which was small and unfavorable for bridging stents. Another leading point was to be able to preserve thoracoabdominal spinal perfusion, which would not have been possible with standard B/F-EVAR or parallel grafts. Moreover, B/F-EVAR would not solve the limb ischemia caused by the thrombosed right iliac artery aneurysm. Altogether, a more creative solution was indeed needed.

The treatment concept in the patient was to exclude the extensive thoracoabdominal aortoiliac aneurysm and to maintain renovisceral perfusion in a less invasive manner than by conventional thoracoabdominal aortic replacement. Therefore, a hybrid approach was considered to achieve recycling of the TL for retrograde perfusion of the renovisceral vessels and the significant number of spinal arteries at the thoracoabdominal level. The parallel grafting technique is gaining popularity in the treatment of complex aortic aneurysms, with fairly promising results.³ Its use in CTBAD, however, has seldom been reported and is not part of its treatment armamentarium.^{1,4} The periscope technique was first described by Lachat et al⁵

in 2008 to revascularize (from a transfemoral access) the visceral arteries during stent graft repair of a ruptured thoracoabdominal aortic aneurysm. Covering the FL in cases with compressed TLs has been successfully performed in the past.⁶⁻⁸ Combining the periscope reasoning with the FL coverage with multiple thoracic endoprosthesis allowed exclusion of the aneurysm and salvage of the TL and its vital branches. This technique had the additional theoretical benefit of highly reducing the risk of spinal cord ischemia as the lumbar arteries are preserved by the total TL perfusion through the periscopes. We used two bare-metal stents instead of just one, not only to increase the functional lumen of the TL but also to have a potentially lifesaving backup perfusion in case of stent thrombosis. Considering that the FL will host the aortic stent graft that will eventually (primarily or secondarily in case of aortic remodeling) compress the TL, the uncovered self-expanding stents have, in addition, the long-term role of preventing the collapse of the TL. However, this imaginative endovascular approach was possible only after open repair of the infrarenal aorta; considering that later access to both dissection channels—the true for renovisceral perfusion and the false for stent graft implantation to exclude the thoracoabdominal aneurysm—would be necessary, the dissection membrane was resected locally before graft anastomosis was performed. The technical challenge was to cross-clamp the partially thrombosed aorta infrarenally, which only seemed safe distal to the left lower renal artery. This would have resulted in a short

graft trunk and very short unsecure landing zone, considering that the endoluminal aortic repair would use tubular stent grafts. Therefore, to get a longer stable landing zone, the aorta to graft anastomosis was performed 4 cm distal from the distal left renal artery, and the aortic segment from the renal artery to the bifurcated surgical graft was reinforced by an external collar of Dacron graft surplus (wrap technique). To summarize, the open repair not only revascularized the right limb but also permitted a clear femoral access to both the TL and FL, with the wrap technique promoting a reinforced area for the distal landing zone of both the thoracic endoprosthesis and nitinol stents (periscopes). Because of the potential risks of aneurysmal degeneration caused by the retrograde perfusion of the TL into the thoracic aorta, the possibility of primarily occluding this lumen at thoracic level was considered. However, the aortic wall in the TL looked particularly normal, and therefore we believed that it would remain stable. In addition, spinal perfusion through the TL was considered an important neuroprotective tool. In that way, we decided to primarily maintain patency of this lumen up to the thoracic aorta. Close follow-up will include monitoring the behavior of the aortic wall with computed tomography scans at 1 month, 6 months, and 12 months. In case any degeneration is detected, secondary occlusion with an Amplatzer occluder (St. Jude Medical, St. Paul, Minn) will be performed.

CONCLUSIONS

To the best of our knowledge, this is the first description in the literature of an aortobi-iliac bypass followed by FL coverage with TL salvage using parallel grafts as CTBAD treatment. Early and midterm results show that this technique can be feasible and stable at 1 year of follow-up. This original technique might be useful in selected patients with B type aortic dissection and presenting with aneurysmatic degeneration extending over the aortic bifurcation and where reno-visceral perfusion originates from nondilated aortic TL. This method maintains antegrade flow to the spinal arteries and may have low paraplegia occurrence. Longer follow-up and more clinical experience will show the real value of the technique. Endovascular techniques allow elegant resolutions for several clinical

settings, but sometimes only the synergy of both open and endovascular repair can offer a convincing solution.

The authors would like to thank Pedro Couto for technical support in the development of the images displayed in the article. The authors would like to thank David Pakeliani for the development of the three-dimensional scan reconstructions displayed in Fig 5.

REFERENCES

1. Writing Committee, Rimbau V, Bockler D, Brunkwall J, Cao P, Chiesa R, et al. Editor's choice—management of descending thoracic aorta diseases: clinical practice guidelines of the European Society for Vascular Surgery (ESVS). *Eur J Vasc Endovasc Surg* 2017;53:4-52.
2. Erbel R, Aboyans V, Boileau C, Bossone E, Bartolomeo RD, Eggebrecht H, et al. 2014 ESC Guidelines on the diagnosis and treatment of aortic diseases: document covering acute and chronic aortic diseases of the thoracic and abdominal aorta of the adult. The Task Force for the Diagnosis and Treatment of Aortic Diseases of the European Society of Cardiology (ESC). *Eur Heart J* 2014;35:2873-926.
3. Donas KP, Lee JT, Lachat M, Torsello G, Veith FJ. PERICLES investigators. Collected world experience about the performance of the snorkel/chimney endovascular technique in the treatment of complex aortic pathologies: the PERICLES registry. *Ann Surg* 2015;262:546-53; discussion: 552-3.
4. Kamman AV, de Beaufort HW, van Bogerijen GH, Nauta FJ, Heijmen RH, Moll FL, et al. Contemporary management strategies for chronic type B aortic dissections: a systematic review. *PLoS One* 2016;11:e0154930.
5. Lachat M, Frauenfelder T, Mayer D, Pfiffner R, Veith FJ, Rancic Z, et al. Complete endovascular renal and visceral artery revascularization and exclusion of a ruptured type IV thoracoabdominal aortic aneurysm. *J Endovasc Ther* 2010;17:216-20.
6. Watanabe Y, Kuratani T, Shirakawa Y, Torikai K, Shimamura K, Sawa Y. Hybrid endovascular repair of a dissecting thoracoabdominal aortic aneurysm with stent graft implantation through the false lumen. *J Vasc Surg* 2014;59:264-7.
7. Simring D, Raja J, Morgan-Rowe L, Hague J, Harris PL, Ivancev K. Placement of a branched stent graft into the false lumen of a chronic type B aortic dissection. *J Vasc Surg* 2011;54:1784-7.
8. Quinones-Baldrich W, Jimenez JC, DeRubertis B, Moore WS. Combined endovascular and surgical approach (CESA) to thoracoabdominal aortic pathology: a 10-year experience. *J Vasc Surg* 2009;49:1125-34.

Submitted Jan 15, 2018; accepted Mar 16, 2018.