




Contents lists available at ScienceDirect

Acta Orthopaedica et Traumatologica Turcica

journal homepage: <https://www.elsevier.com/locate/aott>

Hair tourniquet syndrome of toes and fingers in infants

Okan Aslantürk^{a,*}, Rafet Özbey^b, Özgür Yılmaz^c, Emre Ergen^d^a Department of Orthopaedics and Traumatology, Malatya Training and Research Hospital, Malatya, Turkey^b Department of Plastic and Reconstructive Surgery, Malatya Training and Research Hospital, Malatya, Turkey^c Department of Orthopaedics and Traumatology, Muş State Hospital, Muş, Turkey^d Department of Orthopaedics and Traumatology, İnönü University Faculty of Medicine, Malatya, Turkey

ARTICLE INFO

Article history:

Received 6 October 2018

Received in revised form

26 March 2019

Accepted 28 April 2019

Available online 16 May 2019

Keywords:

Hair tourniquet

Child abuse

Amputation

Strangulation

Toe

ABSTRACT

Objective: Hair tourniquet syndrome is an uncommon condition characterized by strangulation appendages by a hair or thread. The aim of this study was to evaluate the results of hair removal and antibiotic therapy in our patients with hair tourniquet syndrome.

Methods: Between January 2012 and August 2018, 16 patients (8 boys, 8 girls; mean age: 118.5 [range: 20 to 380] days) were treated surgically for hair tourniquet syndrome. All patients were treated surgically under local or general anesthesia in the pediatric emergency department or in the operating theater using magnifying loupes. The age, gender, affected fingers or toes and the affected sides of the patients and the duration of symptoms until presentation were recorded.

Results: A total of 24 toes and fingers were treated for hair tourniquet syndrome. The right side was affected in 12 patients, the left side was affected in three, and both sides in one. The second toe was affected in three patients, the third toe in eleven, the fourth in six, and the fifth in two patients. Both the thumb and the second finger were affected in one patient. The average duration of the symptoms (excessive crying, swelling, redness) was 1.5 (range: 1 to 2) days. All patients healed without any complications.

Conclusion: Hair tourniquet syndrome should be kept in mind as an etiology in infants with toe and finger strangulation. These patients should be examined undressed. Immediate removal of hair is an effective treatment method to save appendage.

Level of evidence: Level IV, Therapeutic Study

© 2019 Turkish Association of Orthopaedics and Traumatology. Publishing services by Elsevier B.V. This is an open access article under the CC BY-NC-ND license (<http://creativecommons.org/licenses/by-nc-nd/4.0/>).

Introduction

Hair tourniquet syndrome (HTS) is an uncommon condition characterized by strangulation of the finger, toe and other appendages such as uvula or penis by a hair or thread wrapped around the appendage.^{1,2} The incidence of HTS was reported in only one study as 0.02%.³ Clinical findings include swelling, edema, redness of the affected appendage and even necrosis in late cases.^{4,5} Etiology is still controversial whether it is accidental or due to child abuse.^{1,3} Bad hygiene is one of the risk factors.¹ The management of

HTS includes the immediate removal of the hair or thread that causes strangulation, surgically or with chemical depilatories.^{3,6}

Due to the rare incidence of HTS, the diagnosis could be missed or misdiagnosed (as like infection, etc.). Late presentation to hospital or missed diagnosis may lead to serious problems, even amputation of the appendage.⁴ Swelling and edema can make it hard to determine the hair or thread (Fig. 1). Physicians should carefully examine the affected appendage, in some cases, magnifiers could be helpful to see the hair or thread.

The aim of this study was to attract the attention of physicians to this rare condition and present our clinical experience.

Patients and methods

After obtaining the approval of the local ethical committee of our hospital, data of the patients treated for HTS between January 2012 and August 2018 were retrospectively reviewed. The age,

* Corresponding author. Department of Orthopaedics and Traumatology, Malatya Eğitim ve Araştırma Hastanesi, Özalper Mah. Turgut Özal Bulvarı No: 4, 44330, Malatya, Turkey. Tel.: +90 506 329 76 16.

E-mail address: okaslanturk@hotmail.com (O. Aslantürk).

Peer review under responsibility of Turkish Association of Orthopaedics and Traumatology.

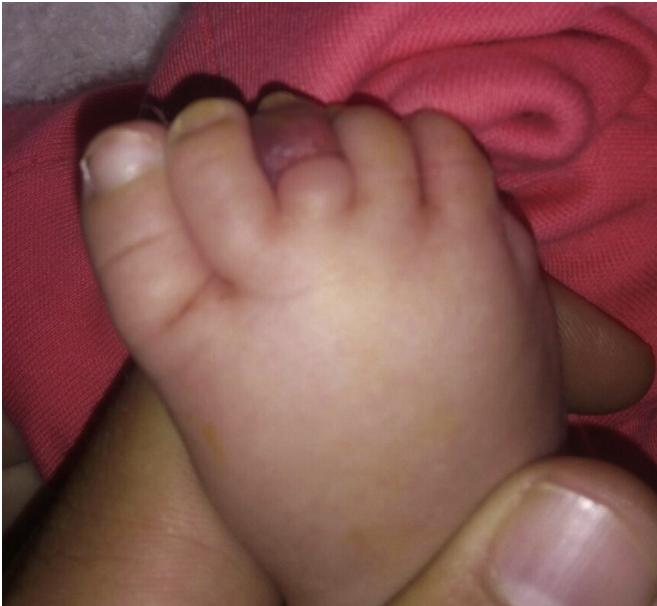

Fig. 1. Edema and swelling of the toe due to hair strangulation (Patient 13).

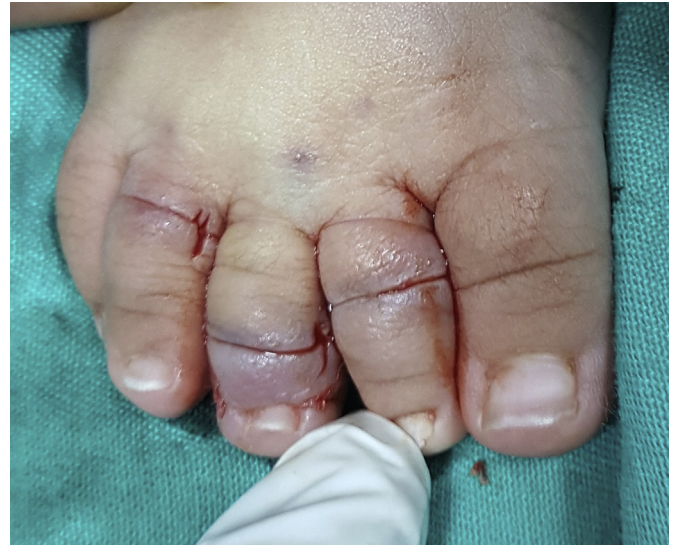

Fig. 2. Appearance of the toes after the removal of hair (Patient 4).

gender, affected fingers or toes and the affected sides of the patients and the duration of symptoms until presentation were recorded (Table 1).

All patients were treated surgically under local or general anesthesia in the pediatric emergency department or in the operating theater with magnifying loupes (Figs. 2 and 3). After the removal of hair, patients were kept in the hospital at least for one night in order to follow-up the blood circulation in the affected toe or finger. Prophylactic antibiotic therapy (cefazolin 50 mg/kg/day) was administered in three injections. Topical antibiotic ointment was used for wound care.

Statistical analysis

The statistical analyses were carried out using the SPSS v.22.0 software (SPSS Inc., Chicago, IL, USA). Binomial test was used to compare the rate of the affected side. A *p* value of <0.05 was considered statistically significant.

Table 1
Demographic data of the patients.

Patient no.	Gender	Age (days)	Side – affected limb	Duration of complaints (days)
1	Boy	60	Right – 4th toe	2
2	Boy	168	Right – 3rd toe	2
3	Girl	59	Right – 3rd–4th toe	1
4	Girl	105	Right – 2nd–3rd–4th toes	2
5	Girl	20	Right – 3rd toe	2
6	Boy	130	Right – 2nd toe	1
7	Boy	60	Right – 3rd toe	2
8	Girl	121	Right – 2nd–3rd toe	1
9	Boy	30	Right – thumb Left – 2nd finger	1
10	Boy	380	Right – 3rd toe	2
11	Boy	25	Left – 3rd toe	1
12	Boy	118	Right – 3rd–4th–5th toes	1
13	Girl	180	Right – 3rd toe	2
14	Girl	85	Left – 4th–5th toes	1
15	Girl	80	Left – 4th toe	1
16	Girl	275	Right – 3rd toe	2

Results

A total of 24 toes and fingers of 16 infants (8 boys, 8 girls; mean age: 118.5 [range: 20 to 380] days) were treated for HTS. The right side was affected in 12, the left side in three, and both sides in one patient (Table 1) (*p* = 0.019). The second toe was affected in three patients, the third toe in eleven, the fourth in six, and the fifth in two patients. Both the thumb and the second finger were affected in one patient. All patients were afebrile and had no sign of an infection. The average duration of the symptoms (excessive crying, swelling, redness) was 1.5 (range: 1 to 2) days.

Patients were discharged after normal circulation in the affected appendage was confirmed. All patients healed without any complications (Fig. 4).

Discussion

Hair tourniquet syndrome is an uncommon condition that has been reported mostly in infants and children. The condition may cause the loss of appendage in case of late or missed diagnosis.^{1,2,4–7} Toes have been reported as the most commonly

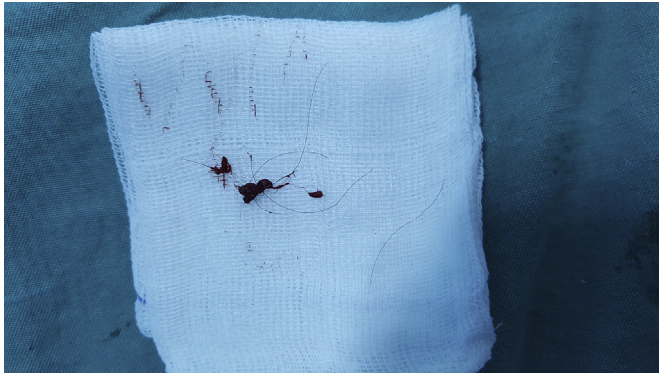


Fig. 3. Removed hair.

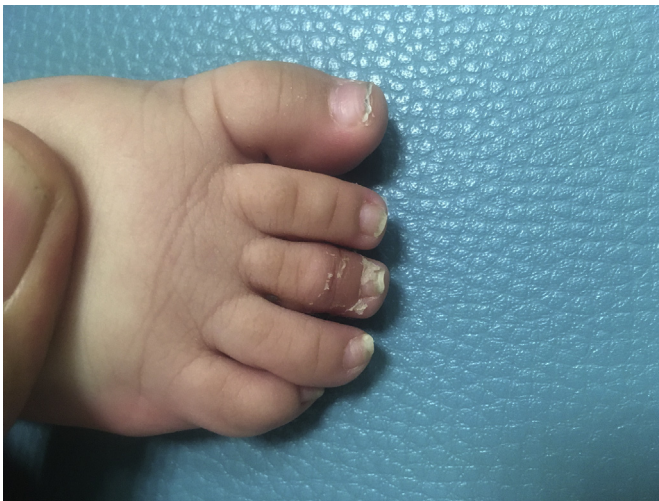

Fig. 4. Healed toe 15 days after the removal of hair (Patient 13).

affected appendage. However, the condition could as well be seen in the fingers, genitals or the uvula.^{6–8} There is no information about the side of the toes mostly affected, but in our series, the right side was statistically significantly higher ($p = 0.019$). HTS is an emergency situation and the removal of hair or thread should be done as soon as possible.

The cause of HTS is still controversial.^{1,3,6,7} Etiology has been reported as accidental in most of the cases.⁸ The infant's repetitive movements in socks or mittens (especially leotard-type clothes) could cause wrapping of the hair or thread.⁹ Laundering socks and mittens and flipping them inside out has been suggested to prevent HTS.² Increased hair shedding due to hormonal alterations of the mother (as the hair enters the telogen effluvium phase, especially in between 2 weeks and 6 months postpartum) is another reported risk factor.^{2,10} Claudet et al reported that 68% of the HTS cases are seen in infants less than 5 months of age.³ In our study, 14 of the 16 patients (87.5%) patients were at 6 months of age or less. Thus, we believe that increased hair loss in the mother is an important risk factor.

Child abuse has been reported as another cause of HTS and should be kept in mind.^{1,3} A knot in the hair or thread could be an indicator of abuse.¹ In our series, no knots were observed. In older children, HTS may be self-inflicted, especially in the genital appendage.⁸ Wrapping the hair around the toe, finger or genitals could be part of cultural behavior to ward off evil spirits or to

prevent nocturnal enuresis.⁸ In our series, parents have not mentioned any such behavior.

The prevalence of the involvement of toes in HTS have been reported as 68–93%.^{3,6} In our series, the prevalence of toe involvement was 93.75%. Claudet et al reported that the right side and the third toe were more affected in HTS, however, they did not report of any statistical significance.³ In our series, the right side was statistically significantly more affected and the third toe was more affected, but similarly not significantly. We have no information, idea or literature data for the significance of this disturbance in the affected side or toe. The cases may be simply coincidental.

Treatment of HTS may be performed by removing the hair surgically or by using chemical depilatories.^{6,11,12} Chemical depilatories can be used especially for superficial hairs and should not be used near mucous membranes (e.g. female genitalia).^{6,11} Chemical depilatories break the disulfide bonds in hair.⁶ Furthermore, more than two interventions with depilatories are not recommended.⁶ In the surgical method, a short longitudinal incision is enough to remove the hair in most cases.¹² For our patients, we preferred surgical removal via a short longitudinal incision (Fig. 2) as there were no depilatories in our hospital and we had no experience with those chemicals.

Congenital constrictive bands, ainhum (dactylolysis spontanea), pseudoainhum, pityriasis rubra pilaris, pachyonychia congenital and mal de Meleda should be kept in mind for differential diagnosis.^{8,9} Ainhum is an unusual condition characterized by painful constriction in toes, with an unknown etiology and eventual spontaneous amputation.^{1,9} The condition has usually been reported in dark-skinned people and in the fifth toe.¹ Pseudoainhum is a condition of constriction caused by amniotic bands, keratotic disorders or posttraumatic scars.⁹ Pityriasis rubra pilaris, pachyonychia congenital and mal de Meleda are skin disorders causing the thickening of the skin and keratoderma.

In conclusion, hair tourniquet syndrome is a rare but appendage-threatening situation if not diagnosed and treated timely and properly. Practitioners should keep this situation in mind and examine the patient completely undressed. Parents should also be educated to control the socks and mittens before dressing up the infants. When HTS is detected, immediate surgical or chemical removal of hair must be performed to save the appendage.

Conflicts of interest

None.

Acknowledgments

We would like to thank to Dr. ErKay Nacar, MD, for his assistance with the statistical analysis.

References

1. Klusmann A, Lenard HG. Tourniquet syndrome – accident or abuse? *Eur J Pediatr.* 2014;163:495–498.
2. Uygun E, Çarkçı E, Ünkar E. Can washing socks without flipping inside out cause hair tourniquet syndrome? A claim with two case reports. *J Pediatr Orthop B.* 2017;26:193–194.
3. Claudet I, Pasian N, Debuissou C, Salanne S, Rekhroukh H. Tourniquet syndrome: interest of a systematic analysis of families' social conditions to detect neglect situations. *Child Abuse Negl.* 2009;33:569–572.
4. Wang M, Schott J, Tunnessen Jr WW. Picture of the month. Hair-thread tourniquet syndrome. *Arch Pediatr Adolesc Med.* 2001;155:515–516.
5. Bizzotto N, Sandri A, Regis D, Carpegiani G, Lavini F, Magnan B. Serious delayed hair toe tourniquet syndrome with bone erosion and flexor tendon lesion. *Case Rep Pediatr.* 2014;2014:592323.

6. Bean JF, Hebal F, Hunter CJ. A single center retrospective review of hair tourniquet syndrome and a proposed treatment algorithm. *J Pediatr Surg.* 2015;50:1583–1585.
7. Claudet I, Pasian N, Maréchal C, Salanne S, Debuissou C, Grouteau E. Hair-thread tourniquet syndrome [Article in French] *Arch Pediatr.* 2010;17:474–479.
8. Mat Saad AZ, Purcell EM, McCann JJ. Hair-thread tourniquet syndrome in an infant with bony erosion: a case report, literature review, and meta-analysis. *Ann Plast Surg.* 2006;57:447–452.
9. Corazza M, Carlà E, Itieri E, Irgili A. What syndrome is this? Tourniquet syndrome. *Pediatr Dermatol.* 2002;19:555–556.
10. Strahlman RS. Toe tourniquet syndrome in association with maternal hair loss. *Pediatrics.* 2003;111:685–687.
11. O’Gorman A, Ratnapalan S. Hair tourniquet management. *Pediatr Emerg Care.* 2011;27:203–204.
12. Serour F, Gorenstein A. Treatment of the toe tourniquet syndrome in infants. *Pediatr Surg Int.* 2003;19:598–600.