

Resection of a Meningioma at Craniocervical Junction through Far Lateral Approach: Two-Dimensional Operative Video

Yong Yan^{1,*} Hongxiang Wang^{1,*} Tao Xu¹ Zhenyu Gong¹ Fan Hong¹ Xu Zhang¹ Juxiang Chen¹

¹Department of Neurosurgery, Changzheng Hospital, Naval Medical University, Neurosurgical Institute of Shanghai, Neurosurgical Institute of PLA, Shanghai, China

Address for correspondence Juxiang Chen, MD, PhD, Department of Neurosurgery, Changzheng Hospital, Naval Medical University, 415 Fengyang Road, Shanghai, China (e-mail: juxiangchen@smmu.edu.cn).

J Neurol Surg B 2019;80(suppl S4):S358–S359.

Abstract

Tumors located in the craniocervical junction region are significantly challenging for surgical resection. We shared our experience of a meningioma at craniocervical junction resected through far lateral approach in a 68-year-old female. The patient presented with intermittent headache with discomfort in the neck and shoulders for 3 years without any positive signs. Magnetic resonance imaging (MRI) revealed a tumor of 3.6 cm × 3.0 cm × 2.5 cm lying at the ventral side of medulla oblongata, with T1 hypointensity, T2 hyperintensity, and a significant enhancement on T1-contrast image. The far lateral approach on the right side was planned to resect the tumor with a park-bench position. The patient underwent a standard craniotomy using a lazy S-shaped incision. The transposition of vertebral artery was performed carefully therein, followed by removal of part of the arches of atlas and axis. After exposure of the tumor, vertebral artery (VA) and posterior inferior cerebellar artery (PICA) adhesive to the lesion could be seen operatively. Truncating the supplying blood vessels of the tumor was taken as the first step, followed by resecting the tumor mass in a piecemeal manner. While preserving VA, PICA, posterior nerves, medulla oblongata, and cervical cord, gross-total resection was achieved under the careful operation. The patient tolerated the procedure well without any neurological deficits. Histological examination confirmed the tumor as a meningioma (World Health Organization [WHO] grade I). Postoperative MRI scan depicted complete resection of the tumor. The patient remained symptom free without any evidence of recurrence during the follow-up period of 1 year. Informed consent was obtained from the patient. The link to the video can be found at: <https://youtu.be/i9H-wS4fF10>.

Keywords

- ▶ operative video
- ▶ meningioma
- ▶ craniocervical junction
- ▶ far lateral approach



www.thieme.com/skullbasevideos

www.thieme.com/jnlsbvideos

* These authors contributed equally to this work.

received
April 22, 2019
accepted after revision
August 24, 2019
published online
October 23, 2019

DOI <https://doi.org/10.1055/s-0039-1700509>.
ISSN 2193-6331.

© 2019 Georg Thieme Verlag KG
Stuttgart · New York

License terms



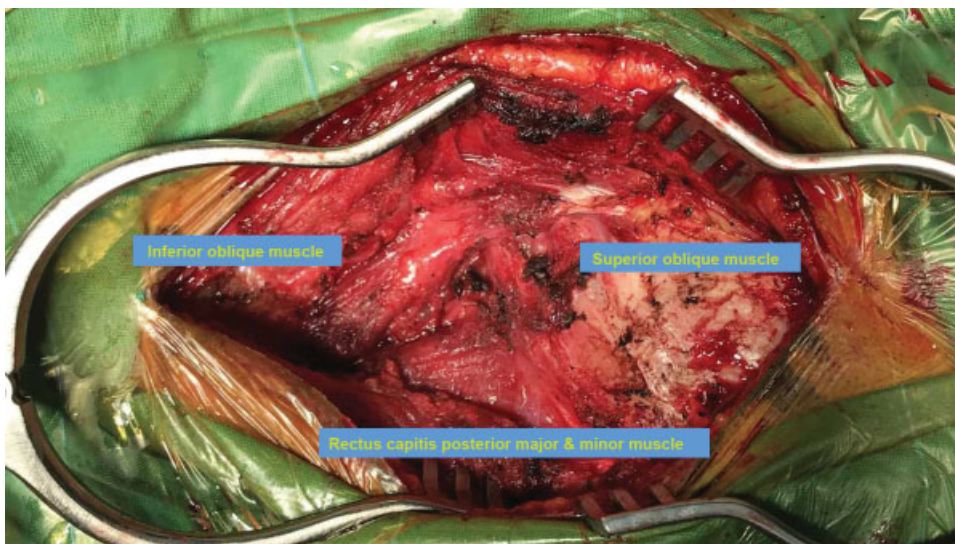


Fig. 1 Exposure of the suboccipital triangle to distinguish vertebral artery.

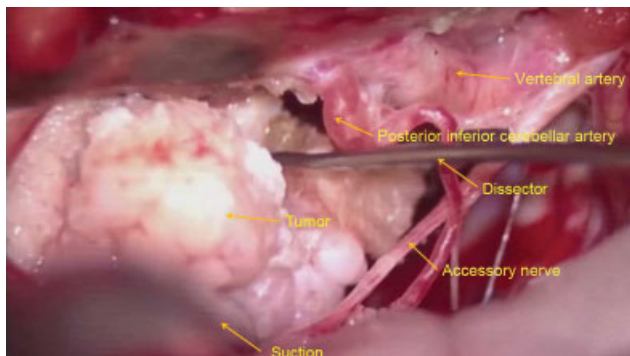


Fig. 2 Intraoperative image shows the exact position and adjacent structures of the tumor.

Conflicts of Interest
None declared.