

Case Report-Inguinoscrotal ureteral hernia diagnosed on micturating cystourethrography

Smiti Sripathi, Rajagopal KV, Chandan Kakkar, Ashwin Polnaya

Department of Radio-diagnosis and Imaging, Kasturba Medical College, Manipal, Karnataka, India

Correspondence: Dr. Smiti Sripathi, Department of Radio-diagnosis and Imaging, Kasturba Medical College, Manipal - 576104, Karnataka, India. E-mail: smitis11@hotmail.com

Abstract

The presence of a ureter within an inguinal hernia is an extremely rare entity, usually discovered incidentally during herniorrhaphy and may pose a surgical risk. Early preoperative diagnosis is crucial to guide proper surgical approach and to preserve renal function.

Key words: Hernia; inguinal; ureteral

Introduction

Inguinal hernias may contain intraperitoneal or retroperitoneal structures, but the presence of a ureter within an inguinal hernia is rare.^[1] Ureteral inguinoscrotal hernias are usually seen in obese elderly men and are generally discovered at herniorrhaphy.^[2] We report the case of an inguinoscrotal hernia in an infant where a grossly dilated ureter was seen as its content.

Case Report

A 10-month-old male infant was referred for USG of the abdomen. The child had antenatally detected left-sided hydronephrosis, along with a history of groin swelling from the first week of life. The swelling was non-progressive in nature and decreased in size on lying down. There was no associated history of vomiting, abdominal distension, or excessive crying during urination.

On examination, a small soft swelling was palpable in

the left groin, which was nontender, compressible, and reducible, with no local rise of temperature. An expansile cough reflux was present. A clinical diagnosis of left inguinal hernia was made.

USG abdomen revealed left-sided grade III hydronephrosis with severe cortical thinning and a grossly dilated ureter throughout its extent. However, herniation of the ureter was not identified at the time of the USG examination. There was grade I hydronephrosis on the right side as well. A micturating cystourethrogram (MCU) was suggested to rule out a vesicoureteric reflux (VUR).

MCU during the filling [Figure 1A] and voiding [Figure 1B] phases showed a grossly dilated and tortuous left ureter in the left inguinoscrotal region with grade V VUR [Figure 1C]. A normal urethra was seen in the voiding phase [Figure 1B]. A radiological diagnosis of grade V VUR with ureter as a content of the left inguinal hernia was considered.

Dimercaptosuccinic acid (DMSA) scintigraphy was performed, which showed a nonfunctioning left kidney. The right kidney showed normal parenchymal uptake with no evidence of scarring.

Left inguinal herniotomy with ureterostomy was done. A hugely dilated ureter was present adjacent to the hernial sac, extending into the scrotal sac, suggestive of a paraperitoneal type of inguinoscrotal ureteral hernia. The postoperative period was uneventful. A DMSA scan repeated after one

Access this article online

Quick Response Code:



Website:
www.ijri.org

DOI:
10.4103/0971-3026.85368

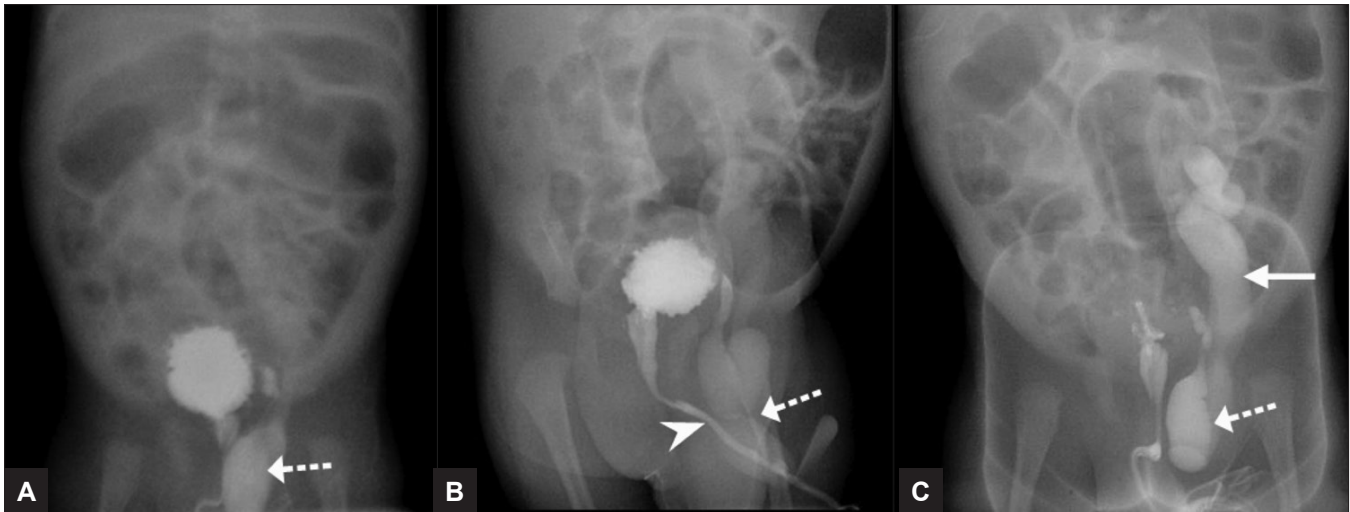


Figure 1 (A-C): Micturating cystourethrogram (MCU) shows a dilated ureter (dotted arrow) in the inguinal hernia with a well-visualized urethra (arrowhead in B) and grade V vesicoureteric reflux (VUR) (arrow in C)

month showed a nonfunctioning kidney (2%) on the left with a normally functioning kidney on the right. A left nephrectomy was planned for the patient but the patient was lost to follow-up.

Discussion

An inguinal hernia containing ureter is a rare entity.^[1] Other sites where the ureter can herniate include femoral, sciatic, para-iliac, and thoracic.^[3,4]

Patients with ureteral hernias rarely have any urinary symptoms and usually present with a mass in the groin.^[2,5] It is important to identify the presence of the ureter prior to surgery in order to prevent injury to the ureter during hernia repair.^[6] There are two types of ureteroinguinal hernias—paraperitoneal and extraperitoneal. Approximately 80% of ureteral hernias are paraperitoneal and 20% are extraperitoneal. The paraperitoneal type is associated with a peritoneal sac [Figure 2A], whereas an extraperitoneal herniation, which is rare, contains only a herniated ureter without a peritoneal sac [Figure 2B].

The paraperitoneal hernia is an indirect inguinal hernia that occurs due to traction on the underlying abdominal structures due to which the ureter gets pulled into the scrotum.^[7] Abdominal organs like the urinary bladder, colon, etc., can make up the wall of the indirect hernial sac. The paraperitoneal hernia is not associated with other congenital renal or ureteric anomalies.^[5,8]

Extraperitoneal ureteral herniation is associated with congenital anomalies of the urinary tract.^[9] In this type of hernia, there may be an abnormal attachment of the ureter to the genitofemoral ligaments and Wolffian duct.^[6] Retroperitoneal fat may be present in the hernia and the

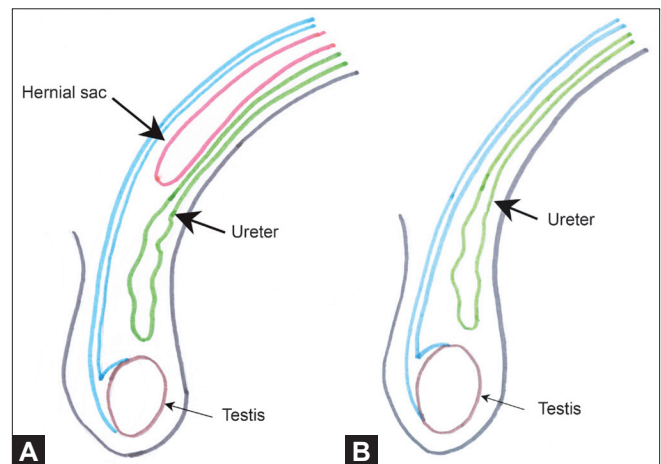


Figure 2 (A, B): Line diagram depicts paraperitoneal (A) and extraperitoneal (B) types of ureteral inguinoscrotal hernias

fat is often mistaken to be an indirect hernial sac. These hernias are smaller in size and are difficult to palpate. Unlike paraperitoneal hernia, extraperitoneal hernias present with urinary symptoms.^[5] Crossed ectopia and nephrotosis are the most common associated congenital anomalies.^[2,5]

Roach *et al.*, described the CT scan findings, showing the path of the dilated ureter into the inguinal hernia.^[10] There may be hydronephrosis in such cases, due to marked angulation of the ureter or due to direct ureteral compression because of inflammation of other herniated contents.^[11] In our case, the hydronephrosis seen on USG was most likely due to vesicoureteric reflux. Inguinoscrotal ureteral hernias have also been described in postrenal transplant patients where hydronephrosis is seen due to a sharp stenosing bend of the ureter in the hernial sac, the ascending portion of the ureter remaining thin.^[11]

So far, 140 cases have been described in the world literature;^[12,13] however, only one such case has been diagnosed on a preoperative urogram.^[14] The diagnosis of ureteral inguinoscrotal hernia is often missed because of the absence of urinary symptoms. Increased fatty tissue in the hernia should raise the suspicion of ureter within the hernial sac. CT scan clinches the diagnosis in patients with irreducible inguinal hernias presenting with urinary symptoms. Intravenous pyelography (IVP) may have a role when CT scan is not readily available. Surgical treatment usually involves replacement of the ureter into the retroperitoneum along with hernial repair.

With the widespread use of multiplanar imaging, it is likely that more such cases will be seen preoperatively.

References

- Percival WL. Ureter within a sliding hernia. *Can J surg* 1983;26: 283, 286.
- Mantle M, Kingsnorth AN. An unusual cause of back pain in an achondroplastic man. *Hernia* 2003;7:95-6.
- Hwang CM, Miller FH, Dalton DP, Hartz WH. Accidental ureteral ligation during an inguinal hernia repair of patient with crossed fused renal ectopia. *Clin Imaging* 2002;26:306-8.
- Giglio M, Medica M, Germinale F, Raggio M, Campodonico F, Stubinski R, *et al.* Scrotal extraperitoneal hernia of the ureter: Case report and literature review. *Urol Int* 2001;66:166-8.
- Rocklin MS, Apelgren KN, Slomski CA, Kandzari SJ. Scrotal incarceration of the ureter with crossed renal ectopia: Case report and literature review. *J Urol* 1989;142:366-8.
- Ballard JL, Dobbs RM, Malone JM. Ureteroinguinal hernia: A rare companion of sliding inguinal hernia. *Am Surg* 1991;57:720-2.
- Goldin RR, Rosen RA. Effects of inguinal hernias upon the bladder and ureters. *Radiology* 1975;115:55-7.
- Powell MC, Kapila L. Bilateral megaureters presenting as an inguinal hernia. *J Pediatr Surg* 1985;20:175-6.
- Zmora O, Schachter PP. Sliding inguinal hernia containing the ureter: A case report. *J Urol* 1996;155:1387.
- Roach SC, Moulding F, Hanbidge A. Inguinal herniation of ureter. *AJR Am J Roentgenol* 2005;185:283.
- Verbeeck N, Niedercorn JB, McIntyre D, Pouthier D, Lamy S. Assessment of renal graft obstruction due to ureteral inguinal hernia: US detection and 3DMR confirmation. *JBR-BTR*, 2007;90:132-4.
- Bertolaccini L, Giacomelli G, Bozzo RE, Gastaldi L, Moroni M. Inguino-scrotal hernia of a double district ureter: A case report and literature review. *Hernia* 2005;9:291-3.
- Agarwal P, Pujahari AK. Ureter in sliding inguinal hernia. *Med J Armed Forces India [MJAFI]* 2009;65:289.
- Giuly J, Francois G, Giuly D, Leroux C, Nguyen Cat CR. Intrascrotal herniation of the ureter. *Ann Chir* 2002;127:218-20.

Cite this article as: Sripathi S, Rajagopal KV, Kakkar C, Polnaya A. Case Report-Inguinoscrotal ureteral hernia diagnosed on micturating cystourethrography. *Indian J Radiol Imaging* 2011;21:199-201.
Source of Support: Nil, **Conflict of Interest:** None declared.

IJRI now Indexed with PubMed

NCBI Resources How To

PubMed.gov
U.S. National Library of Medicine
National Institutes of Health

Search: PubMed
RSS Save search Limits Advanced search Help

Indian Journal of Radiology and Imaging[Jour] AND 2011[mdat] Search Clear

Display Settings: Abstract, 20 per page, Sorted by Recently Added Send to:

Results: 1 to 20 of 22 << First < Prev Page 1 of 2 Next > Last >>

Indian J Radiol Imaging, 2011 Jan;21(1):71-2.

1. **Business of radiology/radiologist in business.**
 Sripathi S.
 Department of Radio-diagnosis and Imaging, Kasturba Medical College, Manipal University, Karnataka, India E-mail: smitis11@hotmail.com.
 PMID: 21431042 [PubMed - in process] PMCID: PMC3056380 Free PMC Article
 Related citations

Free Full Text @ www.ijri.org FREE full text article in PubMed Central

Indian J Radiol Imaging, 2011 Jan;21(1):70-1.

2. **Millionaire radiology.**
 Bandopadhyaya I.
 437, Asiad Village Complex, New Delhi - 110 049, India. E-mail: dr.indraneel@gmail.com.
 PMID: 21431041 [PubMed - in process] PMCID: PMC3056379 Free PMC Article
 Related citations

Free Full Text @ www.ijri.org FREE full text article in PubMed Central